Research Square

Preprints are preliminary reports that have not undergone peer review. They should not be considered conclusive, used to inform clinical practice, or referenced by the media as validated information.

Recurrence and retreatment of anterior communicating artery aneurysm after endovascular treatment

Chang Ki Jang
Yonsei University College of Medicine https://orcid.org/0000-0001-8715-8844

Joonho Chung
Yonsei University College of Medicine

Jae Whan Lee
Yonsei University College of Medicine

Seung Kon Huh
Muhas academic medical center

Nak-Hoon Son
Yonsei University College of Medicine

Keun Young Park (KYPARK78.MD@gmail.com)
Yonsei University College of Medicine https://orcid.org/0000-0002-3254-4577

Research article

Keywords: aneurysm, anterior communicating artery, recurrence

Posted Date: April 10th, 2020

DOI: https://doi.org/10.21203/rs.3.rs-20971/v1

License: This work is licensed under a Creative Commons Attribution 4.0 International License. Read Full License

Version of Record: A version of this preprint was published on July 29th, 2020. See the published version at https://doi.org/10.1186/s12883-020-01871-5.

Abstract

Background To describe our experiences with endovascular treatment (EVT) of anterior communicating artery (Acom) aneurysms (AcomAs), and to evaluate the incidence of recurrence and risk factors for recurrence and retreatment Methods The study comprised 260 patients who were treated at a single center between January 2010 and December 2018. Patients who had EVT, including stent-assisted coiling of AcomA, were included. All medical records were retrospectively reviewed. The incidence of recurrence and risk factors for recurrence and retreatment were evaluated. Univariate analysis and multivariate logistic regression analysis were conducted. Results Recurrence of AcomA occurred in 38 (14.6%) patients. Mean follow-up duration was 27 months. Multivariate logistic regression analysis indicated that ruptured aneurysm (odds ratio [OR] 3.55, P=0.001), dome direction (anterior) (OR 3.86, P=0.002), maximal diameter (OR 1.19, P=0.02), and mean age (OR 0.96, P=0.02) were independent risk factors for aneurysm recurrence. Among cases of recurrence, 10 (3.8%) patients had major recurrence. Ruptured aneurysm (OR 14.7, P=0.004), maximal diameter (OR 1.56, P=0.02), inflow angle (OR 1.04, P=0.03), and Raymond-Roy classes II and III (incompletely occluded status of coiling) (OR 6.19, P=0.03) showed significant relation to retreatment in multivariate logistic regression analysis. Conclusions In our study, recurrence rate of AcomA after EVT was 14.6%. Rupture, anterior dome direction, maximal diameter, and mean age were significantly associated with recurrence. Retreatment rate of recurrent AcomA cases after EVT was 3.8%. Patients with AcomA with large inflow, rupture, large size, or incomplete occlusion may be at a high risk of retreatment of recurring aneurysm.

Introduction

Anterior communicating artery aneurysm (AcomA) has a higher risk of rupture than other aneurysms.[1] Therefore, treatment of AcomA is essential and critical for prevention of aneurysmal subarachnoid hemorrhage (SAH). However, surgical treatment of AcomA remains a challenge as it can cause morbidity to patients because it may require rectus gyrus suction and may even cause olfactory nerve injury. AcomA shows a variety of anomalies and complex anatomy like fenestrated, triplicated, and azygous anterior cerebral artery (ACA). It also has many perforator and associated vessels, like the recurrent artery of Heubner and bilateral A1 and A2.[2–4]

Since endovascular treatment has rapidly replaced surgical clipping, Alshekhlee reported that hospital mortality was higher in patients who had surgical clipping than in those who had endovascular coiling (1.6% and 0.57% respectively).[5] However, retreatment after aneurysmal treatment was performed in 17.4% of patients in the endovascular treatment (EVT) group and in 3.8% of patients in the surgical clipping group in an International Subarachnoid Aneurysm Trial (ISAT) study.[6] The study also found that young age, large lumen size, and incomplete occlusion were risk factors for retreatment after EVT. O'Neil et al reported in their systemic analysis that endovascular coiling resulted in significantly lower treatment-related morbidity compared with clipping, but clipping resulted in significantly lower angiographic

recurrence and retreatment.[7] The purpose of this study was to evaluate recurrence and retreatment rates and their risk factors after endovascular treatment of AcomA.

Materials And Methods

Patients' Population

This study was approved by our Institutional Review Board, and the requirement for patients' informed consent was waived due to its retrospective design.

Between January 2010 and December 2018, a total of 514 AcomAs were consecutively treated by either surgical or endovascular method in our institute. Patients who had vasculitis or infectious, fusiform, and blood blister-like aneurysms were excluded from this study. Patients whose aneurysms were treated with flow diverter were also excluded, and finally, 260 AcomA patients who underwent coiling with or without stents were included. All clinical and radiological data were obtained from electronic medical records and a prospectively registered aneurysm database, and they were retrospectively reviewed.

Radiologic Evaluation

All radiologic images were retrospectively reviewed by two investigators.

At the initial coiling, all aneurysms were assessed with 3D angiogram (Allura Xper FD20/20 and Allura Clarity, Philips Medical Systems, Best, The Netherlands). Based on 3D angiogram, aneurysm factors, including maximal size, size ratio, inflow angle, hypoplastic A1, and dome direction were evaluated. Size ratio was calculated by dividing the aneurysm maximal size (mm) by the average size of both A1 segments (mm).[8] Inflow angle was defined as the angle between the maximal height of the aneurysm and the parent vessel.[9]

Hypoplastic A1 was defined as A1 with diameter less than 50% of the diameter of contralateral A1.[10] Additionally, we dichotomized aneurysm direction into anterior or posterior by drawing an imaginary perpendicular line to the anterior cranial fossa using sagittal view of computed tomography angiography (CTA).[11] For the correction of different values between the two investigators, mean values were obtained.

After the initial coiling, routine imaging follow-up was conducted with 3.0-T magnetic resonance angiography (MRA) at 6, 18, 30, and 60 months. Post-treatment and follow-up angiographic occlusion grade were assessed according to Raymond-Roy classification, wherein class I is defined as complete occlusion, class II as neck remnant, and class III as sac remnant.[12] Recurrence was defined as any progression of Raymond-Roy class. All class III recurrent aneurysms were further evaluated with 3D angiogram.

Retreatment

Retreatment was considered for aneurysms if volume of recurred sac was ≥ 20.0 mm^3 on 3D angiogram. Retreatment was planned based on consensus by a multidisciplinary team.

Statistical Analysis

Univariate analysis was performed to determine the association of procedure-related complications with other factors. The statistical significance of recurrence was analyzed using the chi-square test for categorical, nominal variables, or the logistic regression test for continuous, numerical variables. Multivariate logistic regression analysis was performed for variables with an unadjusted effect and a P-value < 0.20 in univariate analysis to determine independent associations of recurrence and retreatment with other factors. Results of binary logistic regression were reported as odd ratios (ORs) with P-value < 0.05 for a 95% confidence interval (CI), which was considered statistically significant. Correlation analysis and chi-square test were performed to identify the strength of relationships between age and statistically significant factors such as maximal diameter, rupture status, and anterior dome direction. All statistical analyses were performed with Statistical Package for the Social Sciences (SPSS) version 19.0 (IBM Corp., Armonk, NY, USA).

Results

A total of 260 patients (male:female = 134:126; mean age, 57.6 years) with AcomAs underwent coiling procedure. Among them, 157 patients had hypertension (60.3%), and 115 were smokers (44.2%).

There were 183 unruptured (70.4%) and 77 ruptured (29.6%) aneurysms. Overall, mean maximal diameter of aneurysms was 5.3 mm (range 2–16.6), and mean size ratio was 2.41 (range 0.9–8.5). Mean inflow angle was 148.6° (range 75–180°). Hypoplastic A1 was noted in 82 patients (31.5%).

All aneurysms were successfully treated without (n = 208, 80.0%) or with (n = 52, 20.0%) stents, and immediate post-procedural angiogram showed 167 Raymond-Roy class I (64.3%), 75 class II (28.8%), and 18 class III (6.9%) aneurysms, respectively.

Recurrence

Follow-up MRA or 3D angiogram was done for all the patients (mean duration, 27 months; range 1–110).

Recurrence was noted in 38 patients (14.6%). In univariate analysis, age (OR 0.96, 95% CI 0.93 to 0.99, P = 0.01), rupture status (OR 3.66, 95% CI 1.81 to 7.52, P = 0.001), maximal diameter (OR 1.20, 95% CI 1.06 to 1.37, P = 0.005), size ratio (OR 1.50, 95% CI 1.17 to 1.95, P = 0.001), and dome direction (anterior) (OR 2.94, 95% CI 1.38 to 6.86, P = 0.007) were significant risk factors for recurrence. In multivariate analysis, age (OR 0.96, 95% CI 0.93 to 0.99, P = 0.02), rupture status (OR 3.55, 95% CI 1.62 to 7.91, P = 0.001), maximal diameter (OR 1.19, 95% CI 1.03 to 1.39, P = 0.02), and dome direction (anterior) (OR 3.86, 95% CI 1.67 to 9.94, P = 0.002) were statistically significant. These results are shown in Table 1. Correlation analysis and chi-square test performed for evaluation of relation of age and statistically significant factors. As a result, p value of correlation analysis between age and maximal diameter was 0.068 which

was not statistically significant at the significance level of 5%, but the p-value was close to being statistically significant. The other factors; ruptured status and dome direction was also not statistically significant correlation with age.

Table 1. Risk factors for recurrence after endovascular coiling of anterior communicating artery aneurysm

(N=260)		Recurrence (n=38)	No recurrence (n=222)	Univariate analysis OR (95% CI)	Univariate analysis P-value	Multivariate analysis OR (95% CI)	Multivariate analysis P-value
Patient factor	Male	24 (63.1%)	110 (49.5%)	1.75 (0.87–3.63)	0.12		
	Mean age (yr)	53.58 ± 11.7	58.3 ± 10.84	0.96 (0.93–0.99)	0.01*	0.96(0.93–0.99)	0.02*
	Hypertension	25 (65.7%)	132 (59.4%)	1.31(0.65–2.77)	0.46		
	Smoking	15 (39.4%)	100 (45.0%)	0.80 (0.39–1.59)	0.52		
Aneurysm factor	Rupture	21 (55.2%)	56 (25.2%)	3.66 (1.81–7.52)	0.001*	3.55 (1.62–7.91)	0.001*
	Maximal diameter	6.3±3.0	5.17±2.1	1.20 (1.06–1.37)	0.005*	1.19 (1.03–1.39)	0.02 *
	Size ratio	3.0±1.6	2.3±1.0	1.50 (1.17–1.95)	0.001*	1.07 (0.69–1.68)	0.76
	Inflow angle	152.8±23.0	147.9±29.1	1.01 (0.99–1.02)	0.11		
	Dome direction (Anterior)	29 (76.3%)	116 (52.5%)	2.94 (1.38–6.86)	0.007*	3.86 (1.67–9.94)	0.002*
	Hypoplastic A1	13 (34.2%)	69 (31.0%)	1.15 (0.54–2.35)	0.70		
Treatment factor	Stent usage	5 (13.1%)	47 (21.1%)	0.56 (0.19–1.41)	0.25		
	Raymond classification (II or III)	18 (47.3%)	75 (33.7%)	1.76 (0.87–3.54)	0.10		

OR= odds ratio, CI = confidence interval

* variable significantly related to recurrence

Table 2. Risk factors for retreatment after endovascular coiling of anterior communicating artery aneurysm

(N=260)		Retreatment (n=10)	No retreatment (n=250)	Univariate analysis OR (95% CI)	P-value	Multivariate analysis OR (95% CI)	P-value
Patient factor	Male	4 (40%)	130 (52%)	0.62 (0.15–2.21)	0.46		
	Mean age (yr)	50.7 ± 12.3	57.9 ± 10.9	0.94 (0.89–1.00)	0.04*	0.95(0.88–1.01)	0.12
	Hypertension	6 (60%)	151 (60.4%)	0.98 (0.27–3.93)	0.97		
	Smoking	4 (40%)	111 (44.4%)	0.83 (0.21–2.99)	0.78		
Aneurysm factor	Ruptured	8 (80%)	69 (27.6%)	10.4 (2.55–70.6)	0.003*	14.7 (2.77–127.9)	0.004*
	Maximal diameter	7.15±3.7	5.27±2.2	1.25 (1.02–1.50)	0.01*	1.56 (1.05–2.36)	0.02 *
	Size ratio	2.9±2.0	2.3±1.1	1.35 (0.87–1.90)	0.11		
	Inflow angle	162.8±27.8	148.0±28.8	1.02 (1.00–1.06)	0.12	1.04 (1.01–1.09)	0.03*
	Dome direction (Anterior)	7 (70%)	138 (55.2%)	1.89 (1.51–8.94)	0.036	5.03 (0.97–36.6)	0.07
	Hypoplastic A1	3 (30%)	79 (31.6%)	0.93 (0.20–3.43)	0.91		
Treatment factor	Stent usage	1 (10%)	51 (20.4%)	0.43 (0.02–2.39)	0.43		
	Raymond classification (II or III)	6 (60%)	87 (34.8%)	2.81 (1.78–11.24)	0.01*	6.19 (1.19–40.8)	0.03*

OR = odds ratio; CI = confidence interval

* variable significantly related to retreatment

Retreatment

Among the 38 recurrent cases, 10 cases (3.8%) showed major recurrence that needed retreatment. Mean follow-up duration of retreatment cases was 24 ± 18 months (median 18 months, range 2–63 months). Retreatment was done within 1–6 months after recurrence which need for retreatment was concluded. One patient had clipping surgery. Three patients were treated with EVT using double catheter technique (Fig. 1), and the other six patients with EVT using stent assisted coiling (SAC) (Fig. 2). The detail of factors is shown in Table 2. In univariate analysis, age, ruptured status, maximal diameter, and Raymond-Roy classification were statistically significant. Ruptured status (OR 14.7, 95% CI 2.77 to 127.9, P = 0.004), maximal diameter (OR 1.56, 95% CI 1.05 to 2.36, P = 0.02), inflow angle (162.8° and 148.0° for retreatment and no retreatment groups respectively; OR 1.04, 95% CI 1.01 to 1.09, P = 0.03), and

Raymond-Roy class II or III (60% and 34.8% for retreatment and no retreatment groups respectively; OR 6.19, 95% CI 1.19 to 40.8, P = 0.03) were significantly associated with retreatment in multivariate analysis.

Case Presentation

Case 1 (Fig. 1)

A 55-year-old female patient underwent an emergency computed tomography (CT) scan due to mental change. Ruptured AcomA was noted. Maximal size of aneurysm was 16.6 mm and neck size 6.6 mm. Emergent EVT was done. Immediate post-embolization imaging showed neck remnant occlusion. Patient recovered well and was discharged without neurological deficit. After 1 year, cerebral angiography revealed major recanalization of aneurysm. Surgical clipping was done. Coil mass within sac was visible. Complete clipping was done without neck remnant and both A2 segments were safely preserved. No more recurrence was seen after 2 years.

Case 2 (Fig. 2)

A 57-year-old male patient came into the emergency room with severe bursting headache. Ruptured AcomA was noted. Maximal size of aneurysm was 4.5 mm and neck size was 3.1 mm. Emergent EVT was done. Immediate post-embolization imaging showed near-complete occlusion without remnant status. After 1 year, cerebral angiography revealed major recanalization of aneurysm. Ipsilateral A1-2 stent-assisted coil embolization with LVIS® Jr. stent was done for dense coil packing. After 1 year, MRA revealed small neck compaction of aneurysm.

Discussion

This study evaluated the incidence of recurrence and risk factors for recurrence and retreatment of anterior communicating artery aneurysm after endovascular treatment. We found that the recurrence rate of AcomA after EVT was 14.6%, and its associated factors were younger age, rupture status, bigger aneurysm size, and anterior dome direction. The rate of retreatment, which signifies major recurrence, was 3.8%. Patients with AcomA with a large inflow angle, ruptured status, large aneurysm size, and incomplete aneurysm occlusion may be at a high risk of retreatment.

Many studies have shown that surgical procedure for AcomA can lead to post-operative deficits such as memory impairment and personality changes.[13,14] Ramos et al also reported that gyrus rectus resection can cause cognitive and psychiatric dysfunction caused by orbital prefrontal cortex lesion or a disconnection in the ventromedial circuits.[15] Another key problem of this surgery is olfactory nerve injury. In some cases of clipping of AcomA, the frontal lobe inevitably is retracted to some degree in order to access the aneurysm. During frontal lobe retraction, the olfactory nerve is also retracted from the cribriform plate. Park et al reported objective olfactory dysfunction rate of 10.8% in their study.[16] Because of the risks of these complications, minimal invasive surgery like keyhole approach with eyebrow or palpebral incision was introduced in AcomA surgery.[17–19] These approaches reduced the amount of brain

retraction and rectus gyrectomy. Some authors even advocated for use of orbitotomy approach,[20,21] and recently, endoscopic endonasal approach was reported for AcomA surgery.[22]

Vascular anomalies such as multiple, fenestrated, or azygous artery are common in Acom.[23–26] These anomalies originate during embryologic development. The prevalence of duplication of Acom is 18% and that of fenestration of Acom is 12–21%.[27] Surgical clipping of Acom is difficult when anomalies are present.[2] Because of these factors, endovascular treatment is becoming a good alternative for AcomA treatment.

O'Neill et al reported that coiling was significantly related to lower rate of treatment-related morbidity compared with clipping (0.8% vs 4.4% for coiling and clipping respectively; P = 0.001), whereas clipping was significantly related to lower angiographic recurrence (4.9% vs 0% for coiling and clipping respectively; P = 0.001) in systemic analysis.[7] Many other studies reported that EVT is associated with a high rate of recurrence and retreatment.[28–30]

Recurrence

Large aneurysm, rupture status, incomplete occlusion, posterior circulation, and incorporating artery with aneurysm are the well-known risk factors for aneurysm recurrence after EVT.[12,31] Park et al reported that total recurrence and retreatment rates were 25.7% (44/171) and 10.5% (18/171), respectively after EVT of saccular aneurysm larger than 8 mm.[32] They revealed that large size, rupture status, low dome-to-neck ratio, and initial incomplete occlusion status were independent risk factors for recurrence. In this present study, age, rupture status, large aneurysm size, and anterior dome direction were the significant factors for recurrence.

Corns et al reported that younger age predisposed to a higher risk of recurrence in ruptured aneurysm.[33] However, their study did not give definite explanation for this observation. In some studies, younger age was a predictor of growth of aneurysm after clipping,[34,35] but this age effect is difficult to understand. Our study also showed that younger patients had more recurrence than older patients. This age effect can be explained in two ways. One, there was a bias toward more frequent surveillance imaging in younger patients. Second, is the correlation with other factors that signify recurrence. We therefore performed a correlation analysis, after which correlation between age and maximal diameter was not statistically significant at the significance level of 5%, although the P-value of 0.068 was close to being statistically significant. Therefore, we cannot completely ignore the association (correlation coefficient = 0.114).

Anterior dome direction is known to reflect aneurysm hemodynamics, including wall shear stress and flow velocity, which play important roles in the growth and rupture of aneurysm.[36] This may explain its significant association with recurrence in this study.

Retreatment

In ISAT study, younger age, large lumen size, and incomplete occlusion were risk factors for late retreatment after EVT.[6] Smoking is known as one of the most important risk factors for formation and rupture of intracranial aneurysm,[37–39] and that association was explained by inhibitory effect of cigarette smoke on alpha 1-antitrypsin (A1AT).[40] Brinjikji however reported that smoking was not an independent risk factor for aneurysm recurrence (OR = 1.04, P = 0.87) and retreatment (OR = 0.82, P = 0.50) for patients receiving EVT for aneurysm.[41] Recently, Futchko found that history of smoking—whether current or former—was associated with a significantly increased risk of aneurysm recurrence. The odds ratios for aneurysm recurrence in current and former smokers were 2.73 and 2.69, respectively, compared with never smokers. The author accounted for the difference between the Brinjikji's study and their study. The former study exclusively used balloon-assisted coiling, whereas the latter study used stent-assisted coiling.[42] Our study showed no association between smoking and recurrence.

Using computational fluid dynamic (CFD) analysis, Merih et al identified inflow angle as an independent and robust rupture status differentiator in intracranial aneurysm.[9] CFD showed that increasing inflow angle led to deeper migration of flow with higher peak flow velocities and a greater transmission of kinetic energy into the dome. Wenjun et al also revealed that an inflow angle of over 90° and incomplete occlusion were associated with aneurysm recurrence in unruptured aneurysm after EVT. Our study showed that inflow angle was not related with recurrence, but associated with retreatment.

Rupture status and large aneurysm size were not only associated with recurrence, but also with retreatment. On the other hand, incomplete coil packing status was associated with retreatment but not with recurrence.

Limitation

This study had several limitations. First, the decision to retreat relied on the clinician's decision, so it was highly subjective. This could have led to bias. Second, recurrence and retreatment cases were few compared with the other group which showed no recurrence and retreatment. This could be a factor in lowering the statistical reliability of the results. Third, inflow angle was not accurate. Even though we used 3D rotation image, there could be inter-observer difference in measurement. Fourth, inflow angle could change after EVT especially in SAC. However, in this study, only 52 patients (20%) were treated with SAC.

Conclusions

In our study, recurrence rate of AcomA after endovascular treatment was 14.6%. Younger age, rupture status, large aneurysm size, and anterior dome direction were significantly associated with recurrence. Retreatment rate of recurrent AcomA cases after EVT was 3.8%. Patients with AcomA with a large inflow, rupture status, large size, and incomplete occlusion may be at a high risk of retreatment of recurring aneurysm. These patients need to be closely followed up after EVT.

Abbreviations

AcomA: anterior communicating artery aneurysm

A1AT: alpha 1-antitrypsin

ACA: anterior cerebral artery

CFD: computational fluid dynamic

CI: confidence interval

CT: computed tomography

EVT: endovascular treatment

ISAT: International Subarachnoid Aneurysm Trial

MRA: magnetic resonance imaging

OR: odd ratio

SAC: stent assisted coiling

SAH: subarachnoid hemorrhage

SPSS: Statistical Package for the Social Sciences

Declarations

Ethics approval and consent to participate

All procedures performed in the studies involving human participants were in accordance with the ethical standards of our Institutional Review Board with the 1964 Helsinki Declaration and its later amendments or comparable ethical standards. In this retrospective study, the requirement for informed consent was waived.

Consent for publication

Not applicable

Availability of data and materials

The datasets used and analyzed during the current study are available from the corresponding author on reasonable request.

Competing interests

The authors declare that they have no conflict of interest.

Funding

No funding was received for this study.

Authors' contributions

CKJ had contributions to the concept of the study, interpretation of data, drafting the manuscript, and revising the manuscript. JC had contributions to the acquisition of data, analysis of data, and revising the manuscript. JWL and SKH had contributions to the interpretation of data and revising the manuscript. NHS had contributions to statistical significance analysis. KYP contributed to the concept of the study, revising and editing the manuscript, and supervising the whole process of the study. All authors have approved the final version of the manuscript.

Acknowledgements

None

References

1. Mira JM, Costa FA, Horta BL, Fabiao OM. Risk of rupture in unruptured anterior communicating artery aneurysms: meta-analysis of natural history studies. Surg Neurol. 2006;66(Suppl 3):12-9. discussion S9.
2. Tomita H, Saito K. A difficult-to-treat Acom aneurysm with the combined vascular anomaly of Acom fenestration and accessory anterior cerebral artery. Surg Neurol Int. 2018;9:67.
3. Serizawa T, Saeki N, Fukuda K, Yamaura A. [Microsurgical anatomy of the anterior communicating artery and its perforating arteries important for interhemispheric trans-lamina terminalis approach: analysis based on cadaver brains]. No Shinkei Geka. 1994;22(5):447–54.
4. Rosner SS, Rhoton AL Jr, Ono M, Barry M. Microsurgical anatomy of the anterior perforating arteries. J Neurosurg. 1984;61(3):468–85.
5. Alshekhlee A, Mehta S, Edgell RC, et al. Hospital mortality and complications of electively clipped or coiled unruptured intracranial aneurysm. Stroke. 2010;41(7):1471–6.
6. Campi A, Ramzi N, Molyneux AJ, et al. Retreatment of ruptured cerebral aneurysms in patients randomized by coiling or clipping in the International Subarachnoid Aneurysm Trial (ISAT). Stroke. 2007;38(5):1538–44.
7. O'Neill AH, Chandra RV, Lai LT. Safety and effectiveness of microsurgical clipping, endovascular coiling, and stent assisted coiling for unruptured anterior communicating artery aneurysms: a systematic analysis of observational studies. J Neurointerv Surg. 2017;9(8):761–5.

8. Dhar S, Tremmel M, Mocco J, et al. Morphology parameters for intracranial aneurysm rupture risk assessment. Neurosurgery. 2008;63(2):185–96. discussion 96 – 7.
9. Baharoglu Merih I, Schirmer Clemens M, Hoit Daniel A, Gao B-L, Malek Adel M. Aneurysm Inflow-Angle as a Discriminant for Rupture in Sidewall Cerebral Aneurysms. Stroke. 2010;41(7):1423–30.
10. Kwak R, Niizuma H, Suzuki J. Hemodynamics in the anterior part of the circle of Willis in patients with intracranial aneurysms: a study of cerebral angiography. Tohoku J Exp Med. 1980;132(1):69–73.
11. Matsukawa H, Uemura A, Fujii M, Kamo M, Takahashi O, Sumiyoshi S. Morphological and clinical risk factors for the rupture of anterior communicating artery aneurysms. J Neurosurg. 2013;118(5):978–83.
12. Raymond J, Guilbert F, Weill A, et al. Long-term angiographic recurrences after selective endovascular treatment of aneurysms with detachable coils. Stroke. 2003;34(6):1398–403.
13. Hillis AE, Anderson N, Sampath P, Rigamonti D. Cognitive impairments after surgical repair of ruptured and unruptured aneurysms. J Neurol Neurosurg Psychiatry. 2000;69(5):608–15.
14. Böttger S, Prosiegel M, Steiger HJ, Yassouridis A. Neurobehavioural disturbances, rehabilitation outcome, and lesion site in patients after rupture and repair of anterior communicating artery aneurysm. J Neurol Neurosurg Psychiatry. 1998;65(1):93–102.
15. Ramos A, Chaddad-Neto F, Joaquim AF, et al. The microsurgical anatomy of the gyrus rectus area and its neurosurgical implications. Arq Neuropsiquiatr. 2009;67(1):90–5.
16. Park J, Son W, Goh DH, Kang DH, Lee J, Shin IH. Height of aneurysm neck and estimated extent of brain retraction: powerful predictors of olfactory dysfunction after surgery for unruptured anterior communicating artery aneurysms. J Neurosurg. 2016;124(3):720–5.
17. Abdel Aziz KM, Bhatia S, Tantawy MH, et al. Minimally invasive transpalpebral "eyelid" approach to the anterior cranial base. Neurosurgery. 2011;69(2 Suppl Operative):ons195-206; discussion – 7.
18. Dare AO, Landi MK, Lopes DK, Grand W. Eyebrow incision for combined orbital osteotomy and supraorbital minicraniotomy: application to aneurysms of the anterior circulation. Technical note. J Neurosurg. 2001;95(4):714–8.
19. van Lindert E, Perneczky A, Fries G, Pierangeli E. The supraorbital keyhole approach to supratentorial aneurysms: concept and technique. Surg Neurol. 1998;49(5):481–9. discussion 9–90.
20. Andaluz N, Zuccarello M. Anterior Communicating Artery Aneurysm Surgery through the Orbitopterional Approach: Long-Term Follow-Up in a Series of 75 Consecutive Patients. Skull Base. 2008;18(4):265–74.
21. Andaluz N, Van Loveren HR, Keller JT, Zuccarello M. Anatomic and clinical study of the orbitopterional approach to anterior communicating artery aneurysms. Neurosurgery. 2003;52(5):1140-8; discussion 8–9.
22. Froelich S, Cebula H, Debry C, Boyer P. Anterior communicating artery aneurysm clipped via an endoscopic endonasal approach: technical note. Neurosurgery. 2011;68(2 Suppl Operative):310–6. discussion 5–6.

23. Dimmick SJ, Faulder KC. Normal variants of the cerebral circulation at multidetector CT angiography. Radiographics. 2009;29(4):1027–43.
24. Makowicz G, Poniatowska R, Lusawa M. Variants of cerebral arteries - anterior circulation. Pol J Radiol. 2013;78(3):42–7.
25. van Rooij SB, Bechan RS, Peluso JP, Sluzewski M, van Rooij WJ. Fenestrations of intracranial arteries. AJNR Am J Neuroradiol. 2015;36(6):1167–70.
26. de Gast AN, van Rooij WJ, Sluzewski M. Fenestrations of the anterior communicating artery: incidence on 3D angiography and relationship to aneurysms. AJNR Am J Neuroradiol. 2008;29(2):296–8.
27. Perlmutter D, Rhoton AL Jr. Microsurgical anatomy of the anterior cerebral-anterior communicating-recurrent artery complex. J Neurosurg. 1976;45(3):259–72.
28. Piotin M, Spelle L, Mounayer C, et al. Intracranial aneurysms: treatment with bare platinum coils—aneurysm packing, complex coils, and angiographic recurrence. Radiology. 2007;243:500–8.
29. Molyneux AJ, Kerr RS, Birks J, et al. Risk of recurrent subarachnoid haemorrhage, death, or dependence and standardised mortality ratios after clipping or coiling of an intracranial aneurysm in the International Subarachnoid Aneurysm Trial (ISAT): long-term follow-up. Lancet Neurol. 2009;8:427–33.
30. Johnston SC, Dowd CF, Higashida RT, et al. Predictors of rehemorrhage after treatment of ruptured intracranial aneurysms: the Cerebral Aneurysm Rerupture After Treatment (CARAT) study. Stroke. 2008;39:120–5.
31. Ferns SP, Majoie CBLM, Sluzewski M, van Rooij WJ. Late Adverse Events in Coiled Ruptured Aneurysms with Incomplete Occlusion at 6-Month Angiographic Follow-Up. American Journal of Neuroradiology. 2010;31(3):464.
32. Park YK, Bae HJ, Cho DY, Choi JH, Kim BS, Shin YS. Risk factors for recurrence and retreatment after endovascular treatment of intracranial saccular aneurysm larger than 8 mm. Acta Neurochir (Wien). 2019;161(5):939–46.
33. Corns R, Zebian B, Tait MJ, et al. Prevalence of recurrence and retreatment of ruptured intracranial aneurysms treated with endovascular coil occlusion. Br J Neurosurg. 2013;27(1):30–3.
34. Nakase H, Kamada Y, Aoki H, Goda K, Morimoto T, Sakaki T. Clinical study on recurrent intracranial aneurysms. Cerebrovasc Dis. 2000;10(4):255–60.
35. Jabbarli R, Pierscianek D, Wrede K, et al. Aneurysm remnant after clipping: the risks and consequences. J Neurosurg. 2016;125(5):1249–55.
36. Tateshima S, Murayama Y, Villablanca JP, et al. Intraaneurysmal flow dynamics study featuring an acrylic aneurysm model manufactured using a computerized tomography angiogram as a mold. J Neurosurg. 2001;95(6):1020–7.
37. Juvela S, Hillbom M, Numminen H, Koskinen P. Cigarette smoking and alcohol consumption as risk factors for aneurysmal subarachnoid hemorrhage. Stroke. 1993;24(5):639–46.

38. Petitti DB, Wingerd J. Use of oral contraceptives, cigarette smoking, and risk of subarachnoid haemorrhage. Lancet. 1978;2(8083):234–5.
39. Juvela S, Poussa K, Porras M, Juvela S, Poussa K, Porras M. Factors affecting formation and growth of intracranial aneurysms: a long-term follow-up study. Stroke. 2001;32:485–91.
40. Schievink WI, Katzmann JA, Piepgras DG, et al. Alpha-1-antitrypsin phenotypes among patients with intracranial aneurysms. J Neurosurg. 1996;84:781–4.
41. Brinjikji W, Lingineni RK, Gu CN, et al. Smoking is not associated with recurrence and retreatment of intracranial aneurysms after endovascular coiling. J Neurosurg. 2015;122(1):95–100.
42. John F, Jordan S, Darryl L, et al. Influence of smoking on aneurysm recurrence after endovascular treatment of cerebrovascular aneurysms. Journal of Neurosurgery JNS. 2018;128(4):992–8.

Figures

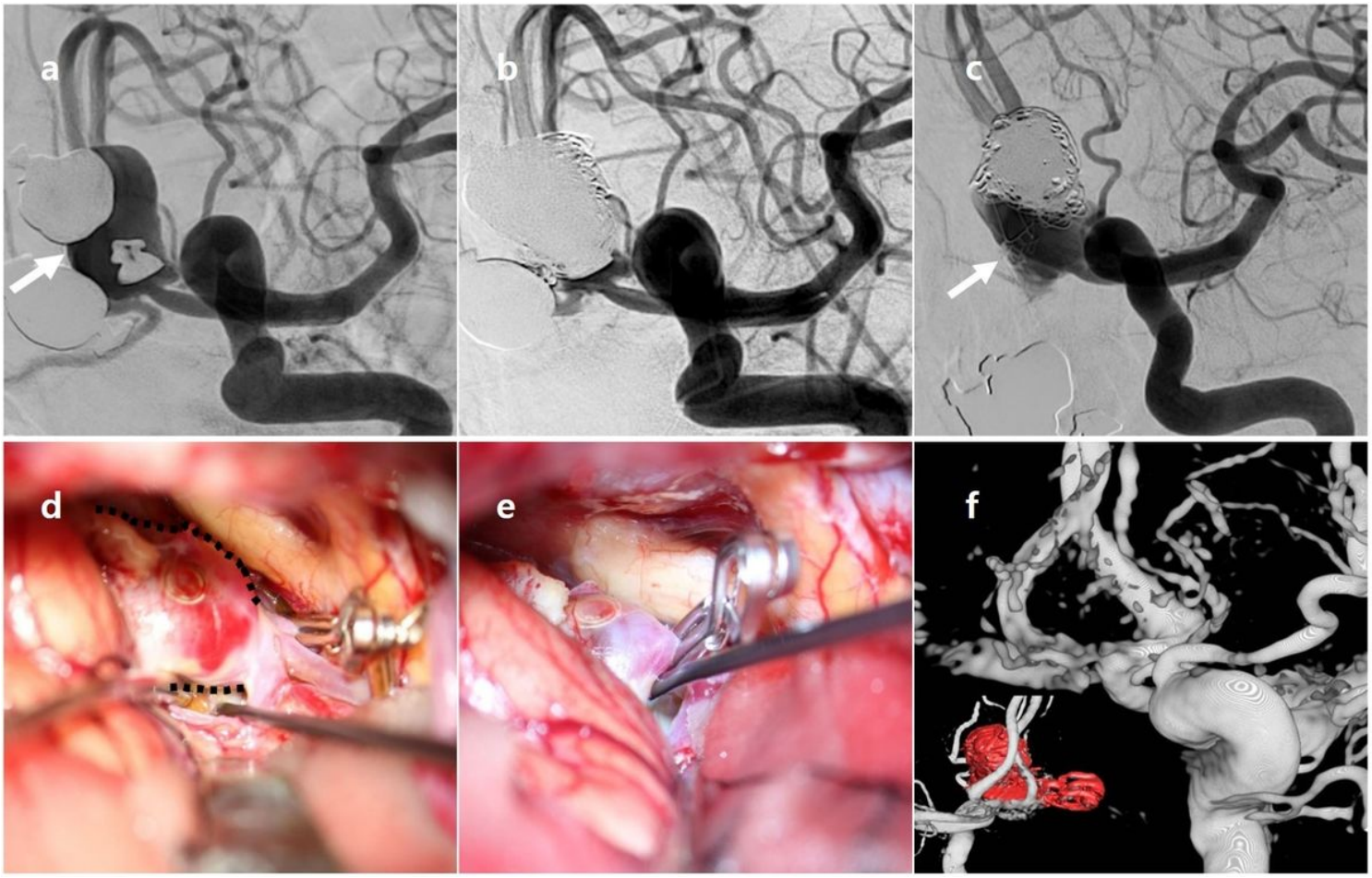

Figure 1

A 55-year-old patient with recurrent AcomA treated by clipping (Case 1, ruptured case) Initial angiogram (A) showed AcomA (arrow); maximal height 16.6 mm, neck size 6.6 mm. Immediate post-embolization image (B) showed neck remnant occlusion of aneurysm without distal sac flow. After 1 year, cerebral angiography (C) revealed major recanalization of aneurysm. (arrow) Intraoperative image showed

recurrent aneurysm sac (dotted line), and temporary clip was done for exploration of aneurysm sac (D). Permanent clip was done, and there was no remnant sac (E). On post-operative cerebral angiogram (F), 3D reconstructive image demonstrated no remnant sac. AcomA= anterior communicating artery aneurysm

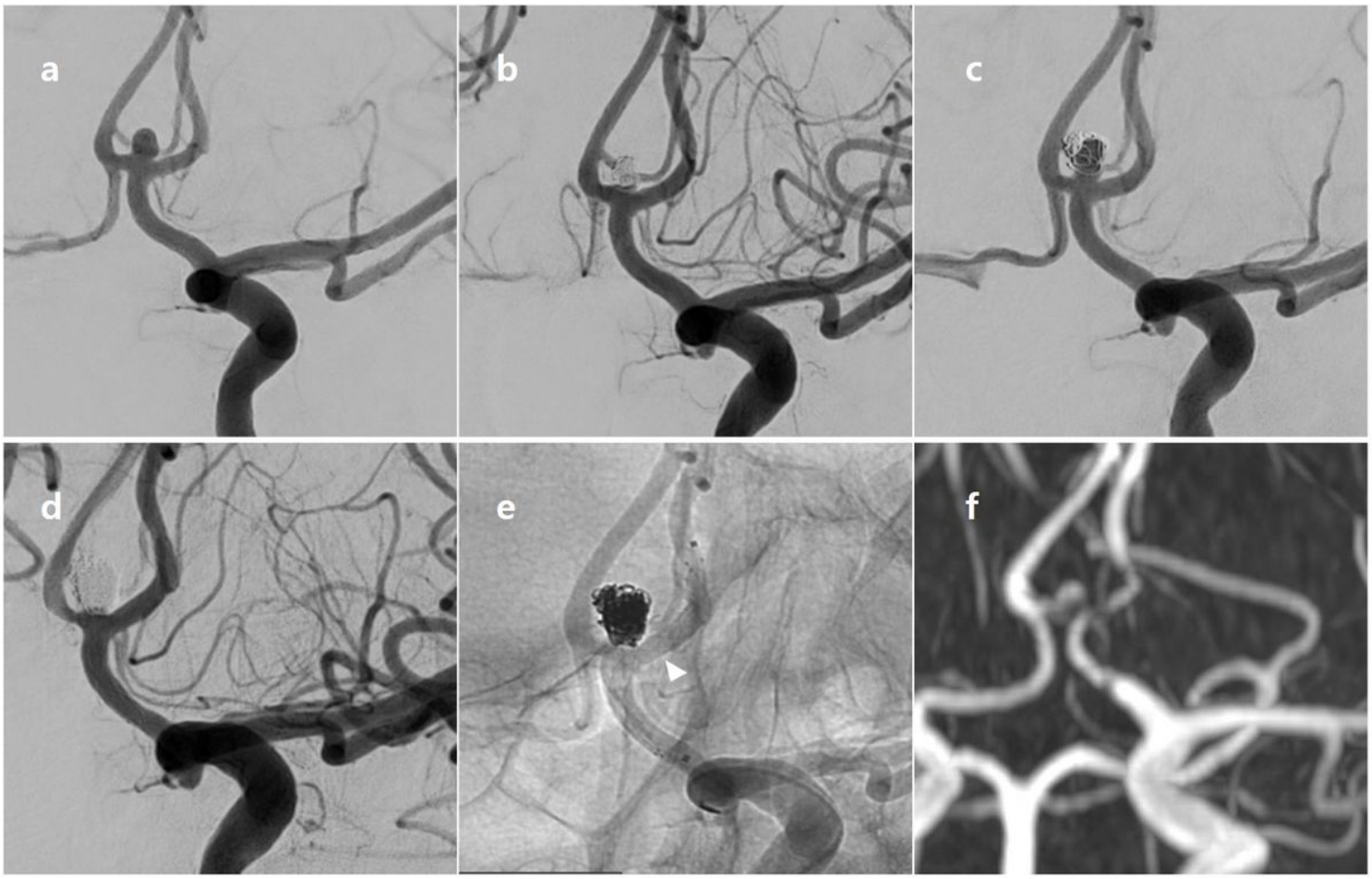

Figure 2

A 57-year-old patient with recurrent AcomA treated by stent-assisted technique (Case 2, ruptured case) Initial angiogram showed AcomA; maximal height 4.5 mm, neck size 3.1 mm (A). Immediate post-embolization image (B) showed near-complete occlusion without remnant status. After 1 year, cerebral angiography (C) revealed major recanalization of aneurysm. One catheter was introduced into ipsilateral A2 for stent-assisted technique, and additional coils were done with another microcatheter, but neck remnant was still observed (D). LVIS® Jr. stent (white arrow head) was inserted into ipsilateral A2-A1 (E). After 1 year, MRA (F) revealed small neck compaction of aneurysm. AcomA = anterior communicating artery aneurysm; MRA = magnetic resonance angiography