

Functional assessment of Zinc oxide nanoparticle and Moringa oleifera supplementation on the male reproductive system of a diabetic rat model

Arslan Shaukat

Government College University, Faisalabad

Umair Rasool

University of Agriculture

Farhan Saeed

Government College University, Faisalabad

Yasir Abbas Shah

Government College University, Faisalabad

Muhammad Afzaal (✉ muhammadafzaal@gcuf.edu.pk)

Government College University, Faisalabad

Research Article

Keywords: Nanoparticles, Zinc oxide, reproductive system, rat model, Moringa oliefera

Posted Date: October 10th, 2022

DOI: <https://doi.org/10.21203/rs.3.rs-2127236/v1>

License:   This work is licensed under a Creative Commons Attribution 4.0 International License.

[Read Full License](#)

Abstract

The probable synergistic effect of chemically synthesized zinc oxide nanoparticles and locally secured *Moringa oleifera* was assessed on diabetic rats' model along with a potential effect on the male reproductive system and rat male serological markers. The plant *Moringa oleifera* was procured from the University of Agriculture Faisalabad (UAF) step solvothermal method was utilized to synthesize the zinc oxide nanoparticles. The zeta sizer, UV-vis, and spectroscopic analysis of ZnO nanoparticles were undertaken. A total of fifty healthy male albino Wistar rats weighing 250 ± 10 g were used in the experimental research study having been divided into six steps designated as negative control (NC), positive control (PC), standard control (Std. C), ZnO na nanoparticle group (ZnO), *Moringa oleifera*. Group (MO) and a group of combinations thereof (ZnONP + MO). The mean body weight was observed to be significantly normalized in the group ZnONP + MO i.e., 230 ± 6 grams in contrast to PC i.e., $162\text{grams} \pm 4$; $P \leq 0.05$. The ZnONP + MO combination had a normoglycemic effect i.e., 154.4 ± 4.5 mg/dl as in opposition to the positive control, i.e., 315.7 ± 3 mg/dl. The serum level of rat testosterone in the ZnONP + MO group was observed at $0.958 \pm .08$ ng/ml in opposition to post-itive control, which revealed it at $0.442 \pm .02$ ng/ml). The follicle-stimulating hormone level in the ZnONP + MO group was recorded at $10.04 \pm .04$ mIU/ml significantly varied from the PC, whose level was noted at $5.08 \pm .09$ mIU/ml. The level of LH in the ZnONP + MO group was observed at $6.89 \pm .08$ mIU/ml, significantly different from PC at $3.78 \pm .08$ mIU/ml. Histopathological changes in the rat testes treated with alloxan alone revealed the distortion in the epithelium of seminiferous tubules (H&E stain). However, the histopathology of testes isolated from rats treated with the zinc oxide nanoparticle and *Moringa oleifera* combination showed almost normal spermatogenic activity, the lumen of seminiferous tubules contained sperms, normal spermatids, outer epithelium layer of seminiferous tubules was intact.

Introduction

Diabetes mellitus is a metabolic disorder associated with insufficient insulin secretion, insensitivity of the endogenous insulin to its receptors, and progressive failure of pancreatic β -cells resulting in hyperglycemia (Rolo and Palmeira, 2006). It is a syndrome resulting from the interactions of environmental and hereditary factors that affect metabolism involving proteins, carbohydrates, and fats in addition to the risk of damaging the pancreas, liver, kidney, and testes (Ghosh and Surawanshi, 2001) (Cheng et al., 2013). There is a crucial link between diabetes and compromised reproductive functioning in males. Diabetes mellitus elicits a decrease in testosterone level along with a reduction in the functionality and concomitant weight of testes, vas deferens, epididymis, prostate gland, and seminal vesicle. Moreover, testicular histology of chronic diabetic subjects reveals a decrease in testicular volume and weight along with lysis of seminiferous tubules, disorientation of spermatids, and reduction in Leydig cells (Scarano et al., 2005). Diabetes mellitus is treated and managed by insulin and oral hypoglycemic drugs (Francis and Sudha, 2016). However, effective therapy of diabetes mellitus is still not available in modern medicine and oral synthetic hypoglycemic drugs are not completely successful in managing diabetes (Sunil, 2014).

Zinc plays a crucial role in different metabolic pathways, including glucose metabolism (Haase et al, 2008). Zinc is also known to augment the functioning of insulin and plays a vital role in insulin biosynthesis, storage, and secretion (Sun et al, 2009). Bionanotechnology is the field of material science that arises at the intersection of biology and nanotechnology. Nanoparticles are the main products of this field. Nanoparticles are defined as ultra-small entities measuring 1 to 100 nm. They are being employed in fields as diverse as therapeutics, diagnostics, drug delivery, medical imaging, tumor suppression, etc. Within the context of DM, zinc oxide nanoparticles have been investigated to have promising potential and merit further investigations (Rohela et al., 2019) Zinc oxide nanoparticles (ZnONPs) are agents that have recently been utilized to deliver zinc and have implications in many disease therapies including diabetes mellitus (Tang, K.S., 2019). ZnONPs have been shown to effectively mitigate diabetes-induced pancreatic structural, ultrastructural, and functional injuries (Umrani and Paknikar. 2014). Recent investigations have revealed that Zn and ZnONPs supplementation facilitates the normalization of blood glucose and serum insulin levels. It also restores the sensitivity of the insulin receptor to insulin (El-Gharbawy et al, 2016; El-Gharbawy et al, 2016; Umrani and Paknikar et al., 2014).

Recent work has elucidated that ZnONPs supplementation in nicotine-exposed rats minimizes the harmful effects caused by such exposure; by decreasing oxidative stress and increasing the expression of steroidogenic enzymes; which in turn improves male fertility (Mohamed and Abdelrahman. 2019). Thus, the development of a zinc-based agent would be promising in the treatment of diabetes and its associated complications as zinc supplements have shown ameliorating effects in various studies (Tang, K.S. 2019; Ukperoro et al, 2010). In this regard, ZnONPs merit further investigation within the context of their antidiabetic potential and their effect on the male reproductive system as this aspect has not been fully explored previously. Herbs that contain various phytoconstituents such as flavonoids, terpenoids, saponins, carotenoids, alkaloids, and glycosides, have been reported to possess antidiabetic properties. In developing countries, medicinal plants are used to treat diabetes mellitus to overcome the burden cost of conventional medicine (Arumugam et al, 2013). *Moringa oleifera* (MO), also known as the Drumstick tree, has been used to mitigate the effects of diabetes due to its anti-diabetic properties. Leaves, fruits, and stem bark of this plant have been reported to have antidiabetic activity (Kar et al, 2003; Semanya et al, 2012; Maiti et al, 2016; Umar et al, 2011; Geleta et al, 2016; Dièye et al, 2008). A recent study in alloxan-induced diabetic rats found that *Moringa oleifera* leaves had a hypoglycemic effect and prevented body weight loss (Villarruel-López et al, 2018). However, the curative properties of this medical plant in alloxan-induced diabetes mellitus associated with the testicular gonadal axis and reproductive functionality are poorly understood and yet to be studied in detail. In the present study, we undertake such an endeavor. Hence, we aim to investigate the effects of ZnONPs singly and in combination with MO on alloxan-induced diabetic rats and the male rat gonadal tissue.

Materials And Methods

Preparation of Moringa Oleifera Extract:

The plant *Moringa oleifera*, locally known as the Horse Reddish tree, was collected from fields of the University of Agriculture Faisalabad (UAF) in the month of January. Plants were identified by the Department of Botany, GCUF. Identification number for *Moringa oleifera* was 284-bot-22. Plant leaves were separated and washed gently with water, cut into pieces, and kept for drying under shade. The leaves were dried completely after 25 days and then subjected to crushing and grinding to obtain a coarse powder. It was subjected to maceration. After complete maceration, the powder was filtered by using the Whatman number 2 filter paper twice. The filtrate obtained was evaporated using a rotary evaporator under reduced pressure until all the solvent evaporated leaving behind thick plant residue. A concentrated paste was obtained by drying in Petri plates. The leaf extracts were stored in bottles below 10°C in the refrigerator separately.

Zinc Oxide Nanoparticles Preparation

Zinc oxide nanoparticles were prepared in the biochemistry laboratory, University of Agriculture Faisalabad (UAF). A one-step solvothermal method was utilized to synthesize the zinc oxide nanoparticles. Firstly, the dissolution of zinc acetate dihydrate (13.2 mmol) was undertaken in alcohols. A potassium hydroxide solution (28.4 mmol) was dropwise subjected to addition to the zinc acetate solution at 52 °C. Nanoparticles started to precipitate and the solution became turbid. It was stirred rigorously for two hours after which it was allowed to sit for 1 hour. Excess liquid was removed and the precipitate was twice washed with 50 ml methanol and collected by 20-minute centrifugation at 10³ RPM. It was allowed to dry at room temperature for 1 day. The obtained solid was crushed to obtain white powder. It was subsequently dispersed in PVA with an ultrasonicator. The nanoparticles were stable and equally dispersed (Singh et al., 2012; Zak et al., 2011). The nanoparticles were characterized via, Zetasizer, UV-vis spectroscopy, and scanning electron microscopy.

Experimental Animal Used

A total of fifty healthy male albino Wistar rats weighing 250 ± 10 g were used in the experimental research study. Rats were obtained from the experimental animal house, institute of pharmacy, physiology, and pharmacology, University of Agriculture Faisalabad (UAF). They were kept in well-aerated cages at 24 ± 2 °C in a 12 h light and dark cycle, with surrounding humidity (40–60%). For 6 weeks the animals were provided ad libitum standard diet and water. Cleaning and changing water and food were done for all animals twice a day. Ethical rules on care and utilization of animal models for human disease were taken from the institutional bioethics committee, University of Agriculture Faisalabad, Pakistan.

Induction Of Experimental Diabetes

Experimental diabetes mellitus was induced by a single intraperitoneal injection of alloxan monohydrate (Sigma chemical co., Poole, Dorset, UK) having a dose rate of 130 mg/kg. Before induction rats were kept

for 12 hours in a fasting condition. After 72 hours of injection, fasting blood glucose was measured with the help of the blood glucose monitoring system (On-Call EZ II). Blood glucose Test Strips (On Call Plus ACON Laboratories, Inc. USA) and the rats with blood glucose levels over 200 mg/dl were considered diabetic and grouped in the diabetic group.

Experimental Design

Animals were randomly divided into six groups (n = 8). Group 1 of animals was considered a negative control and received normal saline (1ml/kg body wt.) along with a routine diet for the duration of the six-week trial. Group 2, the positive control, received a single intraperitoneal dose of Alloxan monohydrate (130 mg/kg). Group three received a standard commercially available antidiabetic medication glimepiride at a dose rate of 0.1mg/kg of body weight. The remaining three treatment groups were treated with ZnONPs, MO, and a combination of the two.

Group	Group I.D	Administration Route	Treatment
Negative Control	NC	Oral gavage	Routine diet + normal saline (1.0 ml/kg body of body weight)
Diabetic untreated Positive control	PC	Oral gavage	Alloxan + Routine diet + normal saline (1.0 ml/kg of body weight)
Standard treatment group	Std. C	Oral gavage	Glimepiride 0.1mg/kg of body weight
The treatment group was given zinc oxide nanoparticles	ZnONP	Oral gavage	Zinc oxide nanoparticles dosage at 7.5mg/kg of body weight
The treatment group was given <i>Moringa oleifera</i>	MO	Oral gavage	<i>Moringa oleifera</i> dosage at 250mg/kg of body weight
The treatment group was given zinc oxide nanoparticles plus <i>Moringa oleifera</i>	ZnONP + MO	Oral gavage	zinc oxide nanoparticles dosage at (7.5mg/kg) of body weight plus <i>Moringa oleifera</i> dosage at 250mg/kg of body weight

The optimum, safe, and effective dosages of the ZnO nanoparticles and *Moringa oleifera* were assessed from the already published wealth of literature (Ryu et al., 2014; Srivastav et al., 2016; Abbasalipourkabir et al., 2015; Stohs et al., 2015). ZnONPs were dissolved in water by constant magnetic stirring for 25 minutes at 37 °C. The amount of ZnONPs and MO leaf extract for each adult rat was calculated based on their weight. The suspension was administered orally to each adult albino rat via oral gavage.

Determination Of Body Weight, Serum Glucose, Serum Insulin, And Serum Glucagon

The body weight was evaluated at regular intervals of seven days. The estimation of the blood glucose was done via the established strip method (*Accu-Check* by Roche^R). The routinely employed enzyme-linked im-immunosorbent assay (ELISA) was employed for the assessment of serum insulin and glucagon (Ray biotech; Cat. Number E-EL-R0425)

Determination Of Reproductive Hormones

For quantitative determination of follicle-stimulating hormone (FSH), standard ELISA was employed (Rat FSH ELISA Kit Catalog No: MBS2502190; My BioSource^R). Luteinizing hormone (LH), was assessed by Rat LH ELISA Kit; Catalog No.: MBS764675; My BioSource^R. Rat testosterone was evaluated via the rat testosterone ELISA kit; Catalog Number. SE120089; My BioSource^R.

Histopathological Examination Of Testes:

At the end of the trial, rat testes were isolated, and preserved in Bouin's solution for histopathological examination. Then tissues were embedded in paraffin, sectioned, and stained with hematoxylin and eosin (H&E). The composition of Bouin's solution is saturated picric acid (1500ml), formaldehyde (500ml), and glacial acetic acid (100ml).

Statistical Analysis

Statistical analysis was conducted by one-way analysis of variance (ANOVA) followed by Duncan's multiple range (DMR) test at 5% level significance ($P < 0.05$) (Duncan, 1995; Steel *et al.*, 1996). Statistical Package for the Social Sciences (SPSS) version 16.0 and graph pad prism software version 8.00 were used for statistical analysis.

Results

Nanoparticle Characterization: Zetasizer Analysis, Uv-vis Analysis, And Scanning Electron Microscopy Analysis

The spectroscopic analysis (V-730 UV-Visible Spectrophotometer, Jasco^R) of ZnO nanoparticles was undertaken and it showed a distinct peak at 370 nm and it was found to agree with Zak *et al.*, 2011 and Patil & Taranath, T. C., 2016 (Fig. 1.A). The nanoparticle size was corroborated by evaluating the nanoparticles with a zeta sizer (Malvern Zetasizer; Nano-ZS90). The size of the ZnO nanoparticles was noted to be in the range of 25–35 nm as shown in Fig. 1(B). Scanning electron micrography (JSM-IT200 InTouch Scope™; Jeol R) revealed the formation of spherical and rhomboidal nanoparticles within the specified range of 25-35nm (Fig. 1. C).

Assessment of zinc oxide nanoparticle and *Moringa oliefera* and a combination thereof on the concentration of serum glucose, serum insulin, and glucagon and mean body weight.

The mean body weight was significantly normalized in the group ZnONP + MO i.e., 230 ± 6 grams as compared with the positive control i.e., $162 \text{ grams} \pm 4$; $P \leq 0.05$. This effect was markedly better than the MO treatment alone revealing a mean body weight of 188 ± 3 grams; $P \leq 0.05$ (Fig. 2). The ZnONP + MO combination exerted a normoglycemic effect in the treatment group i.e., 154.4 ± 4.5 mg/dl in contrast with the positive control, i.e., 315.7 ± 3 mg/dl. This effect was followed by the effect of the *Moringa oliefera* treatment group, i.e., 212.6 ± 7 grams. $P \leq 0.05$ (Fig. 2A). The negative control revealed 16.4 UI/ml of insulin concentration $P \leq 0.05$ (Fig. 2B). ZnONP + MO combination exerted a normalizing effect on insulin secretion i.e., 13.9 uL/ml as in contrast with the positive control, i.e., 6.2 uL/ml $P \leq 0.05$ (Fig. 2B). The serum glucagon concentration revealed 1997 ± 41.5 pg/ml in contrast with the PC i.e., 3650 ± 45 pg/ml $P \leq 0.05$ (Fig. 2B).

Assessment of zinc oxide nanoparticle and *Moringa oliefera* and a combination thereof on the concentration of serum testosterone, luteinizing hormone, and follicle-stimulating hormone

The serum concentration of rat testosterone in the ZnONP + MO group was noted at $0.958 \pm .08$ ng/ml as contrasted with the positive control, which revealed it at $0.442 \pm .02$ ng/ml (Fig. 3c; $P \leq 0.05$). The MO-treated group had a testosterone level of $0.776 \pm .04$ ng/ml as contrasted with negative control at 0.96 ± 0.04 ng/ml (Fig. 3c; $P \leq 0.05$). The follicle-stimulating hormone level in the ZnONP + MO group was observed at $10.04 \pm .04$ mIU/ml, which was statistically significantly different from the PC, whose level was noted at $5.08 \pm .09$ mIU/ml (Fig. 3B; $P \leq 0.05$). Its level in negative control was recorded at $10.77 \pm .04$ mIU/ml. (Fig. 3B; $P \leq 0.05$). The level of LH in the ZnONP + MO group was observed at $6.89 \pm .08$ mIU/ml which was statistically significantly different than PC which revealed it at $3.78 \pm .08$ mIU/ml (Fig. 3A; $P \leq 0.05$).

Effect of glimepiride, zinc oxide nanoparticle, and *Moringa oliefera* on histopathological changes induced by alloxan in testes of rats

Histopathological changes in the testes of rats treated with alloxan alone showed the distortion in the epithelium of seminiferous tubules (Fig. 4A; 40X; H&E stain). In the positive control, the lumen of tubules was empty, which indicates no spermatogenic activity (Fig. 4B; 40X; H&E stain). Immature spermatids were seen and tubules were reshaped, which ultimately reduces the testes' weight in the standard control (Fig. 4C; 40X; H&E stain). Destruction of the Leydig cells was noted which results in decreased testosterone production. However, the histopathology of testes isolated from rats treated with the zinc oxide nanoparticle and *Moringa oliefera* combination showed almost normal spermatogenic activity, the lumen of seminiferous tubules contained sperms, normal spermatids, outer epithelium layer of seminiferous tubules was intact. (Fig. 4F; 40X; H&E stain).

Discussion

Diabetes, now a day has become one of the leading metabolic disorders in the world. It is on the rise, and its prevalence is increasing with each passing day, especially in the middle-income countries of the world. The available therapies have quite a few adverse effects. In the present study, diabetes was induced in Wistar albino rats by alloxan monohydrate injected intraperitoneally at a dose of 130mg/kg of body weight. Alloxan is a glucose analog having a toxic effect on pancreatic β -cells; it readily destroyed them when administered to rodents. It was quickly and selectively taken up by β -cells followed by the production of reactive oxygen species ROS, superoxide radicals, and hydrogen peroxide by the redox cycle (Szkudelski, 2001). Consequently, the antihyperglycemic and gonad protective effect of *Moringa oleifera* (MO) and Zinc oxide nanoparticles (ZnONPs) alone and in combination thereof was assessed. The one-step solvothermal method utilized in the present study was found to be a highly effective, cost-effective, and efficient method for nanoparticle synthesis. The nanoparticles synthesized were generally of uniform shape and within the size range of 25–35 nm. We report that one step solvothermal process for zinc oxide nanoparticle synthesis can be upscaled for the bulk amount of nanoparticle production as well. Our findings were in agreement with Zak et al., 2011 and Patil & Taranath, T. C., 2016. The current study was designed to investigate the antidiabetic activity of the plant *Moringa Oleifera* in Alloxan-induced diabetic rats. This plant was selected because it is taken as food and is also used as a medicinal plant for the treatment of the respiratory system, digestive system, ulcer, urinary system, and for inflammation. It has been reported to be used traditionally as an antidiabetic agent. The treated diabetic rats with a high dose of *Moringa oleifera* extract recorded a significant decrease in blood glucose level and a significant increase in insulin and this was in agreement with a previous study (Asare et al., 2012). With regards to the antidiabetic effects of MO, it is plausible that its active constituents are responsible for it. These include the antidiabetic constituents (glucoside, quercetin, chlorogenic acid, and moringinine. Quercetin). The therapeutic property of this plant may be due to its regenerative potential affecting pancreatic β -cell, increasing insulin secretion and its uptake in skeletal muscles, and decreasing insulin resistance. However, further studies are needed to evaluate the precise mechanism of action for this beneficial herbal plant (Mahmood, 2006).

Oral administration of zinc oxide nanoparticles resulted in significant antidiabetic effects – that is, improved glucose tolerance, higher serum insulin, and reduced blood glucose. Nanoparticles were systemically absorbed resulting in elevated zinc levels. Nanoparticles were safe up to a 7.5 mg/kg body weight and previous studies have shown that they are safe up to 300 mg/kg dose in rats (Umrani and Paknikar, 2014). In the present study, the ZnONP + MO combination exerted a normoglycemic effect in the treatment group F, i.e., 154.4 ± 4.5 mg/dl as in contrast with the positive control, i.e., 315.7 ± 3 mg/dl. This effect was followed by the effect of *Moringa oleifera* treatment group, i.e., 212.6 ± 7 mg/dl. These findings are similar to those of Barman et al., 2016 and pompano et al., 2019. They have reported that zinc supplementation is beneficial for controlling glucose levels and normalizing insulin secretion. We report that the ZnO nanoparticles are a viable alternative to the bulk form of the zinc supplemental form. ZnONP + MO combination exerted a normalizing effect on insulin secretion i.e., 13.9 UI/ml as in contrast with the positive control, i.e., 6.2 uI/ml.

The main causal rationale behind these observed effects probably is because Zinc has been shown to have an antihyperglycemic effect and it lowers blood glucose by increasing the uptake of glucose from the blood into the cells. Our observation agrees with earlier studies (Almalki et al., 2016; Khaled Hamden et al., 2009). Previously, in a recent and landmark study, Guo and colleagues established that the supplementation by Zinc bulk form ameliorates the toxicity caused by phthalates to the reproductive system of the rats and normalizes the secretory activity of the reproductive system, and serum concentrations of LH, FSH, and testosterone. Our study also augments this study and we show, for the first time, that ZnONP along with *moringa oleifera* has indeed a protective effect on the male reproductive system of diabetic rats. However, the exact causative mechanism as to how this effect is manifested needs to be dissected at a molecular and mechanistic level. It needs to be seen whether this effect is limited locally to the parenchymatous tissue of testes or whether it is a generalized and systemic effect that encompasses the entirety of biochemical processes inside all cell types (Gao et al., 2020). Our work reveals that the ZnONP + MO had a protective effect on the overall parenchymatous structure of the male reproductive tract including the seminiferous tubule shape, spermatogenesis activity, presence or absence of Leydig cell, etc. Within this context, Gao et al., 2020 have already shown that the bulk form of Zinc had a protective effect on the rat male reproductive system.

The absence or abnormality of PIWI proteins may result in disorders of spermatogenesis or folliculogenesis (Gao et al., 2017; Gao et al., 2018). PIWI proteins are therefore essential in maintaining functions related to the rat reproductive system. PIWI proteins are essential for gonadal and embryonic development and their altered or reduced expression is correlated with abnormalities related to the rat reproductive system. It has been argued that the PIWI proteins are essential for the normal functioning and development of the rat reproductive system and alterations in its expression level are strongly correlated with the damage and derangement of testicular structure and function in rats. Furthermore, zinc supplementation has been shown to normalize and protect the expression of the P1WI proteins as shown by Gao and colleagues, 2020. The present study supports their finding and we report that the combination of ZnONP + MO can plausibly be a suitable alternative to bulk supplementation by zinc. However, further work is still required to elucidate whether the protective effect of ZnONP + MO is localized or global within the context of the entire biochemical machinery of the organism.

Conclusion

Diabetes adversely affects the rat's testes. There is increased blood glucose level, decreased body weight, decreased testicular weight, poor oral glucose tolerance, and unusual hematological parameters. Histopathology showed the disrupted epithelium of seminiferous tubules, the empty lumen of the tubules indicated no spermatogenic activity and the destruction of Leydig cells. Diabetes-induced (Morphological and histopathological) changes are recovered with Zinc oxide nanoparticles and *Moringa oleifera* having a synergistic antidiabetic effect and protective effect on the rat reproductive system and LH, FSH and testosterone levels. Histopathology of treated groups showed the intact epithelium and sperms in the lumen of seminiferous tubules.

Declarations

Funding

The authors declare that no funds, grants, or other support were received.

Competing Interests

The authors have no relevant financial or non-financial interests to disclose.

Conflict Of Interest

The authors declare that they have no conflict of interest.

Informed Consent

For this type of study, formal consent is not required.

Data Availability

Even though adequate data has been given in the form of tables and figures, however, all authors declare that if more data is required then the data will be provided on a request basis.

Acknowledgment

The authors are thankful to Government College University Faisalabad and University of Agriculture Faisalabad for providing technical support and laboratory facilities during research work.

References

1. Abbasalipourkabir, R., Moradi, H., Zarei, S., Asadi, S., Salehzadeh, A., Ghafourikhosroshahi, A., Mortazavi, M. and Ziamajidi, N., 2015. Toxicity of zinc oxide nanoparticles on adult male Wistar rats. *Food and chemical toxicology*, 84, pp.154-160.
2. Almalki, W. H., Arafa, E. S. A., Abdallah, A. Y., Mahfoz, A. M., Osman, A. O., Abd El-Latif, H. A., & Shahid, I. (2016). Zinc chloride protects against streptozotocin-induced diabetic nephropathy in rats. *Pharmacology & Pharmacy*, 7(08), 331.
3. Arumugam, G.; Manjula, P.; Paari, N. A review: Antidiabetic medicinal plants used for diabetes mellitus. *J. Acute Dis.* 2013, 2, 196–200.
4. Barman S, Srinivasan K. Zinc supplementation alleviates hyperglycemia and associated metabolic abnormalities in streptozotocin-induced diabetic rats. *Can J Physiol Pharmacol.* 2016 Dec;94(12):1356-1365. DOI: 10.1139/cjpp-2016-0084. Epub 2016 Aug 7. PMID: 27782759.
5. Cheng D, Liang B and Li Y, 2013. Antihyperglycemic effect of Ginkgo biloba extracts in streptozotocin-induced diabetes in rats. *Biomed Res Int* 3:1-7.

6. Dièye, A.M.; Sarr, A.; Diop, S.N.; Ndiaye, M.; Sy, G.Y.; Diarra, M.; Rajraji-Gaffary, I.; Ndiaye-Sy, A.; Faye, B. Medicinal plants and the treatment of diabetes in Senegal: Survey with patients. *Fundam. Clin. Pharmacol.* 2008, 22, 211–216.
7. Duncan DB, 1955. Multirange and multiple F-test. *Biometrics* 11: 1-42.
8. El-Gharbawy, R.M.; Emara, A.M.; Abu-Risha, S.E.S. Zinc oxide nanoparticles, and a standard antidiabetic drug restore the function and structure of beta cells in Type-2 diabetes. *Biomed. Pharmacother.* 2016, 84, 810–820.
9. Francis BT and Sudha S, 2016. Histopathological changes on streptozotocin-induced diabetic rats following administration of polyherbal extract: a study on pancreas and kidney. *World J Pharm Sci* 5: 1188-1200.
10. Gao H.T., Xu R., Cao W.X., et al., 2017. Effects of six priority controlled phthalate esters with long-term low-dose integrated 329 exposure on male reproductive toxicity in rats. *Food Chem. Toxicol.* 101, 94-104.
11. Gao H.T., Xu R., Cao W.X., et al., 2018. Combined effects of simultaneous exposure to six phthalates and emulsifier glycerol 327 monostearate on the male reproductive system in rats. *Toxicol. Appl. Pharmacol.* 341, 87-97. 328
12. Gao, H. T., Di, Q. N., Qian, L. L., Lu, L., Li, R. X., Cao, W. X., & Xu, Q. (2020). Zinc supplement ameliorates phthalates-induced reproductive toxicity in male rats. *Chemosphere*, 246, 125828.
13. Geleta, B.; Makonnen, E.; Debella, A.; Abebe, A.; Fekadu, N. In vitro vasodilatory activity and possible mechanisms of the crude extracts and fractions of *Moringa stenopetala* (baker f.) cufod. Leaves in isolated thoracic aorta of guinea pigs. *J. Exp. Pharm.* 2016, 8, 35–42.
14. Ghosh S and Surawanshi SA, 2001. Effect of *Vinca rosea* extracts in the treatment of alloxan diabetes in male albino rats. *Indian J Exp Biol* 8: 748–59.
15. Haase, H., Overbeck, S. and Rink, L. 2008. Zinc supplementation for the treatment or prevention of disease: current status and future perspectives. *Exp. Gerontol.* 43, 394–408.
16. Kar, A.; Choudhary, B.K.; Bandyopadhyay, N.G. Comparative evaluation of the hypoglycemic activity of some Indian medicinal plants in alloxan diabetic rats. *J. Ethnopharmacol.* 2003, 84, 105–108.
17. Khaled Hamden, Serge Carreau, Abdelfattah Elfeki. Inhibitory effects of Zinc on hyperglycemia and metabolic disorders in the liver of alloxan-induced diabetic rats. *Asian Biomedicine*, 2009, 3 (6), pp.745-750. HAL-02653773
18. Laura M Pompano, Erick Boy, Effects of Dose and Duration of Zinc Interventions on Risk Factors for Type 2 Diabetes and Cardiovascular Disease: A Systematic Review and Meta-Analysis, *Advances in Nutrition*, Volume 12, Issue 1, January 2021, Pages 141–160, <https://doi.org/10.1093/advances/nmaa087>
19. Mahmood S., 2006 Hypoglycemic evaluation of *berberis aristata* (Sumlu) roots in normal and diabetic rabbits. M. Phil thesis, Department of Physiology and Pharmacology, University of Agriculture Faisalabad, Pakistan.

20. Maiti, R.; Rodriguez, H.G.; Kumari, C.A.; Sarkar, N.C. Macro and micro-nutrient contents of 18 medicinal plants are used traditionally to alleviate diabetes in Nuevo Leon, northeast Mexico. *Pak. J. Bot.* 2016, 48, 271–276.
21. Mohamed, D.A.; Abdelrahman, S.A. The possible protective role of zinc oxide nanoparticles (ZnONPs) on the testicular and epididymal structure and sperm parameters in nicotine-treated adult rats (a histological and biochemical study). *Cell Tissue Res.* 2019, 375, 543–558.
22. Patil, B. N., & Taranath, T. C. (2016). *Limonia acidissima* L. leaf mediated synthesis of zinc oxide nanoparticles: A potent tool against *Mycobacterium tuberculosis*. *International journal of mycobacteriology*, 5(2), 197-204.
23. Rohela, G. K., Srinivasulu, Y., & Rathore, M. S. (2019). A review paper on recent trends in bio-nanotechnology: implications and potentials. *Nanoscience & Nanotechnology-Asia*, 9(1), 12-20.
24. Rolo AP and Palmeira CM, 2006. Diabetes and mitochondrial function: Role of hyperglycemia and oxidative stress. *Toxicol Appl Pharmacol* 212: 167-78.
25. Ryu, H. J., Seo, M. Y., Jung, S. K., Maeng, E. H., Lee, S. Y., Jang, D. H., ... & Son, S. W. (2014). Zinc oxide nanoparticles: a 90-day repeated-dose dermal toxicity study in rats. *International journal of nanomedicine*, 9(Suppl 2), 137.
26. Scarano WR, Messias AG, Oliva SU et al., 2005. Sexual behavior, sperm quantity, and quality after short-term streptozotocin-induced hyperglycemia in rats. *Int J Androl.* 29:482- 488.
27. Semenya, S.; Potgieter, M.; Erasmus, L. Ethnobotanical survey of medicinal plants used by Bapedi healers to treat diabetes mellitus in the Limpopo Province, South Africa. *J. Ethnopharmacol.* 2012, 141, 440–445.
28. Singh, D. K., Pandey, D. K., Yadav, R. R., & Singh, D. (2012). A study of nanosized zinc oxide and its nanofluid. *Pramana*, 78(5), 759-766.
29. Srivastav, A. K., Kumar, M., Ansari, N. G., Jain, A. K., Shankar, J., Arjaria, N., ... & Singh, D. (2016). A comprehensive toxicity study of zinc oxide nanoparticles versus their bulk in Wistar rats: toxicity study of zinc oxide nanoparticles. *Human & experimental toxicology*, 35(12), 1286-1304.
30. Steel RGD, eeeeeee JH, and Dicky DA, 1997. *Principles and Procedures of Statistics: A Biometrical Approach* (3rd Ed.). McGraw Hill Book Co. Inc., New York.
31. Stohs, S. J., & Hartman, M. J. (2015). Review of the safety and efficacy of *Moringa oleifera*. *Phytotherapy Research*, 29(6), 796-804.
32. Sun, Q., Van Dam, R.M., Willett, W.C. and Hu, F.B. (2009) Prospective study of zinc intake and risk of type 2 diabetes in women. *Diabetes Care.* 32, 629–634.
33. Sunil K, 2014. Preclinical evaluation of antidiabetic and hypolipidemic effects of *hibiscus tiliaceus*. *World J Pharma Res* 3: 891-900.
34. Szkudelski T. The mechanism of alloxan and streptozotocin action in B cells of the rat pancreas. *Physiol Res.* 2001;50(6):537-46. PMID: 11829314.

35. Tang, K.S. (2019) The current and future perspectives of zinc oxide nanoparticles in the treatment of diabetes mellitus. *Life Sci.* 239, 117011.
36. Ukperoro, J.U., Offiah, N., Idris, T. and Awogoke, D. (2010) Antioxidant effect of zinc, selenium and their combination on the liver and kidney of alloxan-induced diabetes in rats. *Mediterranean J. Nutr. Metab.* 3, 25–30.
37. Umar, A.N.; Mann, A.; Ajiboso, O.S.O. Ethnodietetics of moringa oleifera leaves amongst the ethnic groups in Bida, niger state, Nigeria and its hypoglycaemic effects in rats. *Am. Eurasian J. Sustain. Agric.* 2011, 5, 107–114.
38. Umrani, R.D. and Paknikar, K.M. (2014) Zinc oxide nanoparticles show antidiabetic activity in streptozotocin-induced Type 1 and 2 diabetic rats. *Nanomedicine* 9, 89–104.
39. Villarruel-López, A.; López-de la Mora, D.A.; Vázquez-Paulino, O.D.; Puebla-Mora, A.G.; Torres-Vitela, M.R.; Guerrero-Quiroz, L.A.; Nuño, K. Effect of Moringa oleifera consumption on diabetic rats. *BMC Complement. Altern. Med.* 2018, 18, 127.
40. Zak, A. K., Razali, R., Abd Majid, W. H., & Darroudi, M. (2011). Synthesis and characterization of the narrow size distribution of zinc oxide nanoparticles. *International journal of nanomedicine*, 6, 1399.

Figures


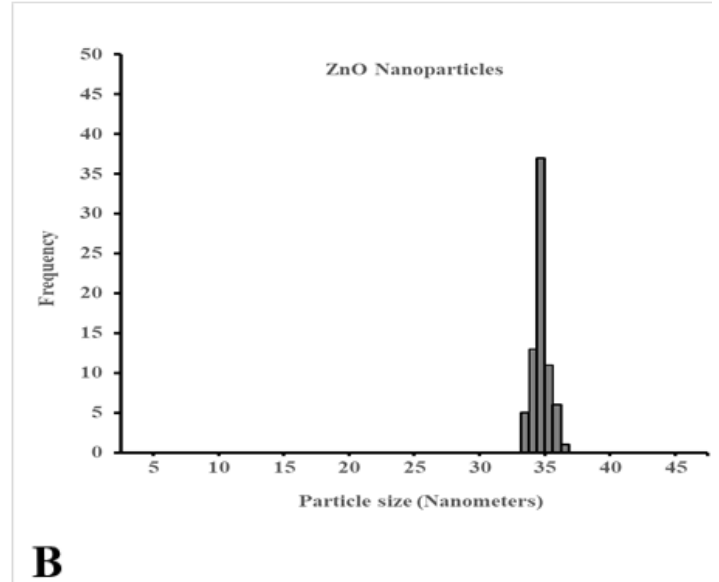
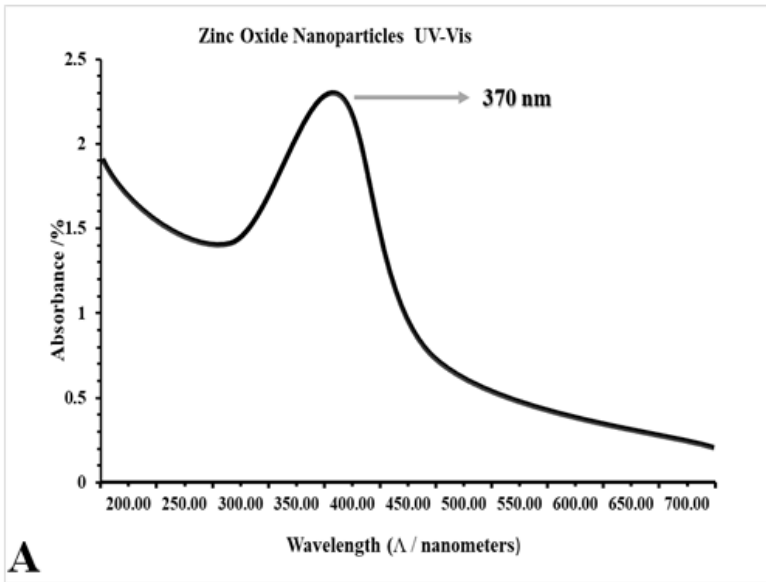


Figure 1

(A, B, and C): Figure 1A: ZnONP spectroscopy; 1B: Zetasizer analysis 1C: SEM analysis

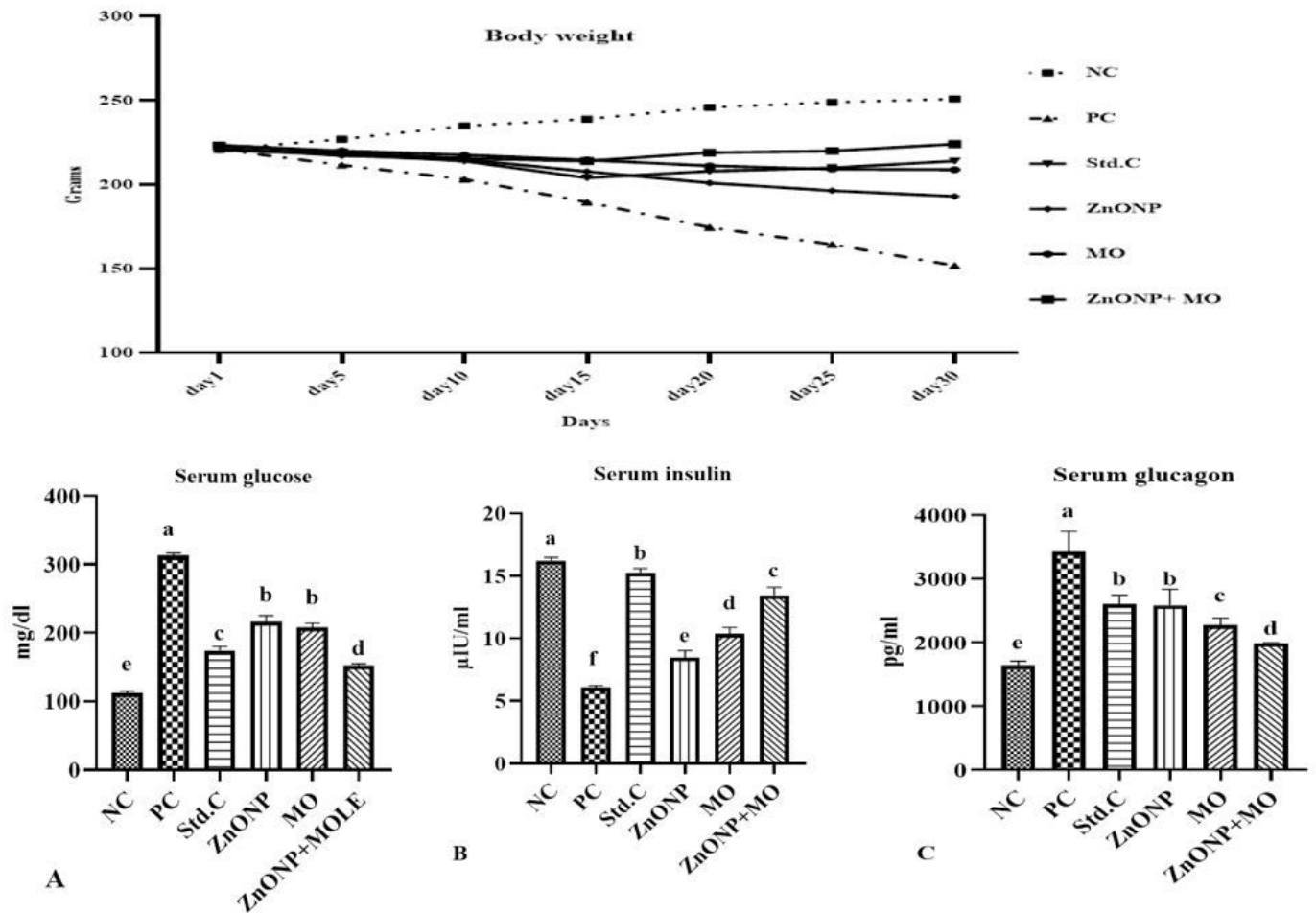


Figure 2

Assessment of zinc oxide nanoparticle and *Moringa oliefera* and a combination thereof on the concentration of serum glucose (2A), serum insulin (2B), and glucagon (2C) and mean body weight.

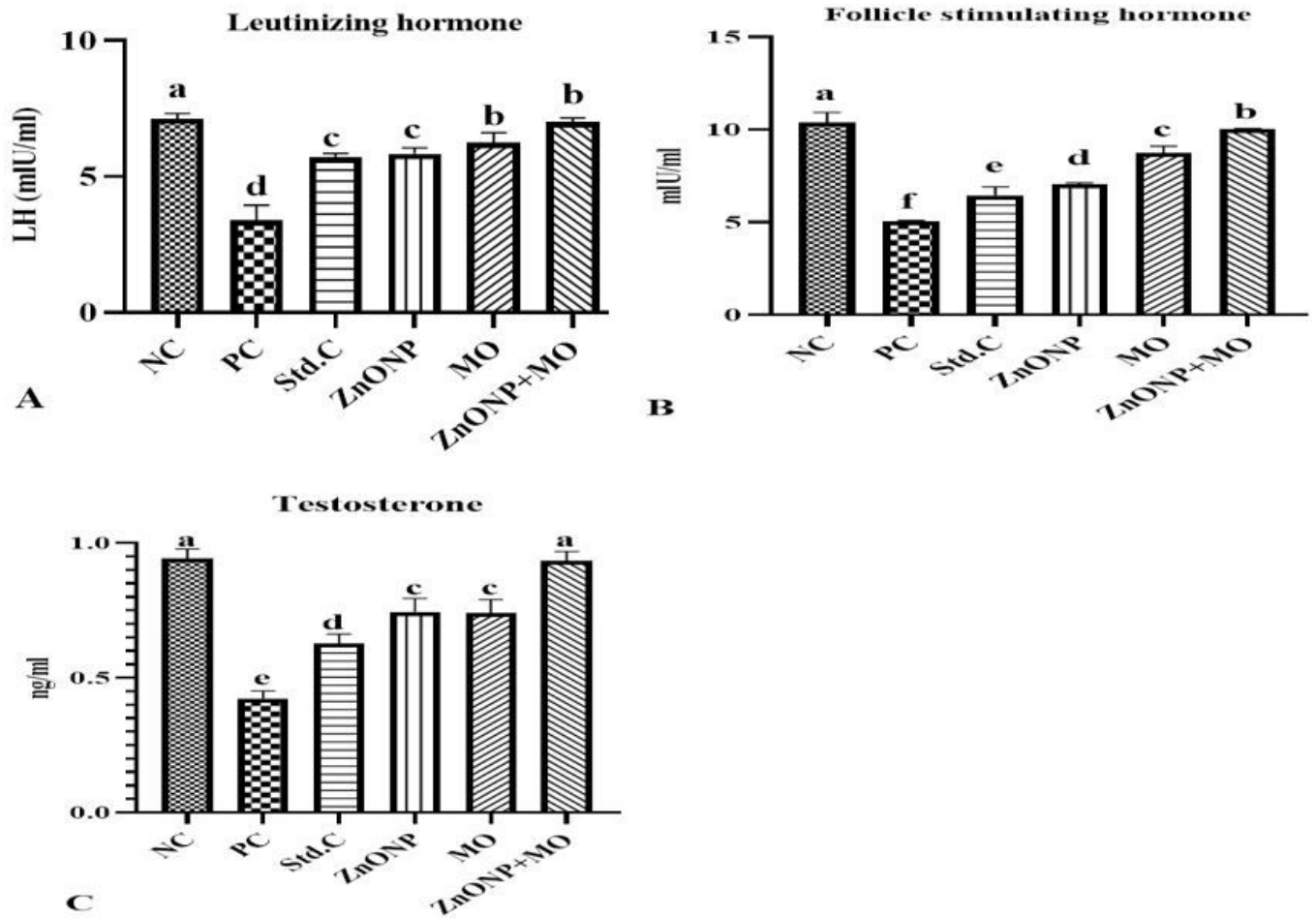


Figure 3

Assessment of zinc oxide nanoparticle & *Moringa oliefera* and a combination thereof on serum testosterone (3C), latinizing hormone (3B), and follicle-stimulating hormone (3A)

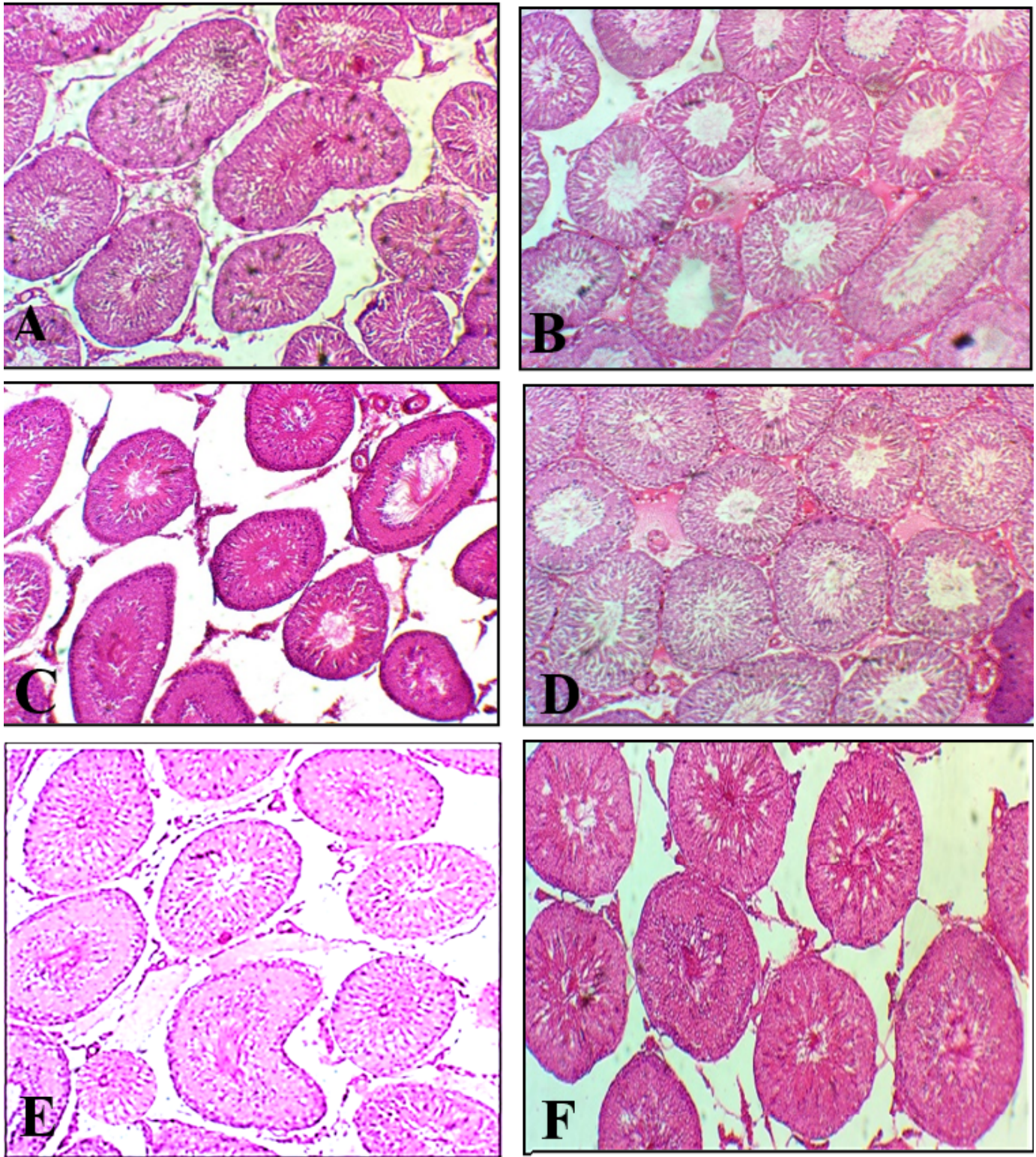


Figure 4

Assessment of zinc oxide nanoparticle & *Moringa oleifera* & combination thereof on testes histology (NC=4A., PC=4B., Std.C= 4C., ZnONP= 4D., MO= 4E., ZnONP +MO= 4F)