Chest CT imaging of pediatric COVID-19 infection: a case report

Huayan Xu
Key Laboratory of Birth Defects and Related Diseases of Women and Children of Ministry of Education, West China Second University Hospital, Sichuan University

Keke Hou
Public Health Clinical Center of Chengdu

Na Zhang
Public Health Clinical Center of Chengdu

Ming Yang
Public Health Clinical Center of Chengdu

Yingkun Guo (gykpanda@163.com)
Key Laboratory of Birth Defects and Related Diseases of Women and Children of Ministry of Education, West China Second University Hospital, Sichuan University

---

Case Report

Keywords: coronavirus disease 2019, pediatric patients, CT Images, case report

Posted Date: April 7th, 2020

DOI: https://doi.org/10.21203/rs.3.rs-21613/v1

Abstract

Background: Coronavirus Disease 2019 (COVID-19) outbreak in Wuhan, China spreading rapidly worldwide. Over 100 countries have reported surpassing 100,000 laboratory-confirmed cases of COVID-19, and in which 2.1% were under aged 19 years. However, little is known about the imaging features about pediatric COVID-19 patients. Herein, we report two cases about COVID-19 involving the clinical data as well as chest images.

Case presentation: Two pediatric patients admitted to hospital because of high fever or dry cough. Both children had been recent exposure to the COVID-19 confirmed patients of their family members. Real-time polymerase chain reaction(RT-PCR) test of these two patients' sputum were positive for SARS-CoV-2 nucleic acid, and diagnosed as COVID-19 infection. Laboratory tests indicate normal white cell count (5.02 x10^9/L) and neutrophils (40.8%) in one case, and slightly increased white cell count (11.86 x10^9/L) and normal neutrophils (16.1%)in the other one. CRP of both cases were within the normal range. Computed tomography (CT) was used to evaluate the novel coronavirus pneumonia (NCP) of these two pediatric patients. Small nodule was found in the upper right lobe of one case; and bilateral peripheral ground-glass opacities were observed in the other patient.

Conclusion: In summary, clinical symptoms and signs, laboratory tests and chest CT images of pediatric patients were untypical. Epidemic exposure history and RT-PCR results still play an important role in the precise diagnosis of COVID-19 children.

Background

Since the outbreak of Coronavirus Disease 2019 (COVID–19), the disease spread rapidly and affected 135 countries. As of 15, March, 2020, there has been 142539 confirmed cases globally according to situation reports of world health organization (WHO) [1], and 2.1% patients were under aged 19 years in china based on the research of Chinese Center for Disease Control and Prevention (CDC) [2]. WHO declared COIVD–19 pandemic form, with more and more reported cases and deaths. Many countries are taking essential actions to control the spreading of this infection diseases and a lot of researches about COVID–19 were polished. However, previous researches about COVID–19 were almost focused on the epidemiology, clinical symptoms and signs, laboratory tests and chest images of adult patients [3]. Little attention has been paid to the pediatric COVID–19 infection. Clinical data and image characteristics of children are still lacking, which should be made more effort on the investigations. Herein, we reported the clinical features as well as the chest computed tomography (CT) imaging characters of novel coronavirus pneumonia (NCP) in two pediatric COVID–19 patients to fill the blanks.

Case Presentation

A ten-year-old child presented to hospital at February 13,2020 for 10 day's high fever and dry cough. He has been traveled in Wuhan for 11 days (from January 14 to 25,2020) recently, and two of his family

members were already confirmed with COVID–19 infection. Laboratory tests showed that normal white blood cell count (5.02 x10^9/L; normal range: 3.50–9.50 x10^9/L), 40.8% neutrophils and 49.4% lymphocytes. The C reactive protein(CRP) was also within normal range (<0.8mg/L, normal range:0–5mg/L). Unenhanced CT imaging showed mild manifestation, which indicated only a small nodule is detected in the upper lobe of right lung(*Figure1A-B).*. Real-time polymerase chain reaction(RT-PCR) test of the patient's sputum was positive for SARS-CoV–2 nucleic acid, and finally diagnosed as COVID–19 infection.

The second case is a 3-month-old infant admitted to hospital at February 09, 2020 for coughing and polypnea one week. Before the onset of symptoms, one of his family member came from Wuhan, and living with them for ten days. Two of his family members were diagnosed as COVID–19. His body temperature was 36.2 °C on admission. CRP showed in normal range (<0.8mg/L, normal range:0–5mg/L). Laboratory test showed 16.1% neutrophils and 72.6% lymphocytes; white cell count (11.86 x10^9/L; normal range: 3.50–9.50 x10^9/L) was slightly increased. Unenhanced CT manifested that bilateral peripheral ground-glass opacities with patchy area of emphysema, epically in the lower lobes *(Figure2 A-B).* RT-PCR of SARS-CoV–2 nucleic acid was tested positive and confirmed as COVID–19.

Discussion And Conclusion

Pediatric COVID–19 infection is commonly family clustering with clearly epidemiologic characteristics [4]. Nevertheless, the clinical manifestations, chest images and laboratory tests of a few children are unspecific, which are similar with influenza or other infections frequently happened in children and been overlooked from the COVID–19 infection. Positive RT-PCR of SARS-CoV–2 nucleic acid and epidemiologic history seems still the most important diagnosis modalities for pediatric patients. Thus, children who have infected family member should be highly mentioned to ensure timely diagnosis. Since the children are as susceptible as adult suggested by previous study, home care must be more careful to avoid children being exposed to the virus [4,5]. Meanwhile, wearing mask and increased handwashing are necessary for children even infant; isolating from the suspected and confirmed family member are also suggested.

In summary, chest CT images as well as clinical features and laboratory tests of COVID–19 pediatric were nonspecific, which may should give more attention and care to these children who had family clustering. RT-PCR and epidemiological history should combine with chest images to diagnose the COVID–19 children.

List Of Abbreviation

COVID–19, Coronavirus Disease 2019; WHO, world health organization; CDC, Center for Disease Control and Prevention; NCP, novel coronavirus pneumonia; RT-PCR, Real-time polymerase chain reaction.

Declarations

Ethics approval and consent to participate: The institutional ethics board of our institutes approved this study (No. 2020.43).

Consent for publication: Written informed consent for their personal or clinical details along with any identifying images to be published in this study was obtained by the guardians of both patients.

Availability of data and materials: Data and material are available.

Competing interests: none

Funding: This work was supported by 2020 Novel coronavirus pneumonia prevention and control technology project of Chengdu (NO. 2020-YF05- 00007-SN); funder: Chengdu Science and Technology Bureau; Grant recipient: HYX.

Author's contributions: YKG and MY had full access to all of the data in the study and take responsibility for the integrity of the data and the accuracy of the data analysis. KKH and HYX contributed equally to the study. YKG and MY contributed equally as senior authors. The contribution of authors is as following: concept and design: HYX, YKG; Acquisition, analysis and interpretation of data: HYX; Drafting the manuscript: HYX, KKH and NZ; Edit and revise the manuscript: YKG and MY; Supervision: YKG.

Acknowledgements: We thank all our colleagues who helped us during the current study. We are also grateful to the many frontline medical staff for their dedication in the face of this outbreak, despite the potential threat to their own lives and the lives of their families.

References

[1] Coronavirus disease 2019 (COVID–19) Situation Report—54. https://www.who.int/docs/default-source/coronaviruse/situation-reports/20200314-sitrep–54-covid–19.pdf?sfvrsn = dcd46351_2.

[2] The Novel Coronavirus Pneumonia Emergency Response Epidemiology Team. The Epidemiological Characteristics of an Outbreak of 2019 Novel Coronavirus Diseases (COVID–19)—China, 2020[J]. China CDC Weekly, 2020, 2(8): 113–122.

[3] Michael Chung, Adam Bernheim, Xueyan Mei, Ning Zhang, Mingqian Huang,

Xianjun Zeng, Jiufa Cui, Wenjian Xu, Yang Yang, Zahi A. Fayad, Adam Jacobi, Kunwei Li, Shaolin Li, Hong Shan. CT Imaging Features of 2019 Novel Coronavirus (2019-nCoV). Radiology. http://pubs.rsna.org/doi/10.1148/radiol.2020200230.

[4].Min Wei, Jingping Yuan, Yu Liu, Tao Fu, Xue Yu, Zhijiang Zhang. Novel Coronavirus Infection in Hospitalized Infants Under 1 Year of Age in China.JAMA. Published online February 14, 2020. doi:10.1001/jama.2020.2131.

[5]. Interim Guidance for Preventing 2019 Novel Coronavirus (2019-nCoV) from Spreading to Others in Homes and Communities: https://www.cdc.gov/ coronavirus/2019-ncov/guidance-prevent-spread.htm

Figures

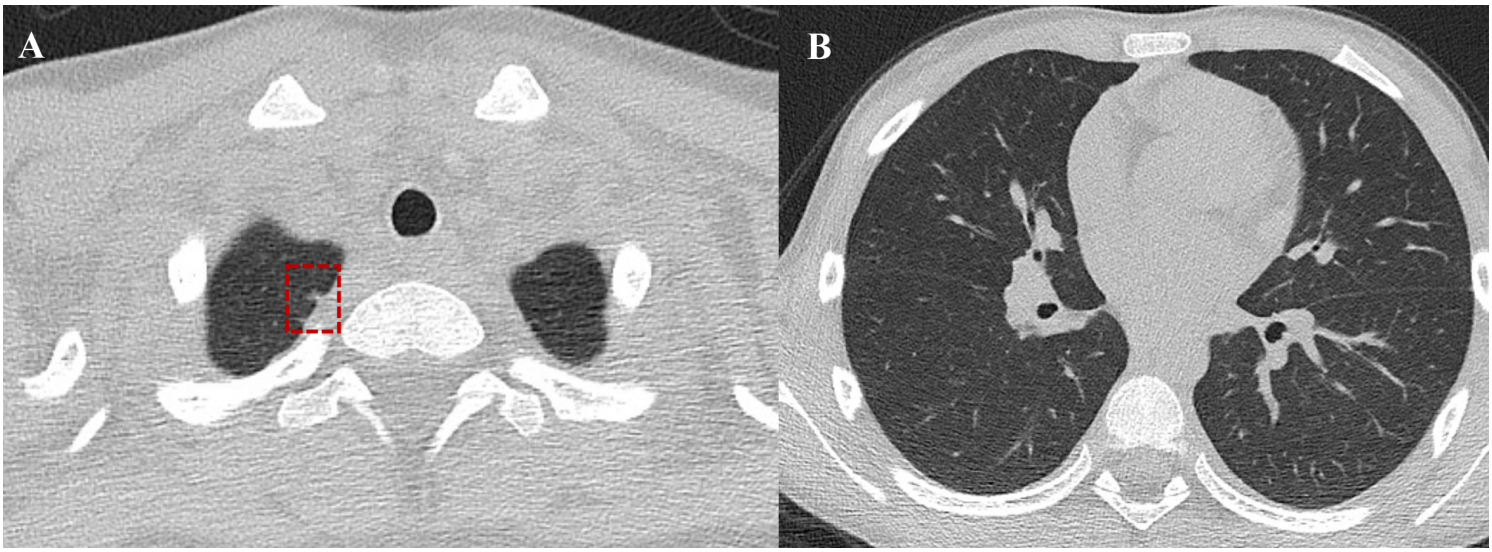

Figure 1

Unenhanced CT images of a 10-year-old pediatric patient confirmed as COVID-19. A small nodule was found in the upper lobe of right lung(A). No other finding was detected in both lung (B). CT, computed tomography; COVID-19, Coronavirus Disease 2019.

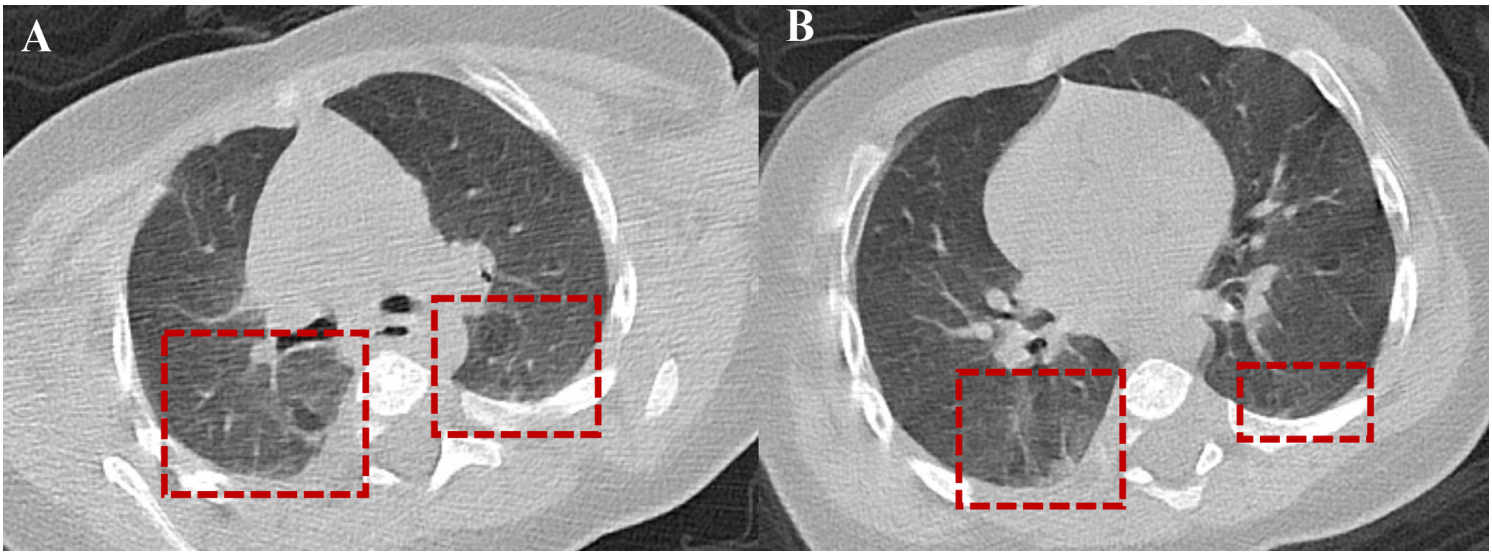

Figure 2

Unenhanced CT images of a 3-month-old infant with COVID-19 infection. Peripheral ground glass opacities were found in the upper (A) and lower lobes of both lung (B). The abbreviations are the same as the figure 1.