Laparoscopic orchiopexy versus traditional inguinal incision orchidopexy for palpable undescended testes in cryptorchidism

Shaodong Gu
Lianyungang No 1 People's Hospital https://orcid.org/0000-0002-8071-8105

Yingxun wang
Lianyungang No 1 People's Hospital

Hong Luo (luohong8498@outlook.com)
Department of Pediatric Surgery, The First People's Hospital of Lianyungang

Research article

Keywords: Laparoscopic, orchiopexy, Palpable, undescended testes, Cryptorchidism

Posted Date: August 5th, 2020

DOI: https://doi.org/10.21203/rs.3.rs-21664/v2

Version of Record: A version of this preprint was published on February 15th, 2021. See the published version at https://doi.org/10.1089/lap.2020.0832.

Abstract

Background Laparoscopic orchidopexy (LO) has become a standard procedure for the treatment of nonpalpable undescended testes. Nevertheless, the use of LO for palpable undescended testes still remains controversial. The aim of this study was to explore the impact of laparoscopic orchiopexy procedure on palpable undescended testes in children suffering from cryptorchidism.

Methods: A retrospective study was performed for LO and traditional inguinal incision orchidopexy (TIO) carried out to treat palpable undescended testes. In total, 291 children aged 9 months to 96 months with either left or right side palpable inguinal canalicular testes were included. 170 patients received LO and 121 patients received TIO. Age, operative time and clinical outcomes of the patients were reviewed. Independent t test and Fisher's exact test were performed by using the SPSS 25.0 software.

Results: In the younger groups, the mean operative time (younger than 1 year old, 30.50±5.88 vs. 39.86±6.11 min; 1-2 years old, 34.43±6.65 vs. 40.23±8.74) and postoperative normal activity time (younger than 1 year old, 1.20±0.40 vs. 2.12±0.48 days; 1-2 years old, 1.58±0.50 vs. 2.02±0.43 days) of LO were significantly shorter than those in the TIO group ($P < 0.05$). The operative time of LO was significantly longer than that in the TIO group in older groups (aged>3 years old). 47 of 49 cases (95.9%) of patients aged less than 1 year old were treated by LO successfully. Among the patients aged 1-2 years, 80 of 86 cases (93.0%) successfully completed LO. Totally, 43 cases were transferred to inguinal incisions.

Conclusion: LO is an appropriate choice for palpable undescended testes, especially in children younger than 2 years old. The percentage of successful LO decreased with the increasing age.

Background

Cryptorchidism or undescended testes (UDT) are a common genital malformation in boys. In similar studies performed in different countries, the prevalence of cryptorchidism varies from 2% to 8% [1]. The incidence of undescended testes in premature infants and/or infants with a birth weight of <2500 g varies from 1.1% to 45.3%, and the incidence of bilateral presentation among these patients was 50% to 75% [2]. Nearly 80 percent of undescended testes are palpable [3]. Traditional inguinal incision orchiopexy (TIO) is recommended after 6 months of age [4]. Laparoscopic orchidopexy (LO) is a standard procedure for the treatment of nonpalpable undescended testes [5]. However, LO for palpable undescended testes still remains controversial. The LO procedure has not been recommended by any organization yet. While many literatures have reported LO as a great and safe option for the treatment of palpable undescended testes, regardless of the age of the patients [6,7], this study compared LO with TIO in children with palpable undescended testes who were treated at the hospital of the authors in the past 5 years.

Methods

This study was approved by the Ethics Committee of The First People's Hospital of Lianyungang. Here, a retrospective study of LO and TIO was conducted on patients admitted from August 2014 to August 2019. In total, 291 children with either left or right side palpable inguinal canalicular testes were included (Table 1). LO was performed on 170 patients aged from 9 months to 48 months (mean 16.62 ± 8.43 months), including 74 patients at the left side and 96 patients at the right side. 121 patients aged from 9 months to 96 months (mean 18.37 ± 15.35 months) received TIO, including 50 patients at the left side and 71 patients at the right side. All patients had unilateral palpable undescended testes and the testicles could not be drawn into the scrotum in the physical examination. Age, operative time, the proportion of closure of internal inguinal ring (IIR), and clinical outcomes of the patients were reviewed. Follow-up visits were performed to assess the condition of postoperative testes.

The patients were placed in a supine position under general anesthesia. Then, the operating table was tilted to 15-20 degrees with the head of the patients below their feet. A 5-mm umbilical incision was made along the superior border of umbilicus. First, a 5-mm trocar was inserted into the umbilical incision. CO2 pneumoperitoneum was established routinely at a pressure of 8-10 mmHg. The lens (30 degrees) was placed into the abdominal cavity to explore the IIR. If the IIR was closed, the inguinal incisions were transferred. If the IIR was open, the other two 5-mm trocars were placed at the subcostal midclavicular line. Alternately, two graspers were used to pull the testes from the inguinal canal into the abdominal cavity. If the testicle could be pulled into the abdominal cavity, laparoscopic dissection and orchiopexy were performed. The gubernaculums testis (GT) was cut off in the abdominal cavity and the peritoneum around the IIR was cut off completely, and the vessels and deferent duct were dissected for adequate testicular mobilization before the testicle was retracted to the scrotum for orchiopexy by using a clamp inserted from scrotum and guided by a suction tube. The suction tube was inserted from the ipsilateral trocar through the inguinal canular and eventually sent out from the scrotum incision. A clamp was inserted into the suction tube [Fig. 1] to retract it until the clamp could be smoothly pushed into the abdominal cavity. After bringing the testis into the scrotum, 2-3 sutures were made to fix the testis inside the scrotum. If the testicle could not be pulled into the abdominal cavity, the inguinal incisions were transferred.

In the TIO group, the GT was cut off through an inguinal incision and a standard inguinal orchiopexy was performed. The operations in both groups were done by different surgeons in the same period.

Independent t test and Chi-square test were performed by using the SPSS 25.0 software. The normality of data was checked before the t-test (U-test was used if the data did not obey normal distribution). Chi-square test was performed (for cell(s) with n<5, Fisher's exact test was performed).

Results

Among the 170 patients who underwent laparoscopic exploration, 137 patients (80.5%) achieved LO without being transferred to the inguinal incisions. Among them, 49 cases were younger than 1 year old, 48 cases (98.0%) had open IIR, and 47 cases (95.9%) successfully completed LO in an average of

30.77±6.02 minutes. Among the 86 patients aged 1-2 years, 83 cases (96.5%) had open IIR, and 80 cases (93.0%) successfully completed LO. Among the 22 patients aged 2-3 years, 13 cases (59.1%) had open IIR, and 9 cases (40.9%) successfully completed LO. Among the thirteen patients older than 3 years, 3 patients (23.1%) had open IIR and only 1 patient (7.7%) successfully completed LO. In all cases, the testicles were placed at the middle or bottom of the scrotum. 33 cases were transferred to inguinal incisions because their IIR was closed. 10 cases were transferred to inguinal incisions because their testicles could not be pulled into the abdominal cavity although their IIR was open. (Fig. 2, Fig. 3)

The transferred 43 cases were still deemed as subjects in the LO groups. In the younger groups, the mean operative time (younger than 1 year old, 30.50±5.88 vs. 39.86±6.11 min; 1-2 years old, 34.43±6.65 vs. 40.23±8.74) and postoperative normal activity time (younger than 1 year old, 1.20±0.40 vs. 2.12±0.48 days; 1-2 years old, 1.58±0.50 vs. 2.02±0.43 days) of LO were significantly shorter than those in the TIO group ($P<0.05$). The operative time of LO was significantly longer than that in the TIO group in older groups (aged>3 years old). There were no statistically differences in postoperative normal activity time between LO and TIO in the elder group (aged>3 years old). (Fig.4, Fig.5) The follow-up also showed no difference between the two groups. (Table 2)

Discussion

In recent years, LO has been mostly applied to the treatment of nonpalpable undescended testes and peeping testicles. The results showed that laparoscopic surgery was more efficient and more sufficient than the traditional surgery in terms of testicular dissection. To date, laparoscopic surgery has become a gold standard for nonpalpable undescended testes [3, 8]. However, the application of LO for palpable undescended testes still remains controversial.

In 1995, Docimo et al. [9] first reported the use of LO treatment for palpable undescended testes. Then, Riquelme et al. indicated that LO was a safe procedure for patients with palpable undescended testes, and no more complications were found compared to the traditional surgery. Of 192 patients studied, only one case was converted to TIO [7,10]. However, based on the surgeon’s preference and experience, inguinal and prescrotal techniques are still recommended for palpable UDT undergoing surgery [11].

Bianchi first described a scrotal approach for the management of cryptorchidism in 1989 [12]. Evidence showed that the scrotal approach had a success rate of 88–100% for palpable UDT [13]. However, the general view is that the outcome of the operation tends to be poorer when more proximal testes are involved due to inadequate exposure. [14]

As far as the etiology of cryptorchidism is concerned, testicular descent from the abdominal cavity to scrotum occurs between 25 and 35 weeks of gestation [15]. Testicular descent into scrotum relies on a ligament called gubernaculums testis (GT). Many uncertain reasons prevent testicular descent, and the testicle remains in the abdomen or groin in cryptorchidism [16]. Meanwhile, the GT remains as a ligament and prevents the extension of the testicle into the scrotum.

During the surgery of orchidopexy, it is required to cut off the dysplastic GT as the main procedure to make adequate mobilization of testicles. In LO for palpable undescended testes, if the testicles can be pulled back into the abdominal cavity, it is more convenient to use the laparoscopic approach to cut off the dysplastic GT compared to the traditional approach. The subsequent mobilization of testicles will be sufficient and efficient. Therefore, whether the testicles can be pulled back into the abdominal cavity is a key factor.

According to relevant literature reports, the incidence of cryptorchidism associated with an inguinal hernia is 56% [17]. More than 92% of patients with unilateral palpable undescended testes have an ipsilateral open IIR at a median age of 14.9 months [18]. This study showed that in 98.0% of children under 1 year old, their IIR was open and 97.9% of the testicles could be pulled into the abdominal cavity to accomplish the LO procedure. In this study, it was also found that the opening of IIR did not necessarily cause hernia. The open IIR is generally present in cryptorchidism. The proportion of open IIR decreased gradually with the increasing age. From 2008, guidelines recommended that surgery should be performed before the child's first birthday to minimize the risk of impaired fertility [19]. At this recommended age, almost all IIR is open, which is an advantage for laparoscopy.

This study showed that palpable undescended testes associated with an ipsilateral open IIR were confirmed during more than 90% of laparoscopy (91.7) even in patients younger than 2 years of age. It seemed that LO was not suitable for the majority of elder children, especially those over two years of age. If IIR was closed, it would be very hard to complete LO surgery, since the testicles could not be pulled back into the abdominal cavity. Reopening the closed IIR was tried, but it was found that it was still hard to pull back the testicles and the risk of damage to the vas deferens and spermatic vessels was increased. Thus, a relatively conservative routine was taken by transferring to inguinal incisions when the IIR was closed. 43 out of 170 cases were converted to open inguinal approach. Combination with an inguinal incision may be necessary when the LO procedure is unsuitable for elder children, although further study is needed.

With regards to the closure of the peritoneal defect after the testicle has been mobilized during LO, when no ligature or suture was contemplated, the operative time decreased significantly. Rafiei et al. [20] carried out a randomized controlled trial to evaluate the no-ligation method in children. It was concluded that herniotomy without sac ligation in children saved significant time and also prevented other possible complications such as nerve damage and spermatic cord injury. Riquelme’s study showed that it is unnecessary to close the internal inguinal ring during LO [21]. In the above study on the staged treatment of LO, it was found that the peritoneum of the unsutured IIR in the first stage of the operation was completely closed during the second stage of the operation. Khairi et al. [22] carried out a prospective study to compare the difference between the IIR conventional suture group and non-closed IIR group during LO. It was concluded that the closing of the peritoneum over the IIR is not necessary in LO, saving operative time and effort while not increasing the risk of recurrent inguinal hernia [23, 24].

The main controversy of LO still remains on abdominal interference and anesthesia with tracheal intubation, which may cause more risks to patients. No additional complications of LO were observed in this study. Nevertheless, further studies are needed. Accompanied with the advance of the technique, incisions of Laparoscopic surgery are becoming smaller and their cosmetic impact is becoming less. Additionally, LO imitates the natural descent procedure of testes more closely.

Conclusions

LO is an appropriate choice for treating palpable undescended testes, especially in children younger than two years old. The percentage of successful LO decreased over an increasing age.

Abbreviations

LO: Laparoscopic orchidopexy

TIO: traditional inguinal incision orchidopexy

GT: gubernaculums testis

IIR: internal inguinal ring

Declarations

Ethics approval and consent to participate

The protocol was in accordance with the Declaration of Helsinki. Our study was approved by the Ethics Committee of the First People's Hospital of Lianyungang (JSYY-20131228001) on December 28, 2013.

Consent to publish

Not Applicable.

Availability of data and materials

The datasets used and/or analyzed in the current study are available from the corresponding author on reasonable request.

Competing interests

The authors declare no competing interests.

Funding

This research did not receive any specific grant from funding agencies in the public, commercial, or not-for-profit sectors.

Authors' contributions

GSD and LH designed the study; GSD and WYX collected the data;

GSD drafted the manuscript; WYX and LH revised the manuscript; all the

authors have read and approved the final manuscript.

Acknowledgements

The authors gratefully acknowledge the trust and support from the staff working for our pediatric surgery

The author confirms:

•that the work described here has not been published before;

•that it is not under consideration for publication elsewhere;

•that its publication has been approved by all co-authors, if any;

•that its publication has been approved (tacitly or explicitly) by the responsible authorities at the institution where the work is carried out.

The author agrees to publish in the Journal indicated below and also in English by BMC surgery journal.

Names of ALL contributing authors: Shaodong Gu, Yingxun Wang, Hong Luo

References

[1] Virtanen HE, Toppari J: Epidemiology and pathogenesis of cryptorchidism. Hum Reprod Update 2008, 14(1):49-58.

[2] Barthold JS, Gonzalez R: The epidemiology of congenital cryptorchidism, testicular ascent and orchiopexy. J Urol 2003, 170(6 Pt 1):2396-2401.

[3] Niedzielski JK, Oszukowska E, Slowikowska-Hilczer J: Undescended testis - current trends and guidelines: a review of the literature. Arch Med Sci 2016, 12(3):667-677.

[4] Kolon TF, Herndon CD, Baker LA, Baskin LS, Baxter CG, Cheng EY, Diaz M, Lee PA, Seashore CJ, Tasian GE et al: Evaluation and treatment of cryptorchidism: AUA guideline. J Urol 2014, 192(2):337-345.

[5] Dar SA, Bali RS, Zahoor Y, Rashid Kema A, Bhardwaj R: Undescended Testes and Laparoscopy: Experience from the Developing World. Adv Urol 2018, 2018:1620470.

[6] You J, Li G, Chen H, Wang J, Li S: Laparoscopic orchiopexy of palpable undescended testes_ experience of a single tertiary institution with over 773 cases. BMC Pediatr. 2020, 20(1):124.

[7] Riquelme M, Elizondo RA, Aranda A: Palpable Undescended Testes: 15 Years of Experience and Outcome in Laparoscopic Orchiopexy. J Endourol 2015, 29(9):978-982.

[8] Elderwy AA, Kurkar A, Abdel-Kader MS, Abolyosr A, Al-Hazmi H, Neel KF, Hammouda HM, Elanany FG: Laparoscopic versus open orchiopexy in the management of peeping testis: a multi-institutional prospective randomized study. J Pediatr Urol 2014, 10(4):605-609.

[9] Docimo SG, Moore RG, Adams J, Kavoussi LR: Laparoscopic orchiopexy for the high palpable undescended testis: preliminary experience. J Urol 1995, 154(4):1513-1515.

[10] Riquelme M, Aranda A, Rodriguez C, Villalvazo H, Alvarez G: Laparoscopic orchiopexy for palpable undescended testes: a five-year experience. J Laparoendosc Adv Surg Tech A 2006, 16(3):321-324.

[11] Braga LH, Lorenzo AJ, Romao RLP. Canadian Urological Association-Pediatric Urologists of Canada (CUA-PUC) guideline for the diagnosis, management, and followup of cryptorchidism. Can Urol Assoc J. 2017, 11(7):E251-E260.

[12] Bianchi A, Squire BR. Transscrotal orchidopexy: Orchidopexy revised. Ped Surgery Int. 1989,4:189–192.

[13] Novaes HF, Carneiro Neto JA, Macedo A Jr, Barroso Júnior U. Single scrotal incision orchiopexy - a systematic review. Int Braz J Urol. 2013, 39(3):305-311.

[14] Gordon M, Cervellione RM, Morabito A, Bianchi A. 20 years of transcrotal orchidopexy for undescended testis: results and outcomes. J Pediatr Urol. 2010, 6(5):506-512.

[15] Hutson JM, Li R, Southwell BR, Newgreen D, Cousinery M: Regulation of testicular descent. Pediatr Surg Int 2015, 31(4):317-325.

[16] Szarek M, Li R, Vikraman J, Southwell B, Hutson JM: Molecular signals governing cremaster muscle development: clues for cryptorchidism. J Pediatr Surg 2014, 49(2):312-316; discussion 316.

[17] Barthold JS, Wintner A, Hagerty JA, Rogers KJ, Hossain MJ: Cryptorchidism in Boys With Cerebral Palsy Is Associated With the Severity of Disease and With Co-Occurrence of Other Congenital Anomalies. Front Endocrinol (Lausanne) 2018, 9:151.

[18] Aggarwal H, Kogan BA, Feustel PJ: One third of patients with a unilateral palpable undescended testis have a contralateral patent processus. J Pediatr Surg 2012, 47(9):1711-1715.

[19] Mathers MJ, Sperling H, Rubben H, Roth S: The undescended testis: diagnosis, treatment and long-term consequences. Dtsch Arztebl Int 2009, 106(33):527-532.

[20] Rafiei MH, Jazini A: Is the ligation of hernial sac necessary in herniotomy for children? A randomized controlled trial of evaluating surgical complications and duration. Adv Biomed Res 2015, 4:97.

[21] Riquelme M, Aranda A, Rodriguez C, Cortinas J, Carmona G, Riquelme QM: Incidence and management of the inguinal hernia during laparoscopic orchiopexy in palpable cryptoorchidism: preliminary report. Pediatr Surg Int 2007, 23(4):301-304.

[22] Khairi A, Shehata S, El-Kholi N: Is it necessary to close the peritoneum over the deep inguinal ring during laparoscopic orchidopexy? J Pediatr Urol 2013, 9(2):157-160.

[23] Mohta A, Jain N, Irniraya KP, Saluja SS, Sharma S, Gupta A: Non-ligation of the hernial sac during herniotomy: a prospective study. Pediatr Surg Int 2003, 19(6):451-452.

[24] Narayanan SK, Puthenvariath JN, Somnath P, Mohanan A: Does the internal inguinal ring need closure during laparoscopic orchiopexy with Prentiss manoeuvre? Int Urol Nephrol 2017, 49(1):13-15.

Tables

Table 1 General data of the patients

	LO	TIO	*P value*
Total(N)	170	121	
Left side(N)	74	50	
Right side(N)	96	71	0.479‡
Age (months)	16.62±8.43	18.37±15.35	0.372*

P-value<0.05 was considered statistically significant.

*Independent samples t-test was performed between the age of the two groups.

‡ Chi-square test was performed for different sides of the two groups.

'able 2. Comparison of postoperative outcomes between LO and TIO

	LO	TIO	*P*-value
Cases(N)(Total)	170	121	
Age> 6 months &<or=12months	49	50	
Age> 12 months &<or=24months	86	40	
Age> 24 months &<or=36months	22	20	
Age >36 months	13	11	
Operative time in minutes (mean±std)			
Age> 6 months &<or=12months	30.50±5.88	39.86±6.11	<0.001*
Age> 12 months &<or=24months	34.43±6.65	40.23±8.74	<0.001*
Age> 24 months &<or=36months	53.59±9.79	40.20±10.61	<0.001*
Age >36 months	57.31±9.35	47.82±8.12	0.015*
Normal activity time in days (mean±std)			
Age> 6 months &<or=12months	1.20±0.40	2.12±0.48	<0.001*
Age> 12 months &<or=24months	1.58±0.50	2.02±0.43	<0.001*
Age> 24 months &<or=36months	2.09±0.61	2.35±0.50	0.139*
Age >36 months	2.84±0.55	2.81±0.75	0.917*
Follow-up (6-12months)			
Testis atrophy(N)	1	2	1.000‡
Recurrence	0	0	
Hernia recurrence(N)	0	0	

P-value<0.05 was considered statistically significant.

*Independent samples t-test (two-tailed) was performed (normality of data was checked before t-test (if normal distribution was not obeyed, U-test was used))

‡ Chi-square test was performed (for cell(s) with n<5, Fisher’s exact test was performed

Figures

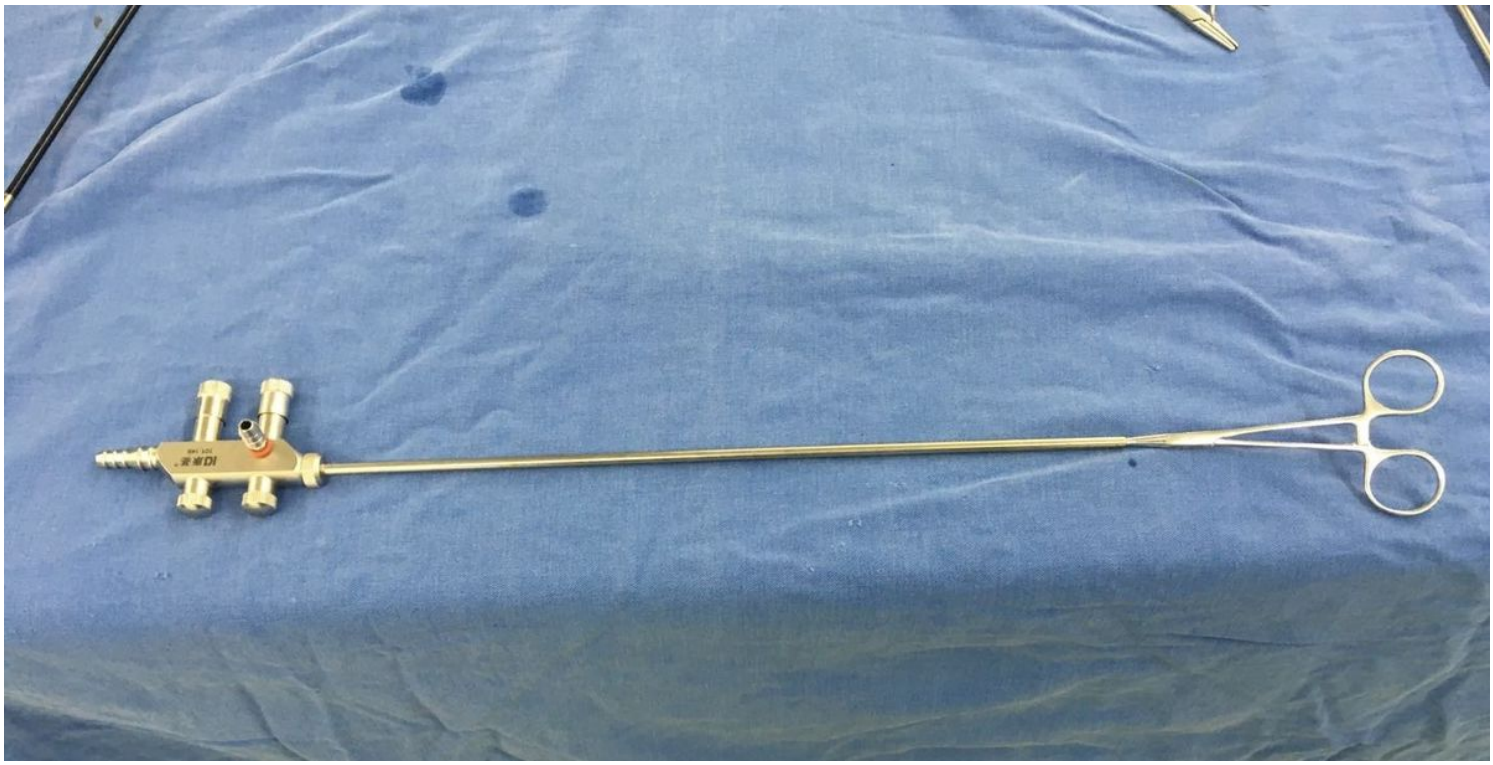

Figure 1

The testicle was retracted to the scrotum for orchiopexy by a clamp inserted from scrotum and guided by a suction tube.

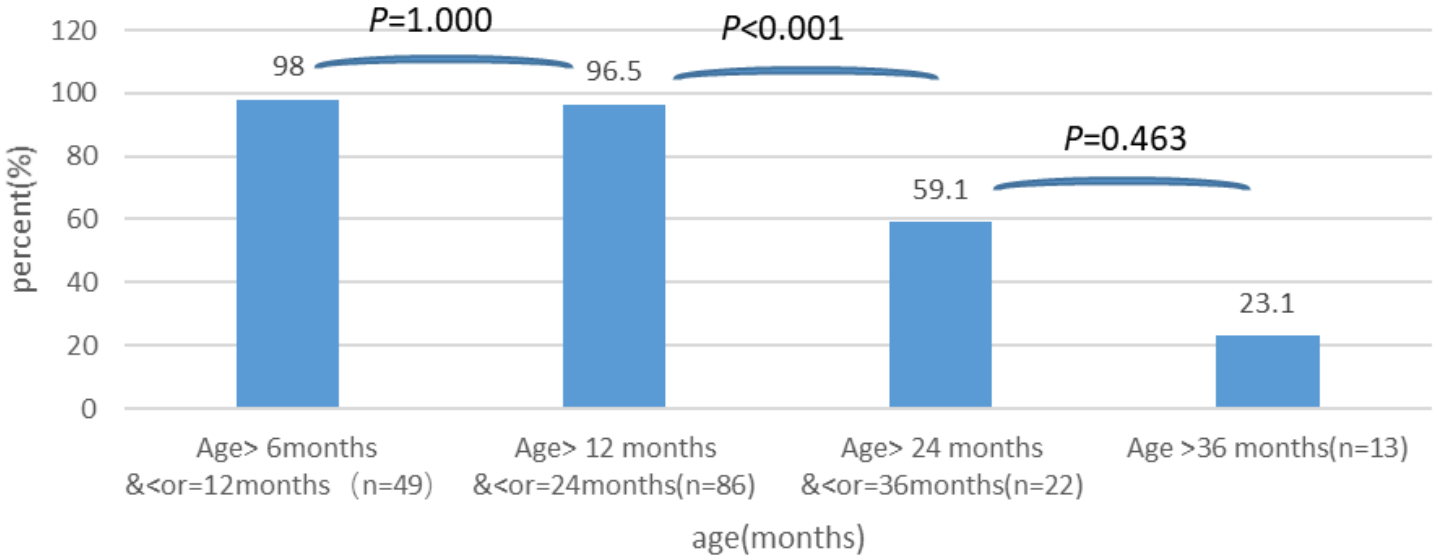

Figure 2

The proportion of open patent ring in LO groups over age. P-value<0.05 was considered statistically significant. Fisher's exact test was performed.

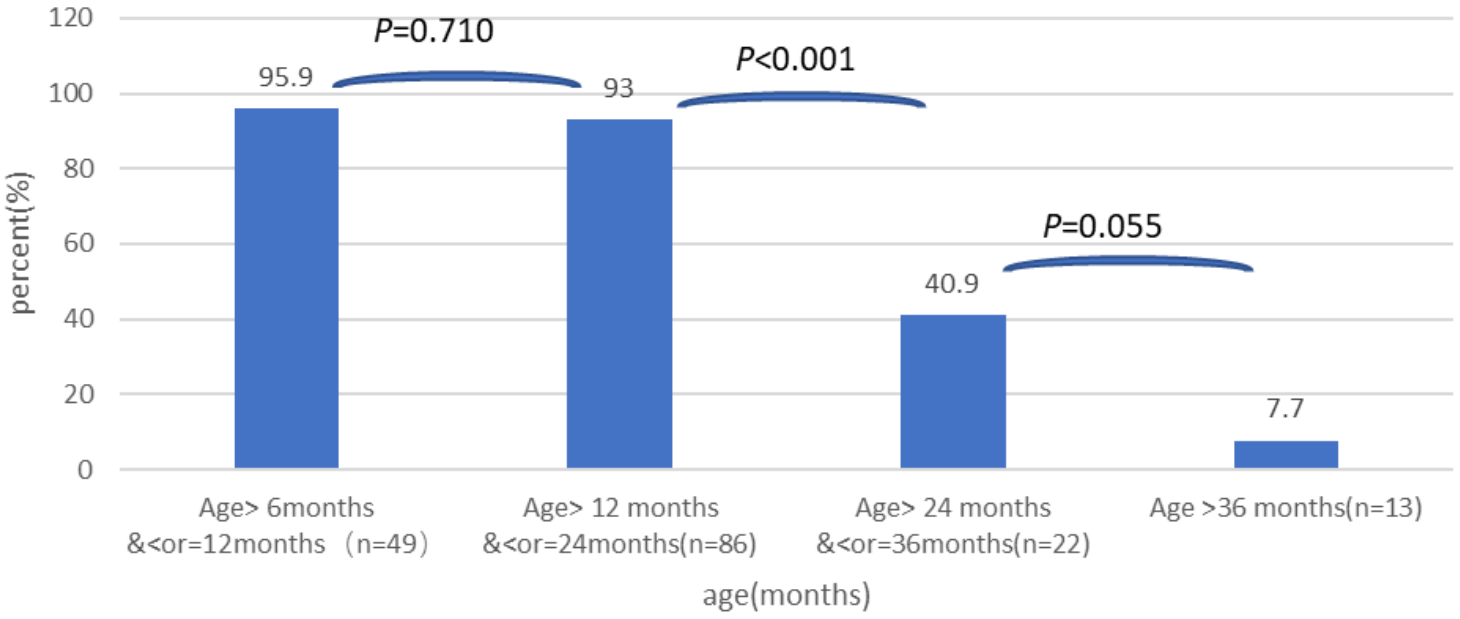

Figure 3

The successful rate of testicles that can be pulled into the abdominal cavity over age in LO groups. P-value<0.05 was considered statistically significant. Fisher's exact test was performed.

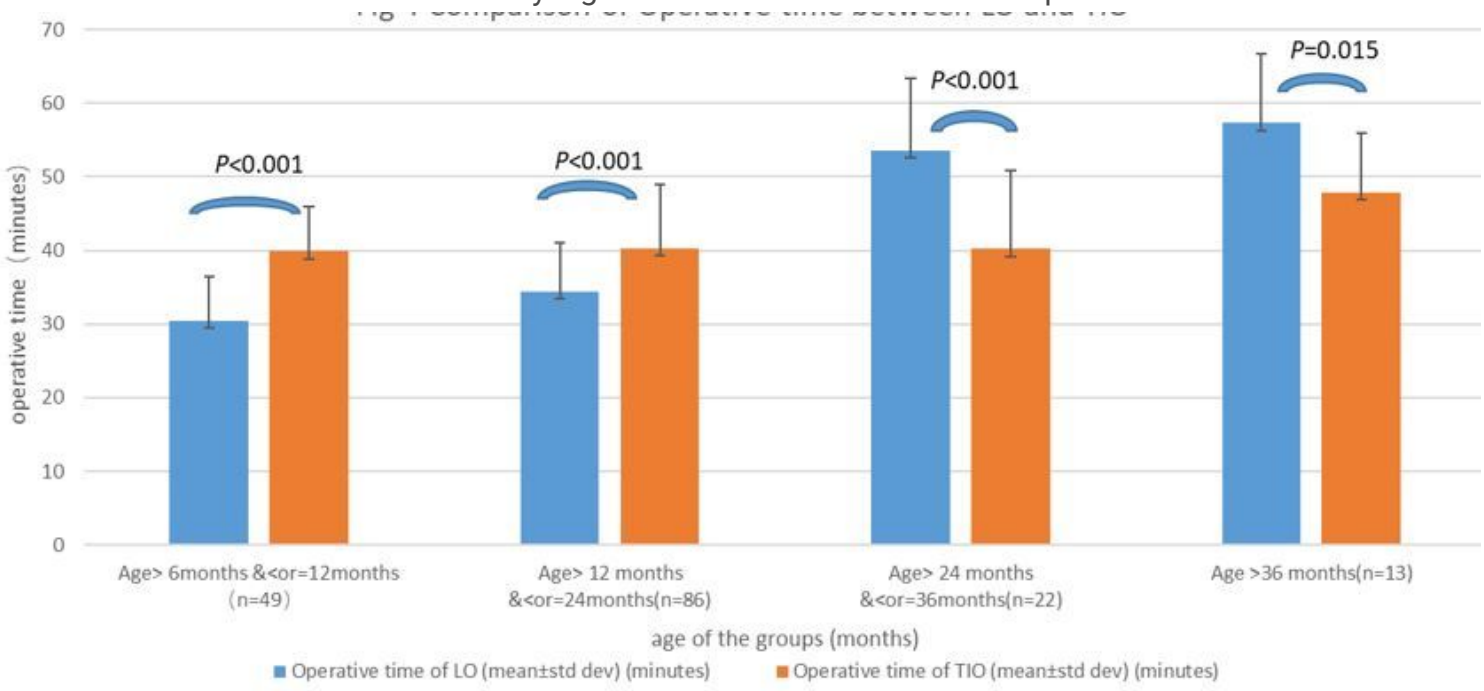

Figure 4

Comparison of operative time between LO and TIO.

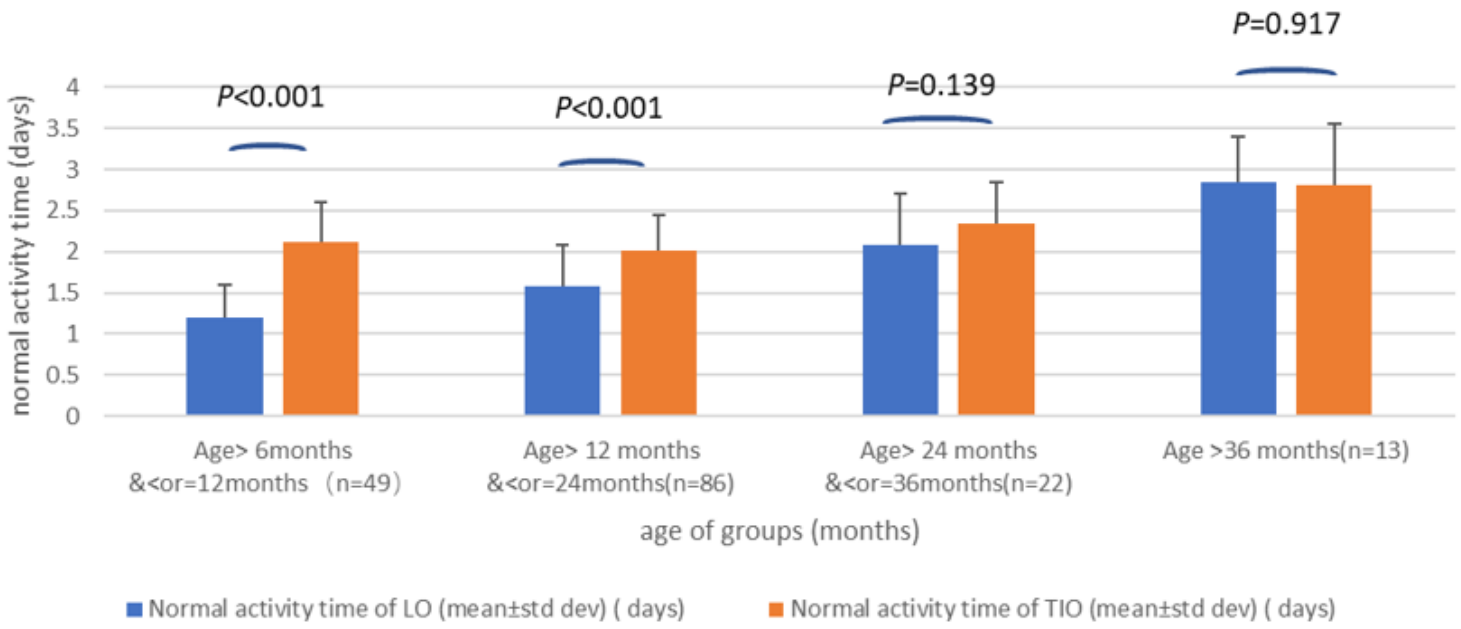

Figure 5

Comparison of postoperative normal activity time between LO and TIO