Research Square

Preprints are preliminary reports that have not undergone peer review. They should not be considered conclusive, used to inform clinical practice, or referenced by the media as validated information.

Trans-rectal natural orifice specimen extraction (NOSE) during laparoscopic anterior resection: Chinese experience with a novel method

Zhu-Qing Zhou
Shanghai East Hospital
Kai-Jing Wang
Shanghai East Hospital
Tao Du
Shanghai East Hospital
Wei Gao
Shanghai East Hospital
Zhe Zhu
Shanghai East Hospital
Qixin Jiang
Shanghai East Hospital
Fang Ji
Shanghai East Hospital
Dan Li
Shanghai East Hospital
Yuanyuan Zhang
Shanghai East Hospital
Chuan-Gang Fu (fugang416@163.com)
Shanghai East Hospital,Tongji University School of Medicnine https://orcid.org/0000-0001-7906-1129

Research article

Keywords: NOSE; Trans-rectal specimen extraction; Laparoscopy; Stapler anvil; colorectal cancer

Posted Date: July 16th, 2019

DOI: https://doi.org/10.21203/rs.2.11291/v1

License: This work is licensed under a Creative Commons Attribution 4.0 International License. Read Full License

Abstract

Background: To introduce a novel method for double stapling technique in colorectal anastomosis during laparoscopic anterior resection of upper rectal or sigmoid colon cancer with trans-rectal natural orifice specimen extraction (NOSE).

Methods: From June 2015 and May 2016, patients with upper-rectal or sigmoid colon cancer who received treatment in Shanghai East Hospital were enrolled. Preoperative and postoperative clinical variables were analyzed and compared between groups. Postoperative pain was analyzed utilizing a visual analog scale (VAS). Postoperative overall survival was analyzed using a K-M curve.

Results: A total of 99 colorectal cancer cases were randomly divided into NOSE with novel method group (NOSE, n=48) and conventional laparoscopic group (non-NOSE, n=51). No statistically significant differences in preoperative demographics of the patients as sex, age, body mass index were found among the groups. The NOSE group had the longer operation time, but less blood loss than the non-NOSE group. The NOSE group had no abdominal incision and the lower postoperative VAS score. The time for intestinal function recovery and the length of hospital stay (LOS) was statistically significantly different, with the non-NOSE group having the longer time. The incidence of postoperative complications was lower in NOSE group (5/48, 10.4%) than in the non-NOSE group (8/51, 15.7%), the difference was statistically significant. The K-M survival curve showed no statistically significant difference in the disease free survival rate between the NOSE group and non-NOSE group.

Conclusion: NOSE with novel method is safe and feasible to use in patients having colorectal cancer. Compared with traditional laparoscopic surgery, the postoperative complication rates of NOSE surgery were lower with an improved short-term clinical recovery.

Background

Traditional laparoscopic assisted colorectal surgery has the advantages of less trauma and quicker recovery, with surgical effects that are equivalent or similar to those of open surgery [1]. However, the vast majority of laparoscopic surgeries for rectal and sigmoid colon cancers are still laparoscopic assisted rather than total laparoscopic surgeries. After the complete dissociation of the tumour, a 5–6 cm incision on the abdomen is required for specimen removal and intestinal reconstruction[2].

Laparoscopic NOSE was first reported by Franklin in 1993 [3]. In 2008, Palanivel was the first to name the no-abdominal incision surgery as NOSE[4]. The innovation of NOSE surgery lies in the removal of specimens from natural orifices and bowel reconstruction with laparoscopy. Compared with the traditional laparoscopic surgery, the surgical trauma of NOSE is significantly reduced, because NOSE surgery is performed without an additional abdominal incision. Previous studies have reported that NOSE surgery has the advantages of a shorter hospital stay and recovery time, compared with traditional laparoscopic surgery[5-7].

NOSE was usually applied for benign tumour or early stage cancer in previous studies, and the methods of these study could not fulfill the principles of a sterile and tumour-free operation[8-11]. The NOSE with this novel method requires the avoidance of intra-abdominal bacterial contamination and tumour cell shedding. The short-term safety and complication between NOSE surgery and conventional laparoscopic surgery were compared.

Methods

Patient selection and clinical variables

From June 2015 and May 2016, 99 patients with colorectal cancer who received surgery in Shanghai East Hospital were randomly divided into two groups using the random number table (1:1), including NOSE with the new novel method group (NOSE, n=48), laparoscopy with abdominal incision group (non-NOSE, n=51). The exclusion criteria were as follows: (1) preoperative examination confirmed with distant organ metastasis of tumors; (2) radiation therapy, chemotherapy, or immunotherapy was performed before surgery; (3) no complete clinical and pathological data; (4) ulcerative colitis, Crohn's disease, or radiation proctitis in the intestinal canal distal to the tumour. This study was approved by the Ethics Committee of the Shanghai East Hospital affiliated to Tongji University. Written informed consents were obtained from all patients.

The preoperative and postoperative clinical variables of the two groups of patients were recorded, including sex, age, BMI, tumor distance from the anal verge, history of previous abdominal surgery, and carcinoembryonic antigen (CEA) and carbohydrate antigen 19-9 (CA199) levels. The postoperative variables of operation time, estimated intraoperative blood loss, size of tumor, intestine function recovery, length of hospital stay (LOS), postoperative complications, postoperative pain score. The pathologist determined the integrity of the TME and the pathologic Stage of the rectal cancer. A 10-point visual simulation scale was used for the assessment of the level of pain. The VAS scores on the first three postoperative days were collected and assessed in the two groups. The more severe the pain, the higher the score.

Operative procedure

Laparoscopic colorectal resection was performed in accordance with the principles of total mesorectal excision, and the specific surgical steps and the preparation of the specimen protection sleeve were performed as previously described. Upon completion of intestinal resection, the self-made specimen protection sleeve was inserted through the trocar into the abdomen. The stapler anvil was placed into the abdominal cavity through the protection sleeve. After the specimen was completely contained in the protection sleeve, the protection sleeve was pulled out together with the specimen. A piece of clean gauze was placed under the proximal colonic stump, the edge of the stump was cut off, and the open colonic stump was locally disinfected using iodophor. The stapler anvil was then placed in the colonic stump, and the colonic stump was closed with Hem-o-lok clips. The colonic stump was annularly fixed onto the

central rod of the stapler anvil with a snare, and excess colonic tissue was cut away with scissors. A tubular stapler was inserted through the rectum, and the central rod was pulled out from the centre of the rectal stump and closed with the proximal anvil to complete the colorectal anastomosis, as shown in Figure 1.

Statistical analyses

All data were completed using the SPSS 20.0 statistical software. Measurement data were expressed as () and compared with the t test, and the enumeration data were expressed as [n (%)] and compared using a $\chi 2$ test. The survival curves were plotted with the Kaplan-Meier method, and the log-rank test was used to analyze the relationship between the survival cycles of the two groups. Any difference with a *P* value of <0.05 was considered as statistically significant.

Results

Comparison of Preoperative and Postoperative Clinical Indexes among the two Groups

No statistically significant differences were found among the two groups in terms of preoperative indexes such as age, sex, BMI, tumor distance from the anal margin, and serum CEA and CA199 levels. No significant differences in postoperative tumor diameter, lymph node positivite rate, and tumor staging were found among the two groups (P>0.05).

Compared with the non-NOSE group (146.2 ± 42.1 min), the NOSE group had a longer operation time (167.0±45.0min, P=0.014). The non-NOSE group had a larger amount of intraoperative bleeding (91.3±75.7ml) than the NOSE group (52.6±23.1ml), P<0.001. The times for postoperative intestine function recovery were shorter in NOSE group (16.0±6.0h) than non-NOSE group (25.4±6.2h, P=0.021). The mean lengths of hospital stay were 11.7±3.1, 18.1±4.2days in the NOSE and non-NOSE groups, with the differences achieving statistical significance (P<0.001).The VAS scores for postoperative 3 days were significant difference between the two groups. NOSE group was significantly lower than that of the non-NOSE group (P<0.001), as shown in Table 1. (see Supplementary Files)

The incidence of postoperative complications in the NOSE group (5/48, 10.4%) was significantly lower than that in the non-NOSE group (8/51, 15.7%, P=0.036). Both of two groups had one case for anastomotic fistula and one case for intestinal obstruction. There were no patients had wound infection in NOSE group but 4 cases in non-NOSE group. 3 cases in NOSE group had postoperative fever, and that was 2 cases in non-NOSE group.

Disease free Survival for NOSE and non-NOSE groups

The patients were followed up for 3 years. The K-M curve analysis revealed no statistically significant difference in overall survival between the NOSE and non-NOSE groups (P= 0.856), as shown in Figure 2.

Discussion

With the popularisation and development of laparoscopic minimally invasive surgical techniques, there have been reports of laparoscopic colorectal surgery with specimens removed through the colon, rectum and vagina[12,13]. The dissociation, separation, pull-out, and reconstruction of the intestine are all completed in the abdominal cavity during laparoscopic AR with NOSE. Laparoscopic AR with NOSE has an advantage over traditional laparoscopic surgery in postoperative recovery[6,14]. This study described a novel method of NOSE for sigmoid colon and upper rectal cancer. In addition, the safety and clinical recovery of the NOSE surgery were compared with conventional laparoscopic surgery. This study provides a clinical basis for the application of trans-rectal NOSE surgery for colorectal cancer.

This study showed that the short-term clinical efficacy of the NOSE surgery was superior. Postoperative pain scores in the NOSE group were significantly lower than those in the non-NOSE group. NOSE surgery maintained the integrity of the abdominal wall and protected the function of the abdominal wall. Therefore, the patient's postoperative pain was also relatively lighter, which contributed to the patient's early activities. Because the abdominal cavity was not exposed, there was less intestinal interference in the NOSE surgery than in traditional laparoscopic surgery[14]. Therefore, the time of intestinal function recovery in the NOSE group was shorter than the traditional laparoscopic group. Tumor metastasis at the puncture and incision sites after laparoscopic surgery for colorectal cancer is still a controversial issue[15-19]. Because there is no auxiliary incision on the abdominal wall in NOSE surgery, there is no chance of incision metastasis[20-22]. In addition, the incidence of postoperative complications of the NOSE surgery was lower than non-NOSE surgery. Incision complications such as wound infection are eliminated in NOSE group.

Our experience with novel method for NOSE surgery have three key surgical steps. The NOSE surgery for cancer must be completed in a '1-out and 2-in' manner. Here, '1-out' refers to the removal of the specimen with protection sleeve, and '2-in' refers to the insertion of the anvil into the abdominal cavity and placement in the proximal colon. In the previous study, a specimen protection sleeve was used in the surgery, which provided an excellent solution for the problems associated with specimen removal and anvil introduction into the abdominal cavity[23]. Instead of using the anus and rectum as the route of insertion, this study inserted the protection sleeve through the 12-mm trocar in abdomen, then pulled it out from the rectum in an anterograde fashion, thereby effectively avoiding the risk of contamination during the insertion of the protection sleeve. Before the specimen was pulled out through the protection sleeve, the sterile anvil was placed into the abdominal cavity through the protection sleeve, thus avoiding the risk of intra-abdominal contamination by bacteria or shed tumour cells. A variety of methods have been reported for the placement of the stapler anvil in the proximal colon, which have shortcomings in terms of complicated use or implausible techniques[10-11]. The introduction of the central rod of the anvil into the sterile abdominal cavity from the non-sterile intestinal canal leads to a high risk of abdominal cavity contamination and violates the principle of a sterile operation. In the present study, we inserted the anvil into the proximal colon in an anterograde fashion, and subsequently ligated and fixed the anvil with

a snare. This method is in line with the principle of a sterile operation, and is simple to perform and easy to master. Concurrently, Hem-o-lok clips were used to pre-clamp the colonic stump, which facilitated the complete and secure colonic stump ligation with the snare, thereby preventing the incidence of anastomotic fistula. These three steps were sure to avoid bacterial contamination and tumour cell shedding in the abdominal cavity during NOSE surgery.

In summary, in laparoscopic NOSE, the novel method of stapler anvil placement described in the present study can effectively reduce the risk of intra-abdominal contamination as well as tumour cell shedding and implantation. In addition, the ease and feasibility of use provide great value in the wide clinical application of this method. Minimally invasive techniques and related devices are still at a stage of rapid development, and the consequent concept of minimal invasion will be further advance. Certainly, laparoscopic AR with NOSE will be performed in an increasing number of patients, which will lead to more reasonable indications and further optimisation of surgical procedures. Hence, there are great prospects in the practical application of our method.

Conclusion

NOSE with novel method include removal of the specimen with protection sleeve, insertion of the anvil into the abdominal cavity through protection sleeve and placement in the proximal colon. This novel method is safe and feasible to use in patients having colorectal cancer. Compared with traditional laparoscopic surgery, the postoperative complication rates of NOSE surgery were lower with an improved short-term clinical recovery.

Declarations

Ethics approval and consent to participate: This study was approved by the Ethics Committee of Shanghai East Hospital, Tongji University. Collection of patients' follow-up data was conducted in accordance with guidelines for the collection of human follow-up data from the Shanghai East Hospital, Tongji University.

Consent for publication: All patients including the index case signed a consent form for publication

Availability of data and material: The datasets generated and analysed during the current study are available from the corresponding author on reasonable request.

Competing interests: The authors declare that they have no conflict of interest.

Funding: This study was funded by the National Natural Science Foundation of China (approval number 81573004; approval number 81773275; approval number 81871953); Health and Family Planning Committee of Pudong New Area (CN) (Grant No.PWZzk2017–26). The funding body had no role in the study design, data collection and analysis, or preparation of manuscript.

Author`s contributions: WKJ, ZZQ and ZZ conceived and designed the study. LD and DT supervised the power analyses and wrote the data analyses section. JQX, JF and ZYY bear overall responsibility for the design, ethical conduct and publication of the study. Administrative, technical and material support was provided by ZZY, GW and FCG. All authors have read and approved the manuscript.

Acknowledgements: The authors appreciate much support from the doctors in department of colorectal surgery, Shanghai East Hospital. The authors would also like to thank Zuo-ren Yu for his generous assistance with this study.

References

1. Huang CC, Chen YC, Huang CJ, et al. Totally Laparoscopic Colectomy with Intracorporeal Side-to-End Colorectal Anastomosis and Transrectal Specimen Extraction for Sigmoid and Rectal Cancers[J]. Annals of Surgical Oncology, 2016, 23(4):1164-1168.

2. Jayne DG, Guillou PJ, Thorpe H, et al. Randomized trial of laparoscopic-assisted resection of colorectal carcinoma: 3-year results of the UK MRC CLASICC Trial Group.[J]. Journal of Clinical Oncology, 2007, 25(21):3061.

3.Franklin ME, Ramos R, Rosenthal D, et al. Laparo-scopic colonic procedures. World J Surg,1993,17(1):51-56.

4. Benhidjeb T, Stark M. An innovative technique for colorectal specimen retrieval: a new era of "Natural Orifice Specimen Extraction" (N.O.S.E.)[J]. Diseases of the Colon & Rectum, 2008, 51(7):1120-1124.

5.Wolthuis AM, Van Geluwe B, Fieuws S, et al. Laparoscopic sigmoid resection with transrectal specimen extraction: a systematic review[J]. Colorectal Dis, 2012, 14(10): 1183-1188.

6.Ma B, Huang XZ, Gao P, et al. Laparoscopic resection with natural orifice specimen extraction versus conventional laparoscopy for colorectal disease: a meta-analysis[J]. International Journal of Colorectal Disease, 2015, 30(11):1479-88.

7. Park JS, Choi GS, Kim HJ, et al. Natural orifice specimen extraction versus conventional laparoscopically assisted right hemicolectomy[J]. British Journal of Surgery, 2011, 98(5):710-715.

8.Akamatsu H, Omori T, Oyama T, et al. Totally laparoscopic sigmoid colectomy: a simple and safe technique for intracorporeal anastomosis[J]. Surg Endosc, 2009,23(11): 2605-2609.

9.Karagul S, Kayaalp C, Sumer F,et al.Success rate of natural orifice specimen extraction after laparoscopic colorectal resections[J].Tech Coloproctol,2017,21(4):295-300.

10.Christoforidis D, Clerc D, Demartines N. Transrectal specimen extraction after laparoscopic left colectomy: a case-matched study[J]. Colorectal Disease,2013,15(3):347-353.

11.Nishimura A, Kawahara M, Suda K, et al. Totally laparoscopic sigmoid colectomy with transana specimen extraction[J].Surg Endosc,2011,25(10): 3459-3463.

12.Torres RA, Orban RD, Tocaimaza L, et al. Transvaginal Specimen Extraction After Laparoscopic Colectomy[J]. World J Surg,2012,36(7): 1699-1702.

13.Cai JC, Hong XY. Laparoscopic-Assisted Natural Orifice Specimen Extraction Radical Descending Colectomy Using a Cai Tube[J]. World J Surg ,2016,40(11): 2803-2807.

14.Wolthuis A M , Fieuws S , Van D B A , et al. Randomized clinical trial of laparoscopic colectomy with or without natural-orifice specimen extraction[J]. British Journal of Surgery, 2015, 102(6):630-637.

15. Berger-Richardson D, Chesney TR, Englesakis M, et al. Trends in port-site metastasis after laparoscopic resection of incidental gallbladder cancer: A systematic review[J]. Surgery, 2016, 161(3):618-627.

16. Silecchia G , Perrotta N , Giraudo G , et al. Abdominal wall recurrences after colorectal resection for cancer[J]. Diseases of the Colon & Rectum, 2002, 45(9):1172-1177.

17. Vukasin P, Ortega A E, Greene F L, et al. Wound recurrence following laparoscopic colon cancer resection. Results of the American Society of Colon and Rectal Surgeons Laparoscopic Registry[J]. Diseases of the Colon & Rectum, 1996, 39(10):S20-S23.

18. Hofer SOP, Shrayer D, Reichner JS, et al. Wound-Induced Tumor Progression: A Probable Role in Recurrence After Tumor Resection[J]. Archives of Surgery, 1998, 133(4):383.

19. Zmora O, Gervaz P, Wexner SD. Trocar site recurrence in laparoscopic surgery for colorectal cancer[J]. Surgical Endoscopy, 2001, 15(8):788-793.

20. Gazala M A, Wexner S D. Re-appraisal and consideration of minimally invasive surgery in colorectal cancer[J]. Gastroenterology Report, 2017, 5(1):1-10.

21. Wang Q, Wang C, Sun D H, et al. Laparoscopic total mesorectal excision with natural orifice specimen extraction[J]. World Journal of Gastroenterology, 2013, 19(5):750-754.

22. Griffin R, Qureshi I, Awad Z. Laparoscopic right hemicolectomy: A comparison of natural orifice vs. transabdominal specimen extraction[J]. Surgical Endoscopy, 2014, 28(10):2871-2876.

23. Wolthuis AM, DeBVOA, D'Hoore A. Laparoscopic NOSE-colectomy with a camera sleeve: a technique in evolution[J]. Colorectal Disease, 2015, 17(5):O123-O125.

Figures

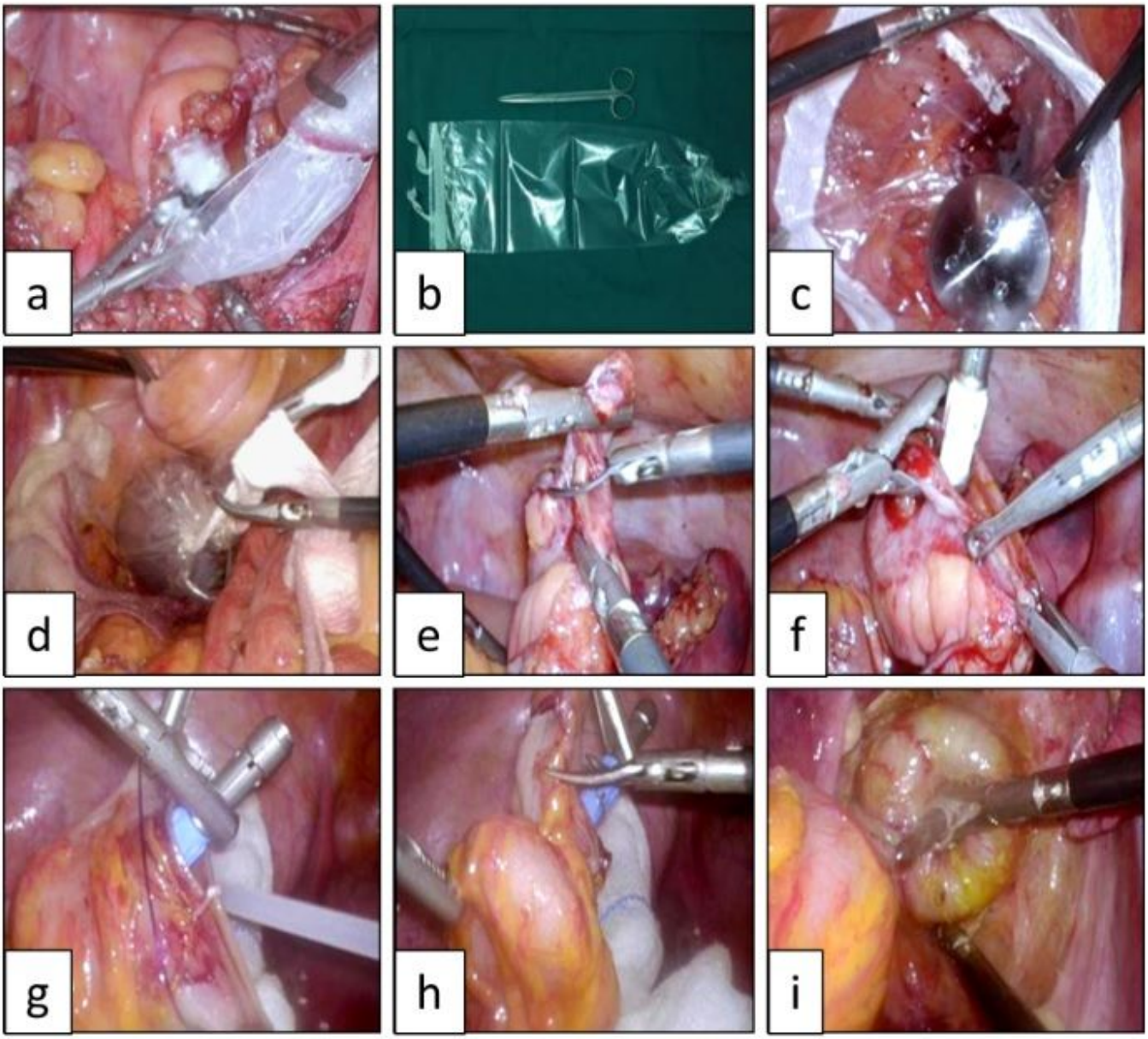

Figure 1

(a)Insertion of the plastic protection sleeve through the primary trocar. (b)Self-made specimen protection sleeve. (c)Introduction of the stapler anvil into the abdominal cavity. (d)Placement of the specimen into the protection sleeve, followed by specimen clamping and pull-out. (e)Cutting of the closed edge of the colonic stump. (f)Placement of the anvil in the intestine canal stump. (g)Ligation of the colonic stump to the central rod with a snare. (h)Cutting of excess intestinal wall tissue. (i)End-to-end colorectal anastomosis.

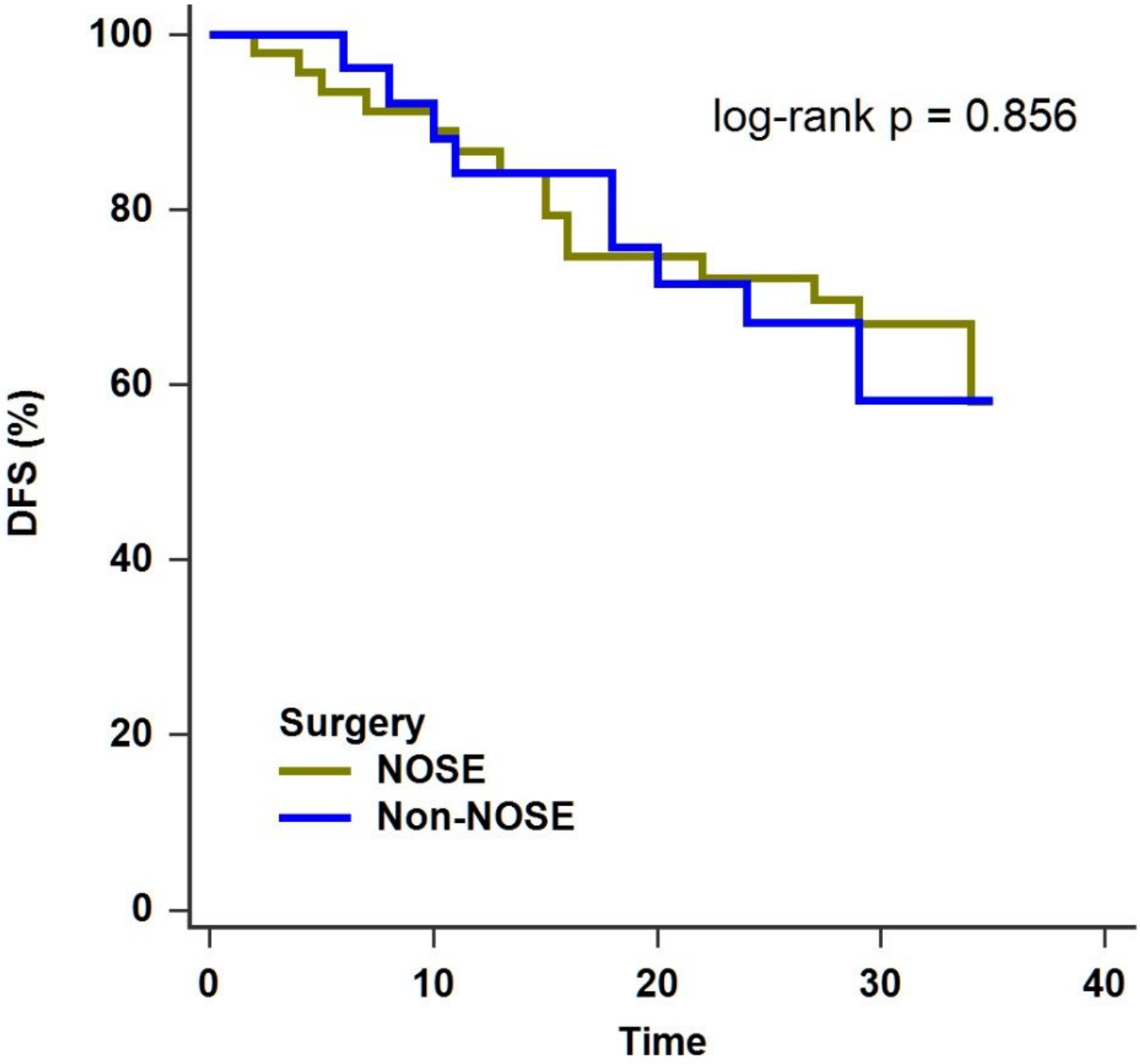

Figure 2

Disease free Survival between NOSE and non-NOSE groups, P>0.05.

Supplementary Files

This is a list of supplementary files associated with this preprint. Click to download.

- supplement1.xlsx
- supplement2.jpg

- supplement3.xlsx