

# Peripheral Sensory Stimulation of the Hand in the Treatment of Stroke. A Preliminary Study of Safety and Effectiveness

Eric S. Nussbaum (✉ [Lnussbaum@comcast.net](mailto:Lnussbaum@comcast.net))

National Brain Aneurysm & Tumor Center

Tariq M. Janjua

National Brain Aneurysm & Tumor Center

Jodi Lowary

National Brain Aneurysm & Tumor Center

Archie Defillo

National Brain Aneurysm & Tumor Center

Mark T. Myers

National Brain Aneurysm & Tumor Center

Leslie A. Nussbaum

National Brain Aneurysm & Tumor Center

---

## Research Article

**Keywords:** Ischemia, Outcome, Sensory stimulation, Stroke

**Posted Date:** November 1st, 2022

**DOI:** <https://doi.org/10.21203/rs.3.rs-2194868/v1>

**License:** © ⓘ This work is licensed under a Creative Commons Attribution 4.0 International License.

[Read Full License](#)

---

# Abstract

## Background

Ischemic stroke impacts roughly 700,000 patients per year in the United States, yet there are limited options to improve recovery for individuals with a completed stroke and associated neurological deficit. We describe a preliminary clinical trial of a novel non-invasive device that provides peripheral somatosensory stimulation using intermittent jets of air to the affected hand in patients with ischemic stroke.

## Methods

The safety and short-term impact of the use of a non-invasive device providing peripheral somatosensory stimulation were investigated in four patients after mild to moderate stroke. Perfusion MR imaging was performed with the device off and then on in each patient. Serial evaluations of the NIH stroke scale score, Glasgow Outcome Score, and Barthel Index were performed in each case.

## Results

All patients tolerated treatment with the device. No complications related to the use of the device were encountered. A non-blinded neuroradiologist interpreted the MR imaging as demonstrating improved perfusion in three of four cases. All patients demonstrated neurological improvement over the course of treatment.

## Conclusions

It has been suggested that peripheral somatosensory stimulation may improve recovery from stroke. We investigated the use of a novel non-invasive device that delivers intermittent jets of air to the affected forearm and hand. In this small, preliminary series, treatment was well-tolerated in all cases. A larger trial properly empowered to demonstrate clinical benefit may be warranted.

## Introduction

It has been shown in rodent models of stroke that early peripheral sensory stimulation significantly and reproducibly improves neurological outcomes following ischemic injury and may prevent injury entirely if applied early enough (1–3). Potential suggested mechanisms for this protection and benefit include encouragement of collateral blood supply to the affected sensorimotor cortex improving regional cerebral perfusion and/or neuronal reorganization allowing for heightened functional recovery (4–5). Clinical experience in humans has suggested that such peripheral sensory stimulation can improve recovery after stroke and may also be beneficial following traumatic brain injury and in degenerative conditions such as

Parkinson's disease and multiple sclerosis (6–16). We report a preliminary clinical study in stroke patients evaluating the safety, efficacy, and impact on CBF of a novel device which can be applied to the hand of a stroke victim during the acute, subacute, or chronic phases of stroke to provide sensory stimulation in the form of pneumatic puffs of air.

## Methods - Study Design

The PSSST (Peripheral Somato-Sensory Stimulation Trial) aimed to recruit four patients between the ages of 25 and 85 years presenting with a mild to moderate stroke with symptoms that did not completely resolve following acute intervention. IRB approval was obtained from our institution with the trial planned as a safety and preliminary effectiveness study. Exclusion criteria included coma, inability to cooperate with the study based on impaired level of consciousness or confusion, complete middle cerebral artery infarction based on imaging, NIH stroke scale score (NIHSS) of 0 or greater than 20, and the presence of neurological impairment at baseline prior to developing this stroke.

Patients were admitted to the hospital and stabilized using the standard protocols established for acute stroke care by our stroke service. Treatments (medical, endovascular, and/or surgical) were offered and performed as per standard protocols, thus inclusion in the trial carried no impact on the management that the patients would have otherwise received. Informed consent was obtained in all cases, and strict patient privacy was maintained throughout the study.

Forty-eight hours after admission to the Neuro-ICU, once deemed stable by the neurology stroke service, eligible patients were offered inclusion in this study with the understanding that their care would in no way be impacted by their decision.

The device, NeuroGlove, is a plastic chamber with multiple apertures along its length to allow for puffs of air to be directed to the volar surface of the distal forearm, the palm, and the fingers (Fig. 1). A pneumatic pump delivers intermittent puffs of air cycling between 1 second on and two seconds off. The affected hand is placed within the device chamber on a gel pad to provide a comfortable resting surface for the duration of the treatment.

Patients included in the study had the device applied to their affected hand (contralateral to the side of the stroke) for 30 minutes, twice per day for 5 days. At some time during the treatment period, patients were brought to the MRI suite and underwent perfusion MRI with their hand in the device, first with the device turned off and then again with it activated. The MR imaging was evaluated by a board certified neuroradiologist who was not blinded. They were asked to provide a qualitative evaluation of the pre- and post-treatment studies to include a limited quantitative comparison of perfusion before and after device activation.

Patients underwent neurological examination including NIHSS, GOS scoring, and Barthel Index evaluation upon entry into the study, at one week, and then at one month after enrollment. Any complications potentially related to the use of the device were recorded. Patients who underwent

treatment were asked to describe the device as “uncomfortable”, “acceptable, or “comfortable/pleasant”. Nurses were asked to rate the difficulty associated with use of the device on a scale of 1–5 with 1 being “simple/straightforward” and 5 being “complicated or difficult to apply”.

## Results

Five patients were screened for the study; four agreed to participate. Patient ages ranged from 59 to 73 years. There were three men and one woman. One patient had diabetes mellitus. Three patients had a prior diagnosis of hypertension. Two patients had a history of coronary artery disease, and three were receiving statin therapy for known hyperlipidemia. All patients demonstrated elevated cholesterol levels with abnormal lipid profiles at the time of admission. All patients were normal neurologically at baseline (before this event), and none had suffered a prior stroke or transient ischemic attack. One patient had a history of chronic obstructive pulmonary disease, and three had a history of smoking. One patient had a history of atrial fibrillation.

No patient in this group underwent endovascular intervention either before or after entry into the trial. Following admission, three patients were started on anticoagulation, and one was treated with antiplatelet therapy alone, with anticoagulant or antiplatelet therapy initiated before entry into the trial. All four patients completed the trial. No patient suffered an adverse reaction attributable to use of the device or inclusion in the study. All patients considered the treatment “comfortable/pleasant”. No patient was unable to tolerate the treatment, and all nurses who administered/oversaw the therapy considered the treatment easy to deliver (rated as 1 on 1–5 scale).

All patients underwent successful perfusion MR imaging with the device off and then activated as planned. MR imaging was interpreted by a board-certified neuroradiologist. In three cases, the neuroradiologist felt that the application of the device resulted in improved local cerebral blood flow based on the perfusion imaging (Fig. 2). Based on quantitative evaluation using multiple regions of interest selected from axial slices at three levels of the brain, the average change in perfusion was – 2%, 11%, 17%, and 21% in the four patients. The available software did not allow for a formal statistical comparison.

One week after enrollment in the trial, all patients had completed therapy and were re-examined at that point by a stroke neurologist and neuro-intensivist. Patients were evaluated once again at 30 days after enrollment by a stroke neurologist or nurse practitioner. Demographic information, baseline neurological status, and status at 7 and 30 days are summarized in Table I.

On admission, all four patients demonstrated unilateral hemiparesis ranging from just a pronator drift to having just antigravity strength in the affected arm and leg. Three had cortical sensory findings on careful neurological examination, and one patient had mild associated dysphasia. All had shown some early improvement by one week, and by one month, three of the four were making good improvement with only mild symptoms, while one of the four still had moderate disability from their stroke (Table I).

## Discussion

Over the past thirty years, the management of acute ischemic stroke has been revolutionized by the introduction and use of intravenous and intra-arterial thrombolytic therapy (17–20). Subsequently, mechanical thrombectomy has become a mainstay of therapy for patients with large vessel occlusion, dramatically improving clinical outcomes in this setting. (21–26). At the same time, efforts aimed at stroke prevention based on dietary, lifestyle, and lipid profile modification have decreased the risk of stroke in the aging population (27–29).

Nevertheless, once a patient suffers an acute ischemic stroke and is left with some deficit, therapeutic options remain limited, largely focusing on combinations of inpatient and outpatient rehabilitation, speech therapy, and occupational therapy. This has created an unmet clinical need for novel therapeutic options to encourage healing and recovery following stroke after the options to limit the degree and extent of the acute ischemic injury have been implemented.

Multiple studies in rodent models of stroke have demonstrated the benefit of peripheral sensory stimulation of the rat whisker in limiting or preventing injury to the brain (1–5). Since the rat whisker is significantly over-represented in the rat sensory homunculus, it has been hypothesized that sensory stimulation of the human hand which has similar over-representation in man could provide protection in the setting of stroke and other brain insults. Based on this, several studies have examined the possible usefulness of vibratory or electrical stimulation in treating patients with stroke and other neurological disorders demonstrating apparent benefit based on improved neurological functioning (6–16, 30–39). Our work suggests that intermittent peripheral sensory stimulation using puffs of air may provide similar benefit in the setting of acute stroke.

The mechanism by which peripheral sensory stimulation may improve outcome after stroke is uncertain, although the importance of somatosensory input in modulating corticomotor excitability has been described (40). It has been suggested that such somatosensory therapy may enhance neuronal reorganization after stroke or traumatic brain injury, possibly taking advantage of intact neural circuits either in the ipsilateral or contralateral hemispheres (41–46). Alternatively, peripheral stimulation may improve regional cerebral perfusion in the sensorimotor cortex, encouraging recruitment of pial collateral channels and recovery of idling or under-perfused neurons. Our very limited work suggests that peripheral stimulation may improve cerebral perfusion in the affected hemisphere raising the possibility that increased blood flow may play a role in this process.

Of note, similar peripheral somatosensory stimulation may also be of benefit to patients with Parkinson's disease in whom motor deficits have been linked to abnormally synchronized neuronal activity in dopaminergic circuits (15, 47). In these patients, coordinated reset based on tactile feedback has been suggested as a mechanism to overcome excessive neuronal synchronization resulting in sustained "unlearning" of pathological synaptic connectivity and synchrony (15). The potential overlap of similar mechanisms of "unlearning" in the stroke patient is unclear but may warrant further investigation.

## Limitations

This very small clinical trial shows that peripheral sensory stimulation of the hand contralateral to the ischemic hemisphere using intermittent puffs of air can be applied safely to patients following acute stroke. The observed clinical benefit may be associated with some positive impact of the device, but could also represent natural recovery from stroke in this very small group of patients. The limited qualitative improvement in perfusion on MR imaging is interesting and suggests that improved local perfusion may be achieved through peripheral sensory stimulation, but the data analysis was limited by the available software, the number of patients is small, and the clinical impact of any such improvement is uncertain.

## Conclusions

In this limited trial, NeuroGlove was found to be safe, easy to apply, and comfortable with all patients successfully completing the trial. All patients showed neurological improvement during the course of the trial. Perfusion MR imaging showed improvement in local cerebral blood flow in 3 of the 4 patients tested, suggesting a potential mechanism by which peripheral sensory stimulation may improve outcomes following ischemic injury to the brain. We suggest a larger clinical trial properly powered to test the clinical benefit of the device is warranted.

## Declarations

### Declaration of Interest:

Drs. Nussbaum are shareholders in NeuroGlove, LLC.

## References

1. Lay CC, Jacobs N, Hancock AM, Zhou Y, Frostig RD. Early stimulation treatment provides complete sensory-induced protection from ischemic stroke under isoflurane anesthesia. *The European Journal of Neuroscience*. 2013;38: 2445-52. PMID 23586641 DOI: 10.1111/Ejn.12217
2. Frostig RD, Lay CC, Davis MF: A rat's whiskers point the way toward a novel stimulus-dependent protective stroke therapy. *The Neuroscientist*, 2012. DOI.10.1177/107385841246260701.
3. Lay C, Frostig RD: Complete protection from impending stroke following permanent MCAO in awake, behaving rats. *Eur J Neurosci* 2014; 40(9), 3413–21. DOI:10.1111/ejn.12723
4. Lay CC, Davis MF, Chen-Bee CH, Frostig RD: Mild sensory stimulation protects the aged rodent from cortical ischemic stroke after permanent MCA occlusion. *JAHA* 2012;1(4). DOI 10.1161/JAHA.112.001255
5. Hancock AM, Lay CC, Davis MF, Frostig RD. Sensory Stimulation-Based Complete Protection from Ischemic Stroke Remains Stable at 4 Months Post-Occlusion of MCA. *Journal of Neurological Disorders* 2013; 1: 135. PMID 24634892 DOI: 10.4172/2329-6895.1000135

6. Celnik P, Hummel F, Harris-Love M, Wolk R, Cohen LG. Somatosensory stimulation enhances the effects of training functional hand tasks in patients with chronic stroke. *Archives of Physical Medicine and Rehabilitation*, 2007;88(11), 1369–1376.
7. Conforto AB, dos Anjos SM, Bernardo WM, Silva AA, d Conti J, Machado AG, Cohen LG. Repetitive peripheral sensory stimulation and upper limb performance in stroke: A systematic review and meta-analysis. *Neurorehabilitation and Neural Repair* 2018; 32(10), 863–871.  
DOI.10.1177/1545968318798943
8. Conforto AB, Cohen LG, Dos Santos RL, Scaff M, Marie SKN. Effects of somatosensory stimulation on motor function in chronic cortico-subcortical strokes. *Journal of Neurology*, 2007;254(3), 333–339.
9. Conrad MO, Scheidt RA, Schmidt BD. Effects of wrist tendon vibration on targeted upper-arm movements in poststroke hemiparesis. *Neurorehab Neurol Repair* 2011; 25:61–70.  
<https://doi.org/10.1177/1545968310378507>
10. Maeda M, Mutai H, Toya Y, Maekawa Y, Hitai T, Katai S. Effects of peripheral nerve stimulation on paralysed upper limb functional recovery in chronic stroke patients undergoing low-frequency repetitive transcranial magnetic stimulation and occupational therapy: A pilot study. *HK J Occ Ther* 2020;33:31–11 <https://pubmed.ncbi.nlm.nih.gov/33815018/>
11. Nasrallah FA, Mohamed AZ, Hong KY, Hwa SL, Yeow C, Lim JH. Effect of proprioceptive stimulation using a soft robotic glove on motor activation and brain connectivity in stroke survivors. *J Neural Eng* 2021;18:1 -. <https://doi.org/10.1088/1741-2552/ac456c>
12. Seo NJ, Enders LR, Fortune A, Cain S, Vatinno AA, Schuster E, Ramakrishnan V, Feng W. Phase I safety trial: Extended daily peripheral sensory stimulation using a wrist-worn vibrator in stroke survivors. *Translational Stroke Research*, 2019;11(2), 204–213.
13. Seo NJ, Woodbury ML, Bonilha L, Ramakrishnan V, Kautz SA, Downey RJ, Dellenbach BHS, Lauer AW, Roark CM, Landers LE, Phillips SK, Vatinno AA. Therabracelet stimulation during task-practice therapy to improve upper extremity function after stroke: A pilot randomized controlled study. *Physical Therapy*, 2019; 99(3), 319–328.
14. Vatinno AA, Hall L, Cox H, et al: Using subthreshold vibratory stimulation during poststroke rehabilitation therapy. A case series. *OTJR* 2021; 42:. <https://doi.org/10.1177/15394492211042275>
15. Kristina JP, Kromer JA, Cook AJ, Hornbeck T, Lim EA, Mortimer BJ, Fogarty A, Han SS, Dhall R, Halpern C, Tass PA.: Coordinated reset vibrotactile stimulation induces sustained cumulative benefits in parkinson's disease. *Front Physiol* 2021; 12:
16. Tramontano M, Morone G, De Angelis S, Conti L, Galeoto G, Grasso MG. Sensor-based technology for upper limb rehabilitation in patients with multiple sclerosis: A randomized controlled trial. *Restor Neurol Neurosci* 2020;38:333–41. <https://pubmed.ncbi.nlm.nih.gov/32925119/>
17. Hacke W, Kaste M, Fieschi C, Toni D, Lesaffre E, von Kummer R, Boysen G, Bluhmki E, Höxter G, Mahagne MH, et al. Intravenous thrombolysis with recombinant tissue plasminogen activator for

- acute hemispheric stroke. The European Cooperative Acute Stroke Study (ECASS). *JAMA*. 1995;274(13):1017–25. PMID: 7563451.
18. Bekhemer O, Beumer F, Berg V, Lingsma H, Schonewile Y, Nederkoom V. The randomized trial of intra-arterial treatment for acute ischemic stroke (Mr. CLEAN). *N Engl J Med* 2015; 372
  19. Ogawa A, Mori E, Minematsu K, Taki W, Takahashi A, Nemoto S, Miyamoto S, Sasaki M, Inoue T; MELT Japan Study Group. Randomized trial of intraarterial infusion of urokinase within 6 hours of middle cerebral artery stroke: the middle cerebral artery embolism local fibrinolytic intervention trial (MELT) Japan. *Stroke*. 2007;38(10):2633–9. doi: 10.1161/STROKEAHA.107.488551. Epub 2007 Aug 16. PMID: 17702958.
  20. Khatri P, Yeatts SD, Mazighi M, et al. IMS III Trialists. Time to angiographic reperfusion and clinical outcome after acute ischaemic stroke: an analysis of data from the Interventional Management of Stroke (IMS III) phase 3 trial. *Lancet Neurol*. 2014; 13(6):567–574
  21. Kidwell CS, Jahan R, Gornbein J, et al. MR RESCUE Investigators. A trial of imaging selection and endovascular treatment for ischemic stroke. *N Engl J Med*. 2013; 368(10):914–923
  22. Broderick JP, Palesch YY, Demchuk AM, et al. Interventional Management of Stroke (IMS) III Investigators. Endovascular therapy after intravenous t-PA versus t-PA alone for stroke. *N Engl J Med*. 2013; 368(10):893–903
  23. Ciccone A, Valvassori L, Nichelatti M, et al. SYNTHESIS Expansion Investigators. Endovascular treatment for acute ischemic stroke. *N Engl J Med*. 2013; 368(10):904–913
  24. Jovin T, Chamorro A, Cobo E, Miquel M, Molina C, Rovira A. Thrombectomy within 8 hours after symptom onset in ischemic stroke (REVASCAT). *N Engl J Med*. 2015
  25. Fields JD, Lutsep HL, Smith WS, MERCI Multi MERCI Investigators. Higher degrees of recanalization after mechanical thrombectomy for acute stroke are associated with improved outcome and decreased mortality: pooled analysis of the MERCI and Multi MERCI trials. *AJNR Am J Neuroradiol*. 2011; 32 (11):2170–2174
  26. Goyal M, Menon BK, van Zwam WH, Dippel DW, Mitchell PJ, Demchuk AM, Dávalos A, Majoie CB, van der Lugt A, de Miquel MA, Donnan GA, Roos YB, Bonafe A, Jahan R, Diener HC, van den Berg LA, Levy EI, Berkhemer OA, Pereira VM, Rempel J, Millán M, Davis SM, Roy D, Thornton J, Román LS, Ribó M, Beumer D, Stouch B, Brown S, Campbell BC, van Oostenbrugge RJ, Saver JL, Hill MD, Jovin TG; HERMES collaborators. Endovascular thrombectomy after large-vessel ischaemic stroke: a meta-analysis of individual patient data from five randomised trials. *Lancet* 2016;387:1723–31. doi: 10.1016/S0140-6736(16)00163-X. Epub 2016 Feb 18. PMID: 26898852.
  27. Bam K, Olaiya M, Cadilhac D, Donnan G, Murphy L, Kilkeny MF. Enhancing primary stroke prevention. A combination approach. *The Lancet Public Health* 2022; 7: E721-4.
  28. White H.D., Simes R.J., Anderson N.E., Hankey G.J., Watson J.D., Hunt D., Colquhoun D.M., Glasziou P., MacMahon S., Kirby A.C., West M.J., Tonkin A.M. Pravastatin therapy and the risk of stroke. *N. Engl. J. Med*. 2000;**343**(5):317–326. doi: 10.1056/NEJM200008033430502.



29. Shepherd J, Blauw G.J., Murphy M.B., Bollen E.L., Buckley B.M., Cobbe S.M., Ford I., Gaw A., Hyland M., Jukema J.W., Kamper A.M., Macfarlane P.W., Meinders A.E., Norrie J., Packard C.J., Perry I.J., Stott D.J., Sweeney B.J., Twomey C., Westendorp R.G., PROSPER study group. PROspective Study of Pravastatin in the Elderly at Risk Pravastatin in elderly individuals at risk of vascular disease (PROSPER): a randomised controlled trial. *Lancet* 2002;**360**:1623–1630. doi: 10.1016/S0140-6736(02)11600-X.
30. Bornheim, Stephen Transcranial direct current stimulation associated with physical-therapy in acute stroke patients - A randomized, triple blind, sham-controlled study. <https://doi.org/10.1016/j.brs.2019.10.019>. 2020
31. Bustamante C, Brevis F, Canales S, Millón S, Pascual R Effect of functional electrical stimulation on the proprioception, motor function of the paretic upper limb, and patient quality of life: A case report.. *J Hand Ther* 2016;**29**:507–514. doi: 10.1016/j.jht.2016.06.012. Epub 2016 Sep 21. PMID: 27665394 Review.
32. Carrico C, Chelette KC, Westgate PM, Salmon-Powell E, Nichols L, Fleischer A, Sawaki L. Nerve stimulation enhances task-oriented training in chronic, severe motor deficit after stroke: A randomized trial. *Stroke* 2016; **47**, 1879–1884.
33. Carrico C, Chelette KC, Westgate PM, Salmon-Powell E, Nichols L, Sawaki L. A randomized trial of peripheral nerve stimulation to enhance modified constraint-induced therapy after stroke. *Am J Phys Med Rehabil* 2016;**95**:397–406. doi: 10.1097/PHM.0000000000000476.
34. Cordo P, Wolf S, Lou JS, Bogey R, Stevenson M, Hayes J, Roth E Treatment of severe hand impairment following stroke by combining assisted movement, muscle vibration, and biofeedback.. *J Neurol Phys Ther* 2013 **37**:194–203. doi: 10.1097/NPT.0000000000000023.
35. Cordo P, Lutsep H, Cordo L, Wright WG, Cacciatore T, Skoss R Assisted movement with enhanced sensation (AMES): coupling motor and sensory to remediate motor deficits in chronic stroke patients.. *Neurorehabil Neural Repair* 2009; **23**:67–77. doi: 10.1177/1545968308317437. Epub 2008 Jul 21.
36. Ghaziani E, Coupe C, Henkel C, Siersma V, Sondergaard M, Christensen H, Magnusson SP. Electrical somatosensory stimulation followed by motor training of the paretic upper limb in acute stroke: study protocol for a randomized controlled trial. *Trials* 2017; **18**:84-. <https://doi.org/10.1186/s13063-017-1815-9>
37. Lo AC, Guarino PD, Richards LG, Haselkorn JK, Wittenberg GF, Federman DG, Ringer RJ, Wagner TH, Krebs HI, Volpe BT, Bever C T Jr, Bravata DM, Duncan PW, Corn BH, Maffucci AD, Nadeau SE, Conroy SS, Powell JM, Huang GD, Peduzzi P. Robot-assisted therapy for long-term upper-limb impairment after stroke. *New England Journal of Medicine* 2010; **362**: 1772–1783.
38. Tosun A, Türe S, Askin A, Yardimci EU, Demirdal SU, Kurt Incesu T, Tosun O, Kocyigit H, Akhan G, Gelal FM. Effects of low-frequency repetitive transcranial magnetic stimulation and neuromuscular electrical stimulation on upper extremity motor recovery in the early period after stroke: a preliminary


- study..Top Stroke Rehabil 2017; 24:361–367. doi: 10.1080/10749357.2017.1305644. Epub 2017 Mar 22.
39. Veerbeek JM, Langbroek-Amersfoort AC, van Wegen EE, Meskers CG, Kwakkel G. Effects of Robot-Assisted Therapy for the Upper Limb After Stroke. *Neurorehabil Neural Repair* 2017; 31:107–121. doi: 10.1177/1545968316666957. Epub 2016 Sep 24.
  40. Kaelin-Lang A, Luft AR, Sawaki L, Burstein AH, Sohn YH, Cohen LG. Modulation of human corticomotor excitability by somatosensory input. *The Journal of Physiology* 2002; 540(2), 623–633.
  41. Hall KD, Lifschitz J. Diffuse traumatic brain injury initially attenuates and later expands activation of the rat somatosensory whisker circuit concomitant with neuroplastic responses. *Brain Res* 2010; 1323:161–173. <https://doi.org/10.1016/j.brainres.2010.01.067>
  42. Cunha BP, Alouche SR, Araujo SR, Freitas SM. Individuals with post-stroke hemiparesis are able to use additional sensory information to reduce postural sway. *Neurosci Lett* 2012; 513:6–11. <https://doi.org/10.1016/j.neulet.2012.01.053>
  43. Lakshminarayanan K, Lauer AW, Ramakrishnan V, Webster JG, Seo NJ. Application of vibration to wrist and hand skin affects fingertip tactile sensation. *Physiological Reports* 2015; 3 2015. Article e12465.
  44. Lew HL, Weihing J, Myers PJ, Pogoda TK, Goodrich GL. Dual sensory impairment (DSI) in traumatic brain injury (TBI)—An emerging interdisciplinary challenge. *Neurorehabilitation* 2010; 26:213–222. <https://doi.org/10.3233/nre-2010-0557>
  45. Serrada I, Hordacre B, Hillier SL. Does Sensory Retraining Improve Sensation and Sensorimotor Function Following Stroke: A Systematic Review and Meta-analysis. *Front Neurosci* 2019; 13:402–15. <https://pubmed.ncbi.nlm.nih.gov/31114472/>
  46. Zhou SA, Huang Y, Jiao J, Hu J, Hsing C, Lai Z, Yang Y, Hu X. Impairments of cortico-cortical connectivity in fine tactile sensation after stroke. *J Neuroeng Rehab* 2021; 18:34. [doi.org/10.1186/s12984-021-00821-7](https://doi.org/10.1186/s12984-021-00821-7)
  47. Hammond, C., Bergman, H., and Brown, P. (2007). Pathological synchronization in Parkinson's disease: networks, models and treatments. *Trends Neurosci.* 2007;30, 357–364. doi: 10.1016/j.tins.2007.05.004

## Table

**Table I.** Neurological Status at the time of enrollment, 7 days, and 30 days

<b>Patient Age, Sex</b>	<b>NIHSSS (0-7-30d)</b>	<b>Barthel (0-7-30d)</b>	<b>GOS (0-7-30d)</b>
65, M	15 - 8-5	7-14-17	4-4-5
73, F	12 - 6-3	8-16-18	4-4-5
61, M	11 - 4-3	10-15-16	4-5-5
59, M	12 - 10-9	8-12-12	4-4-4

## Figures



**Figure 1**

NeuroGlove device prototype used in this study consisting of a lucite chamber with multiple apertures connected via plastic hoses to an air pump to allow for air delivery to the volar surface of the forearm, palm, and fingers.

Fig. 2A

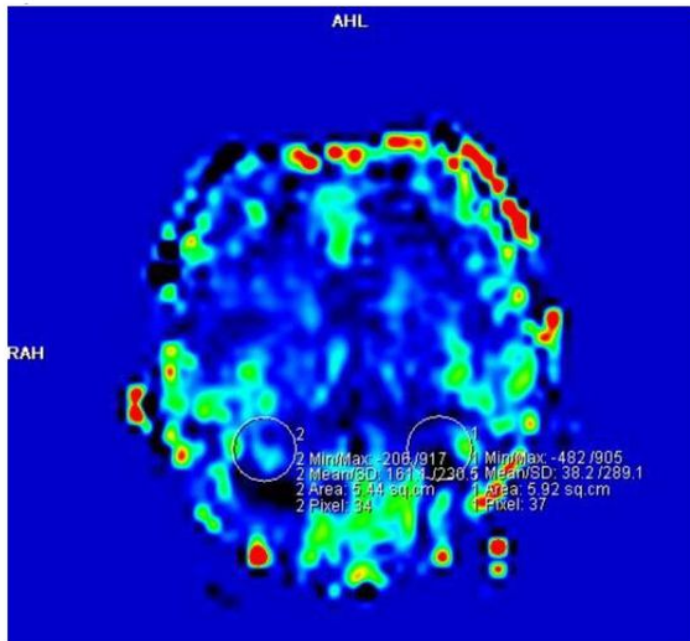
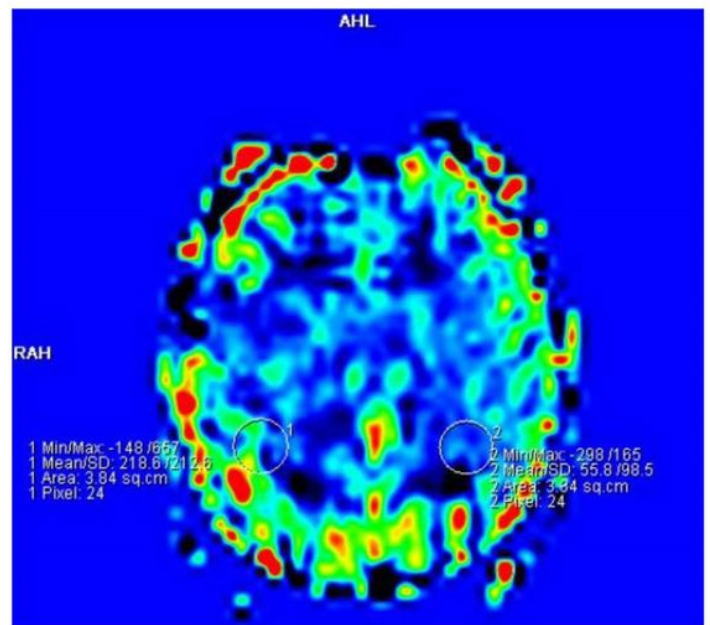


Fig. 2B



**Figure 2**

Axial perfusion MR images obtained before (a) and after (b) activation of the device in Patient 3 demonstrating qualitative improvement in CBF as shown by greater areas of yellow/red (after) as opposed to blue/green (before). This corresponded to an average increase in perfusion of 17%.