Coronavirus Disease 2019 (COVID-19) in Children: A Systematic Review of Imaging Findings

Susan C Shelmerdine (susan.shelmerdine@gosh.nhs.uk)
Great Ormond Street Hospital, London, UK

Jovan Lovrenski
Institute for Children and Adolescents Health Care of Vojvodina, Novi Sad, Serbia

Pablo Caro-Domínguez
Unidad de Radiología Pediátrica, Servicio de Radiodiagnóstico. Hospital Universitario Virgen del Rocío, Sevilla, Spain.

Seema Toso
Department of Diagnostics, Pediatric Radiology, Geneva Children's Hospitals, Geneva, Switzerland

Collaborators of the European Society of Paediatric Radiology cardiothoracic imaging taskforce
ESPR

Systematic Review

Keywords: Imaging, Radiology, Children, Coronavirus, Covid-19

Posted Date: April 9th, 2020

DOI: https://doi.org/10.21203/rs.3.rs-22081/v1

Abstract

Background:

Covid-19, a novel coronavirus infection which can cause a severe respiratory illness, has been declared a pandemic by the World Health Organisation (WHO). As children appear less severely affected than adults, their imaging appearances are not extensively reported.

Objectives:

To systematically review available literature regarding imaging findings in paediatric cases of Covid-19.

Materials and Methods:

Four databases (Medline, Embase, Cochrane, Google Scholar) were searched for articles describing imaging findings in children with Covid-19. All modalities, age <18 years and foreign language articles were included. Descriptive statistics were used to identify pattern, location of imaging findings and association with outcomes.

Results:

Twenty two articles were included, reporting chest imaging findings in 382 children, of which 372 (97.4%) underwent CT. Criteria for imaging was lacking. At diagnosis, 120/372 (32.3%) had a normal CT. Abnormalities were more common in the lower lobes and predominantly unilateral. The most common imaging pattern was ground glass opacification (136/246, 55.3%). None of the studies described lymphadenopathy, while pleural effusions (2/246, 0.8%) were rare. Improvement at follow-up CT imaging, (3 – 15 days later) was seen in 27/91 (29.7%), remained normal in 23/91 (25.3%) and progressed in 11/91 (12.1%).

Conclusions:

CT chest findings in children with Covid-19 are frequently normal or mild. Lower lobes are predominantly affected by patchy ground glass opacification. Appearances at follow-up remain normal or improve in the majority of children. Chest CT imaging adds little to the further management of the patient and should be reserved for severe cases or identifying alternative diagnoses.

This study was registered in PROSPERO, an international prospective register of systematic reviews (Registration ID: CRD42020175945

Introduction

A novel strain of coronavirus (referred to as 2019-nCoV or SARS-CoV-2), causing the sometimes severe respiratory infection Covid-19, was first identified in Wuhan city, China towards the end of 2019 [1]. By 12th March 2020, Covid-19 was declared a global pandemic by the World Health Organisation (WHO), and at the time of writing it has now spread to 177 countries, with almost 700,000 confirmed cases and claimed over 32,000 lives [2].

Epidemiological studies originating from China have shown that children are less likely to be clinically affected than the elderly, with one study finding only 0.9% of those infected aged <15 years old [3]. A different Chinese study which included 731 confirmed paediatric cases found that the majority (84.1%) suffered either mild or moderate symptoms, with <3% described as being severely or critically affected [4], and only one study has reported a death in a 10 month old with multiorgan failure [5]. Given the low number of paediatric cases, keeping abreast of the latest information and assimilating the combined knowledge of radiographic findings in infected children is challenging. Whilst several systematic reviews of imaging findings in Covid-19 cases have been performed for adult patients [6; 7], none have specifically focused on children.

The overall objective of this study was therefore to assimilate the available information on imaging features of Covid-19 disease in children. Particular points of interest include identification of typical imaging findings during diagnosis and follow-up stages of the infection, and whether any features may be used as prognostic markers to determine patient outcome.

Materials And Methods

Ethical approval was not required for this retrospective review of published data. In providing a clinical imaging example for this article, institutional ethical board approval was waived by our collaborators' host institutions and parental permission was obtained.

PRISMA (Preferred Reporting Items for Systematic reviews and Meta-Analyses) guidelines for transparent reporting of systematic reviews were followed. This study was registered in PROSPERO, an international prospective register of systematic reviews (Registration ID: CRD42020175945 [8]).

Literature Review

A systematic literature search was performed of MEDLINE (Ovid), EMBASE and the Cochrane Library databases for the latest articles published between 1 January 2015 and 17 March 2020 (5-year range), using database specific Boolean search strategies with key terms and word variations relating to all three categories:

- 'coronavirus', 'Covid-19', 'SARS-CoV-2' or '2019-nCoV';
- 'paediatrics', 'children', 'neonate', 'infant' or 'adolescent';
- 'radiology', 'imaging', 'ultrasound', 'CT', 'MRI' or 'radiography'

Full search terms are shown in the supplementary material (**Tables S1 – 3**). In order to include as many recent articles as possible, a grey literature search was also performed using the same keywords on Google Scholar and for any WHO Global Library publications. Additional articles were retrieved by manual screening of the reference lists of included studies and relevant review articles/editorial pieces. The initial search was conducted on 17 March 2020. A repeat search was conducted on 23 March 2020 for any further eligible manuscripts.

Eligibility Criteria

Inclusion criteria encompassed all studies investigating and describing imaging findings of confirmed Covid-19 infection in children, using reverse transcriptase polymerase chain reaction (RT-PCR) testing. Studies were limited to human subjects, including foetuses (any gestation) and children (ages 0- 18 years). No restrictions were placed on type of imaging modality, number of cases described or type of clinical setting. In order to widen our search and include as many cases as possible, case reports were considered eligible. No language restrictions were used given that many early articles on imaging findings have been published in Chinese.

Exclusion criteria included studies reported as editorials, opinion articles, multimedia files (online videos, podcasts). Suspected, but unconfirmed cases of Covid-19 were not included. Studies relating to other coronavirus-related illnesses, such as Middle East respiratory syndrome (MERS) or severe acute respiratory syndrome (SARS) were excluded. Any articles reporting on a mixed adult and paediatric cohort where imaging results for the paediatric cohort were not able to be extracted were also excluded.

Data extraction and Quantitative Data Synthesis

All articles were independently searched by two reviewers <BLINDED>. Abstracts of suitable studies were examined, and full papers were obtained according to the eligibility criteria. Disagreements were resolved by consensus.

The same two reviewers <BLINDED> independently extracted data from the full articles into a database (Excel, Microsoft, Redmond WA, USA) which included the following factors: study design, study setting/country, population demographics (e.g. gender, age, underlying co-morbidities), sample size, patient outcomes (number of mortalities), imaging modality and imaging findings (pattern and location of involvement of disease) and results of any follow-up imaging.

Missing data was recorded as 'not recorded' or 'not stated'. Authors of published studies were not contacted, due to the tight time constraints involved in the completion of the systematic review during the unprecedented time of need for this information.

Methodological Quality

The quality for each included study was assessed using the National Institutes of Health Quality Assessment Tool for Case Series Studies (https://www.nhlbi.nih.gov/health-topics/study-quality-assessment-tools) by two reviewers <BLINDED>. Disagreements were resolved by consensus review. Any that could not be resolved by consensus was arbitrated by a third reviewer <BLINDED>.

Statistical Analysis

A meta-analysis was planned to assess association of imaging findings with patient outcomes and demographic data, however this was omitted due to lack of sufficient data, in many cases being incompletely reported. Descriptive statistics were therefore used to determine frequency, percentages of imaging appearances across different articles.

Results

Included Studies

During the initial literature search, after removal of duplicates, we identified 146 unique records. After screening title/abstracts, we excluded 100 studies and checked 46 full-text articles (**Figure 1**). Reasons for exclusions included insufficient description regarding imaging results (n = 8), opinion pieces (n =7), adult population only (n =5), no confirmed (only suspected) Covid-19 cases (n =3), retracted article (n =2) and no full text available (n =1). After a second search of the databases, a further 3 records met our inclusion criteria and were added. We therefore analysed 22 studies overall in this systematic review (16 case series, 6 case reports), including 382 children (210 (54.9%) male) [5; 9-29]. Five (5/22, 22.7%) articles were in Chinese, the remainder in English. All articles were published in 2020, over a three month period from January to March.

Although it was not explicitly stated in the article, a small case series of 8 children [22] was felt strongly to represent a subset of a larger case series already published of 171 children with Covid-19 [5] (also included in our review). Both articles originated from Wuhan city, China. We have included both studies for completeness and made clear in our tables where we believe there might be an overlap of cases. The findings from the smaller case series have not been summated into our overall case numbers and results.

Methodological Quality

Methodological quality assessment of the studies are presented in **Table 1**. The majority of articles were given an overall scoring of 'Fair' (13/22, 59.1%), with 5/22 (22.7%) described as 'Good'. Despite several articles described as 'Poor' (4/22, 18.2%), none were excluded due to the desire to incorporate as much information on the available paediatric cases in the literature.

Patient Demographics

The demographics of the children and their presenting complaints are summarised in full in the supplementary material (**Table S4)**. All children were confirmed Covid-19 cases on RT-PCR testing. The studies mainly originated from China (20/22, 91%), with 1/22 (4.5%) from South Korea

[21] and 1/22 (4.5%) from Iran [29]. Of the Chinese studies, 7/22 (31.8%) described cases from Wuhan city [5; 12; 19; 22; 25-27]. The youngest child in our cohort was 36 hours old; the oldest was 17 years old.

Eighty-two (82/382, 21.5%) children were asymptomatic upon admission to hospital, being assessed due to having recent travel to a Covid-19 endemic area or close contact with an infected individual. Of those with symptoms, fever (108/300, 35.4%) and coughing (87/300, 29.0%) were the more common presenting complaints.

Imaging Modality & Parameters

The majority of the imaging modalities described in the studies were chest CT (21/22, 95.4%), of which only 1/21 (4.8%) utilised intravenous contrast for imaging [21]. In one study (1/22, 4.5%) only chest radiography findings were described [9]. In 8/22 (36.4%) studies a combination of both chest radiography and CT imaging findings were described [12; 21-23; 25; 27-29]. Two case reports also reported findings from abdominal ultrasound [12; 27], with one also describing normal head CT and echocardiography appearances [27]. None of the studies described MRI, nuclear medicine or chest ultrasound findings (See supplementary material for full details, **Table S5**).

In only 4/22 (18.1%) studies were the CT vendor and scanner model described [14; 18; 19; 26]. Of these 3 articles provided detailed imaging acquisition parameters [14; 18; 26]. One study did not report on the CT scanner model, but did report upon the imaging parameters[13]. Details on imaging protocols and parameters are provided in **Table 2**. In only 9/22 (40.9%) articles, a radiologist was identified as a co-author. Detailed indications for performing CT imaging were lacking in all studies.

Initial Imaging Findings

Where CT imaging was used, 120/372 (32.3%) cases did not have any radiographic findings despite being Covid-19 positive. In one study where only chest radiography was used, 6/10 (60%) of the imaged cases were normal [9]. In a case report from South Korea, the admission chest radiography was normal, although the CT demonstrated patchy nodular consolidation with ground glass opacification [21].

Throughout all studies, there were significant heterogeneities in terminologies used with reference to radiographic findings, many of which included well known terms (e.g. ground glass opacifications) as well as non-standard descriptive terminologies (e.g. “thickened lung texture” [25]). In addition, missing information regarding imaging findings made summarising these difficult. Despite this, summation of available findings has been provided in **Table 3 and 4**. It should be acknowledged that the percentage of cases for the various descriptors are less important than their relative frequencies to each other, given the missing information.

Localization

Lung pathology was identified in the upper lobe in 25/250 (10.0%), middle lobe in 12/250 (4.8%), and in the lower lobe of the lung in 44/250 (17.6%) patients. Diffuse/ multifocal disease was described in 4 patients (1.6%). In the remainder, an affected lobe or lobes were not stated (165/250, 66.0%).

Pathology was unilateral in 65/250 (26.0%) and bilateral in 52/250 patients (20.8%), and not commented in 133/250 (53.2%) of articles. Subpleural disease (i.e. peripheral in location) was described in 22/250 (8.8%) patients.

Patterns

The most characteristic pattern on CT were ground glass opacities, described in 136/246 (55.3%) patients (**Figure 2**). Patchy consolidations were seen in 7/246 (2.8%) patients. A so-called ‘halo sign’ (of ground glass opacification) around areas of consolidation was reported in

21/246 (8.5%) patients across three studies [14; 26; 29]. Non-specific terminologies of 'lung infiltrates/ shadows' were reported in 112/246 (45.5%) and interstitial lesions in 5/246 (2.0%) patients. Not all articles had case specific individual descriptions of CXR and CT, which were frequently described together.

There were several findings that were either not reported or only rarely reported. For example, none of the articles described significant mediastinal lymphadenopathy or cavitation on imaging, although there was only one study which performed a contrast enhanced CT. In only 2/246 (0.8%) children there were pleural effusions. Of these, one was a neonate also infected with respiratory syncytial virus (RSV) [18]. The underlying condition of the other case was not reported [19].

Follow-up Imaging Findings

In 14/22 (63.6%) studies, repeat imaging results were described, representing a total of 93 children (24.5%). In the majority of the studies (11/14 (78.6%)) this involved repeat CT imaging for 91 children (91/372, 24.4%). In 2/14 (14.3%) studies this was only done by chest radiography (for 2 children) and in 1/14 (7.1%) both chest radiography and CT appearances were reported (for 1 child).

When assessing changes in CT appearances after 3 – 15 days of admission, the majority of imaging studies remained normal (23/91, 25.3%) or showed some improvement of previously detected abnormalities (27/91, 29.7%). In a minority of cases the abnormalities had progressed (11/91, 12.1%) or new findings developed (4/91, 4.4%). Findings were stable in 16/91 (17.6%) cases, and a complete resolution of previous abnormalities was seen in 10/91 (10.9%) **(Table 5).**

For the two cases where only chest radiography follow-up was performed, the CXR either remained normal (n = 1) [21] or demonstrated mild progression with right upper and left lower lobe opacities (n = 1) [27]. In this latter case, the admission CT was reported to have demonstrated mild perihilar opacification bilaterally.

Imaging Findings and Demographic

Given the small number of cases and the heterogenous nature of case reporting, it was not possible to determine whether differences in imaging presentations varied significantly with patient age group, gender or presenting symptoms.

Given the lack of available RT-PCR testing kits available in many countries there has been interest in using CT to identify early pulmonary findings suggestive of Covid-19, particularly where patients are asymptomatic but at risk of disease due to infected co-habitants. In a subset of 20 children across 7 publications, it was possible to extract imaging findings from asymptomatic children (**Table S6**). Of these, 9/20 (45%) had normal CT findings, 7/20 (35%) reported the more typical pattern of ground glass opacification and 4/20 (20%) described non-specific, consolidative changes or 'patchy shadowing'.

Regarding differences with adults, Ma et al[19] found that their paediatric cohort (compared to a published adult cohort of 1099 cases [3]), were more likely to demonstrate abnormalities on chest CT (86% (43/50) vs 76% (840/1099)), although these were less likely to be bilateral (18% (9/50) vs 46% (505/1099)) and less likely to demonstrate interstitial abnormalities (6% (3/50) vs 13% (143/1099)). The presence of ground glass opacification (58% (29/50) vs 50% (550/1099)) and local patchy 'shadowing' (32% (16/50) vs 37% (409/1099)) were similar.

Patient Outcomes

At time of publication, 278/382 (72.8%) children had been discharged from hospital, 40/382 (10.4%) were in a stable condition in hospital, 3/382 (0.8%) had been admitted to intensive care units. One child admitted to intensive care reportedly later died at 4 weeks post hospital

admission; this was a 10 month old child with multiorgan failure, septic shock and intussusception [5]. The outcome of the remainder of cases is unclear from the published reports.

One study performed subgroup analysis to determine the relationship between patient outcomes and CT imaging results [19]. The authors reviewed a subset of 23/50 (46.0%) children in their cohort who had been discharged, symptoms resolved and had negative RT-PCR testing on two separate occasions. The majority of these children 17/23 (73.9%) still demonstrated lung abnormalities, in 2 cases these had progressed. A cox regression analysis did not find any statistically significant association between differences in imaging findings during treatment and likelihood of discharge. This was supported in part by findings by Xia et al [26] where the authors stated that CT findings appeared to lag behind resolution of clinical symptoms and two sets of negative nucleic acid testing.

Discussion

Chest CT imaging findings in children with Covid-19 are frequently normal or mild, with lower lobes most commonly affected demonstrating patchy ground glass opacification, or less frequently areas of consolidation. Imaging appearances at follow-up remain normal or improve in the majority.

These findings raise important clinical implications for paediatricians and radiologists. Given the mild and sometimes absent findings on CXR or CT, it is unlikely that imaging will provide an increased confidence in the diagnosis for Covid-19, nor can it provide reassurance for the absence of infection if imaging is normal. This finding is supported by a recent study of 24 asymptomatic carriers of Covid-19, of which 6 were children (5 – 15 years old), and all had normal chest CT findings [15]. Similar results have also been supported by work in adult patients [30; 31]. Whilst it is well known that CXR can underplay the chest CT findings, the identification of mild to moderate severity imaging appearances in the majority, with little subsequent change in management is unlikely to justify the CT imaging. Some experts believe that there may be a role in determining whether those deemed to be ‘super spreaders’ are more likely to have early CT changes and require a longer isolation period, however evidence here is currently lacking. Therefore, given the risk of disease transmission and additional radiation burden, CT imaging should not be routinely conducted for diagnosis, but rather reserved for those with severe or deteriorating symptoms, or in the search for an alternative diagnosis to aid management.

The fact that imaging appearances frequently resolve, improve or remain normal at follow-up imaging is reassuring as it suggests that long-term pulmonary damage is unlikely, although at present there is insufficient evidence to confirm this also. It is also important to bear in mind that the persistence of pulmonary findings does not necessarily imply ongoing infection, given that one study found persisting CT findings in 17/23 (73.9%) children who had been treated, with resolution of their symptoms and two negative RT-PCR tests. Therefore, follow-up CT imaging would also be better guided by clinical symptoms rather than being performed as a matter of routine.

It is worth noting that although our inclusion criteria was not set to review infected pregnant women, there was one case in this review of an infected newborn, diagnosed at 36 hours of age from a Covid-19 positive mother [25]. The authors had proposed the possibility for vertical transmission as a route of infection, however several subsequent articles reviewing outcomes of infected pregnant women have now suggested this to be unlikely [32-35]. A recently published rapid review of coronavirus in pregnancy [36] found that of the 32 infected women identified in the literature, there was 1 stillbirth (34 weeks gestation) and 15/32 (47%) pre-term deliveries. In 15/32 (47%) neonates which were tested for Covid-19, all were negative. The latest guidance from the Royal College of Obstetricians and Gynaecologists [37] has therefore recommended against routine separation of affected mothers and their babies, and has not found any evidence to suggest intrauterine fetal infection or teratogenic effects from the novel coronavirus. Clinicians should thus remain alert to alternative, more common diagnoses in newborns presenting with respiratory symptoms (e.g. respiratory distress syndrome, aspiration, pneumonia from alternative organisms), even if the mother is Covid-19 positive [35].

Although a comprehensive systematic review has been performed, there are still several gaps in our radiological knowledge regarding Covid-19 in children. In this article we include manuscripts relating to radiographic or CT appearances of lung pathologies in children, although information on other modalities are lacking. There is sparse literature on the use of point of care ultrasound (POCUS) for adult Covid-19 patients in Italy [38; 39] and one article describes POCUS as a replacement for the stethoscope in children [40]. In adults, POCUS has been

reportedly used to triage more severe cases for urgent management by helping to identify areas of ground glass opacification (so-called 'B lines') as well as areas of necrotic lung – a marker of the more advanced stages of infection [41]. Nevertheless, given that severe disease in children is less likely, the extent to which POCUS may be helpful is questionable, although it has been recommended as one of several potential options for lung assessment by a Chinese expert consensus review for neonatal management in Covid-19 [42]. Two adult publications have reported the use of FDG-PET/CT in Covid-19 [43; 44], and suggested that it could help monitor disease progression and treatment outcomes, particularly by detecting residual activity in mediastinal lymph nodes. This modality has not been reported in infected children so far, and adult studies have only included a small number of cases (4 patients or less). The added value is thus still undetermined [45], and should not be attempted in children particularly given the increased radiation burden.

Our review also did not find many articles reporting imaging findings in immunocompromised children and whether these features may differ from those without health conditions. It has been well documented that more severe infections are found in immunocompromised children with other strains of coronavirus [46] and may spread to other parts of the body, such as the brain causing encephalitis [47]. Whether this also occurs with Covid-19 remains to be seen. It is interesting that the only child death reported in this review was also suffering from an intussusception. Whether this was triggered by the underlying viral infection is unclear, but it is worth noting that gastrointestinal complaints can be the first and more prominent symptom of Covid-19 in some patients and has been reported in an adult series[48].

There are several limitations to this work. Given the widespread public health interest, several manuscripts on the topic of Covid-19 are emerging each week, many bypassing usual peer review processes. It is likely that some information may be missing but later included, or in certain cases articles retracted (as for two articles during our screening process). Nevertheless, where possible, we have tried to mitigate this by conducting our literature review twice in order to provide the most up-to-date information from reliable sources. Whilst not all imaging findings in all cases were reported in the studies, we described all available findings provided to give a general overview of the imaging pathology.

Secondly, due to the origin of the virus in China, some articles have been published in a language other than English, or in English by non-native speakers. This may have hampered our understanding and interpretation of the data, although we used online translation services where required. Whilst other systematic reviews on the topic of Covid-19 have excluded articles not written in English, we felt it was important to review as many foreign language articles where possible to increase our collective knowledge base, particularly given the few reported paediatric cases.

Finally, the majority of articles have included children from China, in particular Wuhan city. It is unclear whether some of these paediatric cohorts overlap, although we did identify two papers where there was clear similarity in many of the patients described, and avoided repetition of findings in summary results. It is also important to highlight that differences in indications for CT imaging in children may also exist (which could explain why Ma et al [19] found slightly more abnormalities on CT in children than adults), but unfortunately these indications were not made clear in the publications.

In conclusion, chest imaging findings in children with Covid-19 are frequently normal or mild, with unilateral changes that include patchy ground glass opacification, commonly affecting the lower lobes. Imaging appearances at follow-up frequently remain normal or improve in the majority of children. Chest CT imaging adds little to the further management of the patient and should be reserved for severe cases or in identifying alternative diagnoses. Further areas of research should include information on imaging and clinical characteristics in immunocompromised children with Covid-19, and information on long term follow-up, particularly in the more severely affected patients. We should therefore be prudent with the usage of CT, particularly at a time where resources are stretched, and only use in the more vulnerable populations.

References

1 Zhu N, Zhang D, Wang W et al (2020) A Novel Coronavirus from Patients with Pneumonia in China, 2019. N Engl J Med 382(8):727-733

2 Coronavirus COVID-19 Global Cases by Johns Hopkins Univeristy, Center for Systems Science and Engineering (CSSE). Available via https://gisanddata.maps.arcgis.com/apps/opsdashboard/index.html#/bda7594740fd40299423467b48e9ecf6. Accessed 29 March 2020

3 Guan WJ, Ni ZY, Hu Y et al (2020) Clinical Characteristics of Coronavirus Disease 2019 in China. N Engl J Med. Mar 27;382. https://doi.org/10.1056/NEJMoa2002032

4 Dong Y, Mo X, Hu Y et al (2020) Epidemiological Characteristics of 2143 Pediatric Patients With 2019 Coronavirus Disease in China. Pediatrics. https://doi.org/10.1542/peds.2020-0702

5 Lu X, Zhang L, Du H et al (2020) SARS-CoV-2 Infection in Children. N Engl J Med. https://doi.org/10.1056/NEJMc2005073

6 Fang Z, Yi F, Wu K et al (2020) Clinical Characteristics of 2019 Coronavirus Pneumonia (COVID-19): An Updated Systematic Review. medRxiv. https://doi.org/10.1101/2020.03.07.20032573

7 Rodriguez-Morales AJ, Cardona-Ospina JA, Gutiérrez-Ocampo E et al (2020) Clinical, laboratory and imaging features of COVID-19: A systematic review and meta-analysis. Travel Med Infect Dis. Mar 13:101623. https://doi.org/10.1016/j.tmaid.2020.101623

8 <BLINDED>

9 Cai J, Xu J, Lin D et al (2020) A Case Series of children with 2019 novel coronavirus infection: clinical and epidemiological features. Clin Infect Dis. https://doi.org/10.1093/cid/ciaa198

10 Chan JF, Yuan S, Kok KH et al (2020) A familial cluster of pneumonia associated with the 2019 novel coronavirus indicating person-to-person transmission: a study of a family cluster. Lancet Feb 15;395(10223):514-523

11 Chen C, Cao M, Peng L et al (2020) Coronavirus Disease-19 Among Children Outside Wuhan, China. Available at SSRN 3550012 via: https://papers.ssrn.com/sol3/papers.cfm?abstract_id=3546071&utm_source=EC&utm_medium=Connect. Accessed 17th March 2020

12 Chen F, Liu ZS, Zhang FR et al (2020) [First case of severe childhood novel coronavirus pneumonia in China]. Zhonghua Er Ke Za Zhi Mar 2;58(3):179-182.

13 Cui Y, Tian M, Huang D et al (2020) A 55-Day-Old Female Infant infected with COVID 19: presenting with pneumonia, liver injury, and heart damage. J Infect Dis. https://doi.org/10.1093/infdis/jiaa113

14 Feng K, Yun YX, Wang XF et al (2020) [Analysis of CT features of 15 Children with 2019 novel coronavirus infection]. Zhonghua Er Ke Za Zhi Feb 16;58(0):E007. https://doi.org/10.3760/cma.j.issn.0578-1310.2020.0007

15 Hu Z, Song C, Xu C et al (2020) Clinical characteristics of 24 asymptomatic infections with COVID-19 screened among close contacts in Nanjing, China. Sci China Life Sci. https://doi.org/10.1007/s11427-020-1661-4

16 Ji LN, Chao S, Wang YJ et al (2020) Clinical features of pediatric patients with COVID-19: a report of two family cluster cases. World J Pediatr. https://doi.org/10.1007/s12519-020-00356-2

17 Li W, Cui H, Li K, Fang Y, Li S (2020) Chest computed tomography in children with COVID-19 respiratory infection. Pediatr Radiol. https://doi.org/10.1007/s00247-020-04656-7

18 Liu H, Liu F, Li J, Zhang T, Wang D, Lan W (2020) Clinical and CT Imaging Features of the COVID-19 Pneumonia: Focus on Pregnant Women and Children. J Infect. https://doi.org/10.1016/j.jinf.2020.03.007

19 Ma H, Hu J, Tian J et al (2020) Visualizing the Novel Coronavirus (COVID-19) in Children: What We Learn from Patients at Wuhan Children's Hospital. Available at SSRN 3550012 via: https://papers.ssrn.com/sol3/papers.cfm?abstract_id=3550012. Accessed 17th March 2020

20 Pan X, Chen D, Xia Y et al (2020) Asymptomatic cases in a family cluster with SARS-CoV-2 infection. Lancet Infect Dis. https://doi.org/10.1016/s1473-3099(20)30114-6

21 Park JY, Han MS, Park KU, Kim JY, Choi EH (2020) First Pediatric Case of Coronavirus Disease 2019 in Korea. J Korean Med Sci 23;35(11):e124

22 Sun D, Li H, Lu XX et al (2020) Clinical features of severe pediatric patients with coronavirus disease 2019 in Wuhan: a single center's observational study. World J Pediatr. https://doi.org/10.1007/s12519-020-00354-4

23 Tang A, Xu W, Chen P, Li G, Liu Y, Liu L (2020) A retrospective study of the clinical characteristics of COVID-19 infection in 26 children. medRxiv https://doi.org/10.1101/2020.03/08.20029710

24 Wang D, Ju XL, Xie F et al (2020) [Clinical analysis of 31 cases of 2019 novel coronavirus infection in children from six provinces (autonomous region) of northern China]. Zhonghua Er Ke Za Zhi. Mar 2; 58(4):E011 https://doi.org/10.3760/cma.j.cn112140-20200225-00138

25 Wang S, Guo L, L. C et al (2020) A case report of neonatal COVID-19 infection in China. Clin Infect Dis. https://doi.org/10.1093/cid/ciaa225

26 Xia W, Shao J, Guo Y, Peng X, Li Z, Hu D (2020) Clinical and CT features in pediatric patients with COVID-19 infection: Different points from adults. Pediatr Pulmonol. https://doi.org/10.1002/ppul.24718

27 Zeng LK, Tao XW, Yuan WH, Wang J, Liu X, Liu ZS (2020) [First case of neonate infected with novel coronavirus pneumonia in China]. Zhonghua Er Ke Za Zhi Feb 17;58(0):E009. https://doi.org/10.3760/cma.j.issn.0578-1310.2020.0009

28 Zhang YH, Lin DJ, Xiao MF et al (2020) [2019 novel coronavirus infection in a three-month-old baby]. Zhonghua Er Ke Za Zhi. Feb 11;58(0):E006. https://doi.org/10.3760/cma.j.issn.0578-1310.2020.0006

29 Rahimzadeh G, Ekrami Noghabi M, Kadkhodaei Elyaderani F et al (2020) COVID-19 Infection in Iranian Children: A Case Series of 9 Patients. J Ped Review 8:139-144. https://doi.org/10.32598/jpr.8.2.139.

30 Bernheim A, Mei X, Huang M et al (2020) Chest CT Findings in Coronavirus Disease-19 (COVID-19): Relationship to Duration of Infection. Radiology. https://doi.org/10.1148/radiol.2020200463:200463

31 Chung M, Bernheim A, Mei X et al (2020) CT Imaging Features of 2019 Novel Coronavirus (2019-nCoV). Radiology Apr; 295(1):202-207

32 Liu D, Li L, Wu X et al (2020) Pregnancy and Perinatal Outcomes of Women With Coronavirus Disease (COVID-19) Pneumonia: A Preliminary Analysis. AJR Am J Roentgenol. https://doi.org/10.2214/ajr.20.23072:1-6

33 Chen H, Guo J, Wang C et al (2020) Clinical characteristics and intrauterine vertical transmission potential of COVID-19 infection in nine pregnant women: a retrospective review of medical records. Lancet 395:809-815

34 Liu W, Wang Q, Zhang Q et al (2020) Coronavirus Disease 2019 (COVID-19) During Pregnancy: A Case Series. Preprints, 2020020373. Available via: https://www.preprints.org/manuscript/202002.0373/v1. Accessed 17th March 2020

35 Zhu H, Wang L, Fang C et al (2020) Clinical analysis of 10 neonates born to mothers with 2019-nCoV pneumonia. Transl Pediatr. Feb;9(1):51-60

36 Mullins E, Evans D, Viner RM, O'Brien P, Morris E (2020) Coronavirus in pregnancy and delivery: rapid review. Ultrasound Obstet Gynecol. https://doi.org/10.1002/uog.22014

37 The Royal College of Gynaecologists (2020) Coronavirus (COVID-19) infection and pregnancy. Available via https://www.rcog.org.uk/globalassets/documents/guidelines/2020-03-21-covid19-pregnancy-guidance-2118.pdf. Accessed 23 March 2020

38 Buonsenso D, Piano A, Raffaelli F, Bonadia N, de Gaetano Donati K, Franceschi F (2020) Point-of-Care Lung Ultrasound findings in novel coronavirus disease-19 pnemoniae: a case report and potential applications during COVID-19 outbreak. Eur Rev Med Pharmacol Sci. Mar;24(5):2776-2780.

39 Soldati G, Smargiassi A, Inchingolo R et al (2020) Is there a role for lung ultrasound during the COVID-19 pandemic? J Ultrasound Med. https://doi.org/10.1002/jum.15284

40 Buonsenso D, Pata D, Chiaretti A (2020) COVID-19 outbreak: less stethoscope, more ultrasound. Lancet Respir Med. https://doi.org/10.1016/S2213-2600(20)30120-X

41 Xu YH, Dong JH, An WM et al (2020) Clinical and computed tomographic imaging features of novel coronavirus pneumonia caused by SARS-CoV-2. J Infect. Apr; 80(4):394-400. https://doi.org/10.1016/j.jinf.2020.02.017

42 Wang L, Shi Y, Xiao T et al (2020) Chinese expert consensus on the perinatal and neonatal management for the prevention and control of the 2019 novel coronavirus infection (First edition). Ann Transl Med. Feb;8(3):47. https://doi.org/10.21037/atm.2020.02.20

43 Qin C, Liu F, Yen TC, Lan X (2020) 18F-FDG PET/CT findings of COVID-19: a series of four highly suspected cases. Eur J Nucl Med Mol Imaging. https://doi.org/10.1007/s00259-020-04734-w

44 Zou S, Zhu X (2020) FDG PET/CT of COVID-19. Radiology. https://doi.org/10.1148/radiol.2020200770:200770

45 Deng Y, Lei L, Chen Y, Zhang W (2020) The potential added value of FDG PET/CT for COVID-19 pneumonia. Eur J Nucl Med Mol Imaging. https://doi.org/10.1007/s00259-020-04767-1

46 Ogimi C, Englund JA, Bradford MC, Qin X, Boeckh M, Waghmare A (2019) Characteristics and outcomes of coronavirus infection in children: the role of viral factors and an immunocompromised state. J Pediatric Infect Dis Soc. 28;8(1):21-28

47 Nilsson A, Edner N, Albert J, Ternhag A (2020) Fatal encephalitis associated with coronavirus OC43 in an immunocompromised child. Infect Dis (Lond). https://doi.org/10.1080/23744235.2020.1729403:1-4

48 Gu J, Han B, Wang J (2020) COVID-19: Gastrointestinal manifestations and potential fecal-oral transmission. Gastroenterology. https://doi.org/10.1053/j.gastro.2020.02.054

Declarations

Funding information:

SCS is supported by a RCUK/ UKRI Innovation Fellowship and Medical Research Council (MRC) Clinical Research Training Fellowship (Grant Ref: MR/R002118/1). This award is jointly funded by the Royal College of Radiologists (RCR).

This article presents independent research funded by the MRC, RCR and the views expressed are those of the author(s) and not necessarily those of the NHS, MRC, RCR or the Department of Health.

Conflicts of interest:

None of the authors have conflicts to declare.

Availability of data and material:

All relevant clinical information is already provided within the manuscript. Additional information is available from the corresponding author upon reasonable request.

Code availability:

Not applicable

Ethics approval:

Ethical approval for the systematic review was not required due to retrospective review of publicly available, published data. For the clinical images demonstrating Covid-19 infection in children, institutional ethical board approval was waived by our collaborators' host institutions and parental permission was obtained to use the imaging.

Consent to participate and publication:

Not required due to retrospective review of publicly available, published data.

Authors' contributions:

All authors listed in this manuscript fulfil the ICMJE recommendations for authorship. SCS, ST, JL performed the data collection, analysis and primary write up of the manuscript. PCD, SCS conceived the idea of the research project. All authors have had an input in reviewing and editing the final draft of this manuscript.

Acknowledgements:

We would also like to thank all collaborator colleagues from the European Society of Paediatric Radiology (ESPR), Society of Pediatric Radiology (SPR) and Asian and Oceanic Society for Pediatric Radiology (AOSPR) for their help in reviewing and supporting this article.

Tables

Table 1: Quality Ratings of Included Studies According to NIH Quality Assessment Tool for Case Series Studies

The NIH Quality Assessment Tool for Case Series Studies questions include the following: nine questions: 1 = Was the study question or objective clearly stated?, 2 = Was the study population clearly and fully described, including a case definition?, 3 = Were the cases consecutive?, 4 = Were the subjects comparable?, 5 = Was the intervention (i.e. imaging modality) clearly described?, 6 = Were the outcome measures clearly defined, valid, reliable, and implemented consistently across all study participants?, 7 = Was the length of follow-up adequate?, 8 = Were the statistical methods well-described?, 9 = Were the results well-described? NIH = National Institutes of Health, Y = yes, N = no, NR = not reported, CD = cannot determine, NA = not applicable.

First Author	Question									Overall Rating		Final Consensus
	1	2	3	4	5	6	7	8	9	Reviewer 1	Reviewer 2	
Cai J et al. [9]	N	Y	N	CD	NA	Y	CD	NA	Y	Fair	Poor	Fair
Chan JF et al. [10]	Y	Y	NR	CD	NA	Y	CD	NA	Y	Fair	Fair	Fair
Chen C et al. [11]	Y	Y	NR	NA	N	Y	N	Y	Y	Fair	Fair	Fair
Chen F et al. [12]	N	NA	NA	NA	N	Y	CD	NA	N	Fair	Poor	Poor
Cui Y et al. [13]	Y	NA	NA	CD	Y	Y	Y	NA	Y	Good	Good	Good
Feng K et al. [14]	Y	Y	NR	CD	Y	Y	Y	N	Y	Fair	Fair	Fair
Hu Z et al. [15]	Y	Y	NR	CD	N	Y	Y	Y	Y	Fair	Good	Fair
Ji LN et al. [16]	Y	Y	NR	CD	N	Y	CD	NA	Y	Fair	Good	Fair
Li W et al. [17]	Y	Y	NR	CD	N	Y	Y	NA	Y	Fair	Good	Fair
Liu H et al. [18]	Y	Y	NR	Y	Y	Y	N	Y	Y	Good	Good	Good
Lu X et al. [5]	Y	Y	NR	CD	N	Y	N	N	Y	Fair	Good	Fair
Ma H et al. [19]	Y	Y	NR	CD	Y	Y	Y	Y	Y	Good	Good	Good
Pan X et al. [20]	N	Y	NA	CD	N	NA	N	NA	Y	Fair	Poor	Fair
Park JY et al. [21]	Y	NA	NA	NA	N	Y	N	NA	Y	Fair	Fair	Fair
Rahimzadeh G et al. [29]	N	Y	NR	CD	Y	Y	Y	N	Y	Fair	Fair	Fair
Sun D et al. [22]	Y	Y	NR	CD	N	Y	N	NA	Y	Fair	Good	Fair
Tang A et al. [23]	Y	Y	NR	CD	N	Y	CD	Y	Y	Fair	Fair	Fair
Wang D et al. [24]	Y	Y	NR	CD	N	Y	CD	N	N	Fair	Poor	Poor
Wang S et al. [25]	Y	NA	NA	NA	N	Y	Y	NA	Y	Good	Good	Good
Xia W et al. [26]	Y	Y	NR	CD	Y	Y	Y	N	Y	Good	Good	Good
Zeng LK et al. [27]	N	NA	NA	NA	N	Y	CD	NA	N	Fair	Poor	Poor
Zhang Y et al. [28]	N	NA	NA	NA	N	Y	Y	NA	N	Poor	Poor	Poor

Table 2: Details of CT imaging protocols/parameters used in children in this systematic review.

Articles describing or using only chest radiography have been excluded from this table. Where the usage of intravenous contrast agent for CT imaging is not described, this was inferred from imaging included as figures from the manuscript. Given wide differences in availability of reported CT imaging parameters, the full descriptions as stated in the article are listed here. NS – not stated; N – no; Y – yes; U – uncertain; FOV – field of view; MDCT – multidetector computed tomography

Author [Reference]	Radiologist co-author	CT vendor	CT Model	Intravenous Contrast	Parameters
Chan JF et al. [10]	N	NS	NS	N	NS
Chen C et al. [11]	N	NS	NS	N	NS
Chen F et al. [12]	N	NS	NS	N	NS
Cui Y et al. [13]	N	NS	NS	N	80kV, automatic tube current (23-26mAs).
Feng K et al. [14]	Y	Toshiba	TSX-101A	N	64 slice MDCT. 136kV, automatic tube current (unspecified). Matrix 612 x 612, FOV 320 x 320mm. Slice thickness 6mm. Slice interval 1mm. Pitch 0.8. Reconstruction performed with lung window algorithm.
Hu Z et al. [15]	Y	NS	NS	N	NS
Ji LN et al. [16]	N	NS	NS	N	NS
Li W et al. [17]	Y	NS	NS	N	NS
Liu H et al. [18]	Y	GE	Optima 660	N	64 slice MDCT. 100kV, automatic tube current (30-100mA) Slice thickness 3-5mm. Slice interval 1mm. Rotation speed 0.6s. Pitch 0.969:1. Reconstruction of images at 0.625 to 1mm thickness with lung window algorithm
Lu X et al.[5]	U	NS	NS	NS	NS
Ma H et al. [19]	Y	Siemens GE	SOMATOM Definition AS128 Optima 660	N	Slice thickness 0.625mm.
Pan X et al. [20]	Y	NS	NS	NS	NS
Park JY et al. [21]	Y	NS	NS	Y	NS
Rahimzadeh G et al. [29]	N	NS	NS	N	NS
Sun D et al. [22]	N	NS	NS	N	NS
Tang A et al. [23]	N	NS	NS	NS	NS
Wang D et al. [24]	N	NS	NS	N	NS
Wang S et al. [25]	N	NS	NS	N	NS
Xia W et al. [26]	Y	Siemens	SOMATOM Definition AS128	N	120kV, automatic tube current (100 to 150 mA) Collimation 0.6-mm. Pitch 1:1 CT images were reconstructed with 1.25-mm collimation with lung window algorithms
Zeng LK et al. [27]	N	NS	NS	N	NS
Zhang Y et al. [28]	Y	NS	NS	N	NS

Table 3: Summarised Initial Imaging Characteristics of Children with Covid-19

The findings below correspond to readily available reported imaging findings within the relevant publications. Only Covid-19 confirmed cases by RT-PCR are included. Due to the heterogenous, and occasionally incomplete reporting of these findings (e.g. some without pathology location, some using different terminologies), not all features will be mutually exclusive, nor total to the combined number of patients. *UL –upper lobe, ML –middle lobe, LL –lower lobe, CXR – chest radiograph, CT – computed tomography*

Author [Reference]	Sample Size	Imaging Modality	Abnormalities		Lobe Affected				Laterality		Segments		Subpleural
			None	Present	UL	ML/ Lingula/ Hilar	LL	Mulitlobar/ Diffuse	Unilateral	Bilateral	One	Two	
Cai J et al. [9]	10	CXR	6	4					4				
Chan JF et al. [10]	1	Chest CT	0	1									
Chen C et al. [11]	31	Chest CT	20	11					8	3			
Chen F et al. [12]	1	CXR, Chest CT	0	1					1				
Cui Y et al. [13]	1	Chest CT	0	1	1		1		1				
Feng K et al. [14]	15	Chest CT	6	9				1			4	4	
Hu Z et al. [15]	6	Chest CT	4	2			1		1				1
Ji LN et al. [16]	2	Chest CT	2	0									
Li W et al. [17]	5	Chest CT	2	3	1		2						
Liu H et al. [18]	4	Chest CT	1	3		1	1	1					
Lu X et al. [5]	171	Chest CT	60	111					32	21			
Ma H et al. [19]	50	Chest CT	0	50	22	9	28			9			
Pan X et al. [20]	1	Chest CT	1	0									
Park JY et al. [21]	1	CXR Chest CT	0	1			1		1				1
Rahimzadeh G. et al [29]	3	CXR Chest CT	1	2				2		2			
Tang A et al. [23]	26	CXR Chest CT	8	18					11	7			11
Wang D et al. [24]	31	Chest CT	16	14			9						9
Wang S et al. [25]	1	CXR Chest CT	0	1	1								
Xia W et al. [26]	20	Chest CT	4	16					6	10			
Zeng LK et al. [27]	1	CXR Chest CT	0	1		1							
Zhang Y et al. [28]	1	CXR Chest CT	0	1		1	1						
Total	**382**		**131 (34.3%)**	**250 (65.4%)**	**25 (10.0%)**	**12 (4.8%)**	**44 (17.6%)**	**4 (1.6%)**	**65 (26.0%)**	**52 (20.8%)**	**4 (1.6%)**	**4 (1.6%)**	**22 (8.8%)**

Table 4: Patterns of Imaging Findings on Initial CT Study in Children with Covid-19

Descriptors refer to those stated within the relevant publications. Due to the heterogenous, non-standard terminologies, we have included descriptions of ‘shadows/infiltrates’ together and interpret these to mean non-specific opacities. In many articles, there was incomplete reporting of findings, therefore not all features will be mutually exclusive, nor total to the combined number of patients within the study. The relative frequencies are thus more important an indicator than the absolute numbers summated.

CT – computed tomography, GGO – ground glass opacification,

Author	Abnormal CT (n)	GGO	Consolidation	"Halo Sign"	Pulmonary "Infiltrates/ Shadows"	Interstitial lesions	Nodular appearances	Pleural Effusion
Chan JF et al. [10]	1	1						
Chen C et al. [11]	11	4						
Chen F et al. [12]	1				1			
Cui Y et al. [13]	1	1						
Feng K et al. [14]	9	9		9	9			
Hu Z et al. [15]	2	2			1			
Li W et al. [17]	3	3						
Liu H et al. [18]	3	1	2					1
Lu X et al. [5]	111	56			53	2		
Ma H et al. [19]	50	29			25	3		1
Park JY et al. [21]	1	1	1					
Rahimzadeh G et al. [29]	2	2	2	2				
Tang A et al. [23]	18				18			
Wang D et al. [24]	14	9						
Wang S et al. [25]	1	1			1			
Xia W et al. [26]	16	16	1	10	4		3	
Zeng LK et al. [27]	1		1					
Zhang Y et al. [28]	1	1					1	
Total	**246**	**136 (55.3%)**	**7 (2.8%)**	**21 (8.5%)**	**112 (45.5%)**	**5 (2.0%)**	**4 (1.6%)**	**2 (0.8%)**

Table 5: Follow-up CT Imaging Findings in Children with Covid-19

Only articles detailing follow-up CT imaging are included in this table. The findings correspond to readily available reported findings within the relevant publications. *NS = not stated.*

Author	Cases with follow-up imaging	Timing post admission (days)	Remained normal	Complete Resolution of abnormalities	Improving abnormalities	Abnormalities unchanged	New abnormalities (previously normal)	Progressive changes
Chen C et al. [11]	28	NS	19			7	1	1
Chen F et al. [12]	1	11			1			
Cui Y et al. [13]	1	11d			1			
Feng K et al. [14]	15	3-5	3	2		7	3	
Hu Z et al. [15]	1	13		1				
Li W et al. [17]	3	5-7		3				
Liu H et al. [18]	3	7	1		2			
Ma H et al. [19]	29	NS		2	17	2		8
Wang D et al. [24]	2	9-10			1			1
Wang S et al. [25]	1	15			1			
Xia W et al. [26]	6	NS		2	4			
Zhang Y et al. [28]	1	3						1
Total	**91**	**3 – 15**	**23 (25.3%)**	**10 (10.9%)**	**27 (29.7%)**	**16 (17.6%)**	**4 (4.4%)**	**11 (12.1%)**

Figures

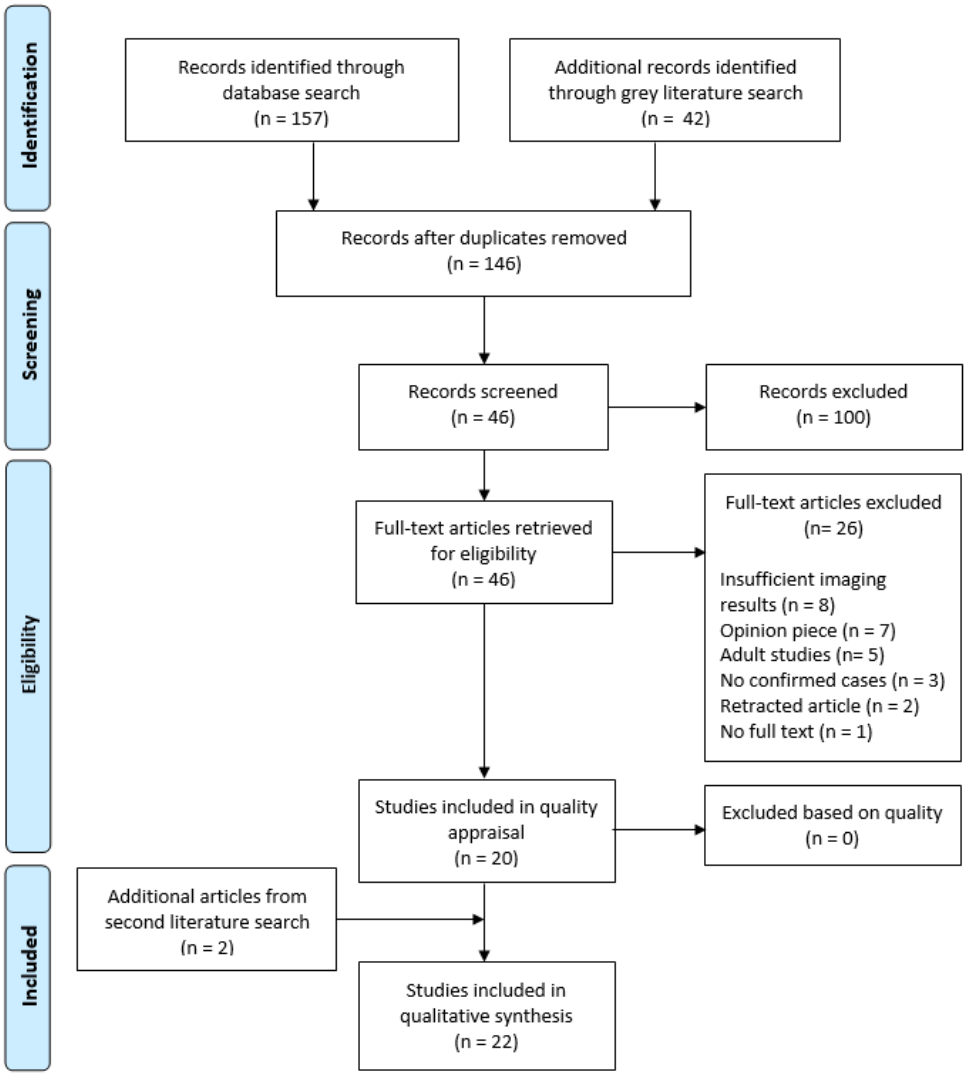

Figure 1

PRISMA flowchart for study search and selection

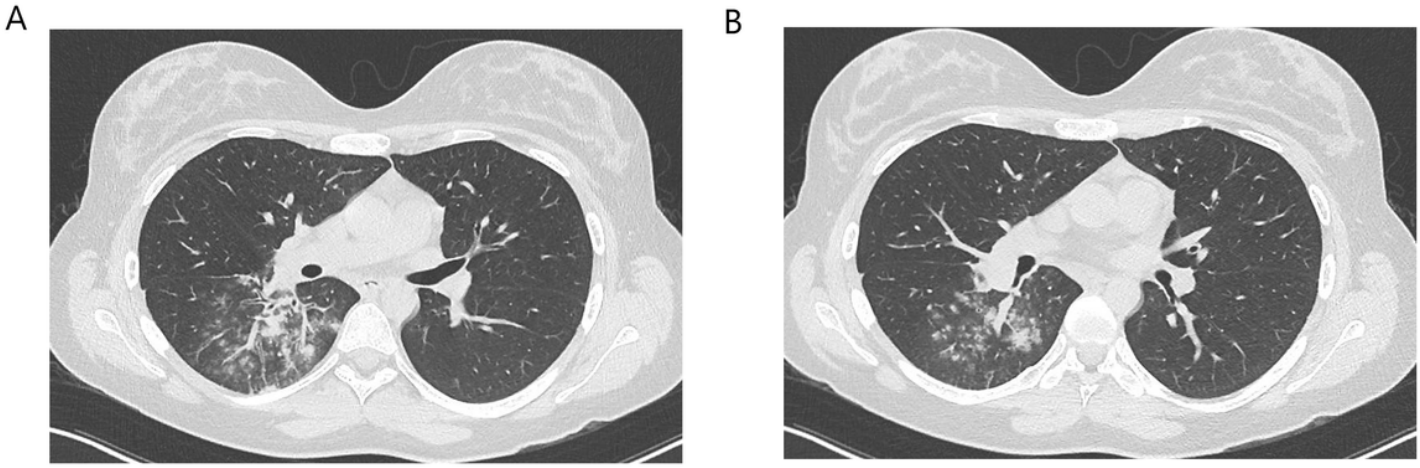

Figure 2

Chest CT of a 17-year-old female with Covid-19, who presented to hospital with a 2 day history of fever and cough. There was a family history of one parent also having Covid-19. a) b) Axial, unenhanced imaging, using lung window reconstruction, demonstrate patchy ground glass change with nodular consolidative appearances in the right lower lobe. There is also mild bronchial wall thickening. The patient was hospitalised for 6 days and made a full recovery prior to discharge.

Supplementary Files

This is a list of supplementary files associated with this preprint. Click to download.

- 004.SupplementaryMaterial.doc
- 005.PRISMAchecklistCovid19.doc