A biomechanics study about the mechanism of ligaments injury in anterior posterior compression type Ⅱ pelvic injury

Jianzhong kong
Nanjing Medical University Second Affiliated Hospital
Yupeng Chu
The Central Hospital of Wenzhou
Chengwei Zhou
The Second Affiliated Hospital and Yuying Children's Hospital of Wenzhou Medical University
Shuaibo Sun
The Second Affiliated Hospital and Yuying Children's Hospital of Wenzhou Medical University
Guodong Bao
The Second Affiliated Hospital and Yuying Children's Hospital of Wenzhou Medical University
Yu Xu
The Second Affiliated Hospital and Yuying Children's Hospital of Wenzhou Medcial University
xiaoshan Guo
The Second Affiliated Hospital and Yuying Children's Hospital of Wenzhou Medical University
xiaolong Shui (sxl202144@163.com)
The Second Affiliated Hospital and Yuying Children's Hospital of Wenzhou Medical University

---

Research article

Keywords: anterior and posterior compression (APC) pelvis fracture, pelvic injury, ligaments injury

Posted Date: April 20th, 2020

DOI: https://doi.org/10.21203/rs.3.rs-22184/v1

Abstract

Background

The anterior and posterior compression (APC) pelvis fracture is a classic pelvic injury, and APC type II is considered to be a typical one caused by the destruction of pelvic ligaments, while the mechanism of ligaments injury and treatment of which is still controversial. This study aims to explore ligaments injury in anterior posterior compression(APC)type II pelvic injury.

Method:

Fourteen human cadaveric pelvis samples (5 female, 9 male) with the sacrospinous, sacrotuberous, anterior sacroiliac ligaments and partial bone retaining unilaterally were made for this study. To simulate the APC pattern pelvic injury, the samples were divided into two groups randomly, set one group as hemipelvis restricted group (experimental group) and the other one as unrestricted group (control group). According to the biomechanical data, eye observation, motion capture system and real-time video system to record the separation distance of the pubic symphysis and anterior sacroiliac joint, external rotation angle and force when the anterior sacroiliac ligament ruptured. Continuing the external rotation violence, observing the bone and posterior ligaments change since sacrospinous and sacrotuberous ligaments from being damaged to completely ruptured.

Result

When anterior sacroiliac ligament failed, the mean separation distance of pubic symphysis and anterior sacroiliac joint between restricted group and unrestricted group was 28.6 ± 8.4 mm to 23.6 ± 8.2 mm($P = 0.11$) and 11.4 ± 3.8 mm to 9.7 ± 3.9 mm ($P = 0.30$) respectively. In addition, the external rotation angle and force was 33.9 ± 5.5° to 48.9 ± 5.2°($P < 0.01$) and 553.9 ± 82.6 N to 756.6 ± 41.4 N ($P < 0.01$) respectively. The two distances were not significantly different ($P > 0.05$), however, the external rotation angle and violence was significantly different ($P < 0.05$), which was bigger in the unrestricted group. In the unrestricted group, when anterior sacroiliac ligament ruptured, no distinct sacrospinous or sacrotuberous ligaments injury was observed, but in the restricted group, all of samples had two ligaments injury and even two samples had ligaments failed. Moreover, with the extreme external rotation violence continuing, there was still no sacrospinous or sacrotuberous ligaments injury in the unrestricted group. But interosseous sacroiliac ligament, posterior sacroiliac ligaments injury and slight sagittal rotation and sacroiliac joint displacement appeared. In the control group, the sacrospinous ligament ruptured firstly and then the sacrotuberous ligament ruptured. When both of the two ligaments failed, the interosseous sacroiliac ligament was damaged while posterior ligament was not. In the restricted group, when all of the anterior sacroiliac ligament, sacrospinous ligament or sacrotuberous ligament failed, mean separation distance of pubic symphysis and anterior sacroiliac joint increased significantly (from 28.6 ± 8.4 to 42.0 ± 7.6 mm, 11.4 ± 3.8 to 16.7 ± 4.2 mm respectively, all $P < 0.05$).

Conclusion

We have three main findings: First, pelvic external rotation injury can divide into two situations: hemipelvis is restricted and unrestricted, which result into two different outcomes. When anterior sacroiliac ligament rupture, the unrestricted group needs more external rotation angle and force, without obvious sacrotuberous or sacrospinous ligaments injury. But in the restricted group, both of two ligaments injury appear. Second, when anterior sacroiliac ligament fail, pubic symphysis displacement ranges from 14 to 40 mm, which has a high fluctuation. Third, when the anterior sacroiliac ligament is damaged, we dose not observe the inevitable destruction of the pelvic floor ligaments (sacrospinous ligament and sacrotubercular ligament).

Introduction

Fractures of the pelvic ring are frequently seen, especially in polytrauma patients or geriatric patients with poor bone quality [1–3]. The anterior and posterior compression (APC) pelvic injury, which is a classic type, also known as the external rotation injury, is considered to be a typical one caused by the destruction of pelvic ligaments. On basisi of the anatomical and biomechanical research, the anterior structures, including the pubic symphysis and the pubic rami, contribute approximately 40% to the stability of the pelvis. The remaining 60% of the stability of the pelvis is support with the posterior structures, including the sacroiliac joint [4]. APC type Ⅱ fracture is the intermediate type between stable and unstable external rotation pelvic fracture, the mechanism of ligaments injury of which is still controversial [5, 6]. Thus, the injury mechanism and classification of APC type II need to be further refined, which is significant and representative. For this purpose, we conducted a specific biomechanical test about the pelvic external rotation injury (APC type II pelvis fracture), to explore ligaments injury and the separation distance of the pubic symphysis and sacroiliac joint when anterior sacroiliac ligament ruptured. When all of anterior sacroiliac ligament, sacrotuberous and sacrospinous ligament failed, observing the injury of the anterior and posterior pelvic rings as well.

Material And Method

1.Experimental materials

1.1 Main experimental instruments

ElectroForCeR 3510 biomechanical testing machine (Bose company, USA,Fig. 1a); WinTest control software, which is used for controlling testing machine and collecting high-precision data; Motion dynamic motion capture system, which can capture pelvis rotation accurately; Real time video system; Portable C-arm fluoroscopy and X-ray machine (provided by biomechanics laboratory, anatomy teaching and research department, Wenzhou Medical University); Vernier caliper; Pelvic embedded fixator; electric drill and Kirschner wires, hacksaw, scalpel, bone rongeur, periosteal stripper, vise, protractor, etc.

1.2 Main experimental reagents

Embedded specimens of denture powder (PMMA, type II) and denture water (Shanghai coral chemical plant).The volume ratio of powder and water is 2:1, 30 minutes at room temperature.

1.3 Experiment specimens

Inclusion criteria: (1) specimens were more than 18 years old; (2) specimens were not associated with pelvic tumor, previous fracture or sacroiliac joint fusion; (3) By naked eye and X-ray plain film observation, specimens were bilateral symmetry. Consequently, fourteen fresh adult cadaver specimens without anticorrosive treatment were collected for this study (5 females and 9 males, all specimens are from the Department of human anatomy, Wenzhou Medical University). We amputated Waist 5 and symphysis pubis, leaving the complete pelvic part retaining, including bone and ligaments (mainly include pubic symphysis ligament, sacrospinous ligament, sacrotuberous ligament, anterior and posterior sacroiliac ligaments and sacroiliac interosseous ligament), then they were numbered 1–14. The specimens were soaked in normal saline, sealed and wrapped in double-layer plastic bags to prevent drying and dehydration when they were not used. They were cryopreserved at − 20 ℃ and ablated at room temperature 12 hours before the experiment. (Table 1, Fig. 1)

Table 1
Characteristics of the specimens and grouping result

Number	Female	Age	Seperation distance of Symphysis pubis (mm)	Seperation distance of Sacroiliac joint (mm)	Time from anatomy to experiment (day)	Group	Rotation side
1	F	29	3.7	0.5	5	R	L
2	M	36	5.9	0.6	5	UR	R
3	M	48	4.7	0.5	4	R	L
4	F	52	3.0	0.4	4	UR	R
5	F	53	4.5	0.3	3	R	L
6	M	56	4.8	0.7	6	UR	R
7	M	37	4.9	0.5	4	R	L
8	M	45	6.0	0.6	3	UR	R
9	M	40	4.7	0.4	5	R	L
10	M	55	5.6	0.3	5	UR	R
11	F	60	3.5	0.8	4	R	L
12	M	39	4.2	0.5	6	UR	R
13	F	37	4.8	1.0	5	R	L
14	M	58	3.8	0.8	6	UR	R

F = female, M = male; R = restricted group, UR = unrestricted group; L = left, R = right.

Table 2
When anterior sacroiliac ligament rupture, comparison of mean data about relevant variables between two groups

Variable	Restricted group	Unrestricted group	T	*P* value
Seperation distance of symphysis pubis(mm)	28.6 ± 8.4	23.6 ± 8.2	1.871	0.11
Seperation distance of anterior sacroiliac joint (mm)	11.4 ± 3.8	9.7 ± 3.9	1.137	0.30
External Rotation Angle (°)	33.9 ± 5.5	48.9 ± 5.2	-5.79	< 0.01
External Rotation Force(N)	553.9 ± 82.6	756.6 ± 41.4	-6.125	< 0.01

2. Experiment Method

The exact mechanism of pelvic external rotation injury in vivo was not clear, and the specific steps of original Tile test was also not clear. Therefore, we randomly divided the specimens into two groups, and made two kinds of pelvic external rotation injury test models. One group was the hemi-pelvic restricted group (1, 3, 5, 7, 9,11,13), the other one was the unrestricted group (2, 4, 6, 8, 10,12,14). In both of two groups, 3–4 steel K-wires with diameter of 1 cm were inserted into the pelvis from the middle of the fifth lumbar vertebrae to the center of the sacrum, leaving about 5 cm longer than the fifth lumbar, and then the pelvis was embedded with fixator, so that it could be fixed on the biomechanical machine, and the biomechanical machine could rotate the sacroiliac joint to back direction of the test side, simulating the external rotation of the lateral pelvis. For figuring out the separation distance of pubic symphysis when anterior sacroiliac ligament ruptured, a 0.3 cm steel plate was inserted into pubic symphysis to maintain a 0.3 cm reference separation point and calculate for separation distance. The plate was fixed on the base of the test machine, in the restricted group, two screws were fixed on the pelvic acetabulum test side, which restricted other directions movement expect internal and external rotation. But the unrestricted group did not fix with screws, which allowed vertical and sagittal movements (Fig. 2). The former group provided with an pure external rotation mode, while the latter group provided with a composite model (external rotation with flexion and extension displacement). As it was not clear which model was closer to the typical injury, we tested both of two models. In order to exclude the difference between the left and right sides, we also randomly selected half of the specimens to external rotate on the right side and the rest on left side. Each pelvic specimen was designed with one side of the sacroiliac joint was restricted and the other side was unrestricted. Then we simulated APC injury mode, set the sacrum as the center and 250 nm as the maximum possible, and performed a pure external rotation of 2°/s. The rotational shift was measured with a rotary variable difference converter. The biomechanical machine recorded angular displacement at each torque and form a torque curve. When this curve slipped sharply and suddenly, which meant anterior sacroiliac ligament ruptured or deformed seriously. At this point, we observed whether sacrospinous and sacrotuberous ligaments were damaged or not by visual inspection and video system, and measured separation distances of pubic symphysis and anterior sacroiliac joint accurately. Continue to external rotate the hemipelvis until both of the sacrospinous ligament and sacrotuberous ligament failed. At this moment, observing the pelvic bone change (the separation of pubic symphysis and anterior sacroiliac joint) and posterior ligaments (including interosseous sacroiliac ligament and posterior sacroiliac ligament). Besides, pelvic X-ray was taken at each point as well.

Observation Index

1. When anterior sacroiliac ligament ruptured, we recorded the separation distance of pubic symphysis and anterior sacroiliac joint, the external rotation angle and force, and observed whether the sacrospinous and sacrotuberous ligaments were damaged or not;

2. When all of the anterior sacroiliac ligament, sacrospinous and sacrotuberous ligaments ruptured, we observed the bone and posterior ligaments change and recorded the external rotation angle, force and relevant separation distances;

Statistical analysis was performed using SPSS version 22.0. We analysed the data using paired sample *t* tests. Differences were considered statistically significant if $P < 0.05$.

Result

(1) When anterior sacroiliac ligament ruptured (Fig. 3), between two groups, mean separation distance of pubic symphysis and anterior sacroiliac joint was 28.6 ± 8.4 mm to 23.6 ± 8.2 mm and 11.4 ± 3.8 mm to 9.7 ± 3.9 mm respectively, all $P > 0.05$. When compared mean external rotation angle and force between two groups, mean data was 33.9 ± 5.5° to 48.9 ± 5.2° and 553.9 ± 82.6 N to 756.6 ± 41.4 respectively, all $P < 0.01$, there were significant differences, the unrestricted group showed more external rotation angle and force. Besides, in the restricted group, all samples were associated with sacrospinous and sacrotuberous ligament injury, two sacrotuberous ligaments and three sacrospinous ligaments ruptured completely. In addition, two samples suffered sacrospinous and sacrotuberous ligament ruptured completely at the same time. On the contrary, no distinct sacrotuberous ligament or sacrospinous ligament injury was observed in unrestricted group. (Fig. 4,5, Table 3)

Table 3, When anterior sacroiliac ligament rupture, comparison of sacrotuberous ligament and sacrospinous ligament between two groups

	Restricted Group	Unrestricted Group
	1 3 5 7 9 11 13	2 4 6 8 10 12 14
Sacrotuberous ligament	Y Y F Y Y F Y	N N N N N N N
Sacrospinous ligament	Y F F Y Y F Y	N N N N N N N
N = normal; Y = ligament is injured obviously (including ligament is prolonged, torn, and the tension cannot be restored obviously); F = ligament is ruptured completely		

(2) After anterior sacroiliac ligament ruptured, we continued to external rotate externally. When samples underwent extremely external rotation force, there was still no sacrotuberous or sacrospinous ligament injury in unrestricted group. However, interosseous sacroiliac ligament, posterior sacroiliac ligament injury and slight sagittal rotation displacement of sacroiliac joint occurred (Fig. 6). When all of the three ligaments ruptured, the separation distance of pubic symphysis and sacroiliac joint was 42.0 ± 7.6 mm and 16.7 ± 4.2 mm respectively, which increased significantly when comparing to the distances anterior sacroiliac ligament ruptured barely($P < 0.05$). These data suggested that the pelvic ring was more unstable too. (Table 4, Fig. 7)

Table 4
When all of the three ligaments fail, compared relevant mean distances to the mean distances when anterior sacroiliac ligament fail barely.

Variable	Restricted group[1)]	Restricted group[2)]	T	*P* value
Seperation distance of symphysis pubis(mm)	28.6 ± 8.4	42.0 ± 7.6	2.836	0.030
Seperation distance of anterior sacroiliac joint (mm)	11.4 ± 3.8	16.7 ± 4.2	2.880	0.028
1) = the distances that when anterior sacroiliac ligament failed barely;				
2) = the distances that when all of anterior sacroiliac ligament, sacrotuberous ligament and sacrospinous ligament failed.				

Discussion

Many researches about pelvic anatomy, morphology and biomechanics have been reported previously, which provides a good foundation for conducting pelvic ligaments study. The anterior sacroiliac ligament covers the front of the sacroiliac joint, which is a wide and thin fiber bundle. As the ligament structure is relatively weak, which has little impact on maintaining the sacroiliac joint stable. The interosseous sacroiliac ligament, which is composed of lots of short and strong fiber bundle, filling much irregular joint space at the upper back of sacroiliac joint. The posterior sacroiliac ligament, also known as the dorsal sacroiliac ligament, dividing into shallow and deep layers. The posterior sacroiliac ligament and the interosseous ligament constitute the sacroiliac ligament complex, which forms the main mechanical resistance at the back of the sacroiliac joint [6–11]. Tile had conducted mechanics experiment, which confirmed that if the posterior sacroiliac ligament complex remained intact, even if other pelvic ligaments ruptured, there still would be no backward and up-down displacement of the hemipelvis [12]. But the control of rotation force of the posterior sacroiliac ligament complex was poor. The sacrotuberous ligament, which starts from the posterior inferior iliac spine, the external edge of the lower part of the sacrum and the upper part of the tailbone, and ends at the ischial node; the sacrospinous ligament is triangular, starting from the external edge of the sacrum and ending at the ischial spine[6, 9]. In a 2002 study, Dujardin F H et al. discovered that the sacrospinous ligament and sacrotuberous ligament played important roles in maintaining the stability of sacroiliac joint. Cutting the two ligaments could not only significantly increase the angular displacement of sacrum, but also the vertical displacement [13]. Sacrospinous ligament mainly controls the external rotation of pelvic ring, while sacrotuberous ligament mainly controls the vertical shear force acting on the semi pelvic area. The two ligaments form an angle of 90° to each other, which are similar to the cruciate ligament of the knee joint and mainly control pelvic vertical external force and external rotation external force. What’s more, they can strengthen the posterior sacroiliac ligament as well. Vukicevic et al. discovered that two ligaments had no preventive effect on pelvic movement, and removal of which also had no effect on sacroiliac joint movement [14]

The APC pelvic injury is considered as a typical pelvic ligaments injury, which is classified into three types. Type I, one or both sides of pubic branches fracture or separation distance of pubic symphysis is less than 2.5 cm, and / or slight separation of anterior sacroiliac joint, but the anterior and posterior ligaments are intact; type II, the pubic symphysis separates more than 2.5 cm, all of the anterior sacroiliac ligament, sacrospinous and sacrotuberous ligament rupture, and the sacroiliac joint separates slightly; type III, the hemipelvis separates completely, but there is no longitudinal displacement. The anterior and posterior ligaments are injured at the same time, and the sacroiliac joint is separate [6, 15]. Among three types, APC type II is the intermediate type, which is between stable and unstable type, still with a lot of controversy about the ligaments injury at present. Thus, it is necessary to have further study about the mechanism of APC pelvic ligament injury.

For APC type I fracture, anterior sacroiliac ligament is considered to be intact and could be taken conservative treatment; While for APC type II fracture, anterior sacroiliac ligament is considered to be injured, operative treatment would be performed [16]. Besides, it is accepted that when the anterior sacroiliac ligament rupture, the separation distance of pubic symphysis must be more than 2.5 cm. Of note, the 2.5 cm distance is used in the Tile classification system to distinguish the chart type of book type B1 pelvic fracture as well [15]. According to our experiment outcome, when APC type II fracture is associated with anterior sacroiliac ligament failure, the mean separation distance is 2.38 cm, which is close to 2.5 cm. However, the distance of each specimen shows great differences, ranging from 1.4 cm to 4.0 cm. This result indicates that the anterior sacroiliac ligament is likely to rupture when the displacement is more than 4.0 cm, and it may not happen between 1.4-4.0 cm.

Besides, we find that the sacrospinous and sacrotuberous ligaments not always rupture completely in APC type II fracture. In unrestricted group, all the pelvic floor ligaments are intact, while in the restricted group, among the seven samples, only two samples completely fail. Slocumn and Terry report that the sacrum is easier to rotate and bend after removal of sacrospinous and sacrotuberous ligaments [17]. EM et al reported that the sacrum is unstable when the two ligaments are torn [18]. In unrestricted group, our result shows that rotational force enables the pelvis to rotate around the sacroiliac joint axis without damaging the two ligaments necessarily. Just as we find in the restricted group, the force of deformation requires a vertical component, which is related to the axis of sacroiliac joint. Thus, our research provides much supplementary content to APC pelvic injury. The two ligaments can make the hemipelvis open by external rotation force, guiding hemipelvis to move downward. APC type II injury with intact sacrospinous and sacrotuberous ligaments is a relatively stable pelvic injury, which can be cured without surgical intervention. Of course, we need more clinical outcomes to prove this viewpoint.

In summary, we mainly have the following findings: (1) pelvic external injury can divide into two situations: pelvis is restricted and pelvis is unrestricted. It is not certain which situation is closer to the real situation, but the results of which are different distinctly. When anterior sacroiliac ligament rupture, the angle and force of external rotation between the restricted group and the unrestricted group are significantly different, and the latter group is bigger. In the unrestricted group, when the anterior sacroiliac ligament rupture, no sacrospinous or sacrotuberous ligaments damage is observed, while the outcome in

the restricted group is opposite. We predict that the main reason is that in unrestricted group, the pelvis can rotate around the axis of sacroiliac joint without damaging the two ligaments while the models in restricted group eliminate the rotation and vertical displacement, which resulting in the two ligaments being injured easily. (2) When anterior sacroiliac ligament fails, mean pubic symphysis distance is 2.38 cm, which is close to 2.5 cm, but the specific data of each samples is various, ranging from 1.4 to 4.0 cm. Thus, we think the 2.5 cm is not the critical standard to distinguish the APC type I from type II pelvic injury. We suggest that clinicians should be cautious to make clinical treatment decisions when the anterior sacroiliac and pelvic ring ligaments are damaged and the pubic symphysis displacement is more than 2.5 cm. Although we think that static and dynamic pelvic imaging can provide useful evidence, we can not make absolute clinical judgment on the anterior sacroiliac ligament completely based on the separation distance of pubic symphysis, unless the distance is very big (more than 4 cm); (3) When the anterior sacroiliac ligament is destroyed, we do not observe the inevitable destruction of the pelvic floor ligaments (sacrospinous and sacrotuberous ligaments). Among all the samples, only two cases show sacrospinous and sacrotuberous ligaments ruptured completely, and none of samples in the unrestricted group shows pelvic floor ligaments rupture. But it is confirmed that when both of two ligaments fail, the pelvic injury is more serious, which has affected the interosseous sacroiliac joint ligament and the stability of the posterior pelvis. When extreme external rotation force is performed in the unrestricted group, the interosseous sacroiliac ligament and posterior sacroiliac ligament torsion damage appear firstly, affecting the stability of the whole hemipelvis, resulting in vertical and sagittal rotation instability, and then pelvic floor ligament rupture occur. According to this experiment, we consider that the pelvic external rotation injury is not as simply caused by violence and ligament injury as we think. The effects of pelvic structures on pelvic rotation and vertical stability need to be reevaluated. These findings indicate that we still need to do further researches about ligaments around sacroiliac joint, pelvic floor ligaments and the mechanism of stability of APC pelvic fractures.

Our study also has a number of limitations. First, it is typically limited by cadaveric biomechanics, our cadaveric samples are a bit older when comparing to the pelvis of patients, which may lead to different characteristics; Our load-bearing model is not enough to represent this kind of injury accurately. However, when we try to relieve this impact through the restricted and unrestricted models, we find similar results. Second, when pelvis is under high-energy injury, the loading rate will be slower than expected. Considering the viscoelasticity of biological tissue, the ligament in particular, the load rate data in our injury model are various. Although these data is controversial in higher tension at present, it is generally accepted by the public that with the tension increasing, the ultimate load-bearing, stiffness and energy absorption of ligaments also increase, and the ligaments failure will be more likely to occur [19, 20]. However, there is no literature about the relation between ligament elongation failure and stress. Although the strain rate of our acute pelvic injury model is not as large as we expected, we believe that the anatomical relationship between pelvic ligament and bone can provide useful information about APC injury [19–21]. The recorded force is not intended to reflect the actual force in pelvic injury. In fact, the distances to the specific ligament failure is the goal of the investigation, which is less affected by viscoelasticity. Third, the quantity of our sample is small, we need more cadaver specimens to support our theory.

Conclusion

First, pelvic external rotation injury can divide into two situations: hemipelvis is restricted and unrestricted, which results into two different outcomes. When anterior sacroiliac ligament rupture, the unrestricted group external rotation angle and force is bigger and no obvious sacrotuberous or sacrospinous ligaments appear, but in the restricted group, both of two ligaments are injured. Second, when anterior sacroiliac ligament fails, pubic symphysis displacement distance is various with a high fluctuation, ranging from 1.4 to 4.0 cm. Third, when anterior sacroiliac ligament is destroyed, we does not observe the inevitable destruction of the pelvic floor ligament (sacrospinous ligament and sacrotuberous ligament).

Abbreviations

APC= anterior posterior compression

Declarations

Acknowledgments

The authors wish to thank the Zhejiang Provincial Medical and Health Technology Project Funding (No. 2019312266) and Wenzhou Science and Technology Bureau Project Funding (No. YZ20130168).

Authors' contributions

XSG, XLS designed the study and obtained the funding. YPC, CWZ collected the data. SBS, GDB, and JZK analyzed the data. JZK and YX interpreted the data. JZK, YPC, and CWZ composed the article. All authors read and approved the final manuscript.

Funding

This research was supported by Zhejiang Provincial Medical and Health Technology Project Funding (No.2019312266) and Wenzhou Science and Technology Bureau Project Funding (No. YZ20130168). The funders had roles in the study design, data collection and analysis and decision to publish.

Availability of data and materials

The authors confirm that the data supporting the findings of this study are available within the article and its supplementary materials.

Ethics approval and consent to participate

The consent of our ethics committee and the donors' relatives was given before the experiments.

Consent for publication

Consent for publication of the data was obtained from the relatives of the donors before the start of the study.

Competing interests

The authors declare that they have no competing interests.

Author details

[1] The Second Affiliated Hospital and Yuying Children's Hospital of Wenzhou Medical University, NO.109, Xue Yuan West Road, Wenzhou, Zhejiang Province, 325027, China; [2]Department of Orthopaedics, the Central Hospital of Wenzhou, NO.252 Baili Road Lucheng District, Wenzhou, Zhejiang,325000,China.

References

[1] Krappinger D, Kaser V, Kammerlander C, Neuerburg C, Merkel A, Lindtner RA. Inter- and intraobserver reliability and critical analysis of the FFP classification of osteoporotic pelvic ring injuries. Injury. 2019;222

[2] Li S, Meng X, Li W, Sun Z, Wang X, Qi H, Wei S, Zhou D. Effects of minimally invasive plate-screw internal fixation in the treatment of posterior pelvic ring fracture. Exp Ther Med. 2018;16(5):4150–4.

[3] Salari P, Cannada LK, Moed BR. Do asymptomatic patients have normal function after percutaneous fixation of the posterior pelvic ring? A casecontrol pilot study. J Orthop Surg Res. 2015;10(1):68.

[4] Bucholz R W. The pathological anatomy of Malgaigne fracture-dislocations of the pelvis [J]. J Bone Joint Surg Am, 1981, 63(3): 400-4.

[5] Tile M, Helfet DL, Kellum JF: Fractures of the Pelvis and Acetabulum. 3rd ed. Philadelphia, PA: Lippincott Williams & Wilkins; 2003

[6] Young JW, Burgess AR, Brumback RJ et al: Lateral compression fractures of the pelvis: the importance of plain radiographs in the diagnosis and surgical management. Skel Radio.1986;15:103-109.

[7] Gary J L, Mulligan M, Banagan K, et al. Magnetic resonance imaging for the evaluation of ligamentous injury in the pelvis: a prospective case-controlled study [J]. J Ortho Trauma, 2014, 28(1): 41-7.

[8] Garcia J M, Doblare M, Seral B, et al. Three-dimensional finite element analysis of several internal and external pelvis fixations [J]. J Biomechanical Enginer, 2000, 122(5): 516-22.

[9] Zheng N, Watson L G, Yong-Hing K. Biomechanical modelling of the human sacroiliac joint [J]. Medical & biological engineering & computing, 1997, 35(2): 77-82.

[10] Zhang L, Peng Y, Du C, et al. Biomechanical study of four kinds of percutaneous screw fixation in two types of unilateral sacroiliac joint dislocation: a finite element analysis [J]. Injury, 2014, 45(12): 2055-9.

[11] Tonne B M, Kempton L B, Lack W D, et al. Posterior iliac offset: description of a new radiological measurement of sacroiliac joint instability [J]. Bone & Joint J, 2014, 96-B(11): 1535-9.

[12] Tile M. Pelvic ring fractures: should they be fixed? [J]. J Bone & Joint Surg Bri.Volume, 1988, 70(1): 1-12.

[13] Dujardin F H, Roussignol X, Hossenbaccus M, et al. Experimental study of the sacroiliac joint micromotion in pelvic disruption [J]. J Ortho Trauma, 2002, 16(2): 99-103.

[14] Vukicevic S, Marusic A, Stavljenic A et al. Holographic analysis of the human pelvis [J]. Spine, 1991, 16(2): 209-14.

[15] Young J W, Burgess A R, Brumback R J, et al. Pelvic fractures: value of plain radiography in early assessment and management [J]. Radiology, 1986, 160(2): 445-51

[16] Müller M E, Allgöwer M. Manual of internal fixation : techniques recommended by the AO-ASIF Group [M]. Springer-Verlag, 1991.

[17] Slocumb L, Terry R J. Influence of the sacrotuberous and sacrospinous ligaments: In limiting movements at the sacroiliac joint [J]. J Am. Medical Association, 1926, 87(5): 307-9.

[18] Edeiken-Monroe B S, Browner B D, Jackson H. The role of standard roentgenograms in the evaluation of instability of pelvic ring disruption [J]. Clin Orthop Relat Res, 1989, 240): 63-76.

[19] Crisco J J, Moore D C, Mcgovern R D. Strain-rate sensitivity of the rabbit MCL diminishes at traumatic loading rates [J]. J Biomechanics, 2002, 35(10): 1379-85

[20] Lydon C, Crisco J, Panjabi M, et al. Effect of elongation rate on the failure properties of the rabbit anterior cruciate ligament [J]. Clin Biomechanics, 1995, 10(8): 428-33.

[21] Woo S L, Peterson R H, Ohland K J, et al. The effects of strain rate on the properties of the medial collateral ligament in skeletally immature and mature rabbits: a biomechanical and histological study [J]. J Orthop Surg Res. 1990, 8(5): 712-21.

Figures

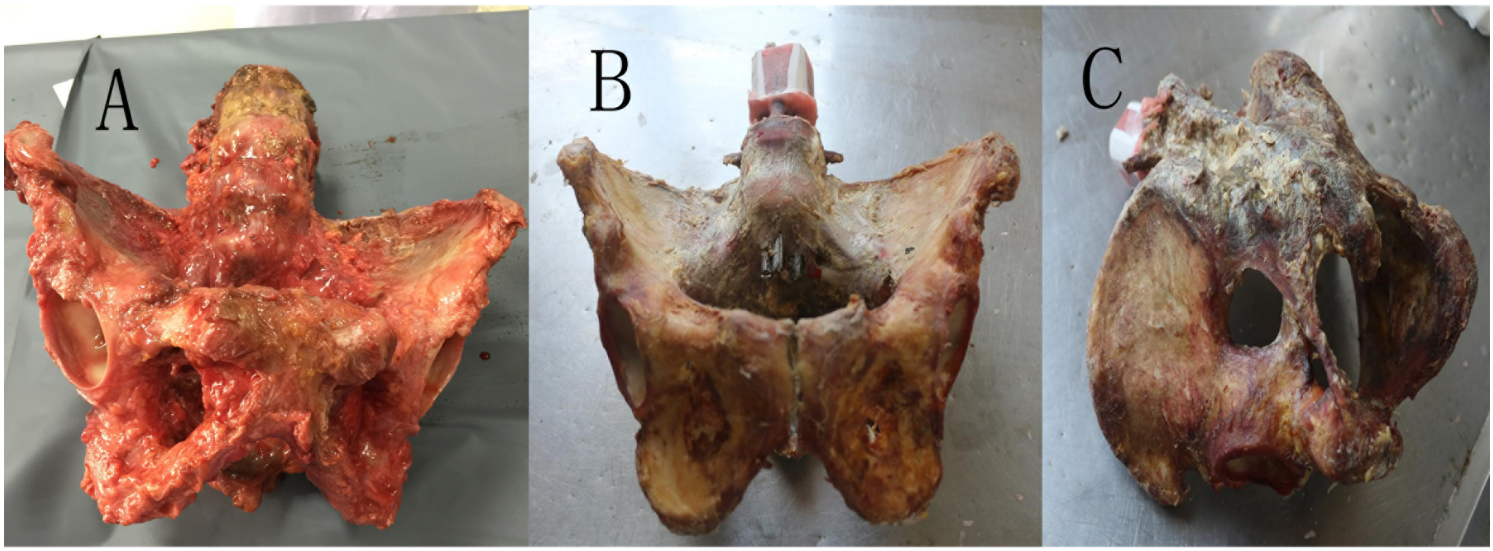

Figure 1

A. pelvic specimens from fresh cadavers; B□C Anterior and posterior views of the immobilized pelvic specimen

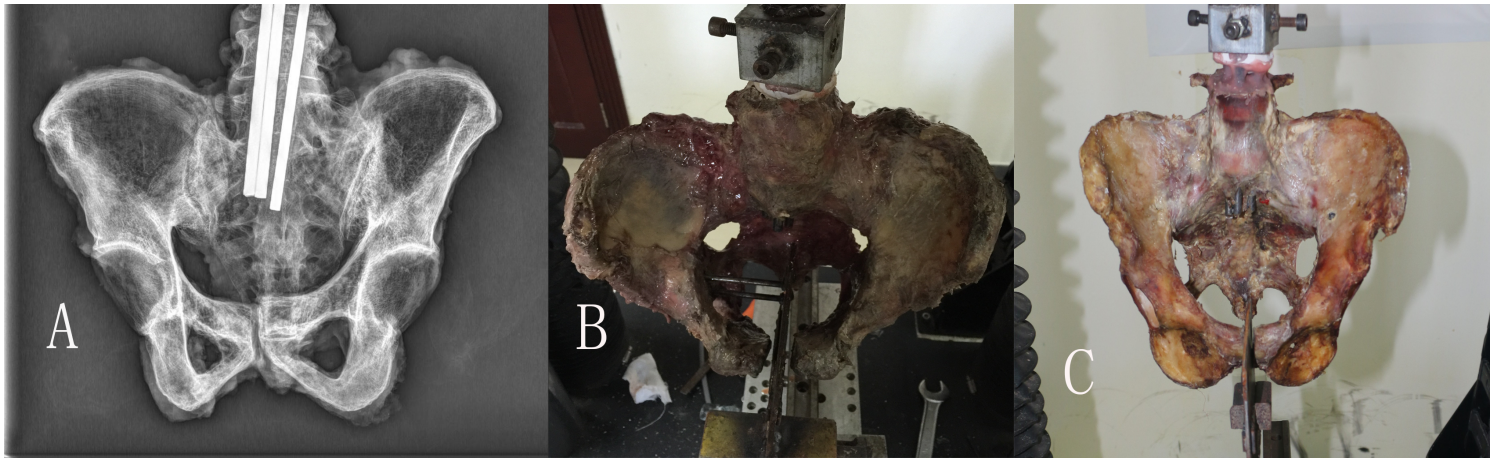

Figure 2

A. X-ray images of the pelvis specimen before the experiment; B□C Restricted hemipelvis model and unrestricted hemipelvis model

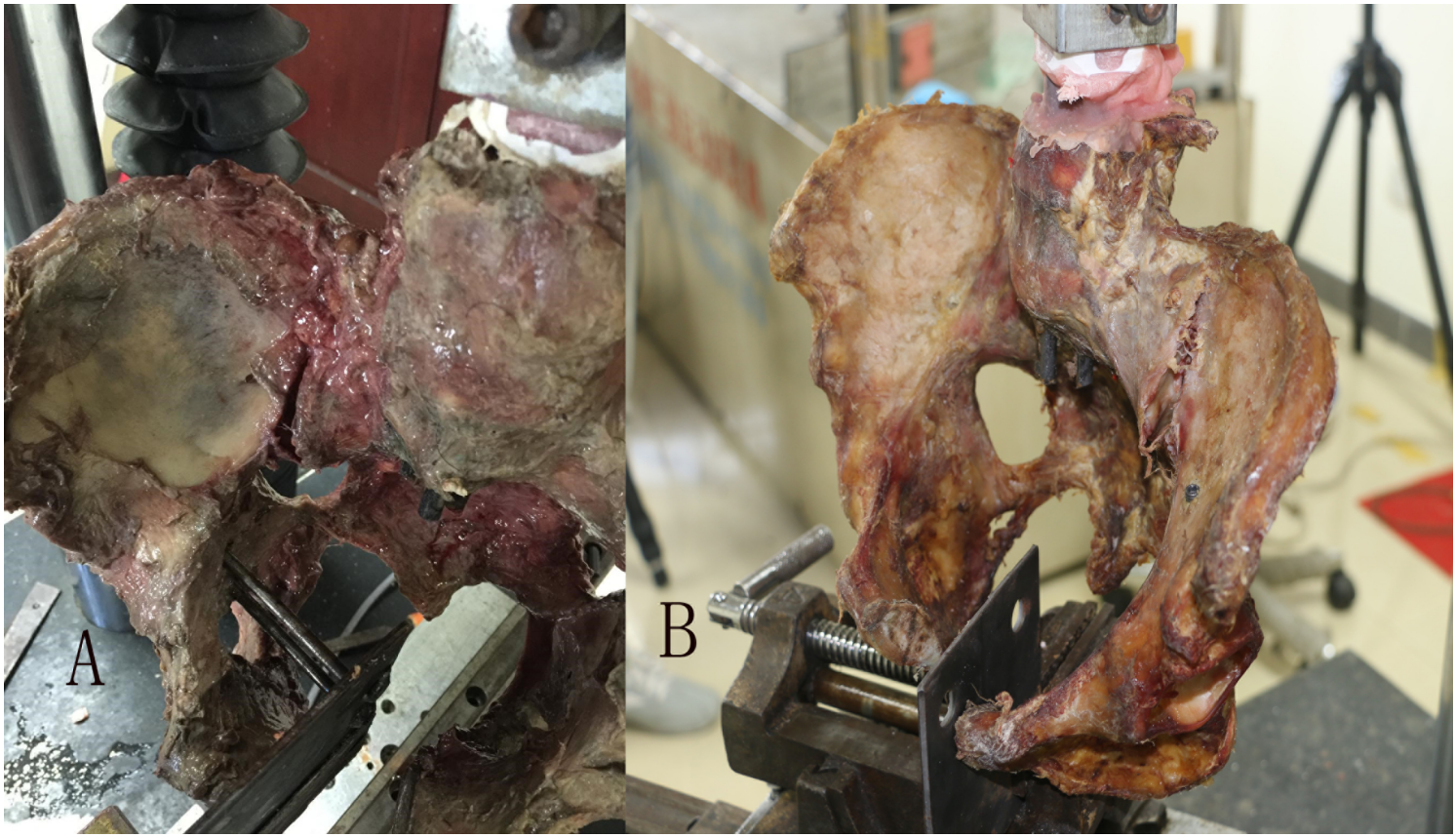

Figure 3

A, B Samples in restricted group and unrestricted group had anterior sacroiliac ligament failed.

Figure 4

A-C In restricted group, anterior sacroiliac ligament and sacrospinous ligament rupture.

Figure 5

A-C In the restricted group, all of anterior sacroiliac ligament and the sacrospinous ligament and sacrotuberous ligament rupture.

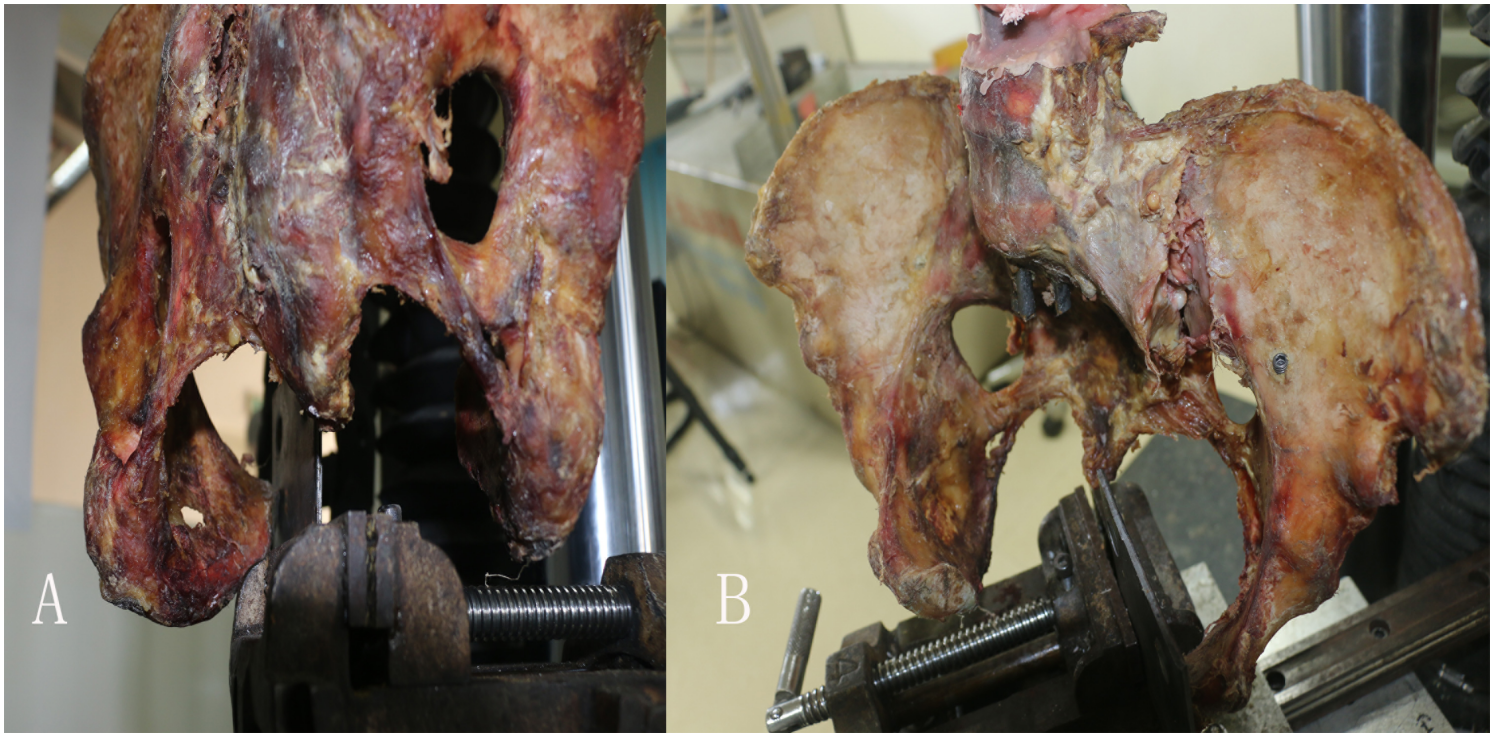

Figure 6

A, B In the unrestricted group, under extreme external rotation force, no obvious sacrospinous ligament or the sacrotuberous ligament injury is observed, but the posterior sacroiliac ligament injury is seen.

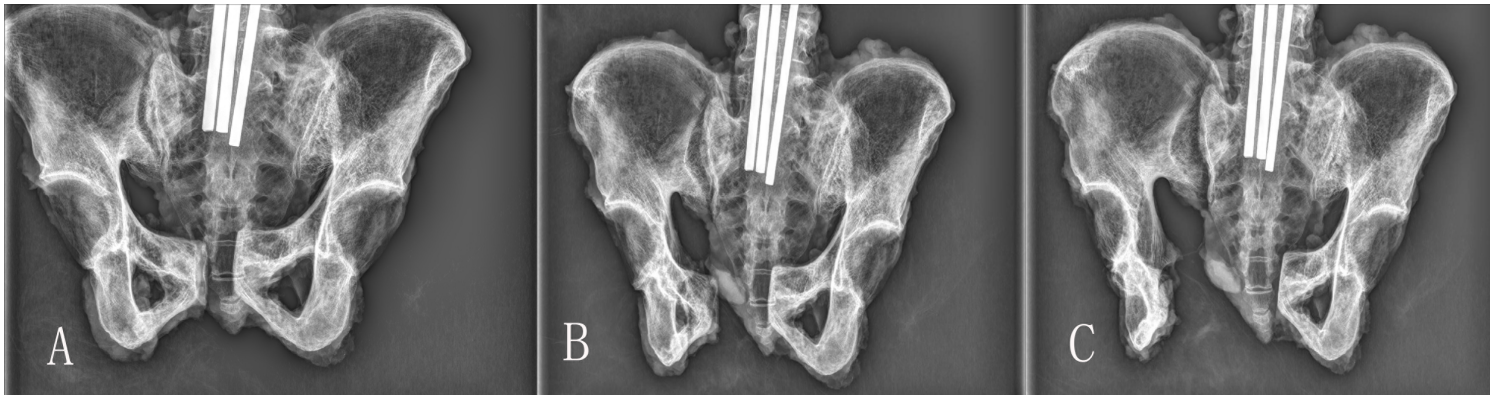

Figure 7

A-C. In the restricted group, the X-ray images are taken when anterior sacroiliac ligament, sacrospinous ligament and sacrotuberous ligament rupture in turn, all of which shows that the separation distance of pubic symphysis increases apparently.