Intraoperative palpation increases the efficiency of sentinel lymph node biopsy but is not necessary for every operation

Xingsong Qin
Zhengzhou People's Hospital
Zhiwei Li
First Hospital of China Medical University
Xinyu Zheng
First Hospital of China Medical University
Wei Liu
Zhengzhou People's Hospital
Xinglei Qin (tougaozhuanyongqxl@163.com)
Henan Provincial People's Hospital

Research Article

Keywords: Indocyanine green, Methylene blue, Palpation, Sentinel lymph node biopsy

Posted Date: February 23rd, 2021

DOI: https://doi.org/10.21203/rs.3.rs-222063/v1

Abstract

Background

Although intraoperative palpation (IOP) is recommended during the sentinel lymph node biopsy (SLNB), its actual effect on SLNB remains unclear. Meanwhile, controversy exists regarding whether IOP is necessary for all SLNB. The study examined the impacts of IOP on SLNB and determined whether IOP is necessary for every operation.

Methods

126 patients with early stage breast cancer underwent SLNB using Indocyanine green (n = 64) and Methylene blue (n = 62). Traced lymph nodes (TLNs) were resected, followed by the palpated lymph nodes (PLNs) surrounding the original TLNs. and we analyzed the results (with and without IOP) in terms of detection rate, number of removed SLNs and detection rate of metastatic SLNs.

Results

Without IOP, the detection rates of the two group were 90.6%(58/64), 88.7%(55/62), but with IOP, all the rates increased to 100% ($p < 0.05$).The mean number also increased (With palpitation: Without palpitation = 3.5 : 2.9; 3.1 : 1.8, $p < 0.05$).73 (57.9%) patients were detected with PLNs and 13 (10.3%) were detected with only PLNs. In the 26 patients detected with metastatic nodes, 4 (15.4%) were detected with only palpated metastatic nodes.

Conclusions

Intraoperative palpation increases detection rate and number of SLNs and reduced the potential false-negative rate. But intraoperative palpation is not necessary for all SLNB when the number of TLNs reaches three or more.

Introduction

Sentinel lymph node biopsy (SLNB) is proved to be alternative to axillary lymph node dissection (ALND) by the ACOSOG Z0011 trial, and has been the standard operation for axillary assessment in patients with early-stage breast[1]. Even intraoperative palpation (IOP) of axillary tissue is recommended during the procedure of SLNB[1, 2], the nodes indentified by tracers (TLNs) were exclusively regarded as sentinel lymph node(SLNs) in most previous studies, but nodes missed by tracer but could be detected by IOP were not assessed. Without releazing the impacts of IOP in clinical practice, many surgons may be prone to neglect intraoperative palpation when TLNs are detected already.

There is limited research investigating the impacts of IOP on SLNB, but in one study investigating SLNB using standard tracing method (the combination of blue dye and radioisotope tracers), the author observed that 2.4% patients had SLNs detected solely by IOP, and seven patients had clinically suspicious nodes identified solely by palpation, in addition to sentinel lymph nodes detected by tracer. In five of the seven patients, the nodes harbored metastasis[3]. The impacts of IOP on SLNB using common tracing methods such as indocyanine green and methylene blue remains unknown. Moreover, compared with standard tracing method, these tracing methods are inferior in detection rate, mean number of SLN and false negative rate but more available and adopted widely in the world[4, 5]. Meanwhile, controversy exists regarding whether IOP is necessary for every SLNB operation.

We conducted this study to examined the impacts of IOP on SLNB and determined whether IOP is necessary for every patient.

Materials And Methods

Patients

This study included 126 breast cancer patients who underwent SLNB with ICG and MB from October 2017 to December 2019 in our department. The study was in accordance with Helsinki Declaration and approved by the Institutional Review Board of Zhengzhou People's Hospital. The IRB numbers was 2017CTN0118, and all patients signed informed consent.

The patient inclusion criteria consisted of pathological diagnosis of breast cancer; maximum tumor diameter of 5 cm; no identification of clinically metastatic axillary lymph nodes through ultrasound, chest computed tomography or breast magnetic resonance imaging. And the exclusion criteria included palpable axillary lymph nodes; previous axillary surgery; neoadjuvant chemotherapy or endocrine therapy.

Surgical procedure

SLNs identification using ICG:

One minute before surgery, 1 ml of ICG solution (Yichuang Pharmaceutical LLC, Dandong, China.) injected subcutaneously and intradermally at the areola. Following gentle breast massage, ICG fluorescence was stimulated and detected by a hand-held photodynamic eye camera (MingDe Biomedical Technology Corporation, Hebei, China). Later, an incision was made to start the SLNB where the fluorescence disappeared. After excising the fluorescent nodes, the area of a 3 cm diameter around the first TLNs was gently palpated, and any enlarged or hard palpable suspicious LNs were also excised. PLNs were more offwhite in color and more pliable and tough in texture than fat or glandular tissue. When suspicious nodes were identified, they were excised and handled as if they were lymph nodes.

SLNs identification using MB:

Ten minutes before surgery, 1 ml of 1% MB (Jichuan Pharmaceutical, Taizhou, China) was subdermally injected into the periareolar region of 4 quadrants of the breast (clockwise). Following gentle massage, a small transverse incision was made one centimeter below the axillary line to detect blue-stained nodes. After that, palpable suspicious nodes around the blue-stained nodes were also excised.

After the complication of SLNB procedure, we divided all removed lymph nodes into two parts: traced lymph nodes (TLNs) and palpated lymph nodes (PLNs). TLNs were defined as any fluorescent lymph nodes located by photodynamic eye camera or any node stained by MB. PLNs were any lymph nodes that were clinically suspicious on systematic palpation of the area of a 3 cm diameter around the first TLNs. All these SLNs were examined by intraoperative histopathology examination of sliced 2-mm sections of frozen tissues to detect SLN metastasis. In patients displaying malignant cells in the nodesof frozen sections, ALND was performed as a standard axillary treatment.

Statistical analysis

Chi-squared test were used to compare detection rate of SLNs, number of

SLNs and detection rate of metastatic nodes between the results with palpation and those without palpation. All statistical analyses were performed using IBM SPSS statistics version 23 (SPSS Inc., Chicago, IL, USA) software, and p-value of < 0.05 represented statistical significance.

Results

Patients and Tumor Characteristics

The patients ranged in age from 26 to 75 years (mean±SD, 47.7±11.4 years) and other characteristics of patients and tumors were presented in Table 1.

Detection rate of SLNB

Table 2 shows that if TLNs were counted as SLNs, the detection rates in the two groups were 90.6% (58/64) and 88.7%(55/62), but with IOP, all the rates increased to 100%. In the 126 patients, 73 (57.9%) patients were detected with PLNs, 22 and 51 patients were from ICG and MB group. 13 (10.3%) patients were detected with only PLNs, 6 patients were from ICG group, 7 patients were from MB group.

Number of SLNs removed

A total of 421 lymph nodes were removed, 227 from ICG group (186 fluorescen and 41 palpated), 194 from MB group (109 blue-stained and 85 palpated; Table 3). The palpation rate was 18.1% and 44.5%. Table 2 shows that the mean number of TLNs was just 2.9±1.1 and 1.8±0.7. With IOP, the numbers increased to 3.5±1.1 and 3.1±0.8, respectively.

Detection rate of metastatic nodes

12(18.8%) and 10(16.1%) patients were detected with13 and 12 traced metastatic SLNs in the two groups. However, 2 and 2 more patients were detected with only palpated metastatic node even there were additional TLNs. As a consequence, the detection rate of metastatic nodes increased to 14 (21.9%) and 12(20.9%), respectively. The metastatic SLNs in the two groups increased to 17 and 14, respectively . The above detailed results were shown in Table2 and Table 3.

Discussion

In previous studies[6–13] those treated TLNs as SLNs exclusively, the detection rates of SLNB using ICG and MB were 95.0%-96.0% and 83.0%-88.0%, respectively. The mean number of SLNs was 1.5–3.4 and 1.1–2.1, respectively. Similar results were observed in our study.

The beneficial impacts of intraoperative palpation may lie on that tracer and intraoperative palpation can complement each other. Tracers such as ICG helped doctors to quickly locate lymph nodes [14, 15]. But leakage caused by cuts in the lymphatic ducts after the excision of the first node made it difficult to detect other fluorescent nodes in the surgical field. MB can stain lymph nodes blue, facilitating their identification during opreation. But the visual interference caused by intraoperative bleeding will obstruct SLNs identification, particularly in obese patients [10, 16]. Surgeons can continue to detect lymph nodes by systematically palpating neighboring axillary contents. In our study, 183 (28.9%) nodes were detected merely by IOP, indicating that these nodes may be undetected if merely traced lymph nodes were reoved and considered as the SLNs. Besides that, we observed that in the 26 patients detected with metastatic nodes, 4 (15.4%) were detected with only palpated metastatic nodes,even there were additional TLNs were detected before. It suggested that if only TLNs were removed and examinated, some metastatic lymph nodes would be undetected, a false-negative does occur inevitably. So PLNs should be counted as part of SLNs to reduce the false-negative rate(FNR).

IOP could raise the number of SLNs removed and many researchers have confirmed the association between the number of SLNB and the FNR. But the optimal number of removed SLNs has always been controversial. Kenny S concluded that two SLNs were enough to predicte the status of axillary lymph nodes[17]. While Melanie A observed all positive SLNs were identified within the first three SLNs detected; removal of more than three SLNs did not increase the accuracy of finding a positive node[18]. Min Yi found that removing up to 5 SLNs was sufficient to identify metastatic carcinoma in > 99% of patients[19]. But Martin D thought that there is no absolute upper threshold for the number of SLNs that should be removed [20]. In our study, The first positive SLN was the first node removed in 20 patients (76.9%), following the second node in 22 patients (84.6%) and was removed in all patients by the third SLN. The correlation between the number of lymph nodes removed and cumulative percentage with a positive SLN was shown in Fig. 1[18, 21–23]. Accoding to previous studies[24–27], the likelihood of a false-negative SLN finding was significantly decreased, when SLNs detection number reaches 3, the FNR can reached an acceptable level of less than 5%, the relationship between SLNs removed and FNR was shown in Fig. 2.

Whereas, the number of SLNs removed is associated with the morbidity of SLNB. Removing too many additional lymph nodes may expose patients to increased morbidity of lymphedema, pain, stiffness and shoulder weakness and brachial plexus injuries[28]. Data from the ACOSOG Z0010 trial found an increase in rates of axillary seroma formation and wound infections in patients who had more than four SLN removed[28]. Cost-effectiveness and cost-utilization studies have found that excision of increasing numbers of SLN is associated with increased OR time, increased pathology costs, and increased procedure costs[21].

Thus, We need to find a balance piont between the benefits and risks of IOP to ensure accuracy and minimize morbidity and procedure costs. We suggest that when the number of TLNs reaches 3 or more, intraoperative palpation of axillary tissue was not necessary to remove redundant lymph nodes.

Conclusion

Intraoperative palpation increases detection rate and number of SLNs and reduced the potential false-negative rate. But intraoperative palpation is not necessary for all SLNB when the number of TLNs reaches three or more.

Abbreviations

IOP: Intraoperative palpation; SLNB: Sentinel lymph node biopsy; CN :Carbon nanoparticles; ICG :Indocyanine green; MB :Methylene blue; ALND : Axillary lymph node dissection ; FNR : False-negative rate.

Declarations

Acknowledgements

Not applicable.

Authors' contributions

Xingsong Q performed the experiments and the data analysis. Xingsong Q and Zhiwei L conceived and designed the study. Zhiwei L and Wei L contributed to the acquisition of the data. Xinsong Q, Xinglei Q and Xinyu Z contributed to the analysis and interpretation of data. Xingsong Q wrote the manuscript. Zhiwei L, Wei L and Xinyu Z reviewed and edited the manuscript. All authors read and approved the final manuscript.

Funding

No sources for funding are to be declared.

Availability of data and materials

The datasets used and/or analyzed during the current study are available from

the corresponding author on reasonable request.

Ethics approval and consent to participate

The study was in accordance with Helsinki Declaration and approved by the Institutional Review Board of Zhengzhou People's Hospital. The IRB numbers was 2017CTN0118, and all patients signed informed consent.

Consent for publication

Not applicable.

Competing interests

The authors declare that they have no competing interests.

References

1. Giuliano AE, Hunt KK, Ballman KV, et al.: Axillary dissection vs no axillary dissection in women with invasive breast cancer and sentinel node metastasis: a randomized clinical trial. Jama 2011;305:569–575.
2. Telli ML, Gradishar WJ, Ward JH: NCCN Guidelines Updates: Breast Cancer. Journal of the National Comprehensive Cancer Network: JNCCN 2019;17:552–555.
3. Carmon M, Olsha O, Rivkin L, et al.: Intraoperative palpation for clinically suspicious axillary sentinel lymph nodes reduces the false-negative rate of sentinel lymph node biopsy in breast cancer. The breast journal 2006;12:199–201.
4. Hu X, Li T, Wang B, et al.: Comparison of 4th ESO-ESMO international consensus guidelines for advance breast cancer and Chinese anti-cancer association committee of Breast Cancer Society guideline. Breast 2019;45:36–42.
5. Qin X, Yang M, Zheng X: Comparative study of indocyanine green combined with blue dye with methylene blue only and carbon nanoparticles only for sentinel lymph node biopsy in breast cancer. Annals of surgical treatment and research 2019;97:1–6.
6. Niebling MG, Pleijhuis RG, Bastiaannet E, et al.: A systematic review and meta-analyses of sentinel lymph node identification in breast cancer and melanoma, a plea for tracer mapping. European journal of surgical oncology: the journal of the European Society of Surgical Oncology and the British Association of Surgical Oncology 2016;42:466–473.
7. Peek MC, Charalampoudis P, Anninga B, et al.: Blue dye for identification of sentinel nodes in breast cancer and malignant melanoma: a systematic review and meta-analysis. Future oncology 2017;13:455–467.

8. Sugie T, Ikeda T, Kawaguchi A, et al.: Sentinel lymph node biopsy using indocyanine green fluorescence in early-stage breast cancer: a meta-analysis. International journal of clinical oncology 2017;22:11–17.
9. Zhang L, Huang Y, Yang C, et al.: Application of a carbon nanoparticle suspension for sentinel lymph node mapping in patients with early breast cancer: a retrospective cohort study. World J Surg Oncol 2018;16:112.
10. Wu X, Lin Q, Chen G, et al.: Sentinel Lymph Node Detection Using Carbon Nanoparticles in Patients with Early Breast Cancer. Plos One 2015;10:e0135714.
11. Sugie T, Sawada T, Tagaya N, et al.: Comparison of the indocyanine green fluorescence and blue dye methods in detection of sentinel lymph nodes in early-stage breast cancer. Ann Surg Oncol 2013;20:2213–2218.
12. Ji Y, Luo N, Jiang Y, et al.: Clinical utility of the additional use of blue dye for indocyanine green for sentinel node biopsy in breast cancer. The Journal of surgical research 2017;215:88–92.
13. Guo W, Zhang L, Ji J, et al.: Evaluation of the benefit of using blue dye in addition to indocyanine green fluorescence for sentinel lymph node biopsy in patients with breast cancer. World J Surg Oncol 2014;12:290.
14. Sugie T, Kassim KA, Takeuchi M, et al.: A novel method for sentinel lymph node biopsy by indocyanine green fluorescence technique in breast cancer. Cancers 2010;2:713–720.
15. Takeuchi M, Sugie T, Abdelazeem K, et al.: Lymphatic mapping with fluorescence navigation using indocyanine green and axillary surgery in patients with primary breast cancer. The breast journal 2012;18:535–541.
16. Ang CH, Tan MY, Teo C, et al.: Blue dye is sufficient for sentinel lymph node biopsy in breast cancer. The British journal of surgery 2014;101:383–389; discussion 389.
17. Low KS, Littlejohn DR: Optimal number of sentinel nodes after intradermal injection isotope and blue dye. ANZ journal of surgery 2006;76:472–475.
18. Lynch MA, Jackson J, Kim JA, Leeming RA: Optimal number of radioactive sentinel lymph nodes to remove for accurate axillary staging of breast cancer. Surgery 2008;144:525–531; discussion 531 – 522.
19. Yi M, Meric-Bernstam F, Ross MI, et al.: How many sentinel lymph nodes are enough during sentinel lymph node dissection for breast cancer? Cancer 2008;113:30–37.
20. Mccarter MD, Yeung H, Fey J, et al.: The breast cancer patient with multiple sentinel nodes: When to stop? Journal of the American College of Surgeons 2001;192:692–697.
21. Povoski SP, Young DC, Walker MJ, et al.: Re-emphasizing the concept of adequacy of intraoperative assessment of the axillary sentinel lymph nodes for identifying nodal positivity during breast cancer surgery. World J Surg Oncol 2007;5:18.
22. Schrenk P, Rehberger W, Shamiyeh A, Wayand W: Sentinel node biopsy for breast cancer: does the number of sentinel nodes removed have an impact on the accuracy of finding a positive node? J Surg Oncol 2002;80:130–136.

23. McCarter MD, Yeung H, Fey J, et al.: The breast cancer patient with multiple sentinel nodes: when to stop? Journal of the American College of Surgeons 2001;192:692–697.
24. Ban EJ, Lee JS, Koo JS, et al.: How many sentinel lymph nodes are enough for accurate axillary staging in t1-2 breast cancer? Journal of breast cancer 2011;14:296–300.
25. Yang B, Zheng G, Zuo WS, et al.: [Analysis of clinicopathological factors associated with false-negative rate of sentinel lymph node biopsy in breast cancer patients: experience of a single center]. Zhonghua zhong liu za zhi [Chinese journal of oncology] 2013;35:389–393.
26. Li H, Jun Z, Zhi-Cheng G, Xiang Q: Factors that affect the false negative rate of sentinel lymph node mapping with methylene blue dye alone in breast cancer. The Journal of international medical research 2019;47:4841–4853.
27. Koo BY, Jeong SG, Eom TI, et al.: The Number of Removed Lymph Nodes for an Acceptable False Negative Rate in Sentinel Lymph Node Biopsy for Breast Cancer. Journal of breast cancer 2009;12:100–105.
28. Wilke LG, McCall LM, Posther KE, et al.: Surgical complications associated with sentinel lymph node biopsy: results from a prospective international cooperative group trial. Ann Surg Oncol 2006;13:491–500.

Tables

Table 1: Patients and tumor characteristics

Characteristics	Number of patients (%)
Age (years)	
≤50	66(52.4%)
>50	60(47.6%)
Body mass index, kg/m^2	
≤18.4	5(4.0%)
18.5-23.9	57(45.2%)
24.0-27.9	46(36.5%)
≥28	18(14.3%)
Histologic type	
Invasive ductal	98(77.8%)
Invasive lobular	5(4.0%)
DCIS	16(12.7%)
Other types	7(5.5%)
Tumor Size	
≤2.0cm	90(71.4%)
2-5cm	36(28.6%)
Menstruation status	
Pre	65(51.6%)
Post	61(48.4%)
Tumor localization	
Upper outer	58(46.0%)
Lower outer	20(15.9%)
Upper medial	35(27.8%)
Lower medial	7(5.6%)
Central	6(4.7%)
Type of breast surgery	
Lumpectomy	82(65.1%)
Mastectomy	44(34.9%)

Molecular subtypes	
Luminal A	18 (14.3%)
Luminal B	71 (56.3%)
HER2 positive	27 (21.4%)
Triple negative	10 (8.0%)

Table 2: Results of SLNB: Without IOP and With IOP

Characteristics	Method	Without palpitation	With palpitation	P value
Detection rate of SLNs, n (%)	ICG	58(90.6%)	64(100%)	0.012
	MB	55(88.7%)	62(100%)	0.006
Mean number of lymph nodes, (mean ± SD)	ICG	2.9 ± 1.1	3.5 ± 1.0	<0.001
	MB	1.8 ± 0.7	3.1 ± 0.8	<0.001
Detection rate of metastatic nodes, n (%)	ICG	12(18.8%)	14(21.9%)	0.66
	MB	10(16.1%)	12(19.4%)	0.64

Table 3: Comparison of TLNs and PLNs.

Characteristics	Method	TLNs	PLNs	Total
Number of removed nodes, n (%)	ICG	186(81.9%)	41(18.1%)	227(100%)
	MB	109(56.2%)	85(43.8%)	194(100%)
Number of metastatic nodes, n (%)	ICG	13(76.5%)	4(23.5%)	17(100%)
	MB	12(85.7%)	2(14.3%)	14(100%)

Figures

Fig 1

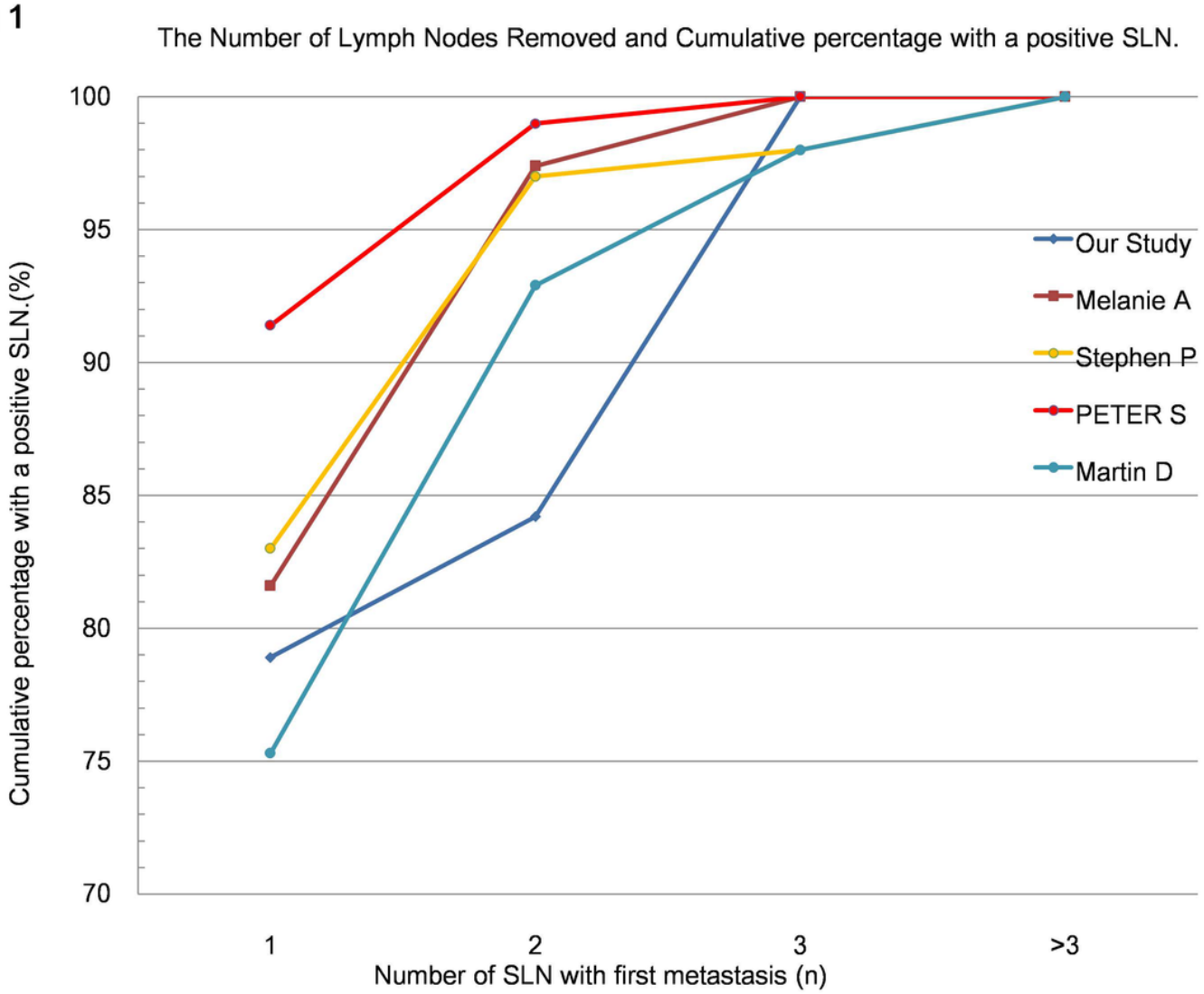

Figure 1

The Number of Lymph Nodes Removed and Cumulative percentage with a positive SLN When two SLNs was removed, around 90% of the first positive SLN was detected; when the number of SLNs reaches 3, more than 95% of the first positive SLN was included.

Fig 2

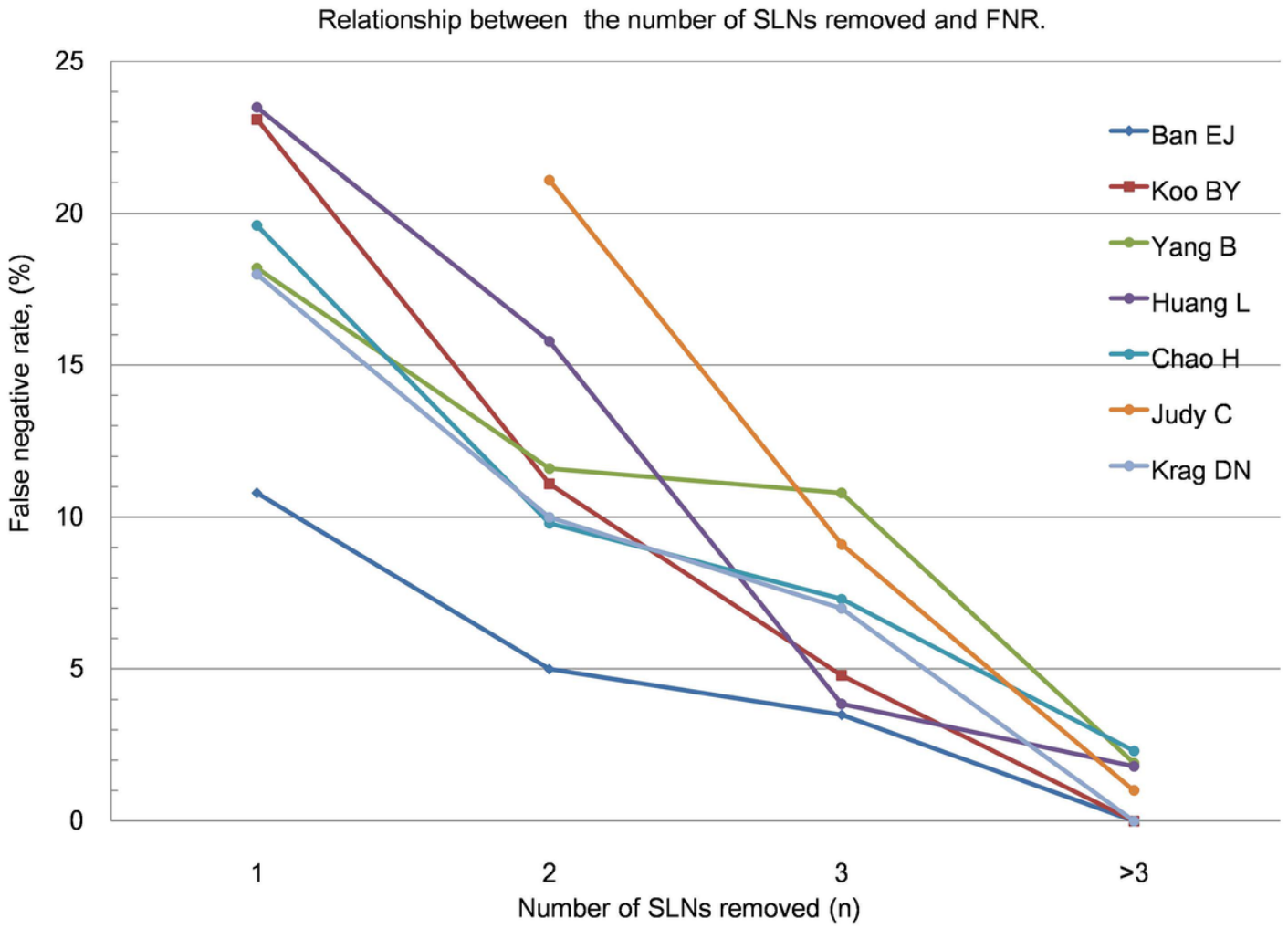

Figure 2

Relationship between SLNs removed and FNR. False-negative SLN finding was significantly decreased when the number increases. As the number reaches 3, the FNR can reached an acceptable level of less than 5%. (In Z1071 trial conducted by Judy C, the corresponding FNR of 1 SLN was not reported)