The tunnel approach versus medial approach in laparoscopic radical right hemicolectomy for colon cancer: A retrospective cohort study

xijie zhang
Henan Cancer Hospital
Junli Zhang
Henan Cancer Hospital
Pengfei Ma
Henan Cancer Hospital
Yanghui Cao
Henan Cancer Hospital
Chenyu Liu
Henan Cancer Hospital
Sen Li
Henan Cancer Hospital
Guangsen Han
Henan Cancer Hospital
Yuzhou Zhao (yuzhouzhao@126.com)
Henan Cancer Hospital https://orcid.org/0000-0003-4693-4063

Research

Keywords: Colon cancer, Tunnel approach, Laparoscopic surgery, Right hemicolectomy, safety

Posted Date: April 20th, 2020

DOI: https://doi.org/10.21203/rs.3.rs-22217/v1

Abstract

Background: Although Multiple studies showed that the median approach is nowadays the most widely accepted approach according to the “no-touch” principle and safety. However, this approach is a demanding procedure with a steep learning curve and has a high rate of conversion to laparotomy. This aim is to explore the feasibility and safety of tunnel approach in laparoscopic radical right hemicolectomy for colon cancer.

Methods: From July 2016 to October 2018, a total of 106 consecutive patients with colon cancer who were subjected to the laparoscopic radical right hemicolectomy in the affiliated cancer hospital of zhengzhou university were enrolled. The patients underwent either tunnel approach (TA) (n=56) or traditional medial approach (MA) (n=50) according to the surgical maneuver performed. The patients' baseline demographics and perioperative results were compared between the two groups.

Results: The baseline characteristics did not differ between groups. The blood loss was significantly less [20.0(5.0-40.0) vs. 100(50.0-150.0) , $p < 0.001$] and operation time was significantly shorter [128.4±16.7 vs. 145.6±20.3min, $p < 0.001$]in the TA group than those in MA group. Time to first flatus and postoperative hospital stay were similar [3.0(2.0-4.0) vs. 3.0(3-4.0)d, $p=0.329$; 10.4±2.6 vs. 10.7±3.0d, $p=0.506$] in both groups. The conversion to laparotomy and complication rates were similar between the groups(0 vs. 6.0%, $p = 0.203$; 14.3% vs. 18.0%, $p =0.603$,respectively). There was no treatment-related death in both groups.

Conclusions: The tunnel approach in laparoscopic radical right hemicolectomy for colon cancer is a technically feasible and safe procedure as a preferable approach at present compared to those of medial approach, meanwhile this method is easier for beginners to master. Hence this tunnel approach right hemicolectomy is worth recommended.

Introduction

Laparoscopic right hemicolectomy was first recommended by Since Jacobs et al[1] in 1990s, laparoscopic radical right hemicolectomy has become the standard procedure for the treatment of right-sided colon cancer with better short-term outcomes and comparable effectivity and safety compared with laparotomy[2–4]. Hohenberger et al[5] also recommended the concept of complete mesocolic excision (CME) with high arterial ligation in 2009. Recent studies have confirmed that CME approach can obtain more thorough lymph node dissection and better oncological outcomes, without increasing the risk of complications[6–8].

Although Multiple studies showed that the various approach being acceptable currently achieve different advantages respectively, the median approach is nowadays the most widely accepted approach according to the “no-touch” principle and safety[9–13]. However, the medial-to-lateral approach laparoscopic right hemicolectomy is a demanding procedure with a steep learning curve and has a high

rate of conversion to laparotomy, the main reason is anatomic complexity numerous variation of right colonic vessels[14, 15]. Thus, we design the tunnel type lower right approach to finish the complete mesocolic excision (CME) based on the operation idea of "Easier surgery" and have achieved satisfactory clinical results[16]. The aim of this study is to compare the surgical feasibility and safety with this new surgical approach performed.

Methods

Search strategy

A total of 106 consecutive patients with colonic cancer who underwent the laparoscopic radical right hemicolectomy were included in the affiliated cancer hospital of zhengzhou university from July 2016 to October 2018. The patients underwent either tunnel approach (TA) (n=56) or traditional medial approach (MA) (n=50) according to the surgical maneuver performed at that time. Inclusion criteria: 1)Eligible patients were diagnosis as right-sided colonic cancer with clinical stage I-III at preoperative examination by colonoscopy and abdominal enhanced computed tomography (CT); 2)Single tumor in ileocecum, ascending colon, hepatic flexure or right transverse colon; 3)Tumor size ≤10 cm in the intraoperative laparoscopic exploration; 4) Diagnosis with adenocarcinoma of the colon were considered; 5) The tumor did not invade adjacent organs. Exclusion criteria: 1) Patients have received the neoadjuvant therapy; 2) Patients with distant metastases confirmed by imaging; 3) Preoperative symptoms of intestinal obstruction; 4) Laparoscopy cannot be tolerated due to the other organ dysfunction. We used the NCCN guidelines for colon cancer (v.1.2019)[17] to evaluate TNM staging. The study was conducted in accordance with the principles of the Declaration of Helsinki, and the study protocol was approved by the ethics committee of affiliated cancer hospital of zhengzhou university. Because of the retrospective nature of the study, patient consent statement is waived.

Operative approach

1. TA group: 56 patients underwent the tunnel approach

First: separate the attachment of the terminal ileum from the posterior peritoneum

The patient was placed in the Trendelenburg position at 15 to 30° and the body titled to the left by 15° to facilitate the small intestine falling on the left side of the abdominal cavity. The terminal ileum was separated from the posterior peritoneum to reach the peritoneum of ileocecus on the lateral side and the superior mesenteric artery trunk on the medial side. (figure 1)

Second: dissociate the tissue cephalad along the Toldt’s gap

Toldt’s gap was entered along the incision. Dissociate the Toldt’s gap cephalad, then the right mesocolon was separated from the retroperitoneum. The mesocolon of right hemicolon from the surface of duodenum and pancreas head was separated bluntly and sharply until the duodenal bulb. (figure 2)

Third: dissociate hepatic flexure to the right until white line of Toldt

Place the patient to the dorsal elevated position of 15 to 30° and tilt to the left by 15° to expose the gastric colon ligament. The gastrocolic omentum was incised at the place where the transverse colon is pre-resected. The hepatic flexure was dissociated to the right until white line of Toldt simultaneously(tissue is dissociated in or out of the gastroomental vascular arch according to the location of the tumor: tissue is dissociated out of the arch without dissecting the No.6 lymph nodes when cancer was located at ileocecus or ascending colon and in the arch close to the gastric wall with dissecting the No.6 lymph nodes when cancer was located at hepatic flexure or transverse colon near hepatic flexure). (figure 3)

Fourth: expose and incise the blood vessels along trunk of the superior mesenteric artery and vein

The ileocolic mesenteric avascular zone was incised below the ileocolic vessel, the root of ileocolic vessel was exposed from the right side of the superior mesenteric vein. Then the ileocolic artery and vein, right colonic artery and vein, middle colonic artery(or its right branch) and vein and gastric colon vein trunk (or its colonic branch) were exposed and divided along the trunk of the superior mesenteric artery and vein(Each patient may has the different vascular variant)figure 4 and 5

Last: remove the specimen completely and digestive tract reconstruction

The lateral peritoneum was dissociated sharply along the paracolic sulcus of ascending colon, then the specimen was removed completely. An approximate 6 cm incision was made approximately 2 cm above the umbilicus. (the length of the incision depended on the size of the cancer). The incision was opened and protected with an incision protector, an extracorporeal functional ileal transverse anastomosis was performed via incision. Then abdominal cavity was irrigated with distilled water at 43°C and two abdominal drainage tubes were inserted prior to abdominal closure. (figure 6)

2. MA Group: 50 patients underwent the traditional medial-to-lateral approach

(1) Expose and incise the mesenteric vessels

The ascending mesocolon is incised along the left side of the superior mesenteric vein at the root of the ileocolic vascular to enter Toldt’s gap. Then dissected cephalad along the superior mesenteric vein until the lower edge of pancreatic neck with crossing the front of the horizontal segment of duodenum and pancreatic uncinate. Then the ileocolic artery and vein, right colonic artery and vein, middle colonic artery (or its right branch) and vein and gastric colon vein trunk (or its colonic branch) were exposed and divided along the trunk of the superior mesenteric artery and vein. So far, the dissection of the right mesenteric vessel and surrounding lymph nodes has been completed.

(2) Dissociate of mesocolon completely

The ascending mesentery was incised close to the right side of the mesenteric vein to enter the Toldt's gap. then dissociated Toldt's gap rightwards until the right white line of Toldt, cephalad until the root of transverse mesocolon with crossing the junction of duodenal descending and horizontal segments, caudalwards until the root of the ileal mesentery. Thus, the right colonic mesentery was separated from retroperitoneum completely.

(3) Dissociate colonic lateral peritoneum

The gastrocolic omentum was incised at the place where the transverse colon is pre-resected, the hepatic flexure was dissociated rightwards (Notices are the same as TA Group). The right white line of Toldt was incised caudalwards from the hepatic flexure to the cecum, the right colon and its corresponding mesentery were dissociated completely.

(4) remove the specimen completely and digestive tract reconstruction

The operation was performed as the same as the procedures in the TA group.

Statistical analysis

All statistical data was analyzed with SPSS 22.0. The continuous variables were expressed as the mean ± standard deviation (SD) with using the t test or the median (interquartile range (IQR)) with using the rank-sum test between groups according to

Whether they fit the normal distribution. Chi-square test or Fisher's exact test was used for categorical variables. We define the p value < 0.05 as a statistically significant difference.

Results

Clinicopathologic characteristics

The mean age was 57 years (29-84 years). A total of 55 were males and 51 were females. Among the 106 patients, the tumor locations were ileocecus (20, 18.9%), ascending colon (56,52.8%), hepatic flexure (18,17.0%) and right transverse colon (12,11.3%). According to NCCN guidelines for colon cancer (v.1.2019), The TNM staging were confirmed by enhanced CT in TNM I (13, 12.3%), TNM II (55, 51.9%) and TNM III (38, 35.8%). The histological type of humor included highly differentiated adenocarcinoma (2,1.9%), moderately differentiated adenocarcinoma (61, 57.5%), poorly differentiated adenocarcinoma (35,33.0%) and mucinous adenocarcinoma (8,7.5%). The baseline demographics were similar between the two groups. (Table 1)

Operative outcomes

All 106 cases were completed laparoscopic radical right hemicolectomy successfully and confirmed R0 resection by postoperative pathology results. The mean operative time had a significant advantage in the TA group compared with MA group (128.4±16.7 vs. 145.6±20.3min, p0.001). Meanwhile, intraoperative

blood loss was significantly lower in the TA group than in the MA group [20.0(5.0-40.0) vs 100(50.0-150.0) ml, $p < 0.001$]. There was no statistically significant difference in tumor size and lymph node yield. There were three patients (6.0%) required conversion to laparotomy only in the MA group, the reasons were severe adhesion in one patient and intraoperative uncontrolled intraoperative bleeding in two patients. (Table 2)

Postoperative recovery

Time to first flatus (3.0(2.0-4.0) vs 3.0(3.0-4.0)d p=0.329) and length of hospital stays (10.4±2.6 vs 10.7±3.0d, p=0.506) had no statistically significant differences in TA group and MA group. The postoperative complications rate was similar both the groups (8 patients (14.3%) vs. 9 patients (18.0%), p=0.603). There was 1 patient (1.8%) experienced major complications in the TA group (ileus) and 2 patients (4.0%) in the MA group (anastomotic stenosis, ileus in one patient each) (p =0.921). there isn't mortality within 30d after surgery in the two groups. 92 patients were treated with adjuvant chemotherapy. (Table 2)

Discussion

In the 1980s, proximal and distal margins of the colonic tumor should be resected at least 5-10cm long with corresponding mesenterium according to JGR[18]. Hohenberger et al[5] also recommended the concept of complete mesocolic excision (CME) in 2009, CME has become a standard procedure as a novel concept for colectomy.

Laparoscopic right hemicolectomy could be performed with less bleeding, less trauma, rapider recovery of gastrointestinal function and shorter postoperative hospital stay compared with traditional laparotomy[19]. But mastery of the laparoscopic approach demanded a steep learning curve[20]. Therefore, numerous studied explored different surgical approaches and tried to find a better one. Jie Ding et al shown that the medial approach is a preferable approach at present[21].

Kuzu et al[22] showed different variation of right colonic vessels is an important reason for the long learning curve of laparoscopic approach. For experienced surgeon, it is not difficult to expose the superior mesenteric vein completely, but it is hard for beginners to master. Dissecting the root of the right gastroepiploic artery is very difficult in the medial approach with causing the hemorrhage and more serious consequences. During the laparoscopic right hemicolectomy, it is the key that how to enter the anatomical plane faster and more accurately to expose the gastrocolic trunk. We summarize the tunnel operation method on the basis of various clinical procedures[23, 24]. The tunnel method starts from the attachment of ileocecal region and the retroperitoneal, so that Toldt's gap can be entered easily the regardless of their bodily form. This approach can also prevent beginners from dissociating superior mesenteric vessels at first. This tunnel approach is to convert the anatomy from two-dimensional to three-dimensional, so the superior mesentery vessels were exposed more easily after dissociating right

mesentery completely, which reduces the risk of bleeding and conversion rate and is easier for beginners to master.

In the present study, intraoperative blood loss and operation time in TA group were Significantly better than those in MA group. Although there was no statistical significance, the conversion and postoperative major complication rates were lower in the TA group compared with the MA group in the present study. Reduced risk of severe complications and conversion is potential advantages of tunnel approach laparoscopic colectomy compared with medial approach. Meanwhile the difference may be caused by a small sample size, which needs to be further confirmed by large sample studies. Conversion rates in randomized controlled trials comparing laparoscopic with other approaches colectomy ranged from 0% to 18.1%[25-26]. The cause of conversion in laparoscopic colectomy for cancer included tumor invasion, abdominal adhesions, intraoperative bleeding, anatomical complexity and so on[27-29]. Tarnowski et al[30] showed the main cause of conversion is local tumor progression. In the present study, two of the three conversions due to uncontrolled bleeding occurred during dissection of superior mesenteric artery, which is considered a complicated operation in laparoscopic procedure. The difference between the results of the study and the results of previous studies may also be caused by insufficient sample size.

We should pay attention to the following points during the operation: 1. Don't dissociate too deeply to avoid injuring ureter and gonad vessels in the procedure; 2. After entering the Toldt’s gap, the ultrasonic scalpel dissociates the complete anatomical plane close to the mesocolon. 3. Adopt the blunt dissociation mainly and sometimes sharp dissociation to protect duodenum carefully. 4. When dissociating liver flexure, avoid entering Gerota fascia to injure the right kidney by putting a gauze at the root of the transverse mesocolon.

Meanwhile, this study is subject to several limitations. Firstly, observation or nonexperimental method are the inherent weaknesses of retrospective design. Secondly, the findings may lack generalizability due to the relatively small number of cases. The long-term outcomes of randomized clinical trials require further confirmation with large number of cases and multicenter studies.

Conclusion

This study suggests that the tunnel approach in laparoscopically assisted radical right hemicolectomy is a technically feasible and safe procedure. It can significantly reduce the operation time and intraoperative blood loss, and has the advantages of lower conversion and complication rates and shorter learning curve compared with traditional middle approach in laparoscopic right hemicolectomy. Therefore, this new surgical approach in right hemicolectomy is recommended.

Declarations

Supplementary information

No

Ethics approval and consent to participate

The study was conducted in accordance with the principles of the Declaration of Helsinki, and the study protocol was approved by the ethics committee of affiliated cancer hospital of zhengzhou university. Because of the retrospective nature of the study, patient consent statement is waived.

Consent for publication

Not applicable

Availability of data and materials

Data are available on reasonable request from the authors.

Competing interests

The authors declare that they have no competing interests

Funding/Support

We have received no funding for this study.

Authors' contributions

All authors participated in the study. GSH and YZZ contributed to the conception and design of the research, XJZ and JLZ contributed to the acquisition of the data, JLZ, SL and YZZ contributed to the analysis and interpretation of the data, PFM, SL, YHC and CYL contributed to the statistical analysis. XJZ, JLZ and YZZ contributed to the drafting of the manuscript. SL and YZZ contributed to the revision of the manuscript. All authors read and approved the final manuscript.

Acknowledgements

The authors acknowledge the following participating investigators who allowed their clinical experience to be included in this study: Yiping Jiao, Department of General Surgery, Affiliated Cancer Hospital of Zhengzhou University (Zhengzhou); Chao Liu, Institute of Hematology and Blood Diseases Hospital (Tianjin)

References

[1] Jacobs M, Verdeja J C, Goldstein H S. Minimally invasive colon resection (laparoscopic colectomy). Surg Laparosc Endosc 1991;1:144-50.

[2] Clinical Outcomes of Surgical Therapy Study Group, Nelson H, Sargent D J, Wieand H S, Fleshman J, Anvari M, et al. A comparison of laparoscopically assisted and open colectomy for colon cancer. N Engl J Med 2004;350:2050-9.

[3] Colon Cancer Laparoscopic or Open Resection Study Group, Buunen M, Veldkamp R, Hop W C, Kuhry E, Jeekel J, et al. Survival after laparoscopic surgery versus open surgery for colon cancer: long-term outcome of a randomised clinical trial. Lancet Oncol 2009;10:44-52.

[4] Shin J K, Kim H C, Lee W Y, Yun S H, Cho Y B, Huh J W, et al. Laparoscopic modified mesocolic excision with central vascular ligation in right-sided colon cancer shows better short- and long-term outcomes compared with the open approach in propensity score analysis. Surg Endosc 2018;32:2721-31.

[5] Hohenberger W, Weber K, Matzel K, Papadopoulos T, Merkel S. Standardized surgery for colonic cancer: complete mesocolic excision and central ligation--technical notes and outcome. Colorectal Dis 2009;11:354-64; discussion 364-5.

[6] West N P, Hohenberger W, Weber K, Perrakis A, Finan P J, Quirke P. Complete mesocolic excision with central vascular ligation produces an oncologically superior specimen compared with standard surgery for carcinoma of the colon. J Clin Oncol 2010;28:272-8.

[7] Bertelsen C A, Neuenschwander A U, Jansen J E, Wilhelmsen M, Kirkegaard-Klitbo A, Tenma J R, et al. Disease-free survival after complete mesocolic excision compared with conventional colon cancer surgery: a retrospective, population-based study. Lancet Oncol 2015;16:161-8.

[8] Pedrazzani C, Lazzarini E, Turri G, Fernandes E, Conti C, Tombolan V, et al. Laparoscopic Complete Mesocolic Excision for Right-Sided Colon Cancer: Analysis of Feasibility and Safety from a Single Western Center. J Gastrointest Surg 2019;23:402-7.

[9] Li F, Zhou X, Wang B, Guo L, Wang J, Wang W, et al. Comparison between different approaches applied in laparoscopic right hemi-colectomy: A systematic review and network meta-analysis. Int J Surg 2017;48:74-82.

[10] Matsuda T, Iwasaki T, Mitsutsuji M, Hirata K, Maekawa Y, Tanaka T, et al. Cranial-to-caudal approach for radical lymph node dissection along the surgical trunk in laparoscopic right hemicolectomy. Surg Endosc 2015;29:1001.

[11] Zou L, Xiong W, Mo D, He Y, Li H, Tan P, et al. Laparoscopic Radical Extended Right Hemicolectomy Using a Caudal-to-Cranial Approach. Ann Surg Oncol 2016;23:2562-3.

[12] Bergamaschi R, Schochet E, Haughn C, Burke M, Reed J F 3rd, Arnaud J P. Standardized laparoscopic intracorporeal right colectomy for cancer: short-term outcome in 111 unselected patients. Dis Colon Rectum 2008;51:1350-5.

[13] Du S, Zhang B, Liu Y, Han P, Song C, Hu F, et al. A novel and safe approach: middle cranial approach for laparoscopic right hemicolon cancer surgery with complete mesocolic excision. Surg Endosc 2018;32:2567-74.

[14] Ye K, Lin J, Sun Y, Wu Y, Xu J, He S. Variation and treatment of vessels in laparoscopic right hemicolectomy. Surg Endosc 2018;32:1583-4.

[15] Lee S J, Park S C, Kim M J, Sohn D K, Oh J H. Vascular Anatomy in Laparoscopic Colectomy for Right Colon Cancer. Dis Colon Rectum 2016;59:718-24.

[16] Zhang X J, Zhang J L, Li S, Ma P F, Zhao Y Z. A tunnel approach in laparoscopically assisted radical right hemicolectomy - a video vignette. Colorectal Dis 2020. (in press).

[17] Colon Cancer, Version 1.2019, NCCN Clinical Practice Guidelines in Oncology.

[18] General rules for clinical and pathological studies on cancer of the colon, rectum and anus. Part I. Clinical classification. Japanese Research Society for Cancer of the Colon and Rectum. Jpn J Surg 1983;13:557-73.

[19] Negoi I, Hostiuc S, Negoi R I, Beuran M. Laparoscopic vs open complete mesocolic excision with central vascular ligation for colon cancer: A systematic review and meta-analysis. World J Gastrointest Oncol 2017;9:475-91.

[20] Kim J, Edwards E, Bowne W, Castro A, Moon V, Gadangi P, et al. Medial-to-lateral laparoscopic colon resection: a view beyond the learning curve. Surg Endosc 2007;21:1503-7.

[21] Ding J, Liao G Q, Xia Y, Zhang Z M, Pan Y, Liu S, et al. Medial versus lateral approach in laparoscopic colorectal resection: a systematic review and meta-analysis. World J Surg 2013;37:863-72.

[22] Kuzu M A, İsmail E, Çelik S, Şahin M F, Güner M A, Hohenberger W, et al. Variations in the Vascular Anatomy of the Right Colon and Implications for Right-Sided Colon Surgery. Dis Colon Rectum 2017;60:290-8.

[23] Yamaguchi S. Laparoscopic right hemicolectomy with intracorporeal anastomosis. Tech Coloproctol 2010;14:365.

[24] Yang X, Wu Q, Jin C, He W, Wang M, Yang T, et al. A novel hand-assisted laparoscopic versus conventional laparoscopic right hemicolectomy for right colon cancer: study protocol for a randomized controlled trial. Trials 2017;18:355.

[25] Waters P S, Cheung F P, Peacock O, Heriot A G, Warrier S K, O'Riordain D S, et al. Successful patient-oriented surgical outcomes in robotic vs laparoscopic right hemicolectomy for cancer - a systematic review. Colorectal Dis 2019.

[26] Tekkis P P, Senagore A J, Delaney C P, Fazio V W. Evaluation of the learning curve in laparoscopic colorectal surgery: comparison of right-sided and left-sided resections. Ann Surg 2005;242:83-91.

[27] Zarzavadjian le Bian A, Genser L, Denet C, Ferretti C, Laforest A, Ferraz J M, et al. Safety and feasibility of repeat laparoscopic colorectal resection: a matched case-control study. Surg Endosc 2019.

[28] Ardu M, Bergamini C, Martellucci J, Prosperi P, Valeri A. Colonic splenic flexure carcinoma: is laparoscopic segmental resection a safe enough oncological approach. Surg Endosc 2019.

[29] Scotton G, Contardo T, Zerbinati A, Tosato S M, Orsini C, Morpurgo E. From Laparoscopic Right Colectomy with Extracorporeal Anastomosis to Robot-Assisted Intracorporeal Anastomosis to Totally Robotic Right Colectomy for Cancer: The Evolution of Robotic Multiquadrant Abdominal Surgery. J Laparoendosc Adv Surg Tech A 2018;28:1216-22.

[30] Tarnowski W, Uryszek M, Grous A, Dib N. Intraoperative difficulties and the reasons for conversion in patients treated with laparoscopic colorectal tumors. Pol Przegl Chir 2012;84:352-7.

Tables

Table 1 Clinical characteristics of patients

Variable	TA Group (n=56)	MA Group (n=50)	χ2 or t test	*p* value
Gender, n (%)			χ2=0.641	0.423
Male	27(48.2)	28(56.0)		
Female	29(51.8)	22(44.0)		
Age(years), means ± SD	58.4±12.0	56.0±11.5	t=1.019	0.310
BMI (kg/m^2), means ± SD	23.0±2.8	23.4±2.7	t=0.816	0.417
TNM Stage, n (%)			Z=0.144	0.886
Ⅰ	6(4.8)	7(8.9)		
Ⅱ	31(66.7)	24(51.1)		
Ⅲ	19(28.5)	19(40)		
Location, n (%)			χ2=3.833	0.280
Ileocecus	14(28.6)	6(13.3)		
Ascending colon	29(42.9)	27(53.3)		
Hepatic flexure	7(16.7)	11(20)		
Right transverse colon	6(11.8)	6(13.3)		
Differentiation, n (%)			χ2=0.065	0.996
Highly differentiated	1(2.4)	1(2.2)		
Moderately differentiated	32(52.4)	29(55.6)		
Poorly differentiated	19(38.1)	16(33.3)		
Mucinous	4(7.1)	4(8.9)		

TA tunnel approach, MA medial approach.

Table 2 Perioperative results

Variable	TA Group (n=56)	MA Group (n=50)	χ2, t or Z	*p* value
Blood loss (ml), median (IQR)	20.0(5.0-40.0)	100(50.0-150.0)	Z=7.137	< 0.001
Operation time(min), means ± SD	128.4±16.7	145.6±20.3	t=4.784	< 0.001
Cancer size(cm), median (IQR)	4.0(3.5-5.5)	5.0(3.5-6.0)	Z =1.490	0.136
Intraoperative conversion, n (%)	0	3(6.0%)	χ2=1.620	0.203
Lymph node harvest, median (IQR)	29.5(18.0-41.8)	26.0(18-35)	Z =0.874	0.382
The first flatus(d), median (IQR)	3.0(2.0-4.0)	3.0(3.0-4.0)	Z=0.976	0.329
Postoperative hospitalization(d), means ± SD	10.4±2.6	10.7±3.0	t=0.667	0.506
Complication, n (%)	8(14.3%)	9(18.0%)	χ2=0.271	0.603
Pneumonia	6	4		
Ileus	2	3		
Wound infection	0	1		
Anastomotic stenosis	0	1		

TA tunnel approach, MA medial approach, IQR inter-quartile range.

Figures

Figure 1

separate the attachment of the terminal ileum from the posterior peritoneum

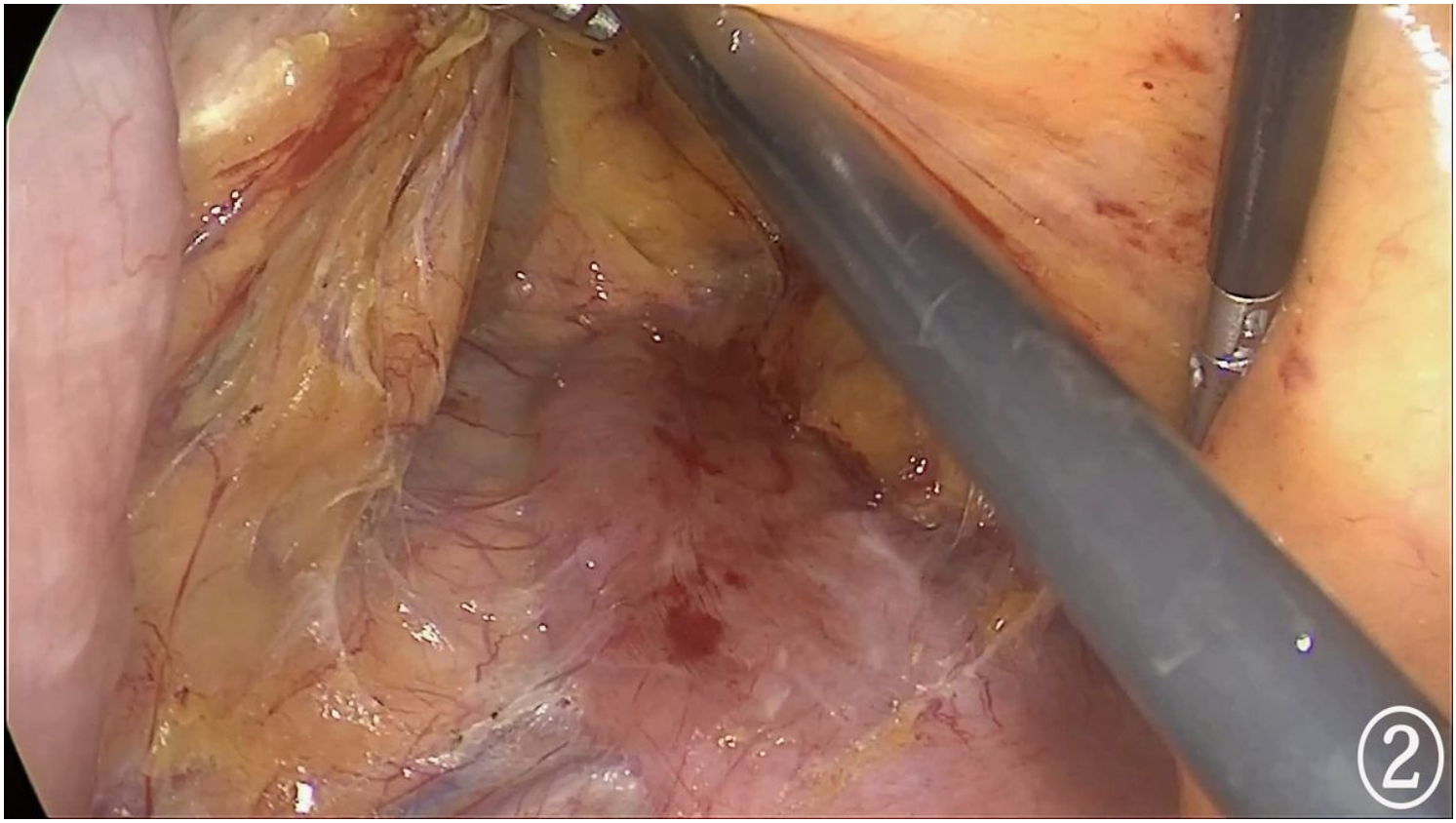

Figure 2

dissociate the Toldt's gap cephalad

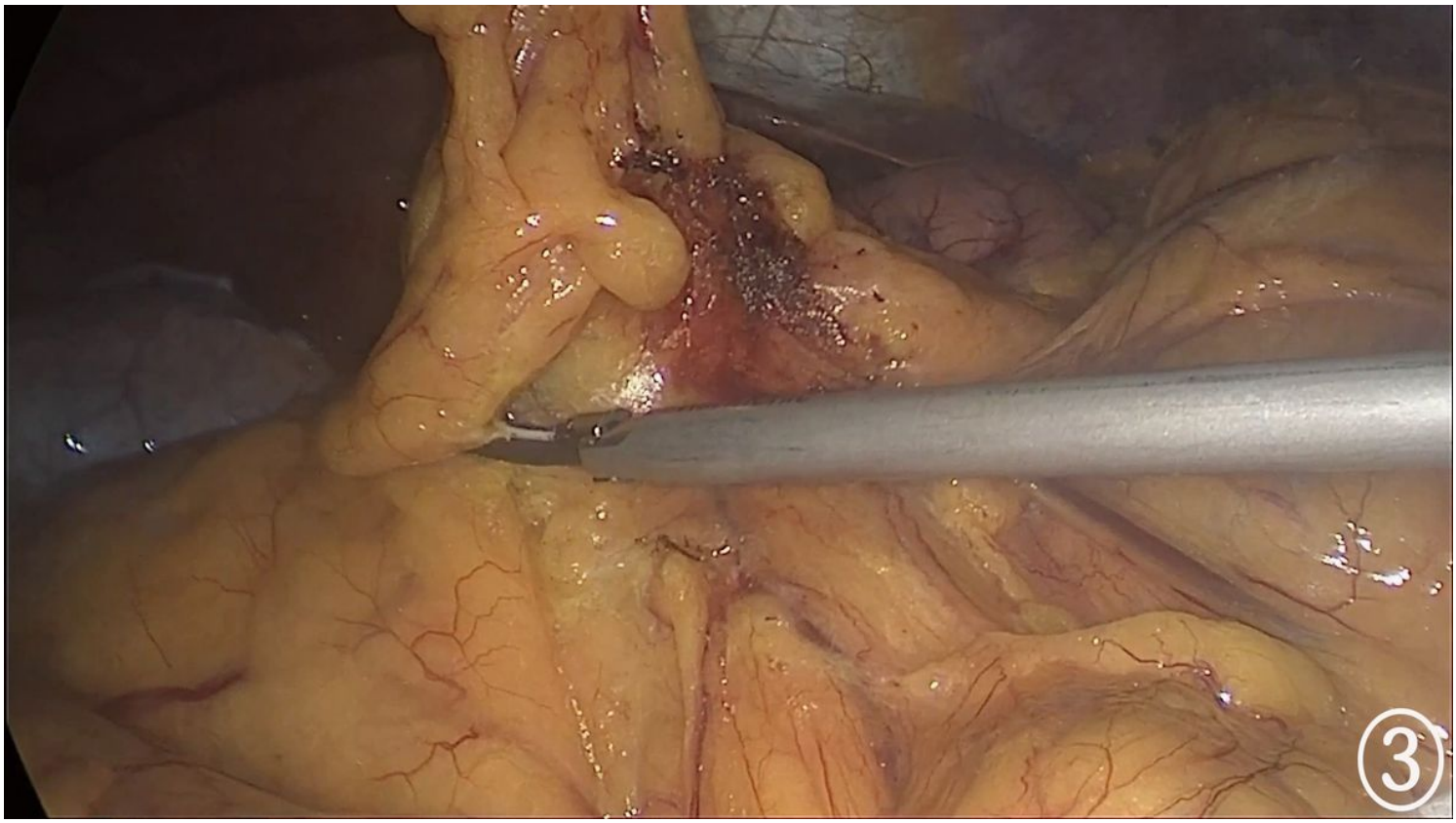

Figure 3

dissociate hepatic flexure to the right

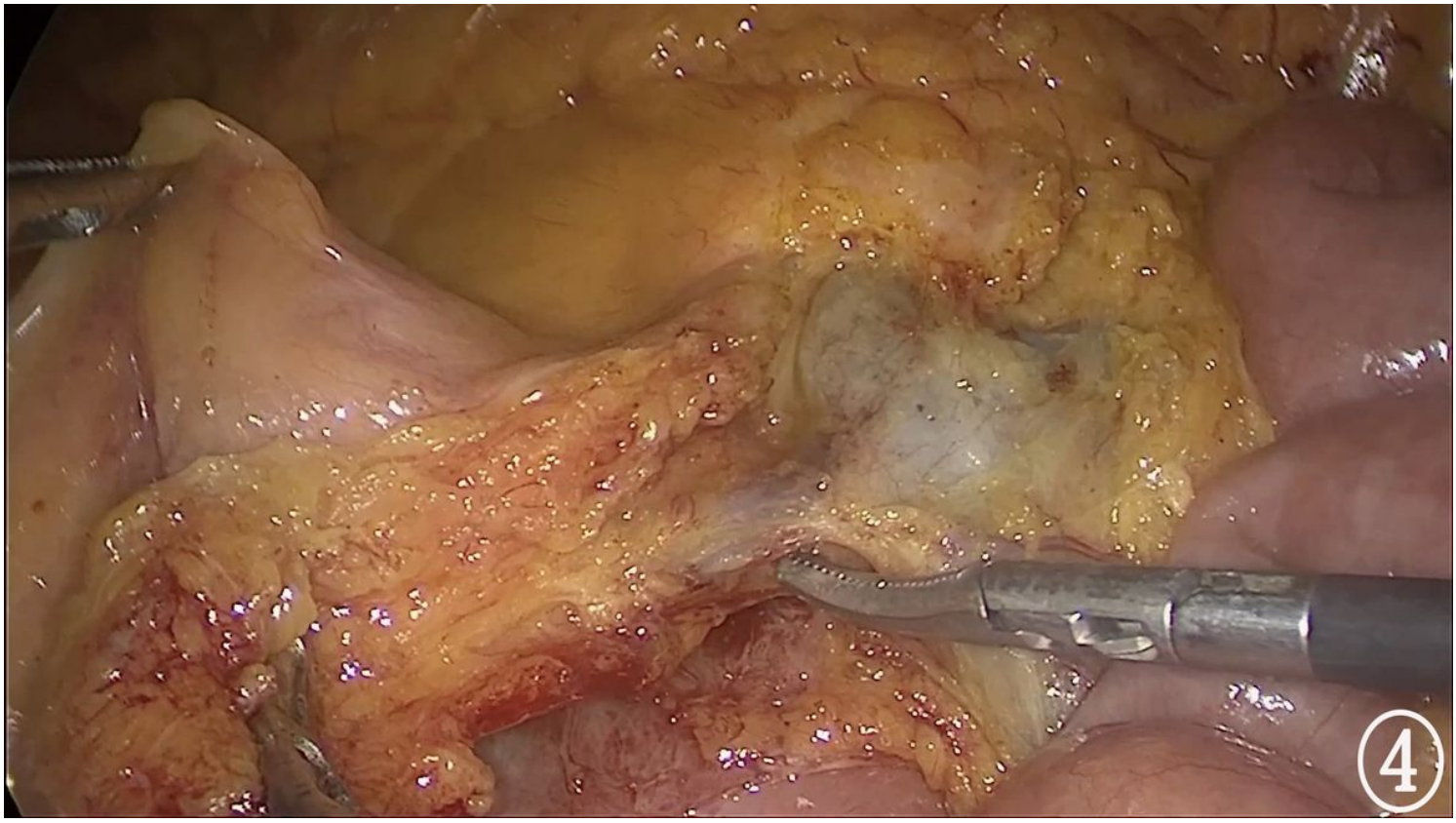

Figure 4

expose trunk of the superior mesenteric vein

Figure 5

complete exposing and dividing vascular branches along the trunk of the superior mesenteric vessel

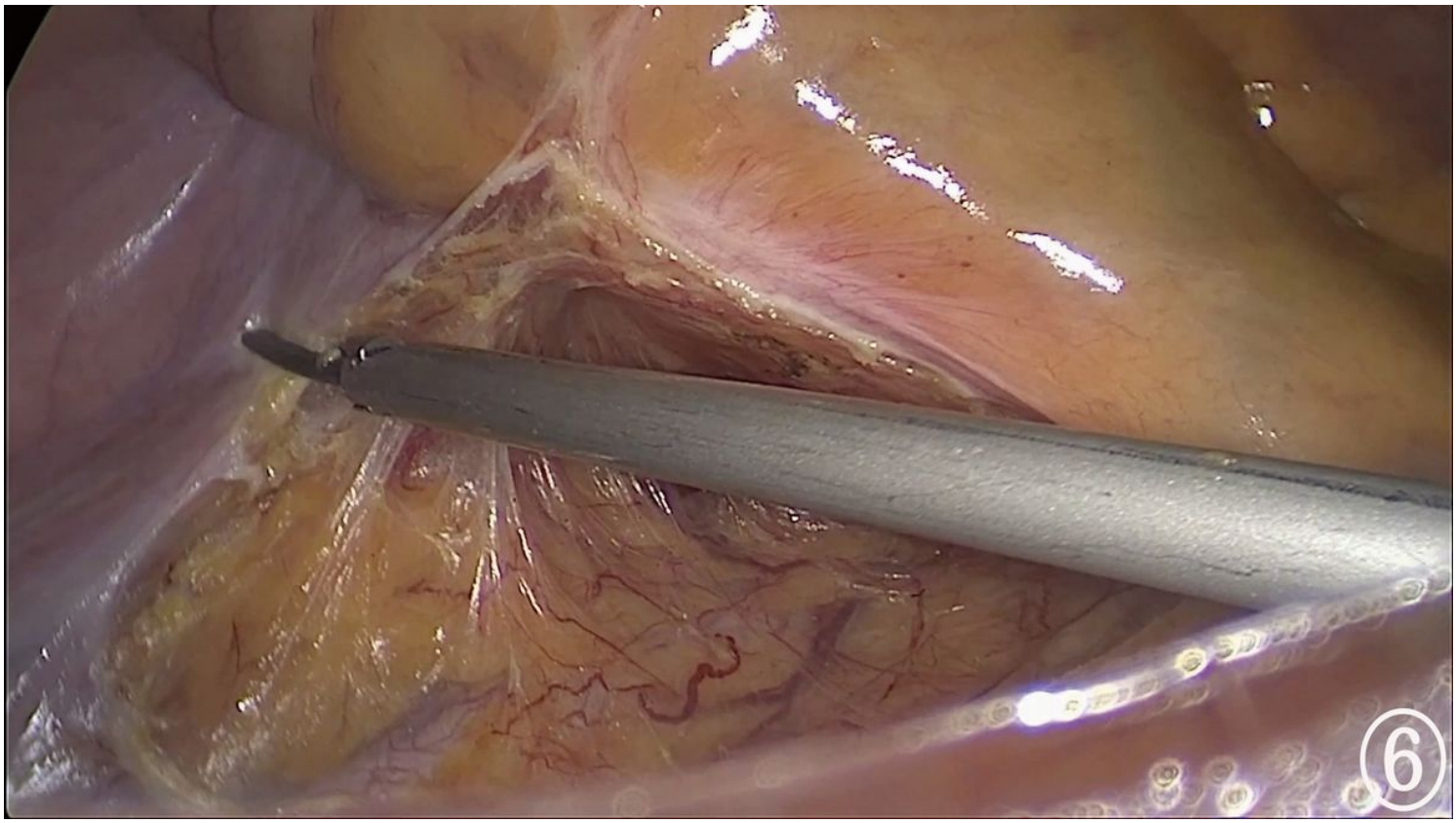

Figure 6

complete exposing and dividing vascular branches along the trunk of the superior mesenteric vessel