Analysis of retinal detachment after post-operative endophthalmitis treated with 23G Pars Plana Vitrectomy

Ying Zheng (anniaannia@126.com)
Shanghai General Hospital affiliated to Shanghai Jiaotong University

Maria Casagrande
University Medical Center Hamburg-Eppendorf

Spyridon Dimopoulos
Eberhard Karls University Medical Center, Tübingen

Ulrich Bartz-Schmidt
Eberhard Karls University Medical Center, Tübingen

Martin Spitzer
University Medical Center Hamburg-Eppendorf

Christos Skevas
University Medical Center Hamburg-Eppendorf

Research Article

Keywords: Endophthalmitis, Retinal detachment, Pars plana vitrectomy, 23 Gauge

Posted Date: February 23rd, 2021

DOI: https://doi.org/10.21203/rs.3.rs-223374/v1

Abstract

Background

To evaluate the rate, risk factors, functional outcome and prognosis in eyes with retinal detachment after post-operative endophthalmitis treated with 23G pars plana vitrectomy.

Methods

Electronic patient files from 2009 until 2018 were screened for the presence of an endophthalmitis. Included were 116 eyes of 116 patients. This population was evaluated for the rate of retinal detachment after 23G Pars Plana Vitrectomy for endophthalmitis following cataract surgery or intravitreal injection. The main outcome measures are retinal detachment and visual acuity.

Results

Reason for endophthalmitis was previous cataract surgery in 78 patients and following intravitreal injection in 38 patients. First clinical evidence of endophthalmitis was present in median 5 days after the triggering surgery. Twenty-five eyes (21.55%) developed a retinal detachment in average 25 days after endophthalmitis. RD is significantly associated with preoperative visual acuity ($p = 0.001$).

Conclusions

Modern 23G vitrectomy technique seems not to lower the rate of retinal detachment after vitrectomy for endophthalmitis. And we also emphasize the prognostic role of preoperative visual acuity in RD development of the endophthalmitis treated with 23G pars plana vitrectomy.

Background

Endophthalmitis (EO) is a severe intraocular inflammatory response. It is typically divided into exogenous, endogenous (systemic infection in an immune-compromised patient), or masquerade syndromes (large cell lymphoma). Exogenous is mostly postoperative (e.g., cataract surgery), but may also be post-traumatic or related to organisms with an ability to penetrate intact corneas. It can be classified as either culture-positive or culture-negative (sterile) [1,2]. and further stratified into an acute form (within 6 weeks after surgery) which is the most common [3] and a delayed-onset form (more than 6 weeks after surgery).

Whatever form it may assume, EO is a serious and dangerous ocular condition and can be very challenging for the vitreoretinal surgeon because visibility can be severely compromised due to corneal edema, anterior chamber cells and non-transparent vitreous [4]. The toxins produced by the infecting

pathogens and the resulting inflammatory responses can be destructive for the retina and lead to complications like retinal necrosis [4] or photoreceptor damage to the retina [5].

Retinal detachment (RD) is a complication of both EO and the surgical procedures used in its treatment. The rate of RD in the management of EO varies between 9 and 21% [6–9]. RD was related to capsular rupture, noxious bacteria and an early additional procedure in the Endophthalmitis Vitrectomy Study (EVS). It led to a poor visual prognosis, with 27% of patients achieving a final best corrected visual acuity (BCVA) of 20/40 [9].

The approach to treatment of endophthalmitis is not consistently agreed on by vitreoretinal surgeons. The treatments involve Pars Plana Vitrectomy (PPV) or intravitreal broad-spectrum antibiotics with vitreous tap/biopsy (VTB).

The main objectives of this retrospective multi-center study was to evaluate the rate and the risk factors of RD after surgical treatment of patients with severe acute exogenous postoperative endophthalmitis having no BCVA exclusion criteria and to contribute with a recommendation to the debate about what is the proper surgical strategy for these complicated cases.

Methods

In this retrospective study data of endophthalmitis patients from the departments of ophthalmology at the university clinic of Hamburg Eppendorf and the university clinic Eberhard Karls in Tübingen, Germany were evaluated.

Electronic patient files (Hamburg: IFA (ifa systems AG, Germany), Tübingen: Arzt-Informations- System (AIS)) were screened from 2009 until 2018 for the rate of EO. In both centers the study included cases which were initially treated in those clinics or operated elsewhere and referred for treatment. Included were patients with EO following cataract surgery and intravitreal injection who were treated with 23 G PPV and intravitreal medication (vancomycin 1 mg/0.1 mL and ceftazidime (2.225mg/ 0.1 mL), voriconazole (0.1 mg/0.2cc)). Patients with other reasons for EO (endogenous source, post trauma, post filtrating surgery and post PPV) and patients treated with VTB were excluded. Criteria employed to diagnose endophthalmitis were fundoscopy, ultrasound with vitreous body infiltration, pain, hypopyon, anterior chamber inflammation and medical history. Recorded parameters were patient related data, pre-existing general health conditions, EO related data, BCVA and treatment. The population was further evaluated for the rate of RD after surgical treatment of endophthalmitis.

The vitrectomy did not include a peripheral shaving of the vitreous base and a posterior vitreous detachment (PVD) was not induced in any of the cases because posterior vitreous was already detached according to surgical reports. After completion of the vitrectomy a thorough examination of the peripheral retina was performed in order to locate any retinal breaks.

The study adhered to the tenets of the Declaration of Helsinki. The study was a retrospective data collection that was anonymized at the source. The study has been reviewed and approved by the ethics committee of Hamburg (PV7372) and written consent from the patients was not needed.

Statistical analysis

All analyses were conducted using statistical software. Association was tested using the Chi-Square Test. Differences in time of factor variables were tested with McNemar Test. The distribution of quantitative variables was given as median. Twenty-five (Q25%) and seventy-five (Q75%) quartiles were calculated. Statistical significance was set at $p < 0.05$.

Results

This retrospective study included 116 eyes of 116 patients with EO. Mean age was 74 years (range 48 to 96 years). 47 patients (40.52%) were male and 69 patients (59.48%) were female. Out of these 116 patients 19% were treated for diabetes, 62.9% for arterial hypertension and 4.3% were immunosuppressed. Clinical evidence of endophthalmitis was reported in median 5 days after the causing incident (Q25: 3 days, Q75: 7.25 days).

Reason for EO was previous cataract surgery in 78 patients and following intravitreal injection in 38 patients.

Surgery was performed at the same day of presentation in both clinics. All patients were treated with PPV in combination with intravitreal antibiotics.

Preoperative visual acuity was no light perception (NLP) in n = 1, light perception (LP) n = 26, hand movement (HM) n = 50, finger counting (FC) to < 0.05 n = 19, 0.05–0.2 n = 11 and > 0,2 n = 9 patients. The distribution of preoperative visual is displayed in Fig. 1.

An anterior chamber hypopyon was present in 81.9% of the patients.

RD occurred in 25 (21.55%) eyes with endophthalmitis after an average of 25.4 ± 16.8 days. RD is statistically significant associated with preoperative visual acuity ($p = 0.001$). There is a slight tendency to lower incidence for eyes with better visual acuity (Spearman correlation rho=-0.292, $p = 0.001$). For the distribution of RD by preoperative visual acuity see Table 1.

Table 1
The rate of RD by preoperative visual acuity

Visual acuity	RD
NLP	1:1 (100%)
LP	13:26 (50%)
HM	6:50 (12%)
FC-<0.05	1:19 (5.3%)
0.05–0.2	2:11 (18.2%)
> 0.2	2:9 (22.2%)

Table 1 displays the rate of RD by preoperative visual acuity. Number of patients with RD : all patients with EO (percentage) for different visual acuity groups.

Following surgical intervention of the RD best corrected visual acuity (BCVA) improved significantly 1 month postoperative ($p = 0.023$) and stays stable until the end of the follow-up period of 3 months postoperatively ($p = 0.42$).

6 eyes (5,17%) were removed by enucleation due to phthisis bulbi. In these eyes no successful retinal reattachment was possible.

Ocular samples were obtained from vitreous sampling at the beginning of PPV. In 44.6% no growth was detected, in 50.7% gram + bacteria, in 3.1% gram – bacteria and in 1.6% fungal. No significant correlation was found between microbiological result and retinal detachment, $p = 0.28$.

There are no statistically significant differences between EO following cataract surgery and intravitreal injection. See Table 2.

Table 2
Demographic data by reason for endophthalmitis

	Reason for endophthalmitis		
	Post phaco	Post IVI	P-value
Eyes	78	38	
Patients	78	38	
Age in years (SD)	73.49 (± 9.87)	75.13 (± 9.44)	0.388[1]
Sex			0.657[2]
Male (%)	30 (38.462)	17 (44.737)	
Female (%)	48 (61.538)	21 (55.263)	
Diabetes			0.514[2]
yes (%)	13 (16.667)	9 (23.684)	
no (%)	65 (83.333)	29 (76.316)	
Arterial hypertension			1.000[2]
yes (%)	49 (62.821)	24 (63.158)	
no (%)	29 (37.179)	14 (36.842)	
Anterior chamber hypopyon			0.405[2]
yes (%)	66 (84.615)	29 (76.316)	
no (%)	12 (15.385)	9 (23.684)	
Retinal detachment			0.416[2]
yes (%)	19 (24.359)	6 (15.789)	
no (%)	59 (75.641)	32 (84.211)	
Enucleation (%)	4 (5.128)	2 (5.263)	0.999[2]
Preoperative visual acuity			0.716[2]
NLP (%)	1 (1.282)	0 (0)	
LP (%)	18 (23.077)	8 (21.053)	
HM (%)	32 (41.026)	18 (47.368)	
FC - < 0.05 (%)	12 (15.385)	7 (18.421)	

	Reason for endophthalmitis	
0.05–0.2 (%)	7 (8.974)	4 (10.526)
> 0.2 (%)	8 (10.256)	1 (2.632)

Table 2: Demographic data by reason for endophthalmitis. [1]Independent T-Test, [2]Chi-Square Test

Discussion

Infectious EO is an inflammatory reaction that poses a high risk of severe visual loss. During any intraocular procedure, prevention of EO should be a priority because of the multiple sources of contamination [10–12].

A number of authors and studies addressed the problem of RD due to EO and its surgical treatment. In the EVS, the rate of postoperative RD was 7.8% in the 20-gauge vitrectomy subgroup. Later then, due to the advancement of surgical techniques and technology, re-evaluation of this study's results is needed [13, 14].

The evolution of the PPV technique with the introduction of 23-gauge and 25-gauge systems have made surgery less invasive. Nelsen et al [6] reported RD rates of 21% after PPV treatment and 9% in eyes not treated with PPV, with an overall RD rate of 16% after surgical treatment of EO. Olson and colleagues [8] reported an overall RD rate of 10% following post-surgical treatment, with a higher rate of 14% in post PPV eyes as well and Sridhar et al reported a high RD rate of 21.4 % in cases of acute EO at the time of initial PPV or during follow up [15, 16]. Altan et al. reported that 13.8% of the subgroup treated with 20-gauge PPV led to a postoperative RD, while no RD developed in the subgroup treated with 25-gauge vitrectomy [17]. In a study by Almanjoumi et al., the rate was 10% after a 23-gauge PPV [18].

EO cases should be treated immediately after diagnosis in order to minimize retinal damage. In our study all cases were treated at the same day of presentation. Even after the inflammation has subsided, strict follow-up examinations are necessary due to onset of late RD. Cases of late RD up to a year after successful treatment of EO have been reported. This could have been caused by the production of various cytokines released into the vitreous cavity over a long period of time, due to the blood-ocular barrier breakdown. Retinal necrosis with tangential traction of retinal membranes can lead to formation of retinal breaks and rhegmatogenous RD. Tori et al reported a rapid progression of proliferative vitreoretinopathy after endogenous bacterial endophthalmitis caused by meningitis [2, 19, 20]. The results of our study can verify this point of late onset RD and of necessary strict follow ups.

The use of silicone oil has been reported by a number of authors in cases of intraoperative retinal breaks after post-surgical or following traumatic EO [21–24]. Dave et al reported high rates of RD at presentation and during follow up after initial surgery for EO. All patients with RD were treated with silicone oil and the

reattachment rates were deemed satisfactory [25]. Sridhar et al reported a high RD rate of 21.4 % in cases of acute EO at the time of initial PPV or during follow up. Silicone oil proved to be effective in stabilizing the retina but the BCVA was poor in almost all patients due to the severity of the cases [15]. Previously, due to the fear of infection behind the silicone oil bubble, there had been a reluctance to use silicone oil as a tamponade agent for EO [26]. Later, silicone oil was proved to have an antibacterial and antifungal effect in vitro. The possible mechanisms of its antimicrobial activity that were reported are nutritional deprivation and toxicity [27]. The dosage of intravitreal antibiotics in eyes treated with silicone oil injection still remains controversial. Hegazy's study demonstrated a retinal toxicity in silicone oil-filled rabbit eyes, when the full dose of intravitreal antibiotics was used [28]. Nevertheless, those results still might not apply to the human eyes. Still we believe it is wise to reduce the dose of intravitreal drugs to about 25% of the dose that is usually injected because all intravitreal drugs will only distribute in the small aqueous phase surrounding the silicone bubble.

On the microbiological side, the results of the organisms identified in our study are in accordance with other studies and there was no statistically significant correlation between the microbiological findings and the occurrence of RD or the initial BCVA (no statistical significance between Gram + bacteria and severity of EO, BCVA and rate of RD) [29, 30].

The treatment strategy of a severe EO is complicated and there is no clear protocol. Of essence is time and the goal is to evacuate the infection and administer antibiotics. The intravitreal injection of antibiotics and the vitrectomy are the standard and main therapeutic options. Every option has advantages and disadvantages. While vitrectomy allows the as complete as possible evacuation and removal of the infection, it is often not possible, since vitreoretinal surgeons and vitreoretinal operating rooms are relatively fewer. The VTB and intravitreal antibiotics injection have their own advantage. For example, they offer a smaller sample, permit earlier intravitreal antibiotics injection and microbiology tests [31]. Vitrectomy has evolved over the years after the EVS study (smaller gauges, faster surgical procedures, minimal invasive) but the rates of RD vary and can be still high in severe cases of EO as demonstrated not only from the EVS study but from other authors using modern PPV techniques (23 and 25 gauge systems) [15, 17, 18, 25].

The high rate of RD in our cohort cannot be attributed to iatrogenic intraoperative breaks or to the vitreous sampling. No shaving of the vitreous base was performed (in combination with detailed indentation search of the peripheral retina) and the posterior hyaloid was not actively detached because it was already detached in all cases. We also did not use for vitreous sampling undiluted vitreous but diluted. Chiquet et al have reported that undiluted vitreous sampling at the start of PPV leads to hypotony, with a potential risk of vitreoretinal tractions, haemorrhages and RD. This can be avoided using diluted samples, since both samples have the same microbiological efficiency using PCR [32].

In our study, retinal detachment is statistically significant associated with preoperative visual acuity, which is similar to the findings of Doft et that RD is more likely to develop in patients who have the most

severe presentation with visual acuity of LP only[9]. On the other hand, Chiquet et reported that other risk factors for RD in patients who had a vitrectomy after cataract surgery were diabetes and vasculitis [16]. Our study could not find a statistical significant correlation between microbiological findings (especially Gram + bacteria), diabetes mellitus, immunosuppression and severity of EO, and RD rate. Vitrectomy offers the advantage of as complete as possible evacuation of the infection but is associated with a spectrum of complications like RD.

One of the limitations of most of the studies in the literature today dealing with this very complex problem are the retrospective nature, lack of a defined treatment protocol, treatment by multiple vitreoretinal surgeons and exclusion of cases due to the complexity of the disease and poor visual prognosis of this condition. These facts apply to our study also, but the large number of cases, the inclusion of two retinal centers, gives us optimism that our conclusions could shed some light on this complex issue.

Conclusions

The findings of this study suggested that modern 23G vitrectomy technique seems not to lower the rate of RD after vitrectomy for endophthalmitis. The risk of retinal detachment still remains high in spite of the updated vitreoretinal techniques, especially with a higher cutting rate. And we also emphasize the prognostic role of preoperative visual acuity in RD development of the endophthalmitis treated with 23G pars plana vitrectomy, presumably due to the inflammatory effect on the vitreous and retina.

Abbreviations

AIS: Arzt-Informations- System

BCVA: Best corrected visual acuity

EO: Endophthalmitis

EVS: Endophthalmitis Vitrectomy Study

FC: Finger counting

HM: Hand movement

LP: Light perception

NLP: No light perception

PPV: Pars plana vitrectomy

PVD: Posterior vitreous detachment

RD: Retinal detachment

VTB: Vitreous tap/biopsy

Declarations

Ethics approval and consent to participate

The study adhered to the tenets of the Declaration of Helsinki. The study was a retrospective data collection that was anonymized at the source. The study had been reviewed and approved by the ethics committee of Hamburg (PV7372) and the need for written consent from the patients was waived by the ethics committee of Hamburg (PV7372).

Consent for publication

Not applicable.

Availability of data and materials

The datasets used and/or analyzed during the current study are available from the corresponding author on reasonable request.

Competing interest

The authors declare that they have no competing interests.

Funding

There was no funding received in relation to this article.

Authors' contributions

Skevas C designed the research; Dimopoulos S and Bartz-Schmidt KU collected the data; Spitzer M.S. revised the manuscript; Zheng Y and Casagrande M wrote the manuscript. All authors read and approved the final manuscript.

Acknowledgements

Not applicable.

References

1. Lee PJ, David V. Seal, and G. A. Payman. Endophthalmitis. Diagnosis and Management. Boca Raton, USA: CRC Press LLC; 2004.

2. Kimura D, Sato T, Suzuki H, Kohmoto R, Fukumoto M, Tajiri K, et al. A Case of Rhegmatogenous Retinal Detachment at Late Stage following Endogenous Bacterial Endophthalmitis. *Case reports in ophthalmology.* 2017;**8**(**2**):334–40.
3. Gower EW, Lindsley K, Nanji AA, Leyngold I, McDonnell PJ. Perioperative antibiotics for prevention of acute endophthalmitis after cataract surgery. *Cochrane Database Syst Rev.* 2013(**7**):Cd006364.
4. *Graefe's archive for clinical and experimental ophthalmology = Albrecht von Graefes Archiv fur klinische und experimentelle Ophthalmologie.* 2005;**243(12)**:1197-9.
5. Pearson JJKBBKKNA. Clinical ophthalmology: a systematic approach. 7 ed. Edinburgh ; New York: Elsevier/Saunders; 2013.
6. Nelsen PT, Marcus DA, Bovino JA. Retinal detachment following endophthalmitis. *Ophthalmology.* 1985;**92**(**8**):1112–7.
7. Lalwani GA, Flynn HW, Jr., Scott IU, Quinn CM, Berrocal AM, Davis JL, et al. Acute-onset endophthalmitis after clear corneal cataract surgery (1996–2005). Clinical features, causative organisms, and visual acuity outcomes. *Ophthalmology.* 2008;**115**(**3**):473–6.
8. Olson JC, Flynn HW, Jr., Forster RK, Culbertson WW. Results in the treatment of postoperative endophthalmitis. *Ophthalmology.* 1983;**90**(**6**):692–9.
9. Doft BM, Kelsey SF, Wisniewski SR. Retinal detachment in the endophthalmitis vitrectomy study. *Arch Ophthalmol*. 2000;**118**(**12**):1661–5.
10. de Caro JJ, Ta CN, Ho HK, Cabael L, Hu N, Sanislo SR, et al. Bacterial contamination of ocular surface and needles in patients undergoing intravitreal injections. *Retina (Philadelphia, Pa).* 2008;**28**(**6**):877–83.
11. Bhavsar AR, Googe JM, Jr., Stockdale CR, Bressler NM, Brucker AJ, Elman MJ, et al. Risk of endophthalmitis after intravitreal drug injection when topical antibiotics are not required: the diabetic retinopathy clinical research network laser-ranibizumab-triamcinolone clinical trials. *Arch Ophthalmol.* 2009;**127**(**12**):1581–3.
12. Ta CN. Minimizing the risk of endophthalmitis following intravitreous injections. *Retina (Philadelphia, Pa).* 2004;**24**(**5**):699–705.
13. Doft BH, Kelsey SF, Wisniewski SR. Additional procedures after the initial vitrectomy or tap-biopsy in the Endophthalmitis Vitrectomy Study. *Ophthalmology.* 1998;**105**(**4**):707–16.
14. Siddiqui F, Crippen C, Hutnik CM. Do we heed the endophthalmitis vitrectomy study in Canada? *Canadian journal of ophthalmology Journal canadien d'ophtalmologie.* 2002;**37**(**7**):395–8.
15. Sridhar J, Yonekawa Y, Kuriyan AE, Joseph A, Thomas BJ, Liang MC, et al. MICROBIOLOGIC SPECTRUM AND VISUAL OUTCOMES OF ACUTE-ONSET ENDOPHTHALMITIS UNDERGOING THERAPEUTIC PARS PLANA VITRECTOMY. *Retina (Philadelphia, Pa)*. 2017;**37**(**7**):1246–51.
16. Chiquet C, Aptel F, Combey-de Lambert A, Bron AM, Campolmi N, Palombi K, et al. Occurrence and risk factors for retinal detachment after pars plana vitrectomy in acute postcataract bacterial endophthalmitis. *Br J Ophthalmol.* 2016;**100**(**10**):1388–92.

17. Altan T, Kapran Z, Eser I, Acar N, Unver YB, Yurttaser S. Comparative outcomes of pars plana vitrectomy in acute postoperative endophthalmitis with 25-gauge and 20-gauge techniques. *Japanese journal of ophthalmology.* 2009;**53**(**5**):506–11.
18. Almanjoumi AM, Combey A, Romanet JP, Chiquet C. 23-gauge transconjunctival sutureless vitrectomy in treatment of post-operative endophthalmitis. *Graefe's archive for clinical and experimental ophthalmology = Albrecht von Graefes Archiv fur klinische und experimentelle Ophthalmologie.* 2012;**250**(**9**):1367–71.
19. Yonekawa Y, Chan RV, Reddy AK, Pieroni CG, Lee TC, Lee S. Early intravitreal treatment of endogenous bacterial endophthalmitis. *Clinical & experimental ophthalmology.* 2011;**39**(**8**):771–8.
20. Torii H, Miyata H, Sugisaka E, Ichikawa Y, Shinoda K, Inoue M. Bilateral endophthalmitis in a patient with bacterial meningitis caused by Streptococcus pneumoniae. *Ophthalmologica Journal international d'ophtalmologie International journal of ophthalmology Zeitschrift fur Augenheilkunde.* 2008;**222**(**5**):357–9.
21. Bartz-Schmidt KU, Bermig J, Kirchhof B, Wiedemann P, Walter P, Heimann K. Prognostic factors associated with the visual outcome after vitrectomy for endophthalmitis. *Graefe's archive for clinical and experimental ophthalmology = Albrecht von Graefes Archiv fur klinische und experimentelle Ophthalmologie.* 1996;**234 Suppl 1**:S51-8.
22. Aras C, Ozdamar A, Karacorlu M, Ozkan S. Silicone oil in the surgical treatment of endophthalmitis associated with retinal detachment. *Int Ophthalmol.* 2001;**24**(**3**):147–50.
23. Azad R, Ravi K, Talwar D, Rajpal, Kumar N. Pars plana vitrectomy with or without silicone oil endotamponade in post-traumatic endophthalmitis. *Graefe's archive for clinical and experimental ophthalmology = Albrecht von Graefes Archiv fur klinische und experimentelle Ophthalmologie.* 2003;**241**(**6**):478–83.
24. Jiang T, Jiang J, Wang R, Lei J, Zhou Y. Visual Outcomes and Prognostic Factors after Pars Plana Vitrectomy for Traumatic Endophthalmitis. *BioMed research international.* 2017;**2017**:5851318.
25. Dave VP, Pathengay A, Relhan N, Sharma P, Jalali S, Pappuru RR, et al. Endophthalmitis and Concurrent or Delayed-Onset Rhegmatogenous Retinal Detachment Managed With Pars Plana Vitrectomy, Intravitreal Antibiotics, and Silicone Oil. *Ophthalmic surgery, lasers & imaging retina.* 2017;**48**(**7**):546–51.
26. Chong LP, de Juan E, Jr., McCuen BW, 2nd, Landers MB, 3rd. Endophthalmitis in a silicone oil-filled eye. *Am J Ophthalmol*. 1986;**102**(**5**):660–1.
27. Azen SP, Scott IU, Flynn HW, Jr., Lai MY, Topping TM, Benati L, et al. Silicone oil in the repair of complex retinal detachments. A prospective observational multicenter study. *Ophthalmology.* 1998;**105**(**9**):1587–97.
28. Hegazy HM, Kivilcim M, Peyman GA, Unal MH, Liang C, Molinari LC, et al. Evaluation of toxicity of intravitreal ceftazidime, vancomycin, and ganciclovir in a silicone oil-filled eye. *Retina (Philadelphia, Pa)*. 1999;**19**(**6**):553–7.

29. Fileta JB, Scott IU, Flynn HW, Jr. Meta-analysis of infectious endophthalmitis after intravitreal injection of anti-vascular endothelial growth factor agents. *Ophthalmic surgery, lasers & imaging retina.* 2014;**45**(**2**):143–9.
30. McCannel CA. Meta-analysis of endophthalmitis after intravitreal injection of anti-vascular endothelial growth factor agents: causative organisms and possible prevention strategies. *Retina (Philadelphia, Pa)*. 2011;**31**(**4**):654–61.
31. Endophthalmitis Study Group ESoCRS. Prophylaxis of postoperative endophthalmitis following cataract surgery: results of the ESCRS multicenter study and identification of risk factors. *Journal of cataract and refractive surgery.* 2007;**33**(**6**):978–88.
32. Chiquet C, Maurin M, Thuret G, Benito Y, Cornut PL, Creuzot-Garcher C, et al. Analysis of diluted vitreous samples from vitrectomy is useful in eyes with severe acute postoperative endophthalmitis. *Ophthalmology.* 2009;**116**(**12**):2437-41.e1.

Figures

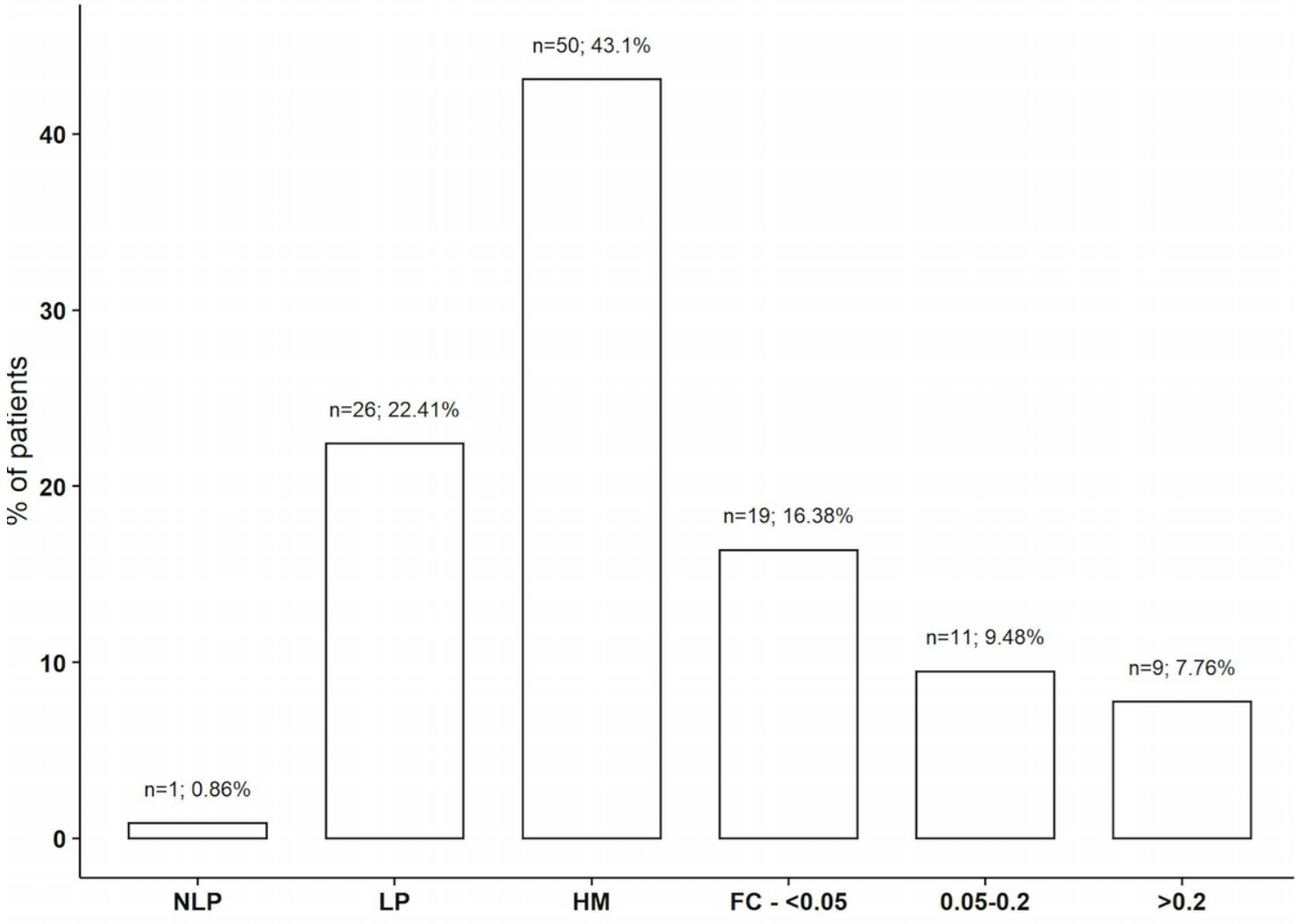

Figure 1

Distribution of preoperative visual acuity. The x-axis represents visual acuity and the y-axis the percentage of patients.