

# Long term outcome of early vitrectomy in non-diabetic, non-traumatic patients with acute posterior vitreous detachment (PVD) and vitreous hemorrhage

**Massimo Lorusso**

Ospedale Generale Regionale F Miulli: Ente Ecclesiastico Ospedale Generale Regionale Francesco Miulli

**Luisa Micelli Ferrari**

Universita degli Studi di Bari: Universita degli Studi di Bari Aldo Moro

**Marco Antonio Bordinone** (✉ [marcoab313@hotmail.it](mailto:marcoab313@hotmail.it))

University of Bari: Universita degli Studi di Bari Aldo Moro

**Giancarlo Sborgia**

Universita degli Studi di Bari Aldo Moro

**Cristiana Iaculli**

Università di Foggia: Universita degli Studi di Foggia

**Giovanni Alessio**

Universita degli Studi di Bari Aldo Moro

**Tommaso Micelli Ferrari**

Ospedale Generale Regionale F Miulli: Ente Ecclesiastico Ospedale Generale Regionale Francesco Miulli

**Francesco Boscia**

Università degli Studi di Bari: Universita degli Studi di Bari Aldo Moro

---

## Research Article

**Keywords:** Dense vitreous hemorrhage, Early vitrectomy, Etiology.

**Posted Date:** March 18th, 2021

**DOI:** <https://doi.org/10.21203/rs.3.rs-224420/v1>

**License:**   This work is licensed under a Creative Commons Attribution 4.0 International License.

[Read Full License](#)

---

# Abstract

**Objective:** Evaluate the etiologies for dense vitreous hemorrhage in pseudophakic, non-diabetic and non-traumatic adults with acute PVD and the efficiency of early vitrectomy treatment.

**Methods:** The study included 93 eyes of 93 patients and it consisted in the evaluation of etiologies of vitreous hemorrhage: retinal tears, retinal occlusion (RVO), choroidal neovascularization (CNV) and acute posterior vitreous detachment (PVD). A comparison of initial visual acuity versus final visual acuity post vitrectomy is performed.

**Results:** The mean time between symptom onset and surgery was 6.9 days. The most common etiologies observed during this study were: retinal tear (63.4%), vein occlusion (18.3%), CNV (9.7%) and PVD (8.6%). Following early vitrectomy treatment, VA significantly improved from 1.673 LogMAR to 0.220 LogMAR. In addition, the incidence of retinal tears identified preoperatively by ocular ecography were 13, but it improved to 46 during surgery.

**Conclusion:** Retinal tears, RVO, CNV and PVD were the most common causes of dense vitreous hemorrhage. Early vitrectomy has a good outcome with improvement on visual acuity and we also observed during surgery retinal tears not efficiently identified by ultrasound preoperatively.

## Introduction

Vitreous hemorrhage (VH) is an extravasation of blood into the vitreous cavity that can occur when mechanical forces cause rupture of normal or abnormal vessel (1). Based on the analysis of the previous studies literature, it can be concluded that the proliferative diabetic retinopathy (19.1% – 54.0%) and retinal tears (27%-37.3%) are the most common causes of VH (2). However vitreous hemorrhage could be frequently associated to an acute posterior vitreous detachment (PVD) and in these cases the incidence of retinal tears increases by up to 70% (3). During a PVD, vitreous traction on the retina may compromise a blood vessel, and this may happen with or without a retinal tear or retinal detachment. For this reason, vitreous hemorrhage in the setting of an acute symptomatic PVD must always alert the clinician and push him to investigate about the risk of a concurrent retinal tears or retinal detachment (4). It is not clear if the conservative management of patients affected by an acute, dense, vitreous hemorrhage with PVD is more efficient than early vitrectomy, considering the high incidence of retinal tears detection in these eyes.

Non-comparative studies investigated the appropriate patient management in eyes with an acute PVD and dense vitreous hemorrhage without leading to a standardized approach. Despite recent improvements in ophthalmologic diagnostic and surgical techniques, an acute vitreous hemorrhage

in non diabetic, non-traumatic patient often represents a medical challenge (5). This study describes the causes, as well as the final visual outcome in non diabetic patients with acute spontaneous PVD and fundus-obscuring vitreous hemorrhage, treated with early vitrectomy.

# Methods

According to the guidelines of the Declaration of Helsinki, we have adopted strict inclusion and exclusion criteria in order to make the statistical analysis as objective as possible.

It's a retrospective study that includes patients operated in the "F. Miulli Hospital", situated in Acquaviva delle Fonti (Bari-Italy) and in Ophthalmology of Policlinico di Bari (Italy) between 01/01/2018 and 31/01/2020. We considered 93 patients: 51 men (54.8%) and 42 women (45.2%) (Fig. 1) with an average age of 68,65 years old.

In order to avoid any influence during fundus examination and surgical variabilities, only pseudophakic patients presenting an acute vitreous hemorrhage dense enough to obscure the retina, were admitted to our study.

We have considered two types of fundus obscuring VH: 1) moderate VH, where optic disc and retinal vessels are barely visible; 2) severe VH, where hemorrhage is dense to avoid the visualization of optic disc.

Following patients have been excluded from the study: diabetics patients, patients on antiplatelet therapy, patients with diseases in the contralateral eye, patients with blood dyscrasias or who have other ocular diseases such as history of retinopathy, history of PDV in the affected eye, macular degeneration, ocular vascular thrombosis recent trauma.

All the patients involved underwent to a careful preoperative ophthalmic examination, i.e.: visual acuity with EDTRS charts (converted to LogMAR for statistical reasons); Ocular tonometry (Perkins Tonometer); Funduscopy by indirect ophthalmoscope; Ultrasound investigation, performed using a SONOMED V-MAX ultrasound with a 10 MHz B-probe. Blood tests have been performed on each patient to exclude diabetics patients.

In all cases the surgery was performed within seven days from the hemorrhage onset relying the idea that early vitrectomy could improve the prognosis of these patients.

After sub-Tenon's anesthesia with ropivacaine, it was performed a three ports vitrectomy (25 gauge system, Alcon Constellation System) that allowed to realize a core vitrectomy and successively a meticulous shaving of vitreous in periphery (6).

In case of retinal tears detection, an intraoperative laser treatment has been added.

A specific type of tamponade system (air, sf6 gas, silicon oil 1000 cts) was chosen, depending on the surgical needs. A follow-up of 12 months was carried out and data were retrieved from an electronic patient clinical report.

Statistical analysis was performed using "R statistical software version 3.5.1". VA before and after surgery was compared using the Paired t-test ( $P < 0.05$  was considered statistically significant).

## Results

Based on blood density we divided the VH into two categories: Moderate in 19 patients (20.4%) (optic disc and major retinal vessels barely visible) and Severe in 74 patients (79.6%) (optic disc visualization not allowed).

Before surgery, all patients showed an average BCVA of 1.673 LogMAR, normal intraocular pressure.

A statistically significant difference it turned out between ocular ecography performed before surgery (13 eyes with retinal tears) and intraoperative observation to identify retinal tears (46 eyes); during surgery the rates of detected lesions significantly improve.

Moreover during the surgery it was possible to identify cases in which the VH was not due to the presence of retinal tears but to CNV in 9 patients (9.7%), PDV in 8 patients (8.6%), a retinal venous occlusion in 17 patients (18.3%) including 12 branch vein occlusion and 5 central vein occlusion (Fig. 2).

Patients were tamponed with Air in 58 cases (62.4%), 20% Sf6 gas in 28 cases (30.1%), balanced salt solution in 3 cases (3.2%) and Silicon oil in 4 cases (4.3%) (Fig. 3).

All data were analyzed using the statistical software. It was concluded that, contrary to previous international literature conclusions, the most frequent cause of vitreous hemorrhage in non-traumatic non-diabetic patients is not retinal venous thrombosis, but is the retinal tear (63.4%). Furthermore it has been observed that the early surgical approach allows to recognize and treat retinal tears unidentified at the ultrasound, therefore avoiding onset of retinal detachment with statistically significant visual improvement ( $P < 0.05$ ). Visual acuity increases from 1.673 LogMAR to 0.220 LogMAR.

## Discussion

The management of vitreous hemorrhage of uncertain origin is usually conservative and requires: the upright position with patient immobilization and close monitoring (7, 10–11). The conservative approach has potential risks such as RD, glaucoma and pigmentary retinopathy (12–13).

Surgical treatment involves vitrectomy with well-known risks such as cataract and retinal detachment, on the other hand several studies agree that eyes with vitreous hemorrhage have increased risk of developing retinal detachment, proliferative vitreoretinopathy (PVR), glaucoma, neovascularization (8–9).

The aim of our study was to investigate the most frequent cause of VH in non-diabetic, non-traumatic eyes with acute PVD, and to identify the outcome of the early surgical approach.

We performed a retrospective study involving 93 non-diabetic, non-traumatic patients with no history of PVD in anamnesis.

According to the statistical analysis of our data it emerged that, the main causes of VH in non-traumatic eyes was retinal tears; the early surgical approach allowed to obtain a statistically significant increase in the visual acuity from 1.673 LogMAR to 0.220 LogMAR.

Furthermore, no recurrence of VH or complications such as retinal detachment has occurred in any case.

Based on these considerations, we believe that early surgery in case of fundus obscuring VH may be a recommended option. In our study there was a significant improvement in visual acuity.

Despite the limitations of our study, its retrospective nature and the lack of a control group, we believe that early vitrectomy in VH is advisable considering the high risk of retinal detachment in these patients and the impossibility of laser treatment and proper close monitoring some patients.

## Declarations

**COMPETING INTEREST:** There is no conflict of interest to disclosure.

**FUNDING INFO:** No author has a financial or proprietary interest in any material or method mentioned.

**AUTHOR CONTRIBUTION:** all authors contributed to the study conception and design, analysis and interpretation of the data. Data collection was performed by MAB. All authors read and approved the final manuscript.

**DATA AVAILABILITY:** data supporting the findings of this study are available within the article.

**ANIMAL RESEARCH:** not applicable.

**CONSENT TO PARTICIPATE:** all participate provided written informed consent.

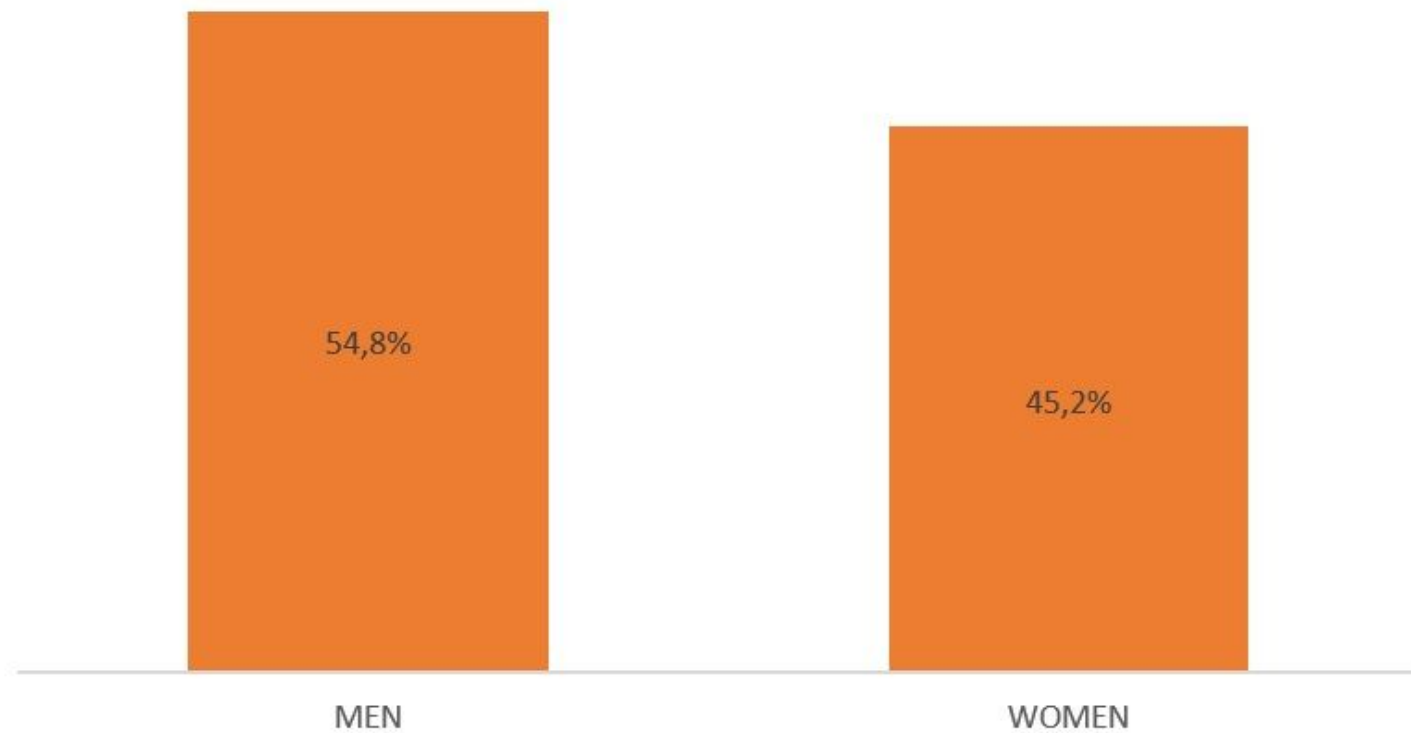
**CONSENT TO PUBLISH:** all participate provided written informed consent.

## References

1. Spraul CW, Grossniklaus HE. Vitreous hemorrhage. *Surv Ophthalmol.* 1997;42(1):3–39.
2. Lindgren G, Sjodell L, Lindblom B. A prospective study of dense spontaneous vitreous hemorrhage. *Am J Ophthalmol.* 1995;119(4):458–465.
3. Byer NE. Natural history of posterior vitreous detachment with early management as the premier line of defense against retinal detachment. *Ophthalmology.* 1994 Sep;101(9):1503-13; discussion 1513-4. doi: 10.1016/s0161-6420(94)31141-9. PMID: 8090453.
4. John P. Berdahl, MD, and Prithvi Mruthunjaya, MD. Vitreous Hemorrhage: Diagnosis and Treatment. <https://www.aao.org/eyenet/article/vitreous-hemorrhage-diagnosis-treatment-2>
5. Rabinowitz R, Yagev R, Shoham A, Lifshitz T. Comparison between clinical and ultrasound findings in patients with vitreous hemorrhage. 2004; **18**: 253– 6.

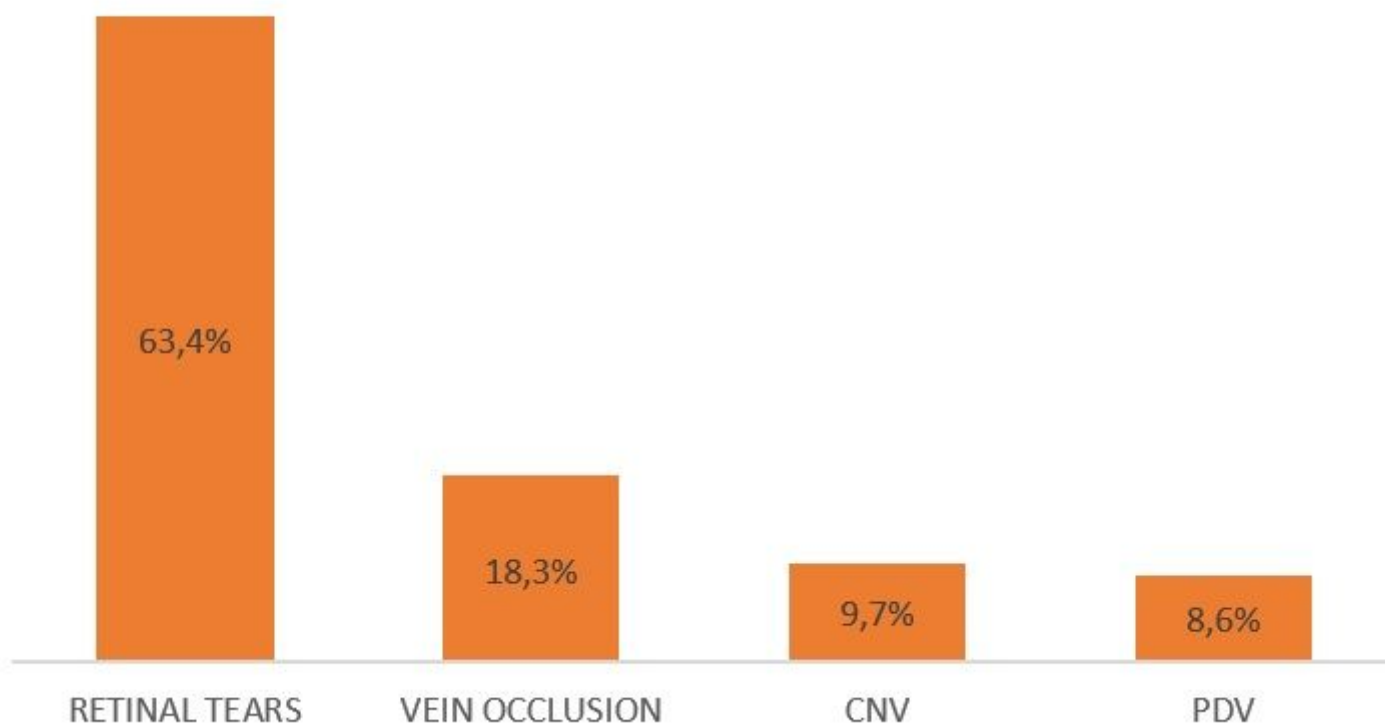
6. Sborgia G, Niro A, Sborgia L, Grassi MO, Gigliola S, Romano MR, Boscia F, Sborgia A, Alessio G. One-year outcomes of 27-gauge versus 25-gauge pars plana vitrectomy for uncomplicated rhegmatogenous retinal detachment repair. *Int J Retina Vitreous*. 2019; 5: 13. doi: 10.1186/s40942-019-0164-0
7. Andrew A Dahl, MD. Vitreous Hemorrhage in emergency medicine treatment e management. Aug 04, 2017 <https://emedicine.medscape.com/article/799242-treatment>
8. Khuthaila MK, Hsu J, Chiang A, DeCroos FC, Milder EA, Setlur V, Garg SJ, Spirm MJ. Postoperative vitreous hemorrhage after diabetic 23-gauge pars plana vitrectomy. *Am J Ophthalmol*. 2013 Apr;155(4):757-63, 763.e1-2. doi: 10.1016/j.ajo.2012.11.004. Epub 2013 Jan 11. PMID: 23317651.
9. Yorston D, Wickham L, Benson S, Bunce C, Sheard R, Charteris D. Predictive clinical features and outcomes of vitrectomy for proliferative diabetic retinopathy. *Br J Ophthalmol*. 2008 Mar;92(3):365-8. doi: 10.1136/bjo.2007.124495. PMID: 18303158.
10. Spraul CW, Grossniklaus HE. Vitreous hemorrhage. *Surv Ophthalmol*1997; 42: 3–39.
11. Wilkinson CP. What ever happened to bilateral patching?*Retina*2005; 25: 393–394.
12. Batman C, Cekic O. Preoperative vitreous hemorrhage associated with rhegmatogenous retinal detachment. *Graefes Arch Clin Exp Ophthalmol*1997; 235: 741–742.
13. Arthur SN, Mason J, Roberts B, et al. Secondary acute angle-closure glaucoma associated with vitreous hemorrhage after ruptured retinal arterial macroaneurysm. *Am J Ophthalmol*2004; 138: 682–683.

## Figures



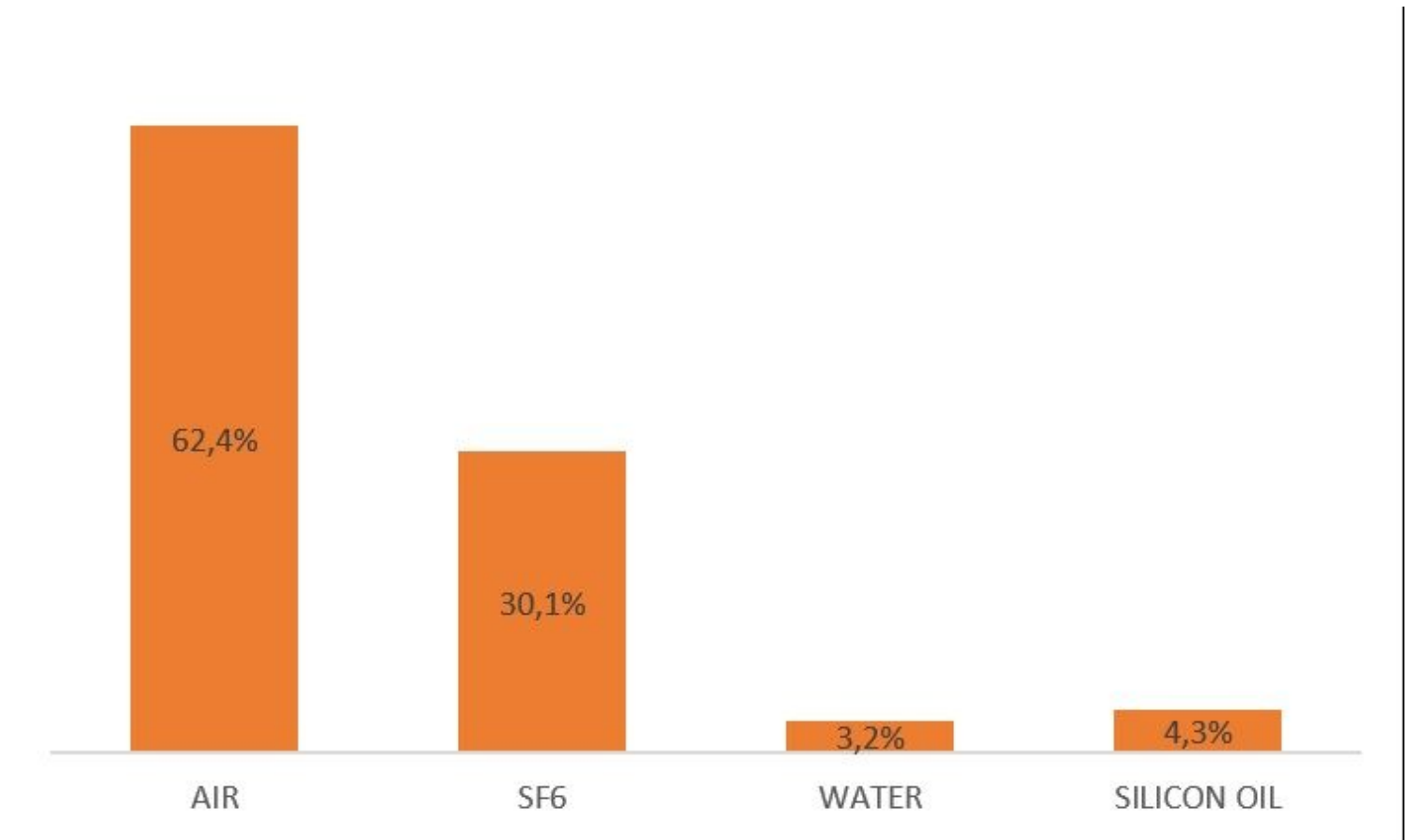
**Figure 1**

Distribution of sex in the our patient group.



**Figure 2**

The most common etiology in our study.



**Figure 3**

Tamponade agents used in our surgery.