Role of Radiofrequency Ablation and Cement Injection for Pain Control in Patients with Spinal Metastasis

Serhat Yildizhan (serhatyildizhan07@gmail.com)
Afyonkarahisar University of Health Sciences Faculty of Medicine: Afyonkarahisar Saglik Bilimleri Universitesi Tip Fakultesi https://orcid.org/0000-0001-9394-5828

Mehmet Gazi Boyaci
Afyonkarahisar University of Health Sciences Faculty of Medicine: Afyonkarahisar Saglik Bilimleri Universitesi Tip Fakultesi

Usame Rakip
Afyonkarahisar University of Health Sciences Faculty of Medicine: Afyonkarahisar Saglik Bilimleri Universitesi Tip Fakultesi

Adem Aslan
Afyonkarahisar University of Health Sciences Faculty of Medicine: Afyonkarahisar Saglik Bilimleri Universitesi Tip Fakultesi

---

Research Article

Keywords: Vertebral Metastasis, Radiofrequency Ablation, Vertebroplasty, Palliative Treatment

Posted Date: February 23rd, 2021

DOI: https://doi.org/10.21203/rs.3.rs-226504/v1

Version of Record: A version of this preprint was published at BMC Musculoskeletal Disorders on October 29th, 2021. See the published version at https://doi.org/10.1186/s12891-021-04799-0.

Abstract

Purpose

The study aimed to investigate the effects and reliability in the prevention of tumour spread of radiofrequency ablation or ablation with vertebroplasty simultaneously applied for pain in patients with painful spinal vertebra metastasis and the effect of preventing tumor spread in long-term follow-up.

Methods

Patients with painful vertebrae metastasis in the XXX Health Sciences University, Medical Faculty, Hospital Neurosurgery Clinic between 01.01.2015 and 01.02.2019 were recruited.

They were divided into groups according to the surgical procedures applied.
Group 1 included 12 patients who underwent radiofrequency ablation only, and group 2 included 16 patients who underwent vertebroplasty with radiofrequency ablation. The metastatic lesion, pain, and quality of life were evaluated with imaging, Visual Analog Scale, and Oswestry Disability Survey before and after the procedure.

Results

A total of 28 patients diagnosed with painful spinal metastasis were included in our study. The degree of collapse increased in five patients in group 1, leading to vertebroplasty. Simple polymethyl methacrylate leakage was observed in four patients in group 2 without spinal cord compression. Pain and quality of life improved significantly in both groups, with more being in Group 2, and analgesic use was significantly reduced. No tumor spread in the vertebrae was observed in any patient during follow-up.

Conclusion

According to our results, patients with painful vertebral metastases should receive vertebroplasty simultaneously with radiofrequency ablation for palliative pain control and prevention of tumour spread.

Introduction

Spinal metastases are common in patients with advanced malignancies, with a reported prevalence of 30% [1]. An autopsy series conducted by Scutellari et al. reported a prevalence of up to 70% [2]. Most metastases are detected in the thoracic spine (70%), followed by the lumbar spine (20%), and cervical and sacral spine (10%) [3]. The incidence of spinal metastasis has increased due to the aging population, increased life expectancy, and advancements in medical technology. The treatment strategy for patients with advanced-stage cancer is based on their health status or physical performance. The management of

patients with expected survival periods <3 months mainly comprises conservative or supportive care [4]. Surgical options are considered in cases where the survival expectation is longer. The most common tumours that metastasize to the spine include lung, breast, kidney, prostate, thyroid, and colorectal cancers and melanomas, myelomas, and lymphomas [5,6]. The metastatic spread of tumours to the spine causes serious neurological problems arising from severe pain, spinal fractures, and compression of the nerve roots and spine by the lesion mass [7]. Radiotherapy, chemotherapy, isotopic therapy, bisphosphonate therapy, pharmacotherapy, radiofrequency ablation (RFA), and palliative surgery may be used for the treatment of spinal metastases [8]. RFA entails the use of a high-frequency alternating current that passes from the electrode needle to adjacent tissues, causing friction heating and tissue necrosis, including necrosis of metastatic tumour cells that produce nerve-stimulating cytokines and adjacent sensory nerve fibres (including those involved in sensory and pain conduction);additionally RFA arrests bone damage, inhibit pain-inducing osteoclastic activity, and also promotes the release of different cytokines and biochemical factors [9,10,11]. Ablation provides curative treatment for benign and malignant lesions measuring up to 3 cm. It reduces the tumour burden and mass effect on adjacent organs by reducing pain and effecting local disease control. Therefore, vertebroplasty (VP) should be performed after RFA, depending on lesion size and location, since the stability of the vertebral column is compromised [12]. This study evaluated the efficacy and reliability of simultaneous VP and RFA for the palliative management of patients with metastatic vertebral metastases with consideration of the current knowledge on this subject.

Methods

The study was approved by the XXX University of Health Sciences Clinical Research Ethics Committee (dated 04.10.2019, approval number: 2019/310). Fifty-three patients with spinal metastasis were examined at the neurosurgery clinic of XXX Health Sciences University Hospital between 1 January, 2015 and 31 September, 2019. Patients with osteolytic vertebral metastasis, analgesic-resistant pain, an age of >18 years, and with ≥3 months of life expectancy were included in the study. These patients had spinal involvements and were neurologically stable. The primary tumour was under control and their only complaint was pain. Patients with an active primary tumour, who previously underwent radiotherapy for the spine, were neurologically unstable, and those who underwent surgical decompression and instrumentation were excluded from the study.

Twenty-eight of the 53 patients met our eligibility criteria. Of these, 12 patients with posterior element fracture out of the corpus underwent only RFA (group 1) and the remaining 16 patients underwent simultaneous treatment with VP and RFA (group 2). All patients underwent computed tomography (CT) and magnetic resonance (MR) imaging before the respective procedures. The Visual Analogue Scale (VAS; 0= no pain, 10= worst pain imaginable) was used for pain assessment. The Oswestry Disability Index was used to assess the quality of life (QoL). Participants were followed-up for up to 6 months. MR imaging was performed at the end of six months. RFA was administered to the vertebrae infiltrated by the neoplastic lesions, under local anaesthesia and conscious sedation at an average temperature of 90°Cfor 3-7 min. Sixteen patients with vertebral metastases underwent VP with polymethylmethacrylate (PMM)

radio-opaque bone cement injection after RFA (Figures 1,2,3,4). Cardiovascular and respiratory parameters were monitored throughout the procedures, and preoperative and postoperative CT scans were compared.

RFA and VP Technique

The patients were placed in the pure prone position. Intravenous cephazolin was administered as a prophylactic antibiotic. An 11-G bone biopsy needle was placed near the lesion under imaging guidance after local anaesthetic administration (1% lidocaine). Subsequently, the RFA electrode (Thermo catheter, 17G, RD Global-İnvamed) was inserted coaxially into the needle along the middle part of the active electrode length, positioned at the approximated centre of the target lesion. RFA was conducted for an average duration of 5 min (3-7 min) at a temperature ranging from 60 to 100°C with the help of the needle. The radiofrequency probe was replaced by a 10-15 G VP cannula using a sterile surgical hammer after RFA completion. Bone cement injection was performed with a special injection set. Intermittent fluoroscopic examinations were conducted during cement injection to detect epidural leakage, eliminate lateral leakage, and evaluate cement distribution.

Statistical Analysis

The general linear model was used for statistical analysis of postoperative outcomes and 6-month follow-up outcomes for each group. The Mann-Whitney U test was used for comparisons between the two groups. Differences were considered significant if $p < 0.05$.

Results

Group 1 consisted of 12 patients who underwent RFA only and group 2 of 16 patients who underwent VP with RFA. PMM leakage was observed from the posterior elements of the corpus vertebrae of the spinal canal in 4 patients; however, no interventions were required because the patients were asymptomatic.

Multiple myeloma was the most common primary malignancy and was observed in 12 patients. Ten patients had thoracic metastases, and 6with lumbar metastases. Multiple metastases were observed in 12 patients.

The mean VAS score before the procedure was 8.3±1.07 in the RFA group (Table 1), and a statistically significant difference was observed in VAS scores at all post-procedural measurement time-points ($p<0.001$). The VAS score decreased significantly in the first 24 h after treatment and was determined to be 4.8±1.03 in patients who underwent only RFA. The mean VAS scores obtained 1 and 6 months after the procedure exhibited statistically significant differences ($p<0.001$). The VAS score, which started to increase in month 3 of treatment (4.50±1.57), was 4.42±1.08points at the end of month 6. The mean pre-treatment Oswestry Disability Index (used to assess the QoL) was 79.33%, and significantly improved to 29.67% after treatment; the differences in the Oswestry Disability Index were statistically significant at all the measurement time-points after the procedure($p<0.001$)(Table 2). The pain scores decreased at a rate

of 58.8%, and 69.6% of patients showed significant improvements in the QoL in the RFA-only group. The severity of pain increased and the vertebral corpus height decreased in 5 patients in this group during the 3-month follow-up; subsequently these patients underwent instrumentation surgery.

The mean VAS score was 7.44±1.06 in group RFA+VP (Table 1) before the procedure; the difference in the mean VAS scores was statistically significant at all measurement time-points after the procedure ($p<0.001$). The mean VAS score inthe first 24 h after treatment was 4.38±1.00in patients who underwent RFA with simultaneous cement injection. The differences between mean VAS scores obtained at the first, third, and sixth months after the procedure were statistically significant ($p<0.001$). The VAS scores were 2.94±1.04 and 2.44±1.61 1 and 3 months after treatment, respectively, and 2.31±1.42 6 months after treatment. An 82.4% reduction in pain was observed in all patients in the RFA+VP group and 52.7% of patients showed a significant improvement in the QoL. Moreover, the mean pre-treatment Oswestry Index (to assess the QoL) was 78.50% in the RFA+VP group, which improved to 14% after treatment (Table 1).

The comparison of pre-treatment and 6-month post-treatment results of the Oswestry Disability Index revealed significant improvements in social life, walking ability, personal care, level of pain, and sleeping function in all patients. Tenoxicam and tramadol hydrochloride were discontinued 48 h after the procedure in patients who had required them before the procedure. The need for tenoxicam significantly decreased in both groups by the end of the first week.

Between-group comparisons revealed a significant decrease in pain in all patients from both groups after the first 3 months and a significant improvement in the QoL, with a lower degree of pain interfering with daily activities. However, patients in group 1 needed analgesics for pain by the end of the third month (Table 2). In group 2, none of the vertebrae treated during the 6-month follow-up period revealed tumour metastasis that could lead to advanced collapse and compression of the spinal cord.

Four patients with painful metastatic bone tumors who did not accept this procedure for different reasons, had a rapid spread and neurodephicitis within two months (Figure 5).

Discussion

Metastatic lesions that spread to the spine can cause severe pain, spinal fractures, and neurological problems due to nerve root and spine compression by the tumour mass [7]. Several treatment alternatives for spinal metastases including radiotherapy, chemotherapy, isotopic therapy, bisphosphonate therapy, pharmacotherapy, RFA, and palliative surgery can be used [8]. The choice of treatment depends on the histopathology of the primary tumour, neurological function before treatment, number of involved vertebrae, vertebral level, site of the osteolytic lesions in the spinal body, degree of intraspinal diffusion, disease severity, and the patient’s general condition.

Narcotic analgesics are the first-line pharmacotherapy for pain control in patients with metastatic lesions; however, they can cause extreme drowsiness, constipation and nausea. Previous studies have reported that palliative radiotherapy is highly beneficial in alleviating metastasis-related pain [13,14]. However, a

57% recurrence rate (of pain) was reported 15 weeks after the end of radiotherapy [9]. Approximately 40% of patients did not benefit from a second round of radiotherapy [15]. Reconstruction surgeries such as surgical decompression, pedicular screws, and corpectomy-cage placement can be performed in patients whose life expectancy exceeds 6 months [16]. However, the complication rate is as high as 20-40%, and systemic complications such as surgical wound area infection, pneumonia, and urinary tract infections were observed in several patients [12,16,17].

Pain is the most common finding in patients with spinal metastasis, with a consequential reduction in mobility and deterioration in the QoL. Approximately 30-50% of patients with cancer experience pain, and excruciating pain disrupts the QoL in 75-90% of patients with advanced-stage cancer [9]. Bone metastasis-related pain is triggered by osseous destruction induced by osteoclasts, which are the principal bone resorption cells of the body [17]. Biochemical factors and cytokines released from the periosteum and tumour cells also contribute to osseous destruction [18]. The pain caused by vertebral involvement is dull and stable and progressively increases, exacerbated by movement of the extremities [15,19]. Radiation and/or chemotherapy, surgery, and use of opioids and other analgesics are common for pain control in patients with spinal metastasis [16]. However, the QoL is extremely poor owing to intolerable pain in these patients. All patients in our study had a history of increasing analgesic use at least 2 months before the procedure.

Callstrom reported that pain in daily life decreased at a rate of 0% 4 weeks after RFA in patients with bone metastasis [16]. While Goetz reported that analgesics use decreased significantly6 months after treatment in 41 of 43 patients treated with RFA [20]. Zhao determined a significant reduction in analgesics use 6 months after the implementation of RFA in 34 patients with metastases [21].

In our study, tramadol hydrochloride was discontinued 48 h after the procedure in groups 1 and 2, while the need for tenoxicam, another analgesic used at the end of the first week, significantly decreased. Group 1 patients had increased pain at the 3-month follow-up, and analgesic use increased before the procedure. This situation was attributed to the increase in the degree of collapse in the affected vertebra.

VP has also been reported to facilitate safe and rapid pain reduction in patients with cancer with spine involvement and increased patients' ability to walk and perform daily activities [22]. The skeleton is stabilized with the application of VP after RFA, thus preventing periosteal deformation and pain [23]. RFA and PMM injection can be combined to reduce pain and improve the QoL. The advantage of performing RFA before PMM injection is increased control for PMM distribution, which can be useful in posteriorly located lesions [24]. Moreover, the spread and displacement of tumour cells are prevented by the ablation shell barrier, which is applied during RFA. RFA can also cause intravertebral venous plexus thrombosis, and subsequently reduce the risk of PMM leakage. Liu et al. reported that the combination of RFA, a minimally invasive intervention used for treating metastatic spine lesions, with percutaneous VP was particularly beneficial in reducing the incidence of fracture, risk of pain and surgery, and improving the QoL [7].

Lane reported a reduction inthe pain scores in some patients treated with combined RFA and VP [24]. Gronemeyer reported a significant reduction in pain and disability in patients treated with RFA and VP [25]. In our study, 16 patients underwent PMM injection into the vertebrae with metastatic lesions after successful RFA.

The reported rate of serious complications for percutaneous VP is low (<10%); however, one study reported a PMM leakage rate of 81% visualised using CT [26]. Barragan-Campos reported 42 cases of PMM leakage cases from amongst 159 percutaneous VP procedures [27]; however, only 2 patients had serious complications. Furthermore, Nakatsuka reported that 4 patients developed hemiplegia and radiculopathy after RFA+VP, which was performed under CT fluoroscopy guidance [28]. In our study, PMM leakage occurred in 4 (25%) of 16 patients who underwent VP, but no serious complications were observed (Figure 2).

All the aforementioned complications occur in cases where the tumour invades the vertebral cortex, and consequently, VP is contraindicated in these patients [29]. On the other hand, the combined procedure is safe in patients without posterior cortex and pedicular invasion. Shimony et al. [29] reported their successfully performing VP in patients with metastasis-related compression fractures but without posterior cortical deterioration, and successful pain control in 82% of patients, without any serious complications. Our study protocol achieved a successful pain control rate exceeding 80% 6 months postoperatively.

Goetz reported a reduction of at least 2 points in the pain scores in 95% of patients after RFA treatment [20]. The reduction in pain levels was the highest in the first week, with a rate of 41%, with significant reductions in the opioid requirement in the 8thand 12thweeks [20]. In our study, significant improvement was observed in patients with refractory pain caused by spinal metastasis. According to the VAS assessment, the mean decrease in pain was 3.3 points after 72 h, 5.3 points in the 1stweek, 5.7 points in the 1stmonth, and 6.7 points in the 6thmonth.

Limitations of the present study include the small sample population, lack of a control group, and short-term follow-up. The patients were followed-up for an average period of 6 months after the procedure, which was insufficient to determine long-term pain control and recurrence rates. Long-term follow-ups are required to determine the rate of recurrence and long-term survival. However, it was difficult to follow-up this patient population for longer durations owing to the progression to terminal cancer stages, characterised by metastases to different organs. Future multi-centre studies are required to improve RFA effects, expand the scope of its application for tumours or metastases, and reduce possible complications.

Conclusion

Minimally invasive techniques can be safely used in patients with spinal metastasis, because such techniques cause less trauma, have fewer complications, and yield more effective results than more

invasive treatments. Simultaneous RFA and VP are safe and effective for the palliative treatment of patients with painful metastatic bone tumours. It was observed that the tumour spread was very rapid in patients who did not accept early treatment (Figure 5). RFA combined with VP is superior in treatment of spinal metastasis with respect to pain reduction, analgesic-consumption reduction, and tumour spread compared to use of RFA alone. This procedure significantly reduced patients' dependence on 'drugs of last resort' and wider tumour spread. None of the patients who underwent treatment exhibited a collapse in the vertebrae or a consequent increase in tumour spread, which was sustained over the6-month follow-up period. Larger case series and longer follow-ups are needed to further validate our results.

Declarations

Funding: No financial contribution has been received

Conflicts of interest/Competing interests: No conflict of interest between authors

Availability of data and material: Not applicable

Code availability: Not applicable

Authors' contributions: Not applicable

Ethics approval: The study was approved by the Afyonkarahisar Health Science University of Health Sciences Clinical Research Ethics Committee (dated 04.10.2019, approval number: 2019/310)

Consent to participate: Not applicable

Consent for publication: Not applicable

References

1. Salmon JM, Kilpatrick SE. Pathology of skeletal metastases. Orthop Clin North Am 2000;31: 537–544.
2. Scutellari PN, Antinolfi G, Galeotti R, Giganti M. Metastatic bone disease. Strategies for imaging. Minerva Med. 2003; 94: 77–90.
3. Murphy KJ, Nwankwo IJ, Gailloud P. Percutaneous vertebroplasty in the treatment of blastic vertebral column metastasis from breast cancer. J Vasc Interv Radiol. 2007;18:321–323.
4. Constans JP, de Divitiis E, Donzelli R, Spaziante R, Meder JF, Haye C. Spinal metastases with neurological manifestations. Review of 600 cases. J Neurosurg. 1983;59: 111-118.
5. Ibrahim AG, Crockard HA, Antonetti P,Boriani S, Bünger C, Gasbarrini A, Grejs A, Harms J, Kawahara N, Mazel C, Melcher R, Tomita K. Does spinal surgery improve the quality of life for those with extradural (spinal) osseous metastases? An international multi-centre prospective observational study of 223 patients. J Neurosurg Spine 2005; 8: 271-278.

6. Jacobs WB, Perrin RG. Evaluation and treatment of spinal metastases: an overwiev. Neurosurg Focus 11. 2001 (Article 10).
7. Liu X, Yang Z, Xie L, Yuan Z, Ren M, Han L. Advances in the clinical research of the minimally invasive treatment for the posterior edge of vertebral-body defects by spinal metastases. Biomed Rep 2015;3:621–625.
8. Mac Manus MP, Hicks RJ, Matthews JP, Wirth A, Rischin D, Ball DL. Metabolic (FDG-PET) response after radical radiotherapy/chemoradiotherapy for non-small cell lung cancer correlates with patterns of failure. Lung Cancer. 2005;49:95–108.
9. Honore P, Luger NM, Sabino MA,Schwei MJ, Rogers SD, Mach DB, O'keefe PF, Ramnaraine ML, Clohisy DR, Mantyhet PW. Osteoprotegerin blocks bone cancer-induced skeletal destruction, skeletal pain and pain-related neurochemical reorganization of the spinal cord. Nat Med 2000;6:521–528.
10. Mannion RJ, Woolf CJ. Pain mechanisms and management: a central perspective. Clin J Pain 2000; 16: 144–156.
11. Woolf CJ, Allchorne A, Safieh-Garabedian B, Poole S. Cytokines, nevre growth factor and inflammatory hyperalgesia: the contribution of tumour necrosis factor alpha. Br J Pharmacol 1997; 121:417–424.
12. Filippiadis DK, Tutton S, Mazioti A, Kelekis A. Percutaneous image guided ablation of bone and soft tissue tumours: a review of available techniques and protective measures. Insights Imaging 2014;5:339–346.
13. Khan I, Bashir Z, Forster M. Interpreting small treatment differences from quality of life data in cancer trials: an alternative measure of treatment benefit and effect size forthe EORTC-QLQ-C30. Health Qual Life Outcomes 2015;13:180.
14. Yang PL, He XJ, Li HP, Zang QJ, Wang GY. Image-guided minimally invasive percutaneous treatment of spinal metastasis. Exp Ther Med 2017;13:705–709.
15. Mercadante S. Malignant bone pain: pathophysiology and treatment. Pain 1997;69:1–18.
16. Callstrom MR, Charboneau JW, Goetz MP,Rubin J, Wong GY, Sloan JA, Novotny PJ, Lewis BD, Welch TJ, Farrell MA, Maus TP, Lee RA, Reading CC, Petersen IA, Pickettet DD. Painful metastases involving bone: feasibility of percutaneous CT- and US-guided radio-frequency ablation. Radiology 2002;224:87–97.
17. Clohisy DR, Ramnaraine ML. Osteoclasts are required for bone tumors to grow and destroy bone. J Orthop Res 1998;16:660–666.
18. Schaefer O, Lohrmann C, Markmiller M, Uhrmeister P, Langer M. Technical innovation. Combined treatment of a spinal metastasis with radiofrequency heat ablation and vertebroplasty. AJR Am J Roentgenol 2003;180:1075–1077.
19. Portenoy RK, Payne D, Jacobsen P. Break through pain: characteristics and impact in patients with cancer pain. Pain 1999;81:129–134.

20. Goetz MP, Callstrom MR, Charboneau JW, Farrell MA, Maus TP, Welch TJ, Wong GY, Sloan JA, Novotny PJ, Petersen IA, Beres RA, Regge D, Capanna R, Saker MB, Grönemeyer DHW, Gevargez A, Ahrar K, Choti MA, Baere TJD, Rubin J. Percutaneous image guided radiofrequency ablation of painful metastases involving bone: a multicenter study. J Clin Oncol 2004;22:300–306.
21. Zhao W, Wang H, Hu JH, Peng ZH, Chen JZ, Huang JQ, Jiang YN,Luo G,Yi GF, Shen J, Gao BL. Palliative pain relief and safety of percutaneous radiofrequency ablation combined with cement injection for bone metastasis. Japanese Journal of Clinical Oncology, 2018;48(8) 753–759.
22. Health Quality Ontario. Vertebra laug mentation involving vertebroplasty or kyphoplasty for cancer-related vertebral compression fractures: a systematic review. Ont Health Technol Assess Ser 2016;16:1–202.
23. Amar AP, Larsen DW, Esnaashari N, Albuquerque FC, Lavine SD, Teitelbaum GP. Percutaneous transpedicular polymethylmethacrylate vertebroplasty for the treatment of spinal compression fractures. Neurosurgery 2001;49:1105–1114.
24. Lane MD, Le HB, Lee S, Young C, Heran MKS, Badii M, Clarkson PW, Munk PL. Combination radiofrequency ablation and cementoplasty for palliative treatment of painful neoplastic bone metastasis: Experience with 53 treated lesions in 36 patients. Skeletal Radiol 2011;40:25–32.
25. Gronemeyer DH, Schirp S, Gevargez A. Image-guided radiofrequency ablation of spinal tumors: preliminary experience with an expandable array electrode. Cancer J 2002;8:33–39.
26. Schmidt R, Cakir B, Mattes T, Wegener M, Puhl W, Richter M. Cement leakage during vertebroplasty: an underestimated problem? Eur Spine J 2005;14:466–473.
27. Barragan-Campos HM, Vallee JN, Lo D, Cormier E, Jean B, Rose M, Astagneau P, Chiras J. Percutaneous vertebroplasty for spinal metastases: complications. Radiology 2006;238:354–362.
28. Nakatsuka A, Yamakado K, Maeda M, Yasuda M, Akeboshi M, Takaki H, Hamada A, Takeda K. Radiofrequency ablation combined with bone cement injection for the treatment of bone malignancies. J Vasc Interv Radiol 2004;15:707–712.
29. Shimony JS, Gilula LA, Zeller AJ, Brown DB. Percutaneous vertebroplasty for malignant compression fractures with epidural involvement. Radiology 2004;232:846–853.

Tables

Due to technical limitations, the tables are only available as a download in the supplemental files section.

Figures

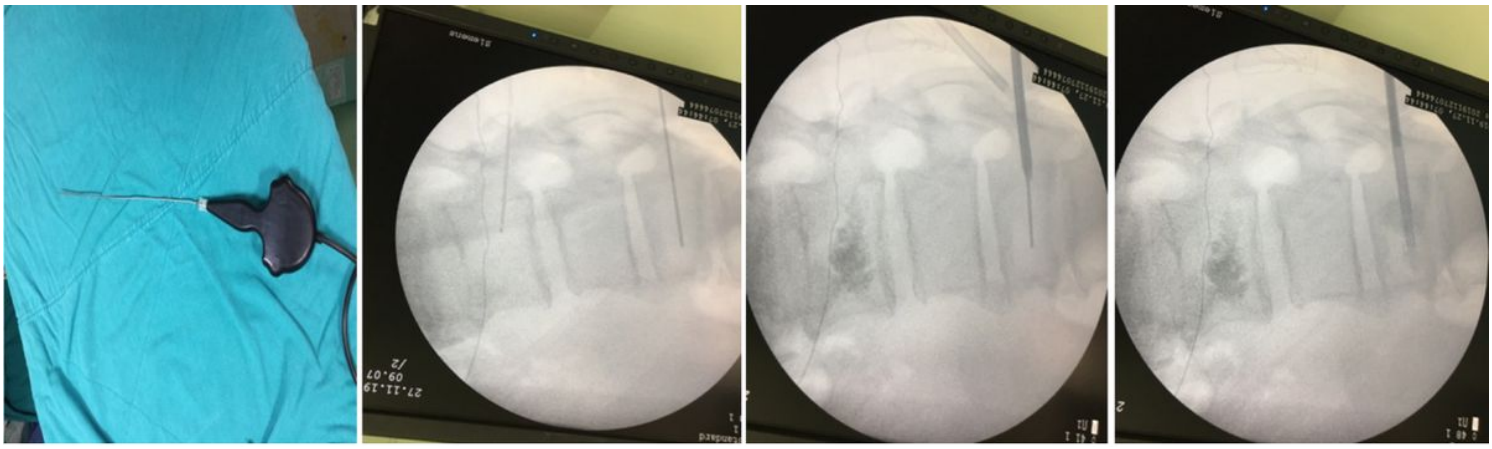

Figure 1

RF and cement application in metastatic involvement

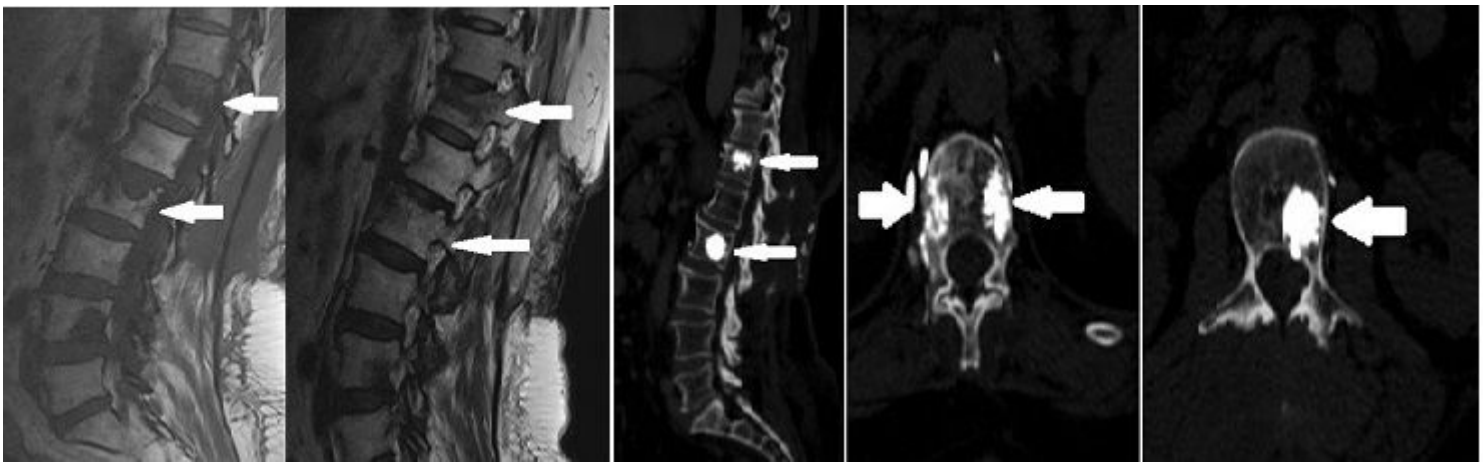

Figure 2

64 years old female patient. T12 and L2 vertebra metastatic involvement MRG images (preoperatively) and CT images after RFA and vertebropalsti.

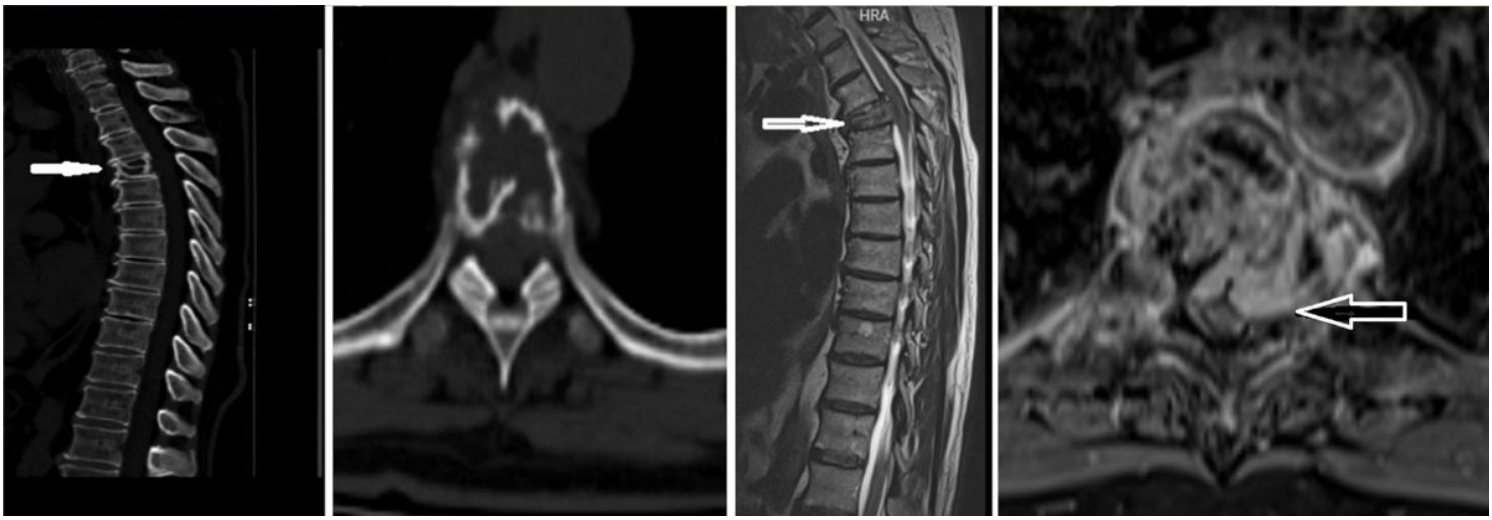

Figure 3

MRI scan of the patient who refused surgical treatment 2 months later.

Supplementary Files

This is a list of supplementary files associated with this preprint. Click to download.

- table1....docx
- table2.docx