Aspiration-Sclerotherapy Versus Laparoscopic De-roofing in the Treatment of Symptomatic Renal Cysts: A Systematic review and meta-analysis

Xueling Zhang
West China Hospital, Sichuan University
Dehong Cao
West China Hospital, Sichuan University
Peizhen Han
West China Hospital, Sichuan University
Zhengju Ren
West China Hospital, Sichuan University
Jia Wang
West China Hospital, Sichuan University
Qiang Wei (weiqiang339@126.com)

Research article

Keywords:

Posted Date: July 16th, 2019

DOI: https://doi.org/10.21203/rs.2.11406/v1

Version of Record: A version of this preprint was published at BMC Nephrology on May 24th, 2020. See the published version at https://doi.org/10.1186/s12882-020-01832-7.

Abstract

Background: Renal cyst is prevailing around the world and symptomatic renal cysts are recommended to be treated in the EUA guidelines. Currently, aspiration-sclerotherapy (AS) and laparoscopic de-roofing (LD) are the main therapies of symptomatic renal cysts. This article aims to compare the clinical efficiency between them in the management of renal cysts through meta-analysis of comparative studies. Method: A comprehensive literature search was performed by PubMed, MEDLINE, EMBASE and the Cochrane Library to ascertain the relevant studies published up to March 2019. Articles with English full-text comparing aspiration-sclerotherapy and laparoscopic de-roofing in renal cyst treatment were included. Results: Our searches of literature generated 6 studies (1547 patients incorporated) comparing AS with LD in the impacts of renal cyst therapy. Of these, 6 studies contained 1106 and 441 patients who were treated with AS and LD, respectively. The outcome of this meta-analysis indicated that although AS group had shorter treatment time (MD -51.10; 95% CI -73.01 to -29.20; p<0.01), radiological successful rate (RR: 0.64; 95%CI: 0.53 to 0.77) are higher in LD group, which also had less recurrence rate (RR: 4.96; 95%CI: 2.28 to 10.81; p<0.01). No statistically significant difference was showed in symptomatic successful rate (RR: 0.90; 95%CI: 0.79 to 1.03 P=0.13) and complications (RR: 2.11; 95% CI: 0.47 to 9.52; P=0.33). Conclusion: In our meta-analysis, laparoscopic de-roofing is superior to aspiration-sclerotherapy in radiological successful rate and recurrence, but the treatment time is longer.

Background

Renal cyst is one of the most common diseases among kidney illnesses, and age, hypertension, proteinuria as well as microscopic hematuria are regarded as risk factors of that.[1] In an adult health-screening cohort, Ozveren et al.[2] found that the prevalence of renal cysts was 7.7% under ultrasonography and higher number of renal cysts in males. Moreover, Kong et al.[3] managed a large sample cross-sectional study about renal cysts, whose results showed the prevalence of it among Chinese adults was 10.5%, and even the existence of it significantly correlated with renal damage and the estimated glomerular filtration rate (eGFR) of 5.7% patients who with more than one renal cyst was decreased under 60 ml/min/1.73m^2. Nowadays according to the Bosniak renal cysts classification, cysts of Bosniak , are symptomatic and even malignant to some extent.[4] In the EUA guidelines, the symptomatic renal cysts (Bosniak ,) are recommended to be treated through surgery.[5] Therefore, we should pay attention to the treatments of symptomatic renal cysts in particular.

Aspiration-sclerotherapy (AS) and laparoscopic de-roofing (LD) are main therapies for symptomatic renal cysts.[6] LD is usually applied to large compressive cysts or increasing in cyst`s size, while AS may be superior in time-consuming or cost but its reliability has not yet been ascertained.[7] Based on the current clinical literature, we first conducted this meta-analysis to compare AS with LD in the management of renal cysts.

Methods

Search strategy

A systematic and comprehensive search was performed in PubMed, EMBASE, Web of Science and the Cochrane Library by two reviewers independently. “sclerotherapy”, “aspiration”, “laparoscopy”, “laparoscopic”, “de-roof”, “decortication”, “decompression”, “ablation”, “kidney cysts”, “renal cysts” are used as search terms to collect relevant studies published up to April 2019. We followed the guideline of Preferred Reporting Items for Meta-Analyses.[8]

Inclusion criteria

- Clinical experimental articles (both prospective and retrospective experiments)
- Patients with renal cysts
- Studies comparing aspiration-sclerotherapy and laparoscopic de-roofing in the treatment of renal cysts only.
- Articles published in the English language with full-text.

Exclusion criteria

- Studies addressing aspiration-therapy only or laparoscopic de-roofing only.
- Studies comparing aspiration-therapy and laparoscopic de-roofing among patients with lymphocele.
- Systematic review articles.
- Abstract articles for academic conferences without full-text.

Date extraction

Data extraction and quality assessment of included studies were performed by two independent reviewers. The following information was selected from each included study: first author’s name, publication year, country, type of treatments, sample number, age, gender, diameter of cyst and length of follow-up. We also extracted some particular outcomes from each treatment type such as clinical presentation, rate of symptomatic success, rate of radiological success, time of treatment, length of hospital stay, complications, total cost and recurrence. In the end, all the included studies were divided into two groups according to the way of therapy for renal cysts and compared accurately.

Quality assessment

Criteria provided by the Oxford Centre for Evidence-Based Medicine was used to assess the level of evidence for each study. The Newcastle–Ottawa Scale was used for the estimation of these studies` methodological quality.[9] Two reviewers accomplished the appraisal respectively. Disagreements were solved after

discussions. If disagreement persisted, a third reviewer would participate in the discussion until an agreement was reached.

Statistical analysis

This meta-analysis compares symptomatic successful rate, radiological successful rate, treatment time, complications and recurrence of aspiration-sclerotherapy versus laparoscopic de-roofing during the cure of renal cysts. Review manager (RevMan) software version 5.3 was used to evaluate the outcomes of each study for comparison. Risk ratio (RR) and mean difference (MD) were used to estimate dichotomous and continuous variables separately. If results are shown with 95% confidence interval (CI), the standard deviation was calculated by the statistical calculation declaimed by Hozo and colleagues[10]. Heterogeneity of these researches was evaluated using the chi-square test. I^2 >50% was regard as high heterogeneity so that we took random effect model; I^2 <50% was regard as low heterogeneity so that we took fixed effect model. A p-value <0.05 was considered as statistically significant.

Results

Study characteristics

Our researches of literature generated 6 studies[11-16] comparing AS with LD in the effects of renal cysts treatment. These studies contained 1106 and 441 patients who were treated with AS and LD respectively. Characteristics (including first author's name, publication year, country, type of treatments, sample number, age, ratio of male, diameter of cyst and length of follow-up) and quality assessment of all studies are summarized in Table 1. Meta-analysis results of these 6 studies are elaborated in Figure 2. Flow chart diagram demonstrating the strategy of search and selection was shown in Figure 1.

Quality assessment

The evidence levels of all the studies were rated Level 2 according to the Oxford level of evidence criteria. The studies by Agarwal et al.[14] and Arisan et al.[15] were scored eight stars based on the Newcastle–Ottawa Scale. The rest of studies were scored seven stars each.

Meta-analysis

Symptomatic successful rate

Four studies[11-14] involving 1498 patients compared the cure rate of symptom between AS group and LD group. The result of this meta-analysis showed that no statistically significant difference between them (random effect model; RR: 0.90; 95%CI: 0.79 to 1.03; P=0.13) with a high heterogeneity (P=0.001; I^2=82%; Fig. 2A). The sensitive analysis claimed a statistical significant difference between them (random effect model;

RR: 0.96; 95%CI: 0.93 to 0.99 P=0.01) and the heterogeneity of that reduced to zero after excluding the study of Bas et al.[12] This demonstrated that this meta-analysis was influenced by this study.

Radiological successful rate

Two studies[11, 12] including 264 patients compared the successful rate of radiology between AS group and LD group. A meta-analysis of these studies stated that LD is significantly higher in the matter of radiological cure rate compared with AS (fixed effect model; RR: 0.64; 95%CI: 0.53 to 0.77; p<0.01). Statistical heterogeneity was not illustrated in the pooled analysis (P=0.72; I^2=0%; Fig. 2B).

Treatment time

Three studies[11, 13, 14] involving 1314 patients compared the treatment time between AS group and LD group. The result of meta-analysis showed that AS was associated with a significantly lower time-consuming in the therapy procedure (random effect model; MD -51.10; 95% CI -73.01 to -29.20; p<0.01), but the heterogeneity of it was high (P<0.01; I^2=99%; Fig. 2C).

Complications

Six studies[11-16] containing 1547 patients compared the number of complication events between AS group and LD group. The outcome of our meta-analysis illustrated that no statistically significant difference was found between these two groups (random effect model; RR: 2.11; 95%CI: 0.47 to 9.52; P=0.33) with a slightly high heterogeneity (P=0.005; I^2=70%; Fig. 2D). After eliminating the data from Agarwal et al.[14] and Shao et al.[13], the sensitive analysis showed a statistical significant difference between them (random effect model; RR: 5.72; 95%CI: 3.20 to 10.23; P<0.01) meanwhile the heterogeneity of it reduced to zero.

Recurrence

Two studies[12, 13] including 1378 patients compared the number of recurrence events of AS group with that of LD group. Our meta-analysis of these studies illustrated that LD was significantly associated with lower rate of recurrence compared with AS (fixed effect model; RR: 4.96; 95%CI: 2.28 to 10.81; p<0.01). Statistical heterogeneity was not stated in this meta-analysis (P=0.63; I^2=0%; Fig. 2E).

Discussion

Currently, comparisons of the effects between AS and LD in the treatment of renal cysts were lacking, therefore, we first conducted a meta-analysis on this subject. Statistics in Table 1 show that renal pain would be the primary presenting symptom among patients with renal cysts, renal lump, hypertension and hematuria

frequently happen to renal cyst patients as well. Besides, Kim et al.[17] investigated 3,249 patients with renal cysts and they also improved that the occurrence of renal cysts was significantly positively related to that of hypertension, which has the following characteristics: bilateral distribution, number of cyst no less than two and diameter of cyst larger than 1 cm. Although renal cyst is a benign disease in most cases, complicated variations of that still has the connection of renal cell carcinoma, which may urge patients with renal cysts to be more cautious about the importance of regular follow-up.[18]

At present, treatments such as AS and LD are available to renal cyst patients. Relating to AS, it is time-saving, economical, well tolerance and simple technique so that can be performed under local anesthesia and even in the outpatient rooms in most cases.[19] Our meta-analysis also illustrated that treatment time of AS is significantly shorter than LD. As we all know, AS can be conducted under local anesthesia while LD should be operated with general anesthesia. Thus, LD needs more time for therapy. The high heterogeneity of treatment may be caused by different ways of records about these data. Some of included studies collected the entire time of hospital stay, nevertheless, the rest of studies only recorded the operation time.

Studies reported by Ali et al.[20] and Monville et al.[19] evaluated the efficiency of ultrasound-guided percutaneous sclerotherapy among patients with renal cysts, their results showed that the radiological successful rate is up to 98% and 91.6% respectively meanwhile the complication and recurrence leveled off to zero. However, the rates of radiological success reported by Efesoy et al.[11] and Bas et al.[12] are 63.2% and 60% separately, which are presented in Table 2. Ethanol contacting the cyst wall causes protein degeneration, cell death as well as inflammatory fibrosis so that patients should keep 5 to 10 minutes at least in each position according to the cyst size and volume.[21] Therefore, the difference among them may be ascribable to the different treatment procedure, which also was hard to make a standard therapy.

In addition to this, although study reported by Zhong et al.[22] shows no recurrence was observed after AS treatment, in the outcome of our meta-analysis, it is remarkably higher in AS group than LD group in the matter of recurrence. The reason why simple fluid aspiration was ineffective and even promoted the recurrence of cyst is that the renal cyst epithelium was not destroyed by sclerosing agents completely and adhered to each other, thus the remained cyst wall can still secrete fluid.[23]

In terms of LD therapy, it has the advantage in high rate of cure and low rate of recurrence and could be thought as a complete treatment of renal cysts.[24] Nasseh et al.[25] collected the data of renal cyst patients treated with LD in their center and 91.3% patients reached symptomatic and radiological success while only one patient got recurrence, which was consistent with our meta-analysis results. As LD operation preferred to excising the complete cyst including all cyst walls, so the leaved tissues were out of secreting function, which lead high cure rate an low recurrence rate.[26] Hence, LD could be the standard in the management of renal cysts, especially suited for patients failed after aspiration-sclerotherapy.[27]

To enhance the efficiency of LD treatment, Lai and colleagues[28] studied the impacts of perirenal pedicled fat tissue wadding technique (PPFTWT) on the recurrence rate during this surgery operation, they found that LD using PPFTWT can decrease the rate of cyst recurrence. Inserting fat tissue into the cavity of the cyst and fixing it prevented the cyst wall from adhering to the residuary cyst wall or surrounding tissue, and contributed

to the secretion drainage and absorption of the remaining cyst wall, thus declined the risk of cyst recurrence.[29] Therefore, laparoscopic de-roofing with PPFTWT may be a better choice in the treatment of renal cysts.

When it comes to complications, our statistics showed there was no significant difference between AS group and LD group, both of which can cause post-treated complications such as fever, infectious, pain, hemorrhage. On account of ethanol as the common sclerosing agents in AS treatment, patients may get alcohol intoxication and lose consciousness even injury femoral nerve due to the rupture of cysts.[30] As for LD therapy, vessels damage and subcutaneous emphysema may happen to patients during the process of cyst ablation and establishing pneumoperitoneum.[31]

The limited included studies in our meta-analysis and the heterogeneity of some date are two main limitations of this study. Due to the lack of researches on the comperation between AS and LD, we included six articles merely and the patients selection bias or difference of provider training/experience could be limitations. Therefore, further studies are expected to confirm our outcomes. As for the heterogeneity, in the study of Bas et al.[12], the difference of treatment techniques may contribute to the heterogeneity in symptomatic successful rate. Besides, in terms of complication rate, the researches of Agarwal et al.[14] and Shao et al.[13] only recorded some severe complications such as port infections so that they might omit some information about comlications after aspiration treatment, which also leaded to the heterogeneity.

Conclusions

Summarily, aspiration-sclerotherapy takes the advantage of less time-consuming, few potential injuries caused by surgery and only local anesthesia demanding, which is more suitable for elder people with renal cysts. Nevertheless, higher radiological cure rate and lower rate of recurrence are the characteristics of laparoscopic de-roofing. Consequently, patients younger or seeking for complete regression are given priority to laparoscopic de-roofing therapy.

Abbreviations

AS: aspiration-sclerotherapy

LD: laparoscopic de-roofing

RR: risk ratio

MD: mean difference

CI: 95% confidence interval

Declarations

Declarations:

Ethics approval and consent to participate: Not applicable

Consent for publication: Not applicable

Availability of data and material: Not applicable

Competing interests:

The authors declare that they have no competing interests.

Funding:

This research was funded by the National Natural Science Foundation of China (81770756) and the National key research and development program of China (SQ2017YFSF090096).

Acknowledgements: Not applicable

Authors' contributions:

PZ performed the literature searches. XL and DH prepared the draft of the manuscript. ZJ, JW and QW reviewed and made revisions to the manuscript. All authors have read and approved the final version of the manuscript.

References

1. Choi JD: **Clinical characteristics and long-term observation of simple renal cysts in a healthy Korean population**. *International urology and nephrology* 2016, **48**(3):319-324.
2. Ozveren B, Onganer E, Turkeri LN: **Simple Renal Cysts: Prevalence, Associated Risk Factors and Follow-Up in a Health Screening Cohort**. *Urology journal* 2016, **13**(1):2569-2575.
3. Kong X, Ma X, Zhang C, Su H, Gong X, Xu D: **Increased risk of kidney damage among Chinese adults with simple renal cyst**. *International urology and nephrology* 2018, **50**(9):1687-1694.
4. Israel GM, Bosniak MA: **An update of the Bosniak renal cyst classification system**. *Urology* 2005, **66**(3):484-488.
5. **<EAU-ESUR-ESTRO-SIOG-Guidelines-on-Prostate-Cancer-large-text.pdf>**.
6. Eissa A, El Sherbiny A, Martorana E, Pirola GM, Puliatti S, Scialpi M, Micali S, Rocco B, Liatsikos E, Breda A *et al*: **Non-conservative management of simple renal cysts in adults: a comprehensive review of literature**. *Minerva urologica e nefrologica = The Italian journal of urology and nephrology* 2018, **70**(2):179-192.
7. Koutlidis N, Joyeux L, Mejean N, Sapin E: **Management of simple renal cyst in children: French multicenter experience of 36 cases and review of the literature**. *Journal of pediatric urology* 2015, **11**(3):113-117.
8. Moher D, Shamseer L Fau - Clarke M, Clarke M Fau - Ghersi D, Ghersi D Fau - Liberati A, Liberati A Fau - Petticrew M, Petticrew M Fau - Shekelle P, Shekelle P Fau - Stewart LA, Stewart LA: **Preferred reporting items for systematic review and meta-analysis protocols (PRISMA-P) 2015 statement**. (2046-4053 (Electronic)).
9. Wells G SB, O'Connell D, Peterson J, Welch V, Losos M, Tugwell P.: **<NEWCASTLE - OTTAWA QUALITY ASSESSMENT SCALE CASE CONTROL STUDIES .pdf>**. 2013.

10. Hozo SP, Djulbegovic B Fau - Hozo I, Hozo I: **Estimating the mean and variance from the median, range, and the size of a sample**. (1471-2288 (Electronic)).
11. Efesoy O, Tek M, Bozlu M, Doruk HE: **Comparison of single-session aspiration and ethanol sclerotherapy with laparoscopic de-roofing in the management of symptomatic simple renal cysts**. *Turkish journal of urology* 2015, **41**(1):14-19.
12. Bas O, Nalbant I, Can Sener N, Firat H, Yesil S, Zengin K, Yalcinkaya F, Imamoglu A: **Management of renal cysts**. *JSLS : Journal of the Society of Laparoendoscopic Surgeons* 2015, **19**(1):e2014.00097.
13. Shao Q, Xu J, Adams T, Tao S, Cui Y, Shen H, Cao W, Xie J, Fan Y, Zhang Y *et al*: **Comparison of aspiration-sclerotherapy versus laparoscopic decortication in management of symptomatic simple renal cysts**. *Journal of X-ray science and technology* 2013, **21**(3):419-428.
14. Agarwal M, Agrawal MS, Mittal R, Sachan V: **A randomized study of aspiration and sclerotherapy versus laparoscopic deroofing in management of symptomatic simple renal cysts**. *Journal of endourology* 2012, **26**(5):561-565.
15. Arisan S, Dalkilinc A, Caskurlu T, Sonmez NC, Guney S, Ergenekon E: **Laparoscopic unroofing and aspiration-sclerotherapy in the management of symptomatic simple renal cysts**. *TheScientificWorldJournal* 2006, **6**:2296-2301.
16. A.A. OKEKE AEM, FXKJ, TIMONEY AG: **A comparison of aspiration and sclerotherapy with laparoscopic de-roofing in the management of symptomatic simple renal cysts**. *BJU international* 2003.
17. Kim SM, Chung TH, Oh MS, Kwon SG, Bae SJ: **Relationship of simple renal cyst to hypertension**. (2005-6443 (Print)).
18. Qin X, Ye L, Zhang H, Dai B, Zhu Y, Shi G, Ye D: **Complicated variation of simple renal cyst usually means malignancy: results from a cohort study**. *World journal of surgical oncology* 2014, **12**:316.
19. Monville H, Wagner L, Dibo D, Soustelle L, Muyshondt C, Droupy S, Costa P: **[Percutaneous ethanol sclerotherapy of symptomatic renal cysts: results after 4 years]**. *Progres en urologie : journal de l'Association francaise d'urologie et de la Societe francaise d'urologie* 2014, **24**(6):353-358.
20. Ali TA, Abdelaal MA, Enite A, Badran YA: **Ultrasound-guided percutaneous sclerotherapy of simple renal cysts with n-butyl cyanoacrylate and iodized oil mixture as an outpatient procedure**. *Urology annals* 2016, **8**(1):51-55.
21. Cheng D, Amin P Fau - Ha TV, Ha TV: **Percutaneous sclerotherapy of cystic lesions**. (0739-9529 (Print)).
22. Zhong J, Sun D, Hu Z, Chen Y, Cai H: **Optimal path of ultrasound-guided percutaneous needle aspiration of infracapsule hepatic and renal cysts**. *Chinese journal of interventional imaging and therapy* 2016, **13**(1):25-28.
23. Skolarikos A, Laguna Mp Fau - de la Rosette JJMCH, de la Rosette JJ: **Conservative and radiological management of simple renal cysts: a comprehensive review**. (1464-410X (Electronic)).
24. Marte A, Pintozzi L: **Laparoscopic treatment of symptomatic simple renal cysts in children: single-center experience**. *La Pediatria medica e chirurgica : Medical and surgical pediatrics* 2018, **40**(1).
25. Nasseh H, Hamidi Madani A, Ghanbari A, Arfa S: **Laparoscopic unroofing of symptomatic kidney cysts. A single center experience**. *Minerva urologica e nefrologica = The Italian journal of urology and nephrology* 2013, **65**(4):285-289.

26. Chen Z, Chen X, Luo YC, He Y, Li NN, Wu ZH: **Retroperitoneoscopic decortication of symptomatic peripelvic renal cysts: Chinese experience**. *Urology* 2011, **78**(4):803-807.
27. Gadelmoula M, KurKar A, Shalaby MM: **The laparoscopic management of symptomatic renal cysts: A single-centre experience**. *Arab journal of urology* 2014, **12**(2):173-177.
28. Lai S, Xu X, Diao T, Jiao B, Jiang Z, Zhang G: **The efficacy of retroperitoneal laparoscopic deroofing of simple renal cyst with perirenal fat tissue wadding technique: A retrospective study**. *Medicine* 2017, **96**(41):e8259.
29. Ryu DS, Oh TH: **Laparoscopic decortication of large renal cysts: a comparison between the transperitoneal and retroperitoneal approaches**. (1557-9034 (Electronic)).
30. Ashraf A, Karami My Fau - Amanat A, Amanat A: **Femoral nerve injury as a complication of percutaneous simple renal cyst sclerotherapy with ethanol: a case report**. (1687-9635 (Electronic)).
31. Al-Otaibi K: **Complications of 411 laparoscopic urological procedures: A single surgeon experience**. (0974-7796 (Print)).

Tables

Table 1:

Author	Country	Treat-ment	Sample number (n)	mean age (y/o)	Male ratio (%)	Mean diameter of cyst (cm)	Clinical presentation (n)				Follow up (month)	NOS
							Renal pain	Renal lump	Hypert-ension	Hema-turia		
Efesoy[1] 2015	Turkey	AS	38	53.2 ± 13.7	57.9	9.5 ± 2.9	36				6	7
		LD	42	51.1 ± 11.6	54.8	8.5 ± 2.7	38					
Bas[2] 2015	Turkey	AS	35	59	62.8	7.2	21	7	3	4	35	7
		LD	149	57.7	56.8	7.9	119	16	5	9		
Shao[3] 2013	China	AS	986	55.3 ± 14.7	53.2	6.3 ± 1.4	494		41	61	12	7
		LD	208	46.8 ± 11.9	41.8	7.5 ± 2.3	101		19	16		
Agarwal[4] 2012	India	AS	20	46.4 ± 9.48	60	6.58 ± 0.85	10	4		2	3	8
		LD	20	44.8 ± 14.28	50	7.28 ± 0.94	9	3		1		
Arisan[5] 2006	Turkey	AS	21	60	52.4	6.0	21	0	4		12	8
		LD	15	57	40	9.0	15	0				
OKEKE[6] 2003	UK	AS	6	50.8	33.3	6.0	5	1			17	7
		LD	7	50.9	28.6	8.0	7	0				

Table title: the characteristics of patients included

Table legend:

AS: aspiration-sclerotherapy

LD: laparoscopic de-roofing

NOS: Newcastle–Ottaa Scale

1. Efesoy O, Tek M, Bozlu M, Doruk HE (2015) Comparison of single-session aspiration and ethanol sclerotherapy with laparoscopic de-roofing in the management of symptomatic simple renal cysts. Turkish journal of urology 41 (1):14-19. doi:10.5152/tud.2015.77675
2. Bas O, Nalbant I, Can Sener N, Firat H, Yesil S, Zengin K, Yalcinkaya F, Imamoglu A (2015) Management of renal cysts. JSLS : Journal of the Society of Laparoendoscopic Surgeons 19 (1):e2014.00097. doi:10.4293/jsls.2014.00097
3. Shao Q, Xu J, Adams T, Tao S, Cui Y, Shen H, Cao W, Xie J, Fan Y, Zhang Y, Huang M (2013) Comparison of aspiration-sclerotherapy versus laparoscopic decortication in management of symptomatic simple renal cysts. Journal of X-ray science and technology 21 (3):419-428. doi:10.3233/xst-130393
4. Agarwal M, Agrawal MS, Mittal R, Sachan V (2012) A randomized study of aspiration and sclerotherapy versus laparoscopic deroofing in management of symptomatic simple renal cysts. Journal of endourology 26 (5):561-565. doi:10.1089/end.2011.0559
5. Arisan S, Dalkilinc A, Caskurlu T, Sonmez NC, Guney S, Ergenekon E (2006) Laparoscopic unroofing and aspiration-sclerotherapy in the management of symptomatic simple renal cysts. TheScientificWorldJournal 6:2296-2301. doi:10.1100/tsw.2006.358
6. A.A. OKEKE AEM, □ FXKJ, TIMONEY AG (2003) A comparison of aspiration and sclerotherapy with laparoscopic de-roofing in the management of symptomatic simple renal cysts. BJU international. doi:10.1046/j.1464-410X.2003.04417.x

Figures

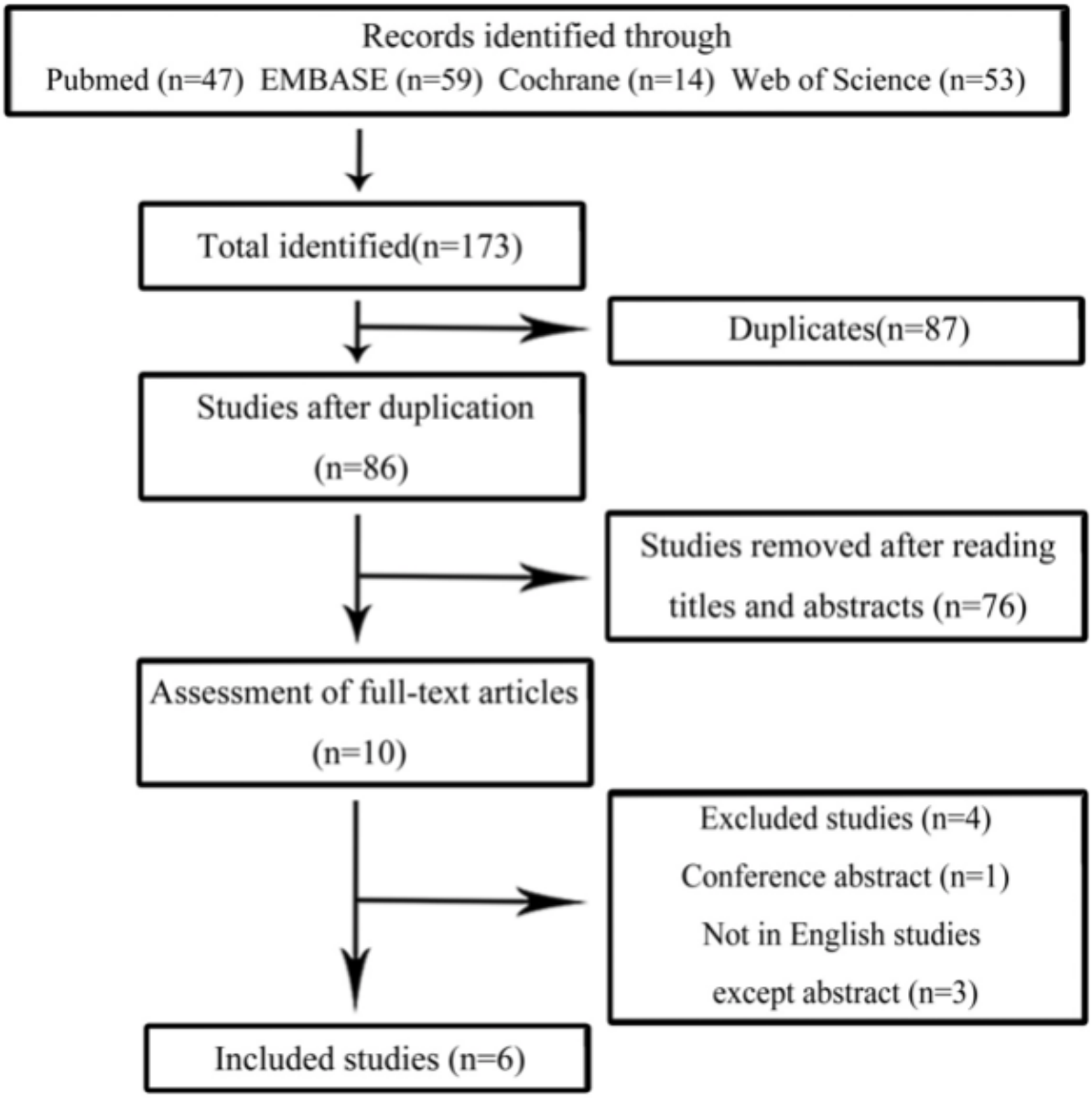

Figure 1

Flow chart of the strategy of search and selection

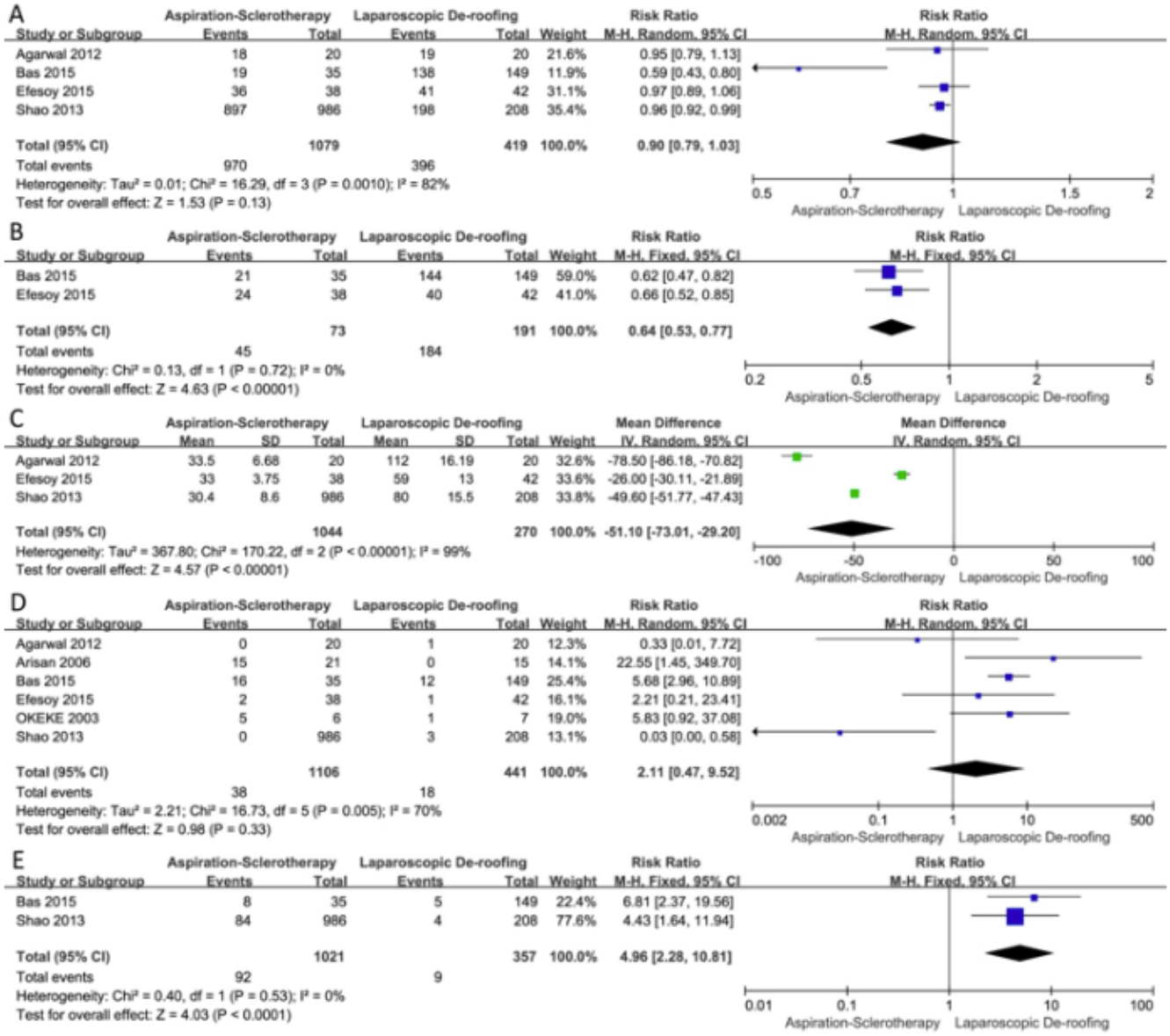

Figure 2

Flow chart of the strategy of search and selection