Clinical Outcomes in Patients With Minimally Invasive Surgical Approach Combined With Plantar Tendon Transfer Repairing Neglected Achilles Tendon Rupture Compared to the Conventional Approach of V-Y Tendon Plasty: A Retrospective Study With Two Years Follow-Up

Feiyu Cai
First Affiliated Hospital of Xinjiang Medical University
Kai Liu
First Affiliated Hospital of Xinjiang Medical University
Yanshi Liu
First Affiliated Hospital of Xinjiang Medical University
Biao Luo
First Affiliated Hospital of Xinjiang Medical University
Pengfei Li
First Affiliated Hospital of Xinjiang Medical University
Jiasharete Jielile
First Affiliated Hospital of Xinjiang Medical University
Aihemaitijiang Yusufu (ahmatjang@163.com)
First Affiliated Hospital of Xinjiang Medical University

Research Article

Keywords: Achilles tendon rupture, minimally invasive technique, tendon reconstruction, graft, exercise

Posted Date: February 24th, 2021

DOI: https://doi.org/10.21203/rs.3.rs-228491/v1

Abstract

Background

Unlike acute Achilles tendon rupture (AATR), neglected Achilles tendon rupture (NATR) requires usually tendon grafting procedures for repair tendon defects caused by removing scar tissue. The conventional open surgery of V-Y tendon plasty and minimally invasive technique with plantar tendon transfer had been described, but the long-term efficacy between the two techniques still needs further certification.

Methods

Between February 1, 2008, and July 31, 2018. All of 46 patients with neglected Achilles tendon rupture, 25 patients in group A (21 males and 4 females; age, 34.28 ± 6.97 years) underwent the conventional operation of V-Y tendon plasty, and 21 patients in group B (14 males and 7 females; age, 35.29 ± 7.42 years) were treated by the minimally invasive technique. Two years follow-up was performed for the functional recovery with examinations of the Achilles tendon rupture score (ATRS), American Orthopaedic Foot and Ankle Society (AOFAS) Ankle Hind-Foot Scale Score, dorsiflexion, calf circumference, and heel raise test.

Results

Patient characteristics between the two groups were similar. The functional score of ATRS and AOFAS in Group B was higher than patients in group A at postoperative months 3, 6, and 12, while there is no difference at month 24. In group A, there were three patients exposed to soft tissue infections (two superficial infections and one deep infection) and one case with tendon exposure. In group B, a patient with tendon re-rupture was observed. There was no difference in dorsiflexion and calf circumference at follow-up two years and the much better recovery in heel raise test group B than A.

Conclusions

Two different techniques produced a significant functional improvement, and return to sports. However, this study demonstrated that the minimally invasive technique was recommended for patients with a tendon defect less than 6 cm and who have an urgent demand to return to the sports.

Introduction

Achilles tendon (AT) is the largest and strongest tendon as well as the most frequently ruptured tendon in the human body[1]. Acute Achilles tendon rupture (AATR) was commonly caused by vigorous sports such as football, basketball, and tennis, which often developed a neglected Achilles tendon rupture (NATR)

with misdiagnosis for more than 4 weeks[2]. A greater tendency of postoperative complications and functional damages could take place in patients with NATR than in acute Achilles tendon rupture[3]. Hence, there is a consent that NATR should be treated with operation unless patients with contraindications of surgery[4]. And Wong J et al. also demonstrated that the increasing rate of AT re-rupture and decreased functional results are related to nonoperative treatment closely[5].

NATR, which causes the gap formed between the proximal and distal stumps and is filled with numerous scar tissues,might be acquired by the AATR with non-operative treatment for four weeks[6, 7]. This scar tissue is too fragile than the normal tendon to meet a good functional recovery. It's suggested to be excised in operation clearly, though the end-to-end repair is difficult to perform. The conventional surgery of V-Y tendon plasty has been reported by some works of literature to repair NATR with a favorable clinical efficacy[8, 9]. However, a 10-15cm longitudinal, slightly curved central skin incision would be created to operate the surgery, which will lead to severe trauma and a long postoperative scar on the skin of the posterior leg undoubtedly. On the other hand, various types of minimally invasive surgical approaches have been reported by many researchers for the treatment of NATR with good functional recovery and fewer complications[10, 11]. Mafulli N and Piontek T et al. also asserted that minimally invasive techniques may be advantageous compared with conventional open techniques since the latter is associated with a higher rate of postoperative infection[12, 13]. However, there are still few studies comparing the advantages and disadvantages between the conventional operation and the minimally invasive technique with plantar tendon transfer in the treatment of patients with NATR, as well as the long-term clinical outcome of the two surgical plans.

In this study, the retrospective study was used to identify the applicable conditions of two different surgeries and evaluate the clinical outcome by the Achilles tendon Total Rupture Score (ATRS), American Orthopaedic Foot and Ankle Society (AOFAS) Ankle Hind-Foot Scale Score, dorsiflexion, calf circumference, and heel raise test.

Materials And Methods

Patients

Between February 1, 2008, and July 31, 2018, we performed a retrospective analysis of all patients undergoing AT reconstruction after approval from our institutional review board. The study consisted of 46 patients (mean age, 34.74 ± 7.11 years; range, 17– 56 years) who have operated a tendon reconstruction with the conventional approach of V-Y tendon plasty or the minimally invasive technique with plantar tendon transfer for the excision process of injured tendon. All of them were diagnosed NATR by magnetic resonance imaging (MRI) and ultrasonography with the main cause of misdiagnosis for least 4 weeks. Among them, 25 patients in group A (mean age, 34.28 ± 6.97 years; males 21 and females 4) who underwent the conventional operation have the tendon defect of 7.04cm ± 1.90 cm (range, 4.0–9.0 cm) and 21 patients in group B (mean age 35.29 ± 7.42 years; males 14 and females 7) who were

treated with the minimally invasive technique with the defect of 4.05cm ± 1.32 cm (range, 2.0–6.0 cm) (Table 1). The operation time and blood loss in surgery and the complications of re-rupture, soft tissue infection, tendon exposure, tendon elongation, and adhesion in postoperative management were collected for analysis. Patients in two groups were taught standard physical exercise therapy and post-operative rehabilitation without immobilization, whose curative effect has been illustrated in our previous research[14]. The evaluation of ATRS, AOFAS were performed at months 3, 6, 12, and 24, and the dorsiflexion, the calf circumference, and the heel raise test were evaluated at follow-up month 24.

Table 1
Characteristics of the study participants (n = 46)

Items	Group A	Group B	*P*-value
Sample size (n)	25	21	-
Age (years)	34.28 ± 6.97	35.29 ± 7.42	0.638
Gender (male/female)	21/4	14/7	0.175
Affected side (life/right)	13/12	10/11	0.770
Body mass index (kg/m^2)	23.07 ± 4.38	22.78 ± 2.56	0.790
Interval from injury to surgery (days)	53.88 ± 15.07	54.24 ± 13.07	0.932
Operative defect (cm)	7.04 ± 1.90	4.05 ± 1.32	<0.001

Abbreviations: BMI, body mass index

Notes: Values are presented as median ± standard deviation;

p values are indicated.

Surgical Procedure

All surgical procedures were performed by the same surgeon, with the support of the same team. The epidural analgesia and stabilized with a tourniquet in the prone position were applied in all patients. All patients were classified into two groups according to different surgical procedures. 25 patients underwent a conventional surgical approach of V-Y tendon plasty in group A. Of these patients, a 15cm longitudinal, slightly curved central skin incision was created from the middle third of the gastrocnemius muscle, and it was also suggested to curve towards the distal end medially to reduce the risk of injury to the sural nerve[15]. The surgical procedure has been relatively mature, and the details were showed as follows (Fig. 1).

The 21 patients, treated with a novel minimally invasive surgical approach that we have reported in previous research, were contained in Group B[16]. Achilles tendon were exposed by two separate longitudinal incisions, which resembled a scythe or letter “J” (Fig. 2)[17]. If necessary, two 3–4 cm

connective incisions around the Kager's triangle and extended to the tendon rupture site were permitted. Careful dissection and complete release of tissue adhesions around the Achilles tendon, and the osteophytes with calcaneal tubercle hyperplasia were removed and the scar tissue between the distal and proximal ends of the Achilles tendon was removed too. The ankle joint was in an extreme plantarflexion position, and the mean gap between the distal and proximal end of the Achilles tendon rupture was 4.05 ± 1.32 cm (range, 2–6 cm) in group B. In the extreme plantarflexion of the ankle joint, PDS-II can be used as the traction line twice, respectively, through the distal incision of the Achilles tendon, and continuous traction for more than ten minutes. From the distal incision, 3–6 longitudinal holes, approximate 2.0cm deep, were drilled in the calcaneus within the calcaneal insertion using a 2.5mm (in diameter) Kirschner wire to ensure the regenerated tendon attached to the bone firmly. After that, a transverse percutaneous calcaneal bone tunnel was drilled with a 3.0mm (in diameter) Kirschner wire to prepare for percutaneous "Yurt bone" suturing[14, 17, 18]. The plantar tendon was considered to be the most ideal biological suture graft material for strengthening the repair of the Achilles tendon. And the plantar tendon was used to bridge the ends of the distal and proximal Achilles tendon stump which play a dual role in tendon transplantation and bridging suture.

Postoperative Management

According to our previous research, similar postoperative management in all patients was recommended[14]. All patients in two groups were advised to lie prone or lateral on the bed without fixation or orthosis and with the knee at 60° flexion and the ankle joint at 45° plantar flexion. In addition, patients were instructed for an early active motion of the ankle and knee joints by a detailed physical rehabilitation regimen from postoperative day 1. In this program, the increasing intensity of motion exercises was initiated at postoperative day 10, followed by another increase at week 3. Full weight-bearing exercise, standing on the toes, and squatting were initiated at postoperative week 4. It should be noted that the exercise of tiptoe stepping on the operated side of the tendon on the balance 3 ~ 9 kg from postoperative day 3 was a novel component of the present program, which was greatly useful not only for reducing the patient's fear of early motion of the ankle joint but also for the surgeon to determine the time of walking with weight-bearing exercises according to the increase in tiptoe stepping.

Statistical analysis

Statistical analysis was performed using SPSS (Version 22.0; IBM). The measurement data were assessed for normal or non-normal distribution. An independent sample *T*-test was used to analyze continuous variables including age, body mass index (BMI), the interval from injury to surgery, operative defect, operation time, blood loss, and the postoperative evaluation of ATRS, AOFAS, Dorsiflexion, Calf circumference, and Heel raise test. And the categorical variables of gender and affected side were analyzed by the Mann-Whitney *U*-test. The difference was statistically significant ($P<0.05$).

Results

All 46 patients with NATR were admitted to our hospital between February 1, 2008, and July 31, 2018. Of these patients, 25 patients (age, 34.28 ± 6.97 years) who underwent the conventional operation of V-Y tendon plasty were arranged in Group A, and 21 patients (age, 35.29 ± 7.42 years) were treated by the minimally invasive surgical approach in Group B. The mean time from the injury to operative treatment in group A and B was 53.88 ± 15.07 days (range, 31–79 days) and 54.24 ± 13.07 days (range, 34–81 days) respectively, and the defects in two groups after the debridement of the scar tissue of the Achilles tendon were 7.04 ± 1.90 cm (range, 4–11 cm) and 4.05 ± 1.32 cm (range, 2–6 cm), respectively (Table 1).

There were significant advantages of group B than A in operation time and blood loss ($P < 0.001$). Of 25 patients in group A, the soft-tissue infection was exposed to three patients which included two surface infections and one deep infection. And a tendon exposure just exposed to group A. On the other hand, only one tendon re-rupture was found in group B. Of all patients, there was no occurrence of tendon elongation or adhesion by ultrasonography, MSCT in two groups (Table 2).

Table 2
Inter-operative evaluations and post-operative complications of two groups.

	Group A	**Group B**	***P*-value**
Operation time (min)	162.40 ± 17.39	133.81 ± 17.74	<0.001
Blood loss in operation (ml)	112.60 ± 32.76	41.91 ± 12.09	<0.001
Rerupture	0	1	-
Surface infection	2	0	-
Deep infection	1	0	-
Tendon exposure	1	0	-
Tendon elongation	0	0	-
Adhesion	0	0	-

Notes: Values are presented as median ± standard deviation;

p values are indicated.

Mean ATRS in group B was 61.36, 77.24, and 91.92 at postoperative month 3, 6, and 12, respectively, significantly higher than that in group A with 42.10, 66.10, and 81.05, respectively, but there was no difference in month 24 (Table 3). Furthermore, similar results were shown in AOFAS of were 55.32, 75.96, and 93.36 at the follow-up months 3, 6, and 12 in group B, respectively, higher than group A with 45.48, 69.00, and 83.57, and no difference in month 24 (Table 3). Two groups both have good recovery of calf circumference, dorsiflexion, and heel raise test at follow-up months 24 (Fig. 3). However, there were much better in group B than group A by the heel raise test (Fig. 4) (Table 4).

Discussion

NATR has been an important challenge to surgeons for a long time, due to the high rate of misdiagnosis of AATR more than four weeks [2]. A large amount of scar tissue filled in the gap between the proximal and distal ends of the ruptured Achilles tendon, which will take a negative impact on the normal reconstruction of the tendon. Thus, an operation removing this scar tissue for a better functional recovery was required undoubtedly. However, the conventional operation repairing the Achilles tenon always need to perform a large skin incision. Therefore, a minimally invasive surgical approach that can complete the clear tissue is the direction that surgeons have been exploring.

Various operative techniques have been reported to repair NATR with a good outcome [8, 9, 19–22]. For instance,V-Y tendon plasty combined with gastrocnemius aponeurosis turndown restoring the tendon length was reported by Bilgin et al. for repairing tendon defects of 4 to 6 cm successfully[22]. Furthermore, a case report published by Leitner et al. demonstrated that a tendon defect of up to 10 cm was treated by V-Y advancement in three patients[23]. Although such studies have illustrated the obvious recovery effect via the conventional open techniques, the perplexing complications that might be related to the large traumatic surgeries were not difficult to notice. In contrast, some researchers demonstrated that patients have a better functional recovery with more mild muscle injuries and low complications via minimally invasive technique[24–28]. However, the clinical outcome of patients with NATR who underwent a minimally invasive surgical approach still needs to evaluate furtherly. In the present study, we compared the 25 patients who underwent the conventional open operation (V-Y tendon plasty) with the 21 patients who were treated by the two separate minimally invasive surgical approaches that have been reported in our previous research to provide an experience for the operative selection to treat in NATR.

In this study, the minimally invasive surgical technique involved two joint incisions in the shape of a longitudinal flipped scythe or letter “J” is currently our technique of choice for repairing AT partial injury in NART patients, as we feel the additional biological properties of the minimal incision are important for the higher activity demands[14, 17, 29]. In this study, the two incisions were disconnected and shortened to approximately 3.5cm respectively[16]. Along the gap between the surface projections of Kager’s triangle and the posterior tibial artery to the border of Kager’s triangle, the curves were extended by the distal sections; the proximal sections stopped at 12-14cm approximately above the AT insertion on the posterior calcaneus. The liner sections' length of the incisions was almost 3-4cm. The veins which supply blood to the wound to promote healing were protected by this particular incision shape effectively. In addition, the separation of the proximal ends of the ruptured tendons from the surrounding tissues to pull out the tendon for tension-free suturing should be avoided to minimize the impact on the local blood circulation.

Apart from the above advantages, there was a modest impact on the local blood circulation, rapid recovery of sports function, and fewer complications are reported in the minimally invasive surgical approach too. In the eye of anatomy, the blood circulation of AT depends on the posterior tibial and peroneal arteries through the tendon sheath arteries. Besides, the sheath arteries were nourished by the proximal peroneal artery, which connects with the posterior tibial artery to supply sheath arteries to the heel together, in the middle of the surface projection of Kager's triangle (at the same horizontal level of

the ankle joint). Since that, there are traffic veins between the saphenous and the small saphenous. Unfortunately, these veins are in the great possibility of damaged unavoidably when V-Y tendon plasty was performed, which will put a negative impact on tendon healing further. In our observation, compared with the conventional approach of the V-Y tendon plasty technique, the minimally invasive technique provides a better situation for patient's postoperative exercise with less blood loss and short operation time (Table 2).

Complications related to the avascular nature of the posterior midline or "S" incision, are common, including high skin tension after suturing and wrinkled heavily, increasing the chance of necrosis of skin as well as soft tissue infection, which may cause tendon exposure eventually. In group A, there were three cases of soft tissue infection, two cases of superficial infections, and one case of deep infection, and there was one case of tendon exposure. In group B, there was one case of Achilles tendon re-rupture (Table 2). The same results have also been reported by Bąkowski et al. that patients who underwent traditional open techniques might be associated with a higher risk to develop the necrosis of skin and infection[10]. Furthermore, the pressure caused by the shortened Achilles tendon will act on the incision surface of conventional open operation, which may affect the healing of the incision, and increase the incidence of Achilles tendon exposure. And the functional exercise of plantarflexion can exaggerate the pressure and wrinkling of the skin further, which may increase the chance of infection[16]. The high rate of postoperative AT defects in largely invasive technique was reported by Mafulli et al., resulting in 20% of patients underwent a free gracilis tendon graft procedure and peroneus brevis tendon transfer was performed in 6% of patients[30, 31]. On the other hand, the study published by Mafulli et al. achieved a good outcome as operating peroneus brevis tendon transfer with minimally invasive in chronic AT rupture patients[26]. Therefore, it is inevitable that the conventional open surgery will damage the soft tissue in the ankle and the course of tendon restoring, but there is an obvious advantage engaged in this surgical plan to repair a large tendon defect after resection of scar tissue (Table 1).

In a word, the minimally invasive surgical approach takes advantage of subcutaneous adipose tissue between the malleolus and AT and beneath Kager's triangle to promote incision closure and wound healing[14, 17, 18, 32]. The scythe-shaped incision chosen by the above surgery alleviates the pressure of the wound during early functional exercise, which can prevent tendon exposure and minimizes damage to the scar by shoes effectively. In this present study, the clinical outcome in two groups was evaluated by ARTS, AOFAS, dorsiflexion, calf circumference, and Heel raise test with least two years follow-up (Tables 3 and 4). Compared with group A, patients with the minimally invasive surgical approach experienced a desirable functional recovery at months 3, 6, and 12. However, the difference between the two groups was shrunk over time gradually and there was no difference between the two groups at year two (Table 3). Moreover, patients in group B had a better outcome in heel raise test compared with patients in group A at follow-up year two, which may relate to earlier functional exercise (Table 4). Patients with a minimally invasive technique more like to accept an early high-intensity ankle exercise, which will better for the early functional recovery and the heel raise. Therefore, for patients with large Achilles tendon defects, we still recommend the use of the conventional operation to repair, but for patients with the defect (≤ 6cm), we

deem that the minimally invasive surgical approach with less trauma, fewer complications, and high aesthetics should be advised.

Conclusion

In the present study, patients who underwent the minimally invasive surgical approach showed superiority in decreasing blood loss and accelerating wound healing, which prevented tendon infection and exposure. Compared with the conventionally traumatic technique, the minimally invasive surgical approach allowed earlier functional rehabilitation therapy, which promoted reconstruction of the Achilles tendon[14, 17, 29]. And it is an optimal choice to treat patients with less tendon defect (≤ 6cm) after removing scar tissue.

Abbreviations

AT: Achilles tendon

AATR: acute Achilles tendon rupture

NATR: neglected Achilles tendon rupture

ATRS: Achilles tendon rupture score

AOFAS: American Orthopaedic Foot and Ankle Society

BMI: body mass index

MRI: magnetic resonance imaging

Declarations

Ethics approval and consent to participate

All methods in this retrospective study were carried out in accordance with the Declaration of Helsinki. This study was approved by the Ethics Committee of The First Aliated Hospital of Xinjiang Medical University. Written informed consent was obtained from all patients for their data to be recorded in our study.

Consent for publication

Informed consent was obtained from all patients for their data to be published in our study.

Availability of data and materials

The datasets analyzed during the current study are available from the corresponding author on reasonable request.

Competing interests

The authors declare that they have no competing interests.

Funding

This study was funded by the grants from National Natural Science Foundation of China (No. 81560357). The funding body was involved in the collection, analysis, and interpretation of data by supporting with salary for the time needed. They were not involved in the design or writing the manuscript

Authors' Contributions

FYC: Conducted the study. Collected, analyzed, and interpreted the data. Wrote the manuscript.

KL: Designed the study. Interpreted the data. Edited the manuscript.

YSL: Planned the project. Interpreted the data.

BL and PFL: Collected, analyzed, and interpreted the data.

JJ: Planned the project. Reviewed the manuscript.

AY: Planned the project. Reviewed the manuscript.

Final approval of the version to be submitted: FYC, KL, YSL, BL, PFL, JJ, AY

Acknowledgments

Not applicable

References

1. Maffulli N, Waterston SW, Squair J, Reaper J, Douglas AS. Changing incidence of Achilles tendon rupture in Scotland: a 15-year study. CLIN J SPORT MED 1999;9:157–60.
2. Nilsson-Helander K, Sward L, Silbernagel KG, Thomee R, Eriksson BI, Karlsson J. A new surgical method to treat chronic ruptures and reruptures of the Achilles tendon. Knee Surg Sports Traumatol Arthrosc 2008;16:614–20.
3. Kosanovic M, Brilej D. Chronic rupture of Achilles tendon: is the percutaneous suture technique effective? Arch Orthop Trauma Surg 2008;128:211–6.
4. Maffulli N, Via AG, Oliva F. Chronic Achilles Tendon Disorders: Tendinopathy and Chronic Rupture. Clin Sports Med 2015;34:607–24.

5. Wong J, Barrass V, Maffulli N. Quantitative review of operative and nonoperative management of achilles tendon ruptures. Am J Sports Med 2002;30:565–75.
6. Maffulli N, Dymond NP, Capasso G. Ultrasonographic findings in subcutaneous rupture of Achilles tendon. J Sports Med Phys Fitness 1989;29:365–8.
7. Kraeutler MJ, Purcell JM, Hunt KJ. Chronic Achilles Tendon Ruptures. FOOT ANKLE INT 2017;38:921–9.
8. Guclu B, Basat HC, Yildirim T, Bozduman O, Us AK. Long-term Results of Chronic Achilles Tendon Ruptures Repaired With V-Y Tendon Plasty and Fascia Turndown. FOOT ANKLE INT 2016;37:737–42.
9. Lin YJ, Duan XJ, Yang L. V-Y Tendon Plasty for Reconstruction of Chronic Achilles Tendon Rupture: A Medium-term and Long-term Follow-up. ORTHOP SURG 2019;11:109–16.
10. Bakowski P, Ciemniewska-Gorzela K, Talaska K, Gorecki J, Wojtkowiak D, Kerkhoffs G, et al. Minimally invasive reconstruction technique for chronic Achilles tendon tears allows rapid return to walking and leads to good functional recovery. Knee Surg Sports Traumatol Arthrosc 2020;28:305–11.
11. Usuelli FG, D'Ambrosi R, Manzi L, Indino C, Villafane JH, Berjano P. Clinical Outcomes and Return to Sports in Patients with Chronic Achilles Tendon Rupture after Minimally Invasive Reconstruction with Semitendinosus Tendon Graft Transfer. Joints 2017;5:212–6.
12. Maffulli N, Oliva F, Maffulli GD, Buono AD, Gougoulias N. Surgical management of chronic Achilles tendon ruptures using less invasive techniques. FOOT ANKLE SURG 2018;24:164–70.
13. Piontek T, Bakowski P, Ciemniewska-Gorzela K, Grygorowicz M. Minimally invasive, endoscopic Achilles tendon reconstruction using semitendinosus and gracilis tendons with Endobutton stabilization. BMC Musculoskelet Disord 2016;17:247.
14. Jielile J, Badalihan A, Qianman B, Satewalede T, Wuerliebieke J, Kelamu M, et al. Clinical outcome of exercise therapy and early post-operative rehabilitation for treatment of neglected Achilles tendon rupture: a randomized study. Knee Surg Sports Traumatol Arthrosc 2016;24:2148–55.
15. Nilsson-Helander K, Thomee R, Silbernagel KG, Thomee P, Faxen E, Eriksson BI, et al. The Achilles tendon Total Rupture Score (ATRS): development and validation. Am J Sports Med 2007;35:421–6.
16. Aisaiding A, Wang J, Maimaiti R, Jialihasi A, Aibek R, Qianman B, et al. A novel minimally invasive surgery combined with early exercise therapy promoting tendon regeneration in the treatment of spontaneous Achilles tendon rupture. INJURY 2018;49:712–9.
17. Jielile J, Sabirhazi G, Chen J, Aldyarhan K, Zheyiken J, Zhao Q, et al. Novel surgical technique and early kinesiotherapy for acute Achilles tendon rupture. FOOT ANKLE INT 2012;33:1119–27.
18. Badalihan A, Aihemaiti A, Shawutali N, Jielile J, Jialihasi A, Tangkejie W, et al. Outcome of a one-stage tensile stress surgical technique and early postoperative rehabilitation in the treatment of neglected achilles tendon rupture. J FOOT ANKLE SURG 2015;54:153–9.
19. Lin Y, Yang L, Yin L, Duan X. Surgical Strategy for the Chronic Achilles Tendon Rupture. BIOMED RES INT 2016;2016:1416971.

20. Shi JD, Jin J, Li B, Zhang ZJ, Tengwang SY, Lu YS. [Clinical effects of suture anchor with V-Y tenoplasty in treating old Achilles tendon rupture]. Zhongguo Gu Shang 2019;32:727–30.
21. Lee KB, Park YH, Yoon TR, Chung JY. Reconstruction of neglected Achilles tendon rupture using the flexor hallucis tendon. Knee Surg Sports Traumatol Arthrosc 2009;17:316–20.
22. Us AK, Bilgin SS, Aydin T, Mergen E. Repair of neglected Achilles tendon ruptures: procedures and functional results. Arch Orthop Trauma Surg 1997;116:408–11.
23. Leitner A, Voigt C, Rahmanzadeh R. Treatment of extensive aseptic defects in old Achilles tendon ruptures: methods and case reports. Foot Ankle 1992;13:176–80.
24. DeCarbo WT, Bullock MJ. Midsubstance Tendinopathy, Surgical Management. Clin Podiatr Med Surg 2017;34:175–93.
25. Jiang XJ, Shen JJ, Huang JF, Tong PJ. Reconstruction of Myerson type III chronic Achilles tendon ruptures using semitendinosus tendon and gracilis tendon autograft. J Orthop Surg (Hong Kong) 2019;27:615493005.
26. Maffulli N, Oliva F, Costa V, Del BA. The management of chronic rupture of the Achilles tendon: minimally invasive peroneus brevis tendon transfer. BONE JOINT J 2015;97-B:353–7.
27. Maffulli N, Oliva F, Maffulli GD, Buono AD, Gougoulias N. Surgical management of chronic Achilles tendon ruptures using less invasive techniques. FOOT ANKLE SURG 2018;24:164–70.
28. Nishikawa D, Duarte FA, Saito GH, de Cesar NC, Monteiro AC, Prado MP, et al. Reconstruction of the Peroneus Brevis Tendon Tears with Semitendinosus Tendon Autograft. Case Rep Orthop 2019;2019:5014687.
29. Benjilali L, Benhima H, Zahlane M, Essaadouni L. [Spontaneous Achilles tendon rupture as early manifestation of systemic lupus erythematosus]. REV MED INTERNE 2012;33:e47-8.
30. Maffulli N, Spiezia F, Testa V, Capasso G, Longo UG, Denaro V. Free gracilis tendon graft for reconstruction of chronic tears of the Achilles tendon. J BONE JOINT SURG AM 2012;94:906–10.
31. Maffulli N, Spiezia F, Pintore E, Longo UG, Testa V, Capasso G, et al. Peroneus brevis tendon transfer for reconstruction of chronic tears of the Achilles tendon: a long-term follow-up study. J BONE JOINT SURG AM 2012;94:901–5.
32. Kober J, Gugerell A, Schmid M, Zeyda M, Buchberger E, Nickl S, et al. Wound Healing Effect of Conditioned Media Obtained From Adipose Tissue on Human Skin Cells: A Comparative in Vitro Study. Ann Plast Surg 2016;77:156–63.

Tables

Table 3 and 4 not available with this version

Figures

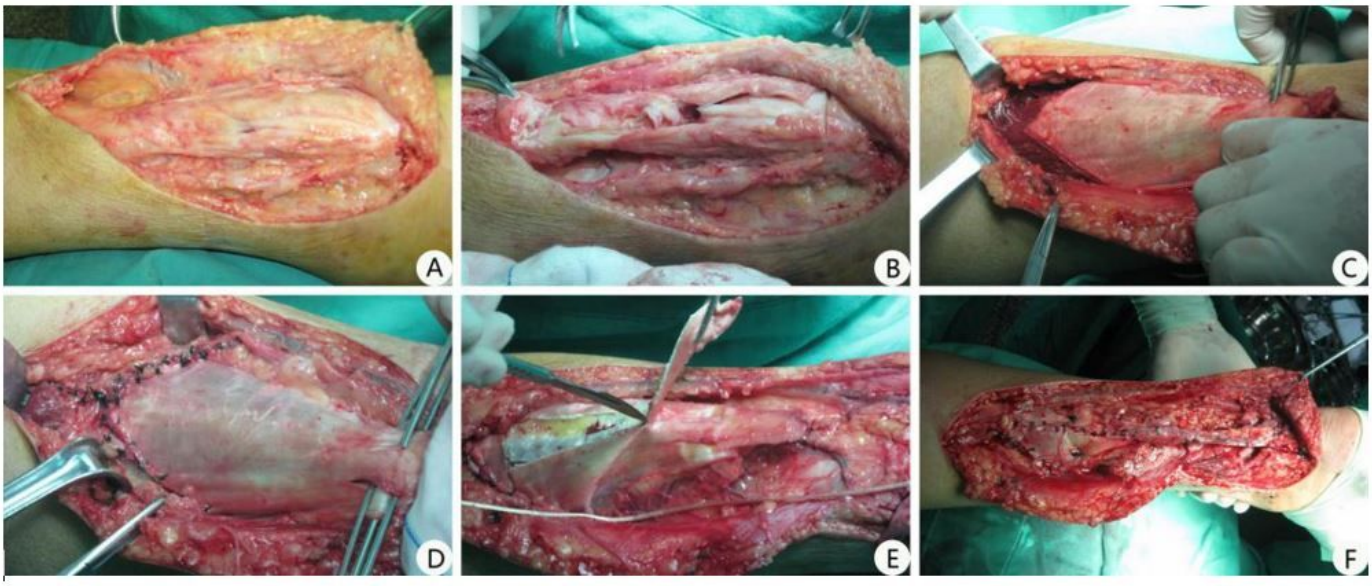

Figure 1

The operative procedure. (A) The scar tissue of the tendon. (B) Excision of the scar tissue. (C) V recession was made and the proximal stump pulled down. (D) Y suture was made. (E) A gastrocnemius aponeurosis flap was dissected. (F) The tendon defect was repaired and reinforced with a flap and the donor side of the flap was repaired.

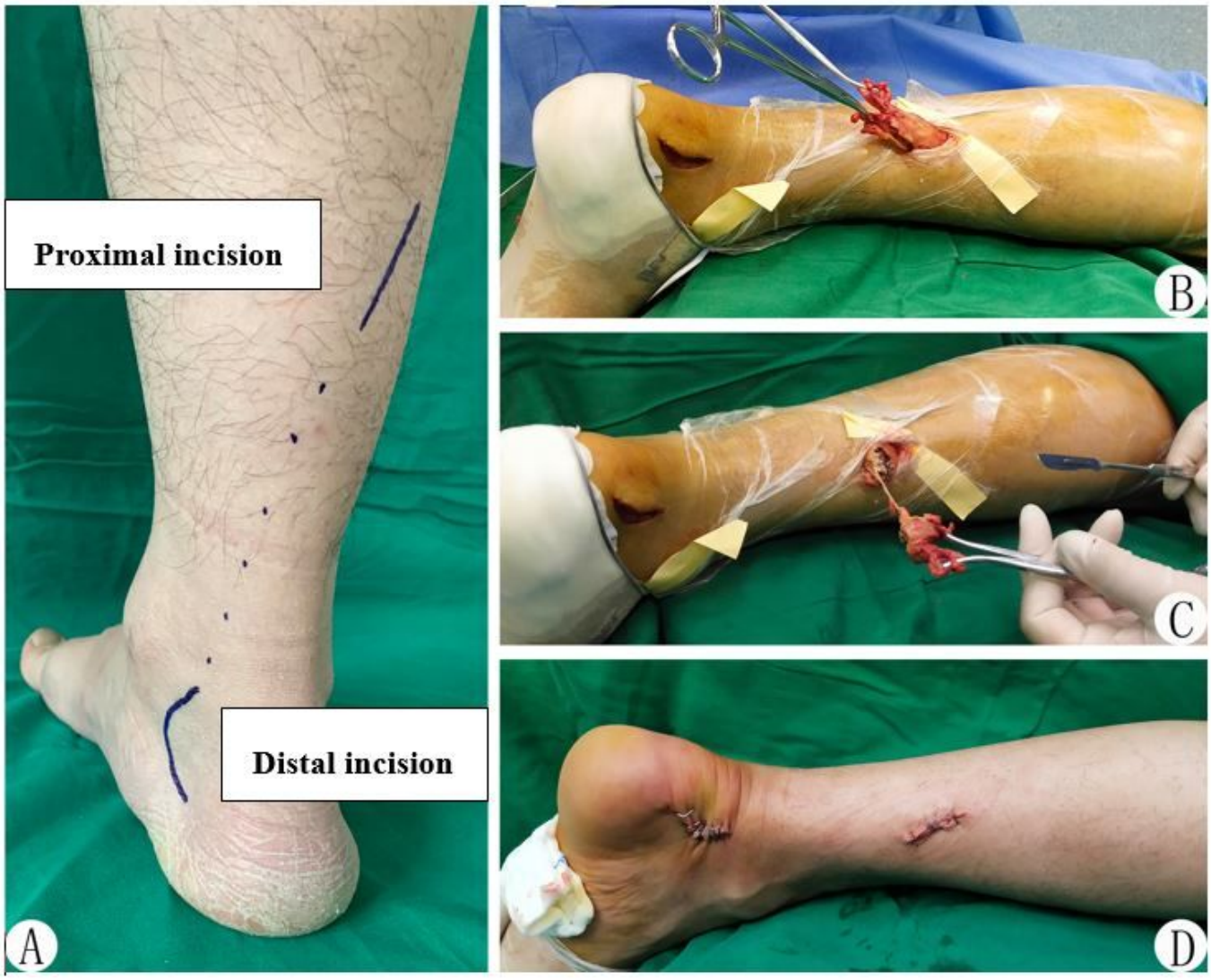

Figure 2

The operative procedure. (A) Two separate longitudinal incisions were created. (B) The incision choosing and the exposure of the scar tissue of the tendon. (C) The proximal tendon was pulled down and sutured with the plantar tendon transfer after the excision of the scar tissue. (D) the incision was sutured.

Figure 3

The functional evaluation of Plantarflexion and Dorsiflexion was performed at year two after the operations. (A and B) The operative limb with the conventional technique of V-Y tendon plasty; (C and D) The non-operative limb; (E and F) The operative limb with the minimally invasive surgical approach of plantar tendon transfer; (G and H) The non-operative limb.

Figure 4

The functional evaluation of the heel raise test was performed at year two after the operations. (A and B) The patient underwent the conventional technique of V-Y tendon plasty; (C and D) The patient was treated by the minimally invasive surgical approach of plantar tendon transfer.