Association of CT Findings with clinical severity in Patients with COVID-19, a multicenter Cohort observational study

Min Liu (mikie0763@126.com)
China-Japan Friendship Hospital Department of Radiology https://orcid.org/0000-0003-1298-4441

Hongxia Zhang
China Rehabilitation Research Center

Nan Yu
Affiliated Hospital of Shaanxi University of Chinese medicine

Qing Hou
Beijing Puren Hospital

Li Zhu
General Hospital of Ningxia Medical

Honglun Li
Qindao University Medical College Affiliated Yantai Yuhuangding Hospital

Jianguo Wang
The third Hospital of Shenzhen University

Zhi Zhang
China-Japan Friendship Hospital

Liu Gao
China-Japan Friendship Hospital

Yimin Wang
China-Japan Friendship Hospital

Rufen Dai
Dali Bai Autonomous Prefecture People Hospital

Xiaojuan Guo
Beijing Chaoyang Hospital

Youmin Guo
the first affiliated Hospital of Xi'an Jiaotong University

Research

Keywords: Coronavirus disease 2019, Pneumonia, Computed tomography, Chest X-ray, ground grass opacity

Posted Date: April 17th, 2020

DOI: https://doi.org/10.21203/rs.3.rs-22920/v1

Abstract

Background

2019 Novel Coronavirus disease (COVID-19) may cause critical illness including severe pneumonia and acute respiratory distress syndrome. Our purpose is to was to analyze the radiological features of COVID-19 pneumonia and its association with clinical severity.

Methods

This retrospective study included 212 patients (122 males, Mean age, 45.6 ± 12.8 years) from 10 hospitals. Chest CT, chest X-ray (CXR), clinical and laboratory data at admission and follow-up CT were collected. Chest CT and CXR were reviewed and CT score of the involved lung was calculated.

Results

94.3% patients had pneumonia on the baseline CT at admission. The most CT findings were as follows: GGO (140/200), GGO with consolidation (38/200) and consolidation (16/200) most involving the lower lobes with a predilection for the peripheral aspects. The CT score negatively correlated with Lymphocyte count while it positively correlated with C-reactive protein. ROC curve showed an optimal cutoff value of the CT score of 15 had a sensitivity of 70% and a specificity of 96.5% for the prediction of severe status. Series CT showed GGO or consolidation gradually reduced in 52 patients while 6 patients had reticular opacities. 14 patients showed the normal CXR while GGO were found on CT.

Conclusion

COVID-19 pneumonia manifests as focal, multifocal ground-glass opacities with/without consolidations. Higher CT score correlated severe clinical status. CXR is yet insufficient for evaluation of COVID-19 pneumonia.

Introduction

In December of 2019, there began an epidemic of acute febrile respiratory illness and caused by a new coronal virus in China. The first cases were reported to be occurred in Huanan Seafood Market of Wuhan, Hubei province, China, and the infection rapidly spread nationwide during Chinese Spring Festival (1, 2). The World Health Organization (WHO) named the disease as 2019 Novel Coronavirus disease (COVID-19) (3),which was caused by severe acute respiratory syndrome coronavirus 2 (SARS-CoV-2) (4) and it shares 79.5% sequence identity with SARS-CoV (5). After series of measures including Wuhan City lockdown, the quarantine and isolation, the number of cases in China has been significantly reduced. Although in most cases, the symptoms of COVID-19 are mild and run a self-limiting course; however, in a small proportion

of individuals,the illness progressed rapidly to severe pneumonia with acute respiratory distress syndrome which can result in respiratory failure and death. By April 4, 2020, more than one million cases of COVID-19 pneumonia had been reported worldwide, and 58901 patients had died, equivalent to a mortality rate of approximately 5.3%. (6).

The diagnosis of viral infection is based on identification of the virus, however, the recognition of some imaging features of the disease can become useful,especially to evaluation of the lung involvement. The CT features of COVID-19 pneumonia in Wu Han were successively reported (7–11). But cases identified in other Chinese cities have not been described moreover, these study only reports chest CT findings of COVID-19 pneumonia. The aim of this study, therefore, was to study the correlation of CT findings of COVID-19 pneumonia with clinical, laboratory findings, and then to compare chest X-Ray (CXR) and CT in detection of COVID-19 pneumonia.

Methods

Study population

This study was approved the institutional review boards of our hospitals (2020-21-K16). The institutional review boards waived written informed consents for this retrospective multicenter study. This retrospective study included 212 patients with COVID-19 from 10 hospitals of six provinces between January and February 2020. SARS-CoV-2 infection was confirmed by positive test for viral RNA in aspiration material or nasopharyngeal or oropharyngeal swab specimens or bronchoalveolar lavage fluid collected from patients by next-generation sequencing or standard real-time reverse transcription polymerase chain reaction protocol. Baseline laboratory Findings including white blood cell count (WBC),Neutrophil count Lymphocyte count and C-reactive protein (CRP) and the CT scan at admission were collected. According to Diagnosis and Treatment Program of 2019 New Coronavirus Pneumonia (trial Sixth version) by National Health and Health Commission of China (12), clinical severity of COVID-19 was classified as mild, common, severe and critical type: Mild Type: Mild clinical symptoms or asymptomatic; no pneumonia manifestation on CT or CXR. Common Type Respiratory symptoms as well as imaging findings suggesting pneumonia. Severe Type: meeting any of the following criteria (Adult): Breathing rate ≥ 30 times / minute; at rest, means oxygen saturation ≤ 93%; PaO2/FiO2 ≤ 300 mmHg. Critical type: meeting any of the following criteria (Adult): Respiratory failure and requirement of mechanical ventilation; Shock; Combining other organ failures and requirement of ICU monitoring.

CT Scan

As multiple institutions were involved, chest CT was performed in the craniocaudal direction with multidetector CT scanners (MX 16, Phillips, Cleveland, Netherlands; Philips iCT/256, Netherlands; BrightSpeed, Siemens, Erlangen, Germany; SOMATOM Perspective, Siemens, Erlangen, Germany; Siemens Sensation/16, SOMATOM Definition Dual Source CT, Germany Lightspeed VCT/64, GE Healthcare;

Toshiba Aquilion ONE TSX-301C/320, Tokyo, Japan; Optima CT680 Series, GE MEDICAL SYSTEMS, America;) by using a standard CT protocol. The whole chest was craniocaudally scanned from lung apex to the lowest hemidiaphragm during a single breath-hold. Scan parameters were as follows: Scan parameters were as follows: The following protocols were used: 120 kVp, reference tube current of 110–250 mAs, detector collimation of 16–320 × 0.5-0.625 mm, slice thickness of 1.5-2 mm, and slice interval of 1.5-2 mm, pitch of 1-1.375, a high spatial resolution reconstruction algorithm. Lung and mediastinal window settings (width = 1,400-1,600 HU; level = − 600 to − 800 HU; and width = 350–450 HU; level = 15–25 HU, respectively) were used.

CT Images Interpretation

All CT images were evaluated by two thoracic radiologists (M.L and H.Z with 15 years and 10 years experiences in chest imaging) in consensus. In case of disagreement, the third senior radiologist (Y.G) with 37- years experiences in the chest radiology) made the final decision.

CT findings were evaluated for the type of radiologic pattern(13) :▯parenchymal attenuation disturbances;▯Ground-glass opacity(GGO): defined as slightly increased attenuation of the lung parenchyma that is unrelated to the obscuration of the vessels and adjacent airway walls. ▯Consolidation: defined as increased attenuation of the lung parenchyma, resulting in the obscuration of the vascular outlines and adjacent airway walls; ▯Nodules and tree-in-bud opacities; ▯Crazy-paving pattern: defined as interlobular septal thickening superimposed on ground-glass opacities; ▯Reticulation: defined as thin linear opacities, which correspond to the thickened peripheral connective septa. Distribution: unilateral/bilateral, upper/middle/lower, and central/peripheral/peribronchovascular/random. Extent: focal (n ≤ 2)/multifocal(n ≥ 3) /diffuse(continuous involvement of at least 2 lobes); Involved number of lung segments. In addition, the presence of pleural or pericardial effusion, mediastinal lymphadenopathy ▯defined as a lymph node ≥ 1 cm in short-axis diameter) were evaluated.

In order to quantitative analysis the extent of lung involvement with CT score, we modified the CT score of opacity proposed by Wu et al (14) based on the size and intensity of opacity: size score-if more than half of the segment on the biggest scope of lesion level on axial section CT was involved, then the segment (2 point) was recorded as being involved. If less than half of the segment on the biggest scope of lesion level on axial section CT was involved, then the segment (1 point) was recorded as being involved; intensity score-if the lesion is GGO or crazy-paving sign, the intensity (1 point) was recorded. If lesion is consolidation, the intensity (2 point) was recorded. Severity Score of each lesion = lesion size score × lesion density score. Summation of scores provided overall lung involvement on CT. Maximal CT score for both lungs was = 2(consolidation)x 2▯size▯x20▯segments▯=80

Chest Radiographs

18 patients underwent CXR with posteroanterior projection in the same day with the baseline CT scan at admission. The senior radiologists (L.Z&H.L) with 20 years experiences in chest radiology who was blinded to the CT and clinical information read the radiographs

Statistical analysis

All data were expressed as mean ± standard deviation (SD), or Median with interquartile range (IQR) for the continuous variables and as a number of individuals with percentage in each group for the categoric variables. The comparison of continuous variables between groups was performed using the Mann-Whitney U test. All analyses were considered significant at p values of less than 0.05 (two-tailed).

Results

Clinical characteristics of the patients

212 patients (122 males and 90 females, mean age of 45.6 ± 12.8 years) included 12 mild cases, 169 common cases, 22 severe cases and 9 critical cases at admission who underwent mechanical ventilation. Clinical manifestations included fever in 174 patients (Body temperature > 37.3^{O}C), dry cough in 100 patients, fatigue in 80 patients, dyspnea in 42 patients, diarrhea in 24 patients, headache in 20 patients, vomiting in 8 patients, and runny nose in 3 patients. 20 cases had no clinical symptoms at admission. The mean time of symptom onset is 3.9 ± 2.7 days(Median = 4days,IQR:2-5days).

Comorbidity included 9 cases of hypertension, 3 cases of coronary heart disease, 3 cases of diabetes, 2 cases of postoperative lung cancer, 2 cases of hypothyroidism, 2 cases of asthma, 1 case of hepatitis B, 1 case of hepatitis C, 1 case of cerebral infarction, and cervical cancer. There was 1 case with old tuberculosis, 1 with atrial fibrillation, 1 with pacemaker implantation, 1 with ankylosing spondylitis, 1 with gout, and 1 with renal vascular smooth muscle lipoma. 120 patients had a short history of staying in Wuhan (meeting, training, travel, business trip) before symptom onset while 80 patients had close contact with COVID-19 patients. However, exposure risks were not identified in the rest of 12 patients.

SARS-CoV-2 were tested 246 times in 212 patients in whom 192 patients were tested once, 10 patients were tested twice, 6 patients were tested 3 times, and 4 patients were tested 4 times. The total number of WBC of 212 patients was (4.52 ± 1.27) × 10^9 / L and 72 patients with the low WBC count (< 4 × 10⁹/L). The neutrophil count was (2.88 ± 1.02) × 10^9 / L and no one with increased the neutrophil count (> 6.3x × 10^9/L), and the lymphocyte count was (1.12 ± 0.48) × 10^9 / L and 96 patients with the lymphocyte count < 1 × 10⁹/L. The median CRP of 115 patients was 14.7 mg / L (IQR: 5.5-43.16). The median PCT of 57 patients at admission was 0.1 ng / mL (IQR: 0.05–0.2) (Normal Value < 0.5 ng/mL).

Features On The Baseline CT

Abnormal opacity was identified on the baseline chest CT scans in 200 patients, thus 94.3% patients had pneumonia at admission. 12 patients without positive findings on the baseline CT showed new GGO in the second CT scan after 3 days. Figure 1 showed abnormal opacity on the baseline CT were found in 30 patients without fever and 14 asymptomatic patients. Table 1 demonstrated the frequency of the baseline chest CT findings. The most CT findings were as follows (Fig. 2): focal or multifocal GGO (140/200) most commonly involve the lower lobes and show a predilection for the peripheral aspects of the lungs. GGO with patchy consolidation (38/200) was the other significant sign. Crazy-paving sign was found in 6 patients, however, no reticulation, nodules or tree-in-bud opacities were found at admission.

Table 1
Baseline CT findings of COVID-19 pneumonia

Baseline CT Findings	Frequency
Parenchymal opacities	
GGO	140
GGO and consolidation	38
Consolidation	16
crazy-paving sign	6
tree-in-bud sign	0
Reticulation	0
Laterality	
right	50
Left	56
Bilateral	94
Distribution	
Peripheral	124
middle	4
Central	2
Peribronchovascular	22
Random	48
Zone	
right upper lobe	104
right middle lobe	78
right lower lobe	150
left upper lobe	80
left lingual lobe	66
left lower lobe	130
Extent	
Focal($n \leq 2$)	72

Baseline CT Findings	Frequency
Multifocal(n > 3)	102
Diffuse	26
Mediastinal lymph node enlargement	6
Pleural effusion	2

CT Score And Clinical, Laboratory Findings

Figure 3 showed range of the baseline CT score was 0–66 with the median score of 5.5(IQR:2.0-10.3) and the baseline CT score negatively correlated with WBC count (r=-0.411,P < 0.001)and Lymphocyte count (r=-0.462,p < 0.001) while it positively correlated with CRP(r = 0.639,p < 0.001, n = 115). Based on the clinical severity of COVID-19(12), we divides patients into two categories: 181 patients in non-severe group (including 12 mild and 169 common cases) and 31 patients in severe group (including 22 severe and 9 critical case). Patients in severe group have higher scores than non-severe group (Median 23.5 & 3.5, U = 614.000, P < 0.001). In the receiver operating characteristic curve (ROC) analysis (Fig. 4), an optimal cutoff value of the CT score of 15 had a sensitivity of 70% and a specificity of 96.5% for the prediction of severe clinical status and the area under ROC was 0.911 (95% confidence interval: 0.840, 0.957).

Temporal Changes On Follow-up CT

60 patients underwent series of follow-up CT scans, of who 26 patients underwent chest CT twice and 34 patients underwent chest CT three times. GGO or consolidation on CT gradually reduced or resolved in 52 patients within a median of 9 days interval (range from 4–21 days). The Second CT scan showed the reduced opacity(Figure 5) in 26 patients in a median of 7 days interval (range from 3–14 days) and the progressed opacity in 34 patients in a median of 4 days interval (range from 2–9 days).The third CT scan of 34 patients showed that the reduced or resolved opacity with / without reticulation in 26 patients in a median of 13 days interval (range from 7–21 days) (Fig. 6), and 2 patients progressed to diffuse GGO or consolidation and 6 patients had reticular opacities with architectural distortion and bronchial dilatation (Fig. 6).

Comparison Of CT And CXR

CXR of 14 patients (14/18) were normal while focal or multifocal GGO were found on CT underwent in the same day (Fig. 7). One CXR showed a cavity in the right upper lobe and patchy opacity in both lower lungs while CT showed a cavity in the right upper lobe with traction bronchiectasis, GGO with patchy lobular consolidation in the periphery of bilateral lower lobes (Fig. 7)

Discussion

In this multicenter cohort study, we retrospectively evaluated the radiological findings of 212 patients with COVID-19 and there are several findings: I. The main findings of COVID-19 pneumonia on CT include GGO and consolidation tending to be peripheral in distribution with lower zone predominance. II. The CT score of lung involvement is a marker of clinical severity and correlated with CRP. IV. Most COVID-19 pneumonia gradually resolve in 8 days and a few cases forms fibrosis. V.CXR cannot detect lesions in early stage or exclude COVID-19 pneumonia.

In this cohort, the most common clinical symptom are fever, dry cough which were consistent with our previous reports (15). Lymphocytopenia and increase of CRP were reported to be the most common laboratory findings (16, 17). The normal white blood cell and lymphocyte count and increased CRP were the most prominent laboratory findings in current study and Lymphocytopenia were found in 45.2%(96/212) patients. Chest CT plays an important role in early detection of lung involvement of infection. Ying et al (9) reported 100% of 42 patients suffer from pneumonia as well as Guan et al(18) showed 76.4% of 840 patients manifested as pneumonia undergoing chest CT on admission. 94.3%(200/212) of patients showed the abnormal opacity on the baseline CT and the median time from symptom onset to the baseline CT were 4 days, suggesting pneumonia can occur in the early stage of COVID-19. For the remaining patients without positive findings on the baseline CT, the second CT after 3 days demonstrated GGO. Thus, 100% of 212 patients with COVID-19 manifested as pneumonia. Notably, the abnormal opacity on the baseline CT scan were found in 30 patients with normal body temperature and 14 asymptomatic patients, suggesting that chest CT scans should be done in high exposure-risk individuals to facilitate early identification of lung involvement.

CXR is widely used to detect pulmonary infection, In Kim et al.'s report on the first case of COVID-19 in Korea (19), they found chest radiography was negative but CT scans performed on the same day showed bilateral, multiple GGOs. And Three of the nine patients (33.3%) had parenchymal abnormalities detected by chest radiography were reported by his team (20). In our study, there were no abnormalities on the initial CXR at admission in 14 patients while their baseline CT showed focal or multifocal GGO. And CXR in 1 patient could not be evaluated due to old tuberculosis. Thus,we believe that the high-risk population can benefit from the early CT scan and CXR is yet insufficient for evaluation of the suspected COVID-19 pneumonia.

Chung et al (8) showed three patients (21%, 3/21) with normal CT scans, 12 (57%) with GGO only, and 6 (29%) with GGO and consolidation in appearance, 15 (71%) patients with two or more lobes involved, and 16 (76%) with bilateral disease. Song et al (21) found pure GGO in 77% patients, GGOs with consolidation in 59% cases, bilateral GGOs in 88% of patients. Similarly, we showed that the most common CT findings of COVID-19 pneumonia in the early stage were focal (36%) or multifocal peripheral GGO (51%) with/without patchy consolidation in a lower lung involvement, however, crazy-paving sign and reticulation were not common. Although some of these findings were similar with SARS-CoV, MERS, H1N1

pneumonia (22–24), cautious attention to high exposure risk and CT findings are helpful for early suspicion of COVID-19 pneumonia and isolation as soon as possible.

CT or radiologic scores of involved lung was reported to be associated with clinical outcomes (14, 25–26). Our modified CT score takes into account the number, size and intensity of lesions, based on the previous method and we found the modified CT score negatively correlated with Lymphocyte count while it positively correlated with C-reactive protein, moreover, the baseline CT scores were higher in severe group than in non-severe group. Regarding the prediction of clinical severity, we found an optimal cutoff value of a CT score of 15 with sensitivity of 70% and specificity of 96.5%. Further study was needed to demonstrate whether this modified CT score predict the lung function and clinical outcomes.

The serial CT scans provided an opportunity to observe the longitudinal lung changes of COVID-19 pneumonia. According to the follow-up CT images, the median time interval to gradually resolved opacity in 52 patients was 8 days. Although the third CT scan of 6 patients showed the features suggestive of lung fibrosis with reticular opacities, architectural distortion and bronchial dilatation.

There are some limitations in our research. First, these patients came from multicenter outside Hubei province, thus they cannot represent real condition in whole country. There are remarkable selection bias because most patients were common type, thus, our study could not comprehensively reflect the difference of clinical and CT findings of patients in mild, common, severe and critical type. Another significant limitation is that, only some of our patients underwent a series of CT scans, there were significant differences in the time interval of CT follow-up and treatment options in each center. Therefore, the characteristics of temporal CT changes and the treatment effect on CT findings cannot be clarified in detail.

Conclusion

Most patients with COVID-19 pneumonia are non-severe type and typically manifests as focal, multifocal ground-glass opacities with/without consolidations on CT. CT score can reflect severe clinical status and CXR is yet insufficient for evaluation of COVID-19 pneumonia.

Abbreviations

2019 Novel Coronavirus disease	COVID-19
Computed tomography	CT
chest X-ray	CXR
ground grass opacity	GGO
severe acute respiratory syndrome coronavirus 2	SARS-CoV-2
white blood cell count	WBC
C-reactive protein	CRP
interquartile range	IQR
receiver operating characteristic curve	ROC

Declarations

Acknowledgements: Not applicable.

Funding: Not applicable.

Contributions: Professor Min Liu and Youmin Guo contributed to the experimental design, Image analysis, discussion and revision of the work. Min Liu, Hongxia Zhang, Nan Yu, Qing Hou ,Li Zhu, Honglun Li, Jianguo Wang, Zhi Zhang, Liu Gao,Rufen Dai,Xiaojuan Guo contributed to the cases collection and analysis. Min Liu, Hongxia Zhang and Nan Yu contributed to manuscript preparation and interpretation of the data and revision.

Competing interests

The authors declare that they have no competing interests.

Availability of data and materials

The datasets used and/or analysed during the current study are available from the corresponding author on reasonable request.

Ethics approval and consent to participate

All procedures were approved by the institutional ethical review board of China-Japan Friendship Hospital (2020-21-K16)

References

1. Novel Coronavirus Pneumonia Emergency Response Epidemiology Team. The epidemiological characteristics of an outbreak of 2019 novel coronavirus diseases (COVID-19) in China. Zhonghua

Liu Xing Bing Xue Za Zhi. 2020;41(2):145-151.

2. Zhu N, Zhang D, Wang W, et al; China Novel Coronavirus Investigating and Research Team. A novel coronavirus from patients with pneumonia in China, 2019. N Engl J Med. 2020 Jan 24. doi: 10.1056/NEJMoa2001017. [Epub ahead of print]
3. World Health Organization. WHO Director-General's remarks at the media briefing on 2019-nCoV on 11 February 2020. . https://wwwwhoint/dg/speeches/detail/whodirector-general-s-remarks-at-the-media-briefing-on-2019-ncov-on-11-february-2020.
4. International Committee on Taxonomy of Viruses. Naming the 2019 Coronavirus. Available at: https://talk.ictvonline.org/. Accessed February 11, 2020.
5. Peng Zhou, Xing Lou Yang, Xian Guang Wang, et al. Discovery of a novel coronavirus associated with the recent pneumonia outbreak in humans and its potential bat origin. bioRxiv152 January 23, 2020. doi: https://doi.org/10.1101/2020.01.22.914952
6. Coronavirus COVID-19 Global Cases by the Center for Systems Science and Engineering (CSSE) at Johns Hopkins University. https://www.arcgis.com/.
7. Kanne JP. Chest CT findings in 2019 novel coronavirus (2019-nCoV) infections from Wuhan, China: Key points for the radiologist. 2020 ;295(1):16-17. doi: 10.1148/radiol.2020200241.
8. Chung M, Bernheim A, Mei X, et al. CT imaging features of 2019 novel coronavirus (2019-nCoV). 2020; 295(1):202-207. doi: 10.1148/radiol.2020200230.
9. Salehi S, Abedi A, Balakrishnan S,et al. Coronavirus Disease 2019 (COVID-19): A Systematic Review of Imaging Findings in 919 Patients. AJR Am J Roentgenol. 2020;14:1-7. doi: 10.2214/AJR.20.23034.
10. Shi H, Han X, Zheng C. Evolution of CT manifestations in a patient recovered from 2019novel coronavirus (2019-nCoV) pneumonia in Wuhan, China. Radiology. 2020 Feb7:200269. doi: 10.1148/radiol.2020200269
11. Shi H, Han X, Jiang N, et al. Radiological findings from 81 patients with COVID-19 pneumonia in Wuhan, China: a descriptive study. Lancet Infect Dis. 2020 Feb 24. pii: S1473-3099(20)30086-4. doi: 10.1016/S1473-3099(20)30086-4. [Epub ahead of print]
12. Diagnosis and Treatment Program of 2019 New Coronavirus Pneumonia (trial Sixth version) by National Health and Health Commission of China. 2020, In Chinese.
13. Franquet, Tomá Imaging of Pulmonary Viral Pneumonia. Radiology, 2011, 260(1):18-39.
14. Wu X, Dong D, Ma D. Thin-Section Computed Tomography Manifestations During Convalescence and Long-Term Follow-Up of Patients with Severe Acute Respiratory Syndrome (SARS). Medical Science Monitor International Medical Journal of Experimental & Clinical Research, 2016, 22(12):2793-2799.
15. Chaolin Huang, Yeming Wang, Xingwang Li, et al. Clinical features of patients infected with 2019 novel coronavirus in Wuhan, China. Lancet 2020; 395: 497–

16. Li LQ, Huang T, Wang YQ, et al. 2019 novel coronavirus patients' clinical characteristics, discharge rate and fatality rate of meta-analysis. J Med Virol. 2020 Mar 12. doi: 10.1002/jmv.25757. [Epub ahead of print].
17. Cascella M, Rajnik M, Cuomo A, et al. Features, Evaluation and Treatment Coronavirus (COVID-19). StatPearls [Internet]. Treasure Island (FL): StatPearls Publishing; 2020-2020 Mar 8.
18. Chen N, Zhou M, Dong X, et al. Epidemiological and clinical characteristics of 99 cases of 2019 novel coronavirus pneumonia in Wuhan, China: a descriptive study. Lancet. 2020;395(10223):507-513. doi: 10.1016/S0140-6736(20)30211-7.
19. Kim JY, Choe PG, Oh Y,et al.The first case of 2019 novel coronavirus pneumonia imported into Korea from Wuhan, China: Implication for infection prevention and control measures. J Korean Med Sci. 2020; 35(5):e61. doi: 10.3346/jkms.2020.35.e61.
20. Yoon SH, Lee KH, Kim JY, et al. Chest Radiographic and CT Findings of the 2019 Novel Coronavirus Disease (COVID-19): Analysis of Nine Patients Treated in Korea. Korean J Radiol. 2020 Feb 26. doi: 10.3348/kjr.2020.0132. [Epub ahead of print]
21. Song F, Shi N, Shan F, et al. Emerging coronavirus 2019-nCoV pneumonia. 2020; 295(1):210-217. doi: 10.1148/radiol.2020200274. Epub 2020 Feb 6.
22. Koo, H. J , Lim, S. , Choe, J. , et al. Radiographic and CT features of viral pneumonia. Radiographics, 2018,38(3), 719-739.
23. Ajlan, A. M , Ahyad, R. A, Jamjoom, L. G. et al. Middle East respiratory syndrome coronavirus (MERS-CoV) infection: chest CT findings. American Journal of Roentgenology. 2014;203(4):782-7.
24. Karadeli, E. , Zafer Koç, Ulusan, S. et al. Chest radiography and CT findings in patients with the 2009 pandemic (h1n1) influenza. Diagnostic & Interventional Radiology, 2011,17(3), 216-222.
25. Yeun-Chung Chang, Chong-Jen Yu, Shan-Chwen Chang,et al. Pulmonary sequelae in convalescent patients after severe acute respiratory syndrome: evaluation with thin-section CT. Radiology,2005, 236: 1067–1075.
26. Feng F, Jiang Y, Yuan M, et al. Association of Radiologic Findings with Mortality in Patients with Avian Influenza H7N9 Pneumonia. PLoS One. 2014 Apr 4;9(4):e93885. doi: 10.1371/journal.pone.0093885. eCollection 2014.
27. Ketai L, Paul NS, Wong KT. Radiology of severe acute respiratory syndrome (SARS): the emerging pathologic-radiologic correlates of an emerging disease. J Thorac Imaging. 2006;21(4):276-83. doi: 10.1097/01.rti.0000213581.14225.f1.

Figures

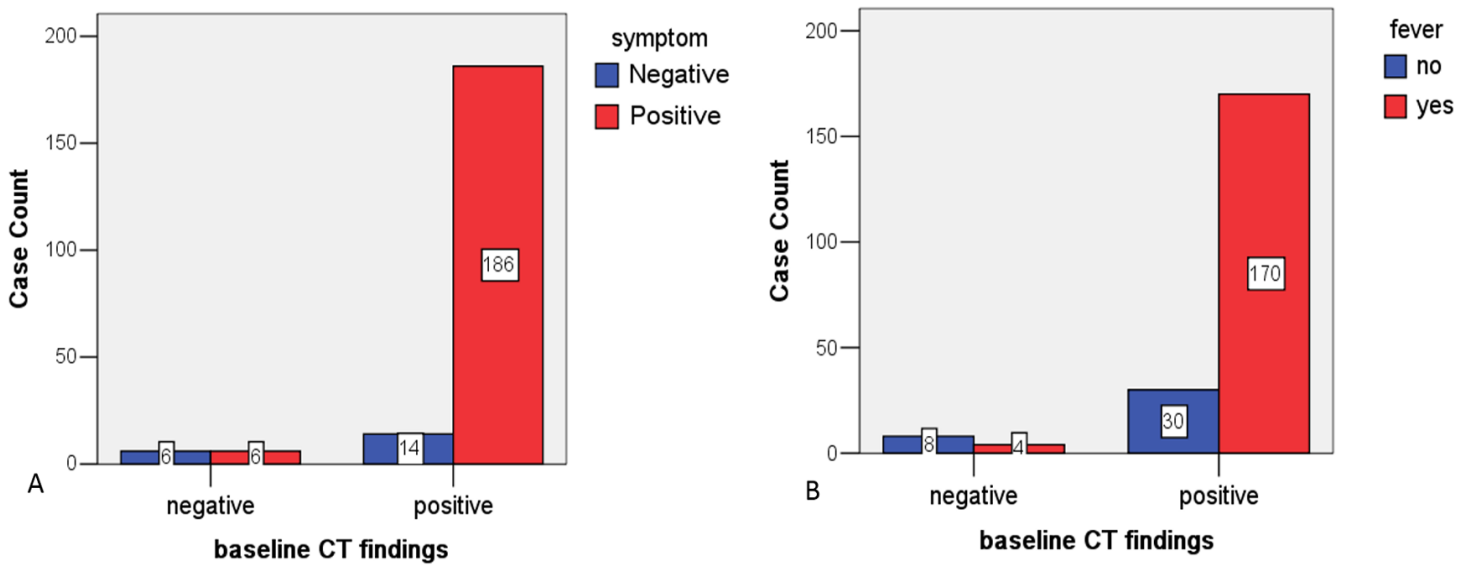

Figure 1

CT and clinical symptoms of COVID-19 patients

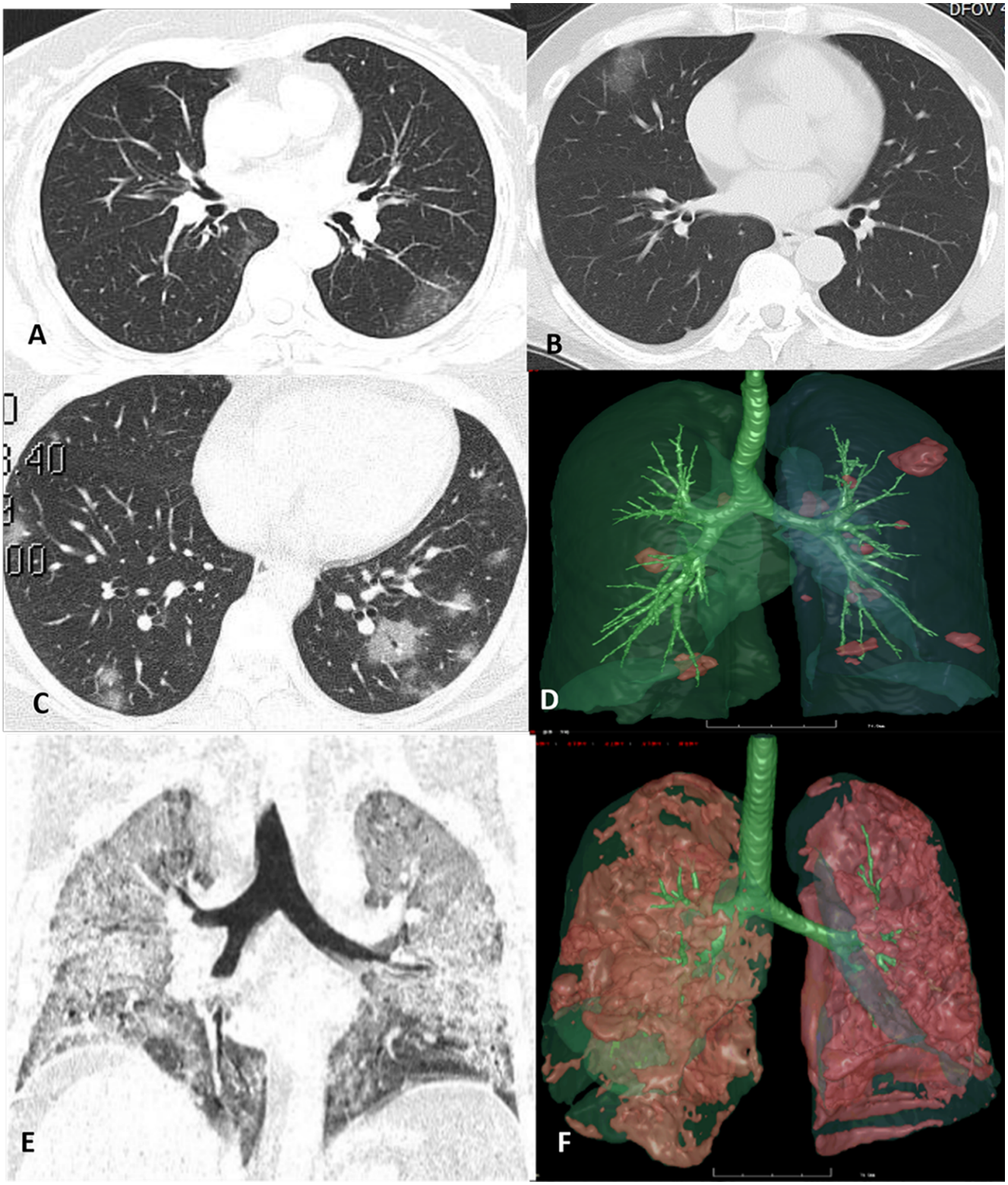

Figure 2

Typical Chest CT features of COVID-19 Pneumonia (A), a 34-year-old female who traveled in Wuhan, complaining with fever in 2 days. Axial CT shows subplueral GGO on the dorsal segment of left lower lobe. (B), a 37-year-old male, husband of A, complaining with dry cough in 1 day. Axial CT shows faint GGO with on the medial segment of right middle lobe. (C and D). a 42-year-old male who had no exposure risk, complaining with high fever in 5 days. Axial CT and Volume Roaming Technology (VRT)

shows multifocal GGO peripherally distributing on the lower lobes of both lungs (E and F), a 61-year-old male without exposure risk, complaining fever, cough and fatigue in 6 days. Coronal CT image and VRT shows diffuse GGO on both lungs.

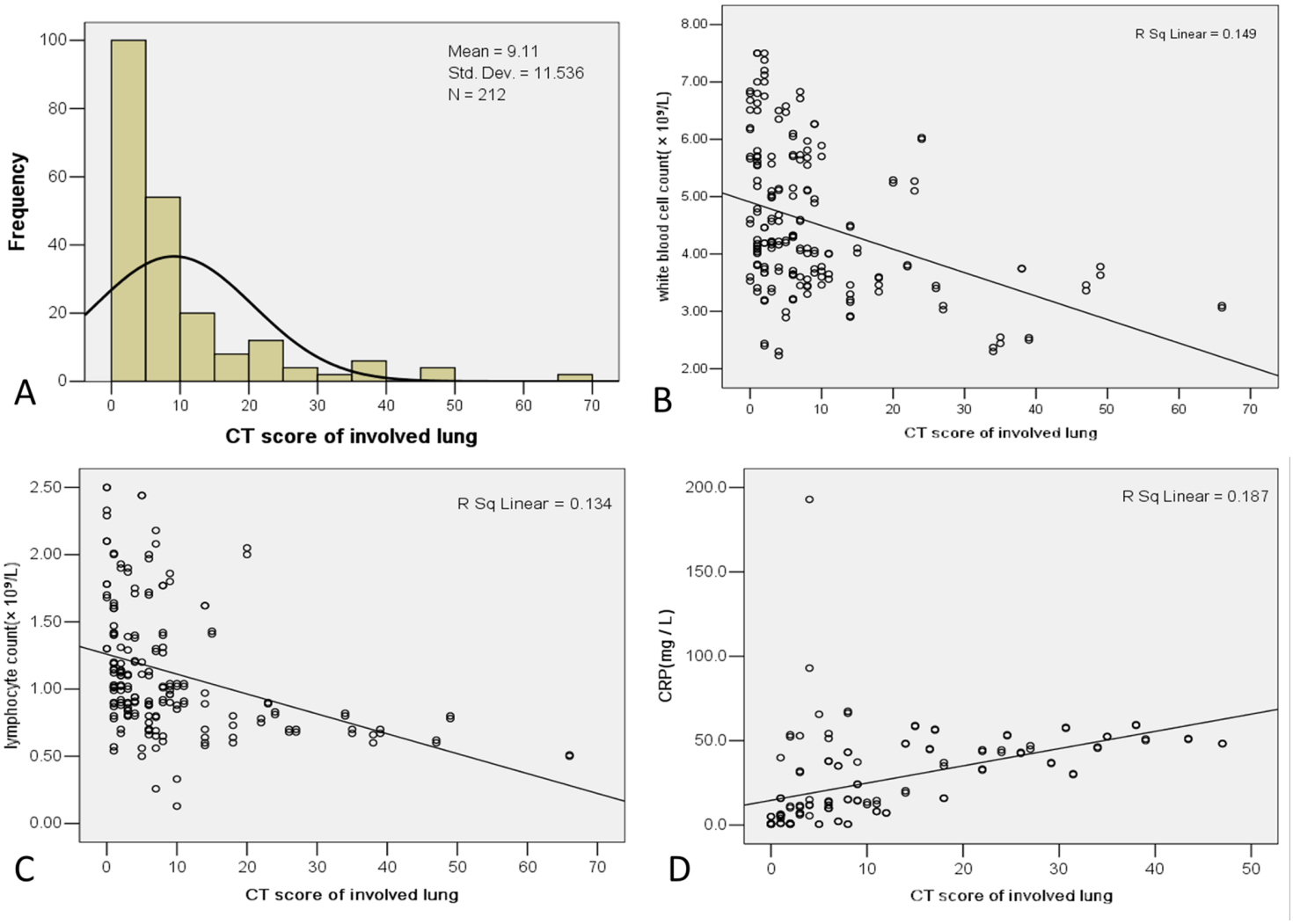

Figure 3

The correlation of CT score with laboratory findings:(A): Range of the baseline CT score; (B):the correlation of CT score and white blood cell count;(C):the correlation of CT score and lymphocyte count((D)the correlation of CT score and C-reactive protein.

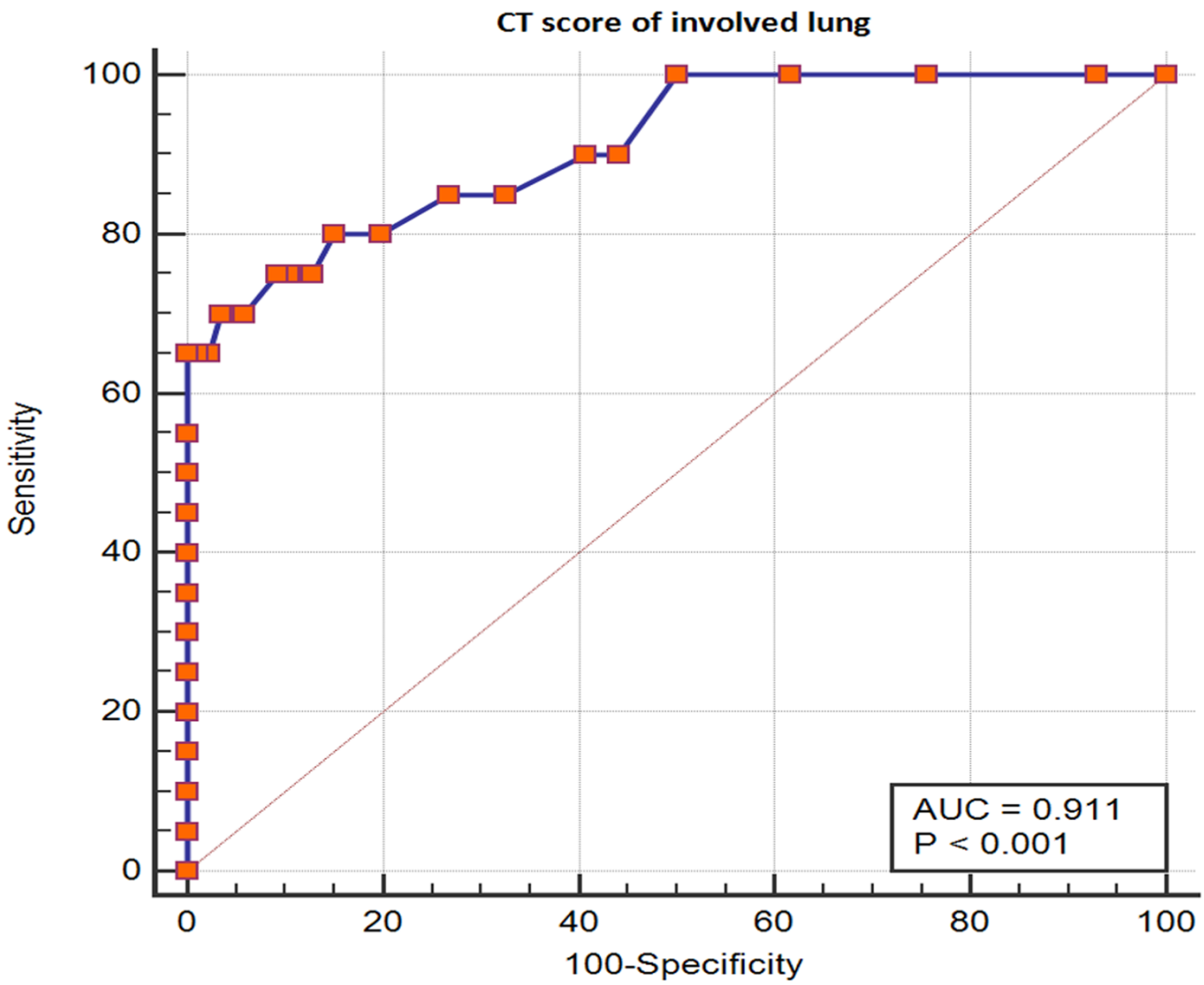

Figure 4

ROC analysis of the chest CT score for evaluation of severity

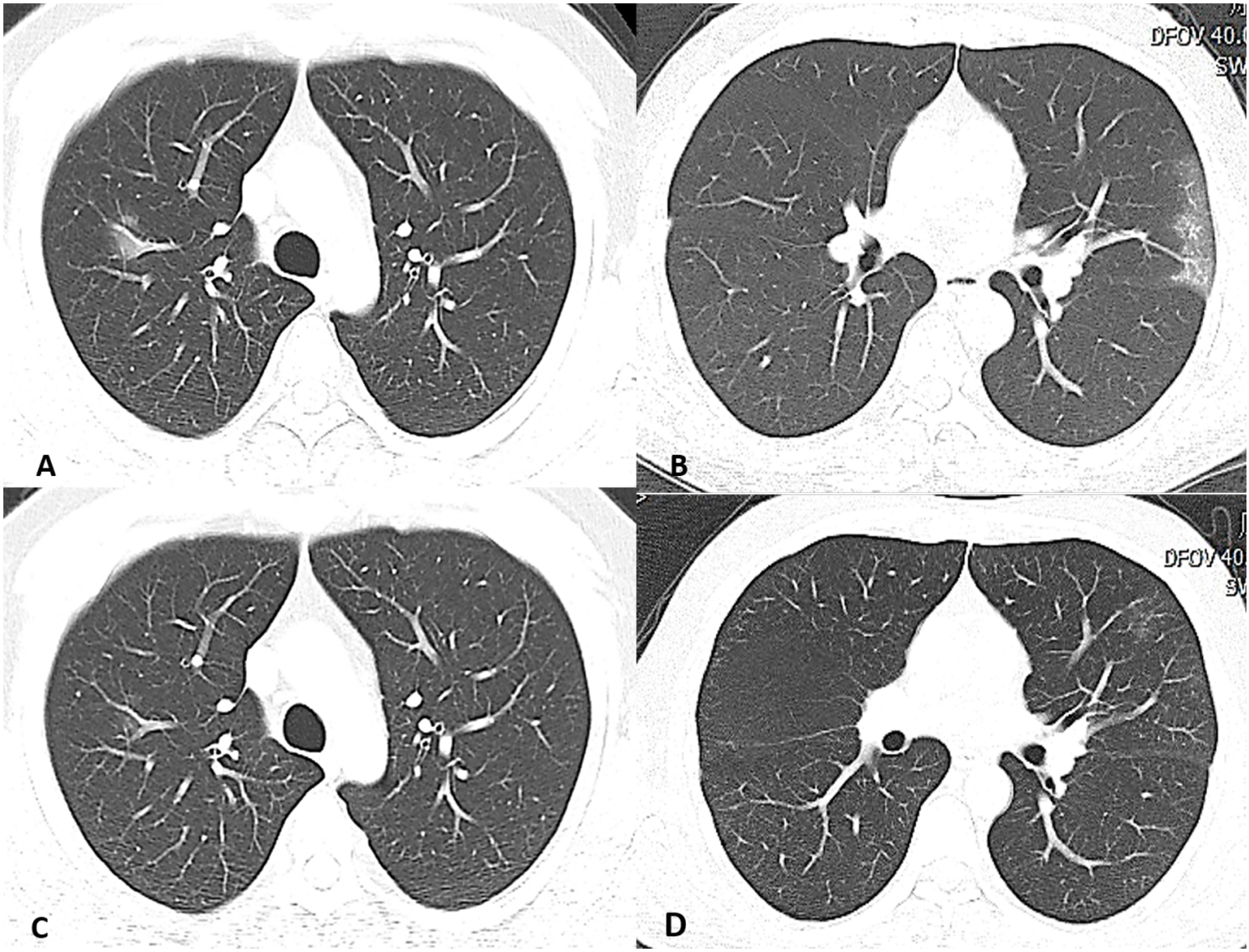

Figure 5

Representative cases at baseline and the second Follow-up CT : A and B: Axial Images of the first chest CT showing the GGO in apex of right upper lobe (A) and the lower tongue of the left upper lobe(B). C and D: Axial Images of the second CT after 6 days showing the prominently resolved GGO.

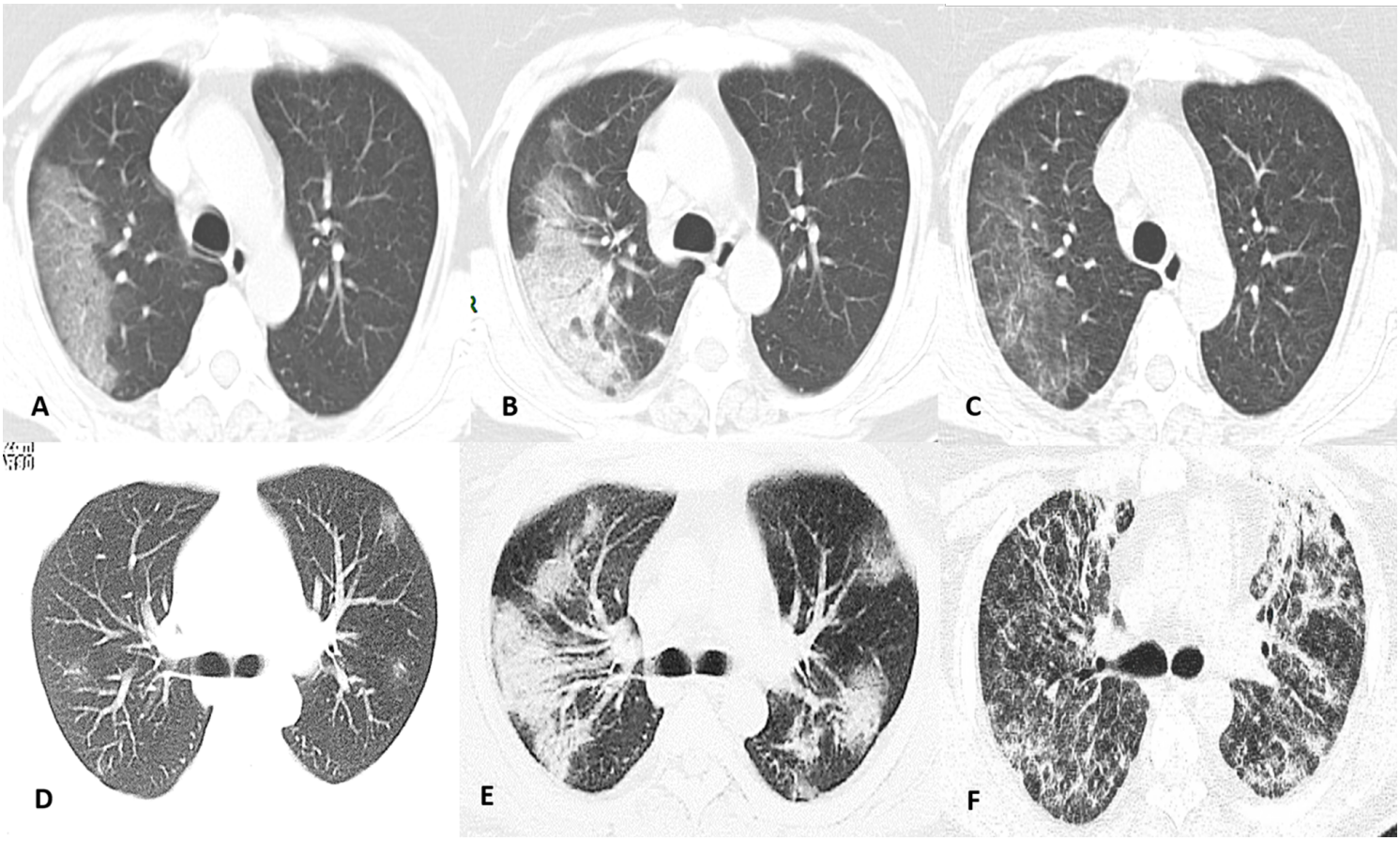

Figure 6

Representative cases at baseline and the twice follow-up CT A 37-year-old male with series CT scans showing the resolution of the lesion□□A□Baseline axial CT image shows GGO in right upper lobe ;(B) The second CT after 4 days shows GGO progressed to consolidation ;(C) The third CT after 8 days, the lesion has complete resolution. A 57-year-old female with series of scans showing the feature of fibrosis□(D) Baseline axial CT image shows multifocal GGO in both lungs ;(E) The second CT after 4 days shows multifocal GGO progressed to multifocal consolidation with GGO;(C) The third CT after 14 days shows features of fibrosis including reticular opacities with residual ground glass opacities, architectural distortion and bronchial dilatation.

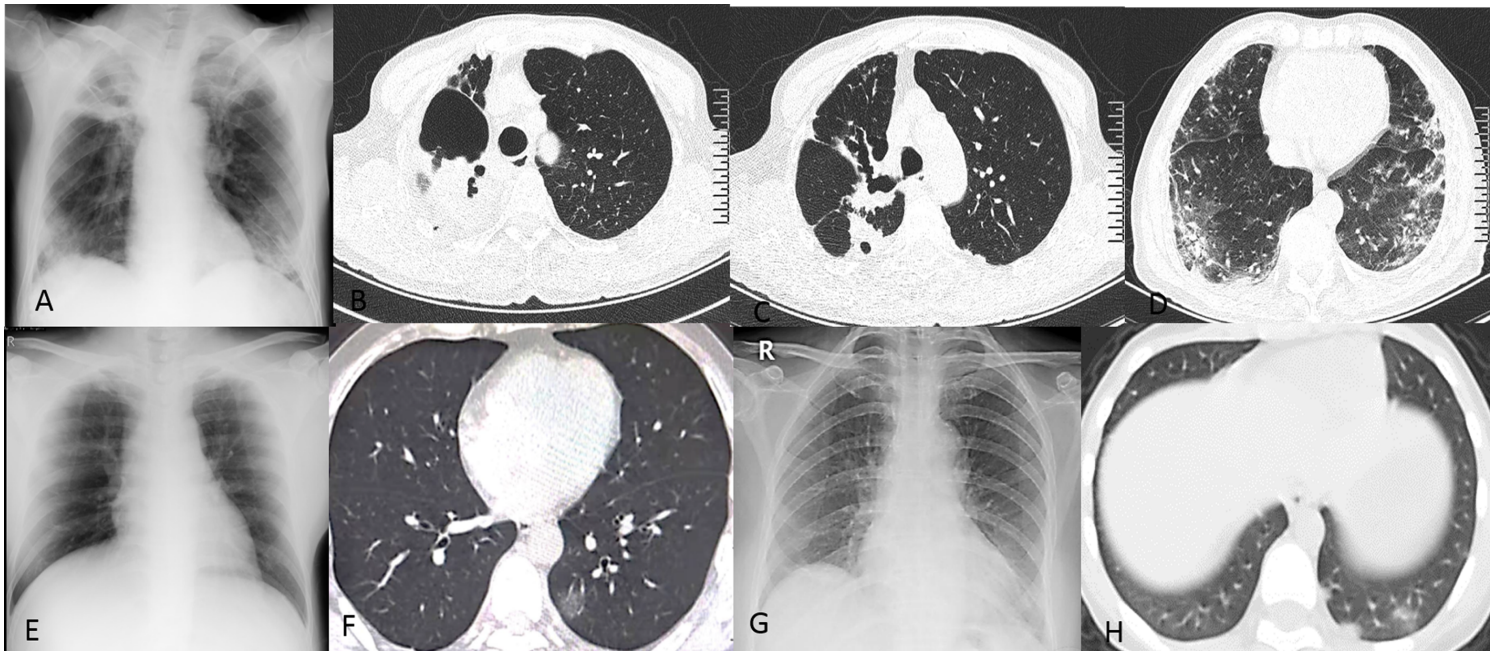

Figure 7

Comparison of the baseline CXR and CT A 55-year-old male (A) CXR showed patchy opacity with cavity in the right upper lobe, and GGO in both lower lungs. (B and C) CT showed cavity and bronchiectasis in the right upper lobe. (D) CT showed subplueral GGO with patchy consolidation of bilateral lower lobes. One son of the above patients, 31- years-old, (E), CXR had no positive findings (F), CT showed subplueral focal GGO in the posterior basal segment of left lower lobe; The other son of the above patient, 22-years-old, (G), CXR had no positive findings ;(H). CT showed subplueral multifocal GGO in the posterior basal segment