Endoscopic ultrasound-based transluminal cholecystolithotomy: the retrievable anchor assisted procedure

Nan Ge
Shingling Hospital, China medical university https://orcid.org/0000-0002-5764-7054
Jinlong Hu
Shengjing Hospital of China Medical University
Fei Yang
Shengjing Hospital of China Medical University
Fan Yang
Shengjing Hospital of China Medical University
Kai Zhang
Shengjing Hospital of China Medical University
Siyu Sun (sunsy@sj-hospital.org)
https://orcid.org/0000-0002-7308-0473

Research article

Keywords: Cholecystolithotomy; endoscopic ultrasound; retrievable anchor; lumen apposing metal stent

Posted Date: November 13th, 2019

DOI: https://doi.org/10.21203/rs.2.11425/v2

Abstract

Background Endoscopic ultrasound-guided gallbladder drainage (EUS-GBD) is gradually emerging as an option among patients with cholecystitis. A stent-bridged endoscopic intervention in the gallbladder (GB) was further introduced. The aim of this study was to assess the effectiveness and safety of the electrocautery-enhanced delivery of a lumen apposing metal stent (ECE-LAMS) and this newly designed retrievable anchor (RA) applied in the transmural cholecystolithotomy. Method We retrospectively reviewed consecutive patients undergoing EUS-guided transmural cholecystoscopic therapy. The main outcome measures for the EUS-GBD procedure were technical success and adverse events, which were also compared between the guided assisted group and the RA-assisted group. The main outcome measures for transmural cholecystoscopy after EUS-GBD were the stent indwelling time, clinical success, and adverse events. Results A total of 24 (15 female) patients with gallstones received transluminal cholecystolithotomy. The mean age of the patients was 36.08±13.69 years. The success rate of the anchor-assisted group was higher than that of the guidewire-assisted group (92.9% vs. 70%, P=0.07). On an average of 12.25±2.77 (range 8-17) days after the initial GB drainage procedure, 20 patients received per-oral cholecystoscopy via the fistula. A ruptured fistula was found in 2 patients in whom the per-oral cholecystoscopy was applied on the ninth day after EUS-GBD. During the follow-up period (mean 314.2± 213.7 days), no GB stone recurrence or other long-term complications were reported. Conclusion We demonstrated that the EUS-assisted per-oral cholecystoscopy technique with ECE-LMAS is an efficient and safe procedure. For the EUS-GBD procedure, a RA could significantly increase the success rate compared with the guidewire.

Background

Take-home message

What is already known:

1. After nearly 10 years of development, EUS-GBD has become an attractive alternative for managing acute cholecystitis in high-risk patients.
2. The formation of a fistulous tract after EUS-GBD facilitates the entry of the endoscope inside the GB, to perform endoscopic lithotomy and polypectomy.

What’s new?

1. Newly developed devices like metal stents with a hot delivery system and RAs could further facilitate the procedure.
2. The stent indwelling time should be no less than 10 days before the following endoscopic transmural operations.

Endoscopic ultrasound-guided gallbladder drainage (EUS-GBD) is gradually emerging as an option among patients who are not eligible for surgical interventions because of advanced malignancy or high

surgical risk[1]. However, after EUS-GBD, most patients were followed up with a wait-and-see strategy until clinical symptoms or stent-related adverse events developed. Several questions remain unanswered. For gallstones and GB polyps, can we take further steps besides just “wait and see”? Besides drainage, is there any other endoscopic approach available? The metal stent has already been used to establish a bridge between the stomach or duodenum and the GB. This bridge may be used to for endoscopic cholecystolithotomy or polypectomy.

In 2012, we started an animal study and proved the feasibility and safety of EUS-guided transgastric cholecystolithotomy[2]. In 2015, we reported the initial attempt of EUS-assisted transduodenal cholecystolithotomy,[3] and then followed up with retrospective studies[4], which all verified the feasibility of the technique. At that time, the procedure was accomplished by using a lumen apposing metal stent (LAMS) without a hot delivery system, which was assisted by the guidewire. In 2018, we reported the initial animal study of the newly developed electrocautery-enhanced delivery of a LAMS (ECE-LAMS) and a retrievable anchor (RA) applied in transduodenal cholecystolithotomy, which significantly simplified the procedure and increased the success rate of EUS-GBD[5]. So far, there have been few studies on the clinical evaluation of the RA -assisted deployment of ECE-LAMS. In this study, we evaluated and compared the efficiency of anchor-assisted EUS-based transluminal cholecystolithotomy via ECE-LAMS with the guidewire-assisted approach.

Methods

Patients

Patients who underwent EUS transluminal cholecystolithotomy (assisted by a guidewire or retrievable puncture anchor) in Shengjing Hospital from Jan 2017 to Dec 2018 were reviewed. The inclusion criteria were as follows: 1. patients with gallstones and recurrent cholecystitis; 2. patients refusing cholecystectomy; and 3. the GB still having satisfactory function (the GB showing satisfactory function by US with an estimated GB ejection fraction greater than 30% or at stage I or II). The exclusion criteria were as follows: 1. GB atrophy and; 2. coagulopathy or other sever comorbidity. The protocol for this retrospective review of the cases was approved by the Medical Ethics Committee. All patients provided informed consent before undergoing the procedure.

Main outcome measurement

The main outcome measures for the EUS-GBD procedure were technical success, clinical effectiveness, and adverse events, which were also compared between the guided assisted group and the RA-assisted group. The main outcome measures for the tansmural cholecystoscopic therapy were the stent indwelling time, clinical success, and adverse events.

Study device

The device used in this study was a through-the-scope LAMS with an electrocautery delivery system (12 mm/25 mm, 16 mm/35 mm; Micro-Tech/Nan Jing Co, Ltd). The stent has wide flanges on both ends, which provide anchoring within the GB. The stent is delivered through a 9F-10.5F catheter. In some patients, the retrievable puncture anchor **(Figure 1)** (Vedkang Inc., Changzhou, China) was applied to anchor within the GB during ECE-LAMS puncturing.

Procedure

The treatment for GB stones has two parts: first, EUS-guided GBD is performed, followed by cholecystolithotomy or polypectomy when a fistula is formed between the duodenum (stomach) and the GB. The operation was performed with all the patients under general anesthesia and in the supine position. After the cholecystolithotomy procedure, the protocol for minimally invasive endoscopic GB preserving cholecystolithotomy guideline in China (2015) was followed for the patients and they were suggested periodic US follow-up and regular ursodeoxycholic acid oral intake for at least 6 months.

Gallbladder puncture with a needle

A longitudinal echoendoscope (Pentax EG-3870-UT) with a working channel of 3.8 mm was introduced into the duodenal cavity to scan for the GB and mark the puncture point. The contact zone (i.e., the region of the duodenal wall representing the shortest distance from the GB walls) was identified. Color Doppler was then used to identify interposing vessels in order to avoid them during puncture. An EchoTip Ultra endoscopic ultrasound needle (19-gauge, Boston Scientific Corp, Marlborough, Mass, USA) was introduced via the working channel of the echoendoscope, and the GB was punctured under EUS guidance. A sample was aspirated to confirm that the punctured structure was the GB. The GB juice was emptied and the GB refilled with saline and the contrast agent for cholecystography.

Guidewire-guided stent deployment group

After the needle puncture, several loops of a guidewire (0.035 inch/480 mm; Boston Scientific, Bloomington, Ind, USA) were inserted into the GB, and then the needle was removed. Under EUS and fluoroscopic guidance, the stent was slowly deployed. When the distal end of the stent contacted the duodenal wall, the electrocautery was started and the stent was gently pushed through the duodenal wall and then the GB wall.

Under fluoroscopic surveillance, the stent was released until the distal flanges completely opened. Gentle traction was applied to pull the GB wall close to the gastric wall. Then, under endoscopic surveillance, the remainder of the stent was deployed (or the remainder stent was just released within the endoscope). EUS was used to confirm the position of the stent and rule out leakage.

Anchor-assisted stent deployment group

After the needle puncture, the RA was passed along the needle into the GB and engaged to anchor the GB. After needle withdrawal, the GB was pulled with the anchor **(Figure 2)** when the GB was punctured and

drained using ECE-LAMS. After the procedure, the retrieval cord was pulled with a pair of forceps, so that the direction of the anchor was changed and it could be easily removed **(Figure 3)**.

Per-oral transgastric cholecystoscopic therapy (cholecystolithotomy or GB polyp resection)

When a fistula is formed between the GI tract and the GB after cholecystostomy with ECE-LAMS, per-oral cholecystoscopy could be performed.

CT or X-ray was used to determine if the stent remained in place. The endoscope was advanced into the GB via the fistula formed by the stent. A stone basket was inserted into the GB to retrieve the stones. The basket was withdrawn from the GB, and the stones were discharged into the GI tract. After several deployments of the basket to remove stones, an endoscope was introduced into the GB to check for any remaining stones. For the polyp resection, a snare or APC can be used. The stent could be removed after the procedure or before the stone removal **(Figure 4)**. The normal diet should be resumed 48 hours after stent removal.

Follow-up

Regular US examination should be performed at 1, 3, 6, and 12 months after the treatment in the first year and every 12 months thereafter.

Data analysis

Statistical analyses were performed using SPSS version 23.0 (SPSS Inc., Chicago, Ill,USA). Frequencies, percentages, means (±standard deviation), and medians (range) were used, as appropriate, for descriptive analysis. For categorical variables, comparisons between groups were performed with the Fisher exact test（small sample less than 40）. Continuous variables with normal distribution were analyzed with the Student t test, whereas those with abnormal distribution were analyzed with the Mann-Whitney U test. All statistical testing was 2-sided.

Results

A total of 24 (15 female) patients with gallstones received transluminal cholecystolithotomy **(Figure 5).** The mean age of the patients was 36.08±13.69 years, ranging from 17 to 76 years. The average diameter of the GB stones found on US was 9±5.575mm, ranging from 4 to 21mmm. Six patients also had common bile duct stones and 2 patients also had low confluence of the cystic duct **(Table 1).**

EUS-GBD procedure

EUS-GBD was successfully performed in 20 (83.3%) patients. The stent access route was through the duodenum in 21 (87.5%) patients and through the stomach in 3 (12.5%). The mean duration of the entire procedure was 19.65±3.554 (range 8-26) min. The stent failed to enter the GB in 4 cases (one in the anchor group and 3 in the guidewire group). Minor migration of the stent was found 14 days after the

procedure in one patient and considered as a late stage adverse event. A fistula between the GB and duodenal wall was still formed regardless of the minor stent migration. No other sever adverse event was observed.

The guidewire-assisted procedure was performed in 10 (41.7%) patients, and the RA-assisted procedure was performed in 14 (58.3%). The success rate of the anchor-assisted group was higher than that of the guidewire-assisted group (92.9% vs. 70%, P=0.07). The adverse event rate was similar between the two groups. (Table 2)

Per-oral cholecystoscopy

On an average of 12.25±2.77 (range 8-17) days after the initial BD drainage procedure, 20 patients received per-oral cholecystoscopy via the fistula. The technical success rate of the per-oral cholecystoscopy technique was 100%. The cholecystolithotomy was completed in 15 out of 20 patients, while stones spontaneous passed out of GB in the remaining 5 patients. During the cholecystolithotomy, lithotripsy was performed in 3/15 patients. GB polypectomy was performed in 5/20 patients. The pathological results of the polyps were as follows: cholesterol polyps in 3 patients, adenomas polyp in 1, and inflammation polyp in 1. During the cholecystolithotomy procedure, direct fistula tearing (injured by the introduction of the endoscope) was seen in one case (8 days post the GBD), which was repaired by metal clips. Contrast agent leakage (9 days post-GBD) via the fistula was seen in another case during the balloon-assisted GB radiography, so the indwelling time of the stent was prolonged for 48 h. No symptom was observed in this patient post-procedure (**Table 3**).

Follow-up

During the follow-up period (mean 314.2± 213.7 days, range 675.0-28.0 days) no GB stone recurrence or other long-term complications were reported.

Discussion

The EUS-GBD technique has undergone continuous improvement through the use of plastic stents, SEMS, and LAMS; these continuous improvements have increased the success rate[6-8]. However, the stenting procedure is skill challenging and time consuming. The newly developed ECE-LAMS has shortened the operative time significantly and reduced bile leakage[9, 10]. Large amount of bile leakage causes GB collapse during the procedure and obvious signs of peritoneal irritation post-procedure. The total success rate of EUS-GBD with ECE-LMPS in our study was 83.3%, similar to that in other studies. Four (3 in the guidewire-assisted group; 1 in the RA -assisted group) patients in whom the ECE-LAMS failed were underwent the endoscopic trans-duodenal GB-preserving cholecystolithotomy procedure, which has also been an available method[11]. No sever complications were observed in our study.

In the early stage of our application of EUS-GBD, we used the guidewire to facilitate stent introduction, as reported by other studies[12], which was high skill demanding and with a success rate of 70%. From 2017,

we tried the preinsertion of RA into the GB, which would hold the GB close to the duodenal wall and stabilized the GB during stent introduction. The use of the RA has increased the technical success rate of EUS-GBD to 92.9%. In most patients, ECE-LAMS can be easily performed with the RA. We assumed that the RA has several advantages. First the anchored GB is more stable for the stent to target. Second, bile leakage may also be reduced because the puncture site was pressed by the duodenal wall. Third, In the stent release process, pulling the GB can make the internal space larger, which is more conducive to reduce the probability of stenting failure. Of note, these anchors are non-damaging to the GB, and they are retrievable. This method heightens the probability of success by ensuring a simpler and safer procedure. Operator confidence is boosted as well.

Formation of the fistulous tract after EUS-GBD facilitates the entry of the endoscope inside the GB, to perform endoscopic lithotomy and polypectomy. The average stent indwelling time before transmural cholecystolithotomy is 12.25±2.77 days. A longer stent indwelling time may have potential risks like migration, which could be treated with the LAMS-in-LAMS technique[13]. The shorter time duration may not be enough for the formation of the fistulous tract and increase the chance of fistula rupture. Contrast agent leakage was found in one case, when the attempted transduodenal cholecystolithotomy was perform 9 days after the EUS-GBD. Another case of fistula tearing also occurred during transduodenal cholecystolithotomy, which was also 9 days after the GB stent placement. Thus, a stent indwelling time of less than 10 days is not safe for the transmural cholecystolithotomy approach.

Gallstone removal from the GB is a simple procedure and lithotripsy could also be efficient in the treatment of large stones. In our study, 10% of the small stones could pass through the LAMPS spontaneously. A higher spontaneous stone passage was reported by other experts. The overall success rate of transmural cholecystolithotomy in our study was 100%. Polypectomy was also successfully performed with the standard snare in 5 patients during the mucosal examination, which indicated the application of transmural cholecystoscopy[14-16]. The applications were also reported in other studies[17].

GB stone recurrence may be another important issue requiring long-term observation studies. It has been 4 years since the first EUS-guided transmural cholecystolithotomy was applied in our center; no stone recurrence has been reported during the periodic follow-up. The protocol for the *Minimally invasive endoscopic gallbladder preserved cholecystolithotomy guideline in China (2015)* was followed. If the GB stones recurred with symptoms, EUS-guided transmural cholecystolithotomy could be repeated or the patients could still be considered for surgery (eg. laparoscopic cholecystectomy).

Our study implies that EUS-based cholecystolithotomy is an efficient and minimally invasive, scarless procedure, which has advanced in preserving the GB and its related digestive functions. It has the potential to become the procedure of choice for gallstones besides laparoscopic cholecystectomy (LC). Long-term follow-up studies have found that cholecystectomy is associated with an increased incidence of dyspepsia, calculus of the common bile duct, and colon carcinoma[18]. Thus, LC at a young age could become a potential risk for life long. GB-preserving cholecystolithotomy could also be accomplished by using a laparoscope combined with a choledochoscope, which has successfully preserved the GB

function, and effectively avoided the various complications of cholecystectomy. During the follow-up for this procedure, GB function was not affected and the stone recurrence rate was also quite low[19].

Our study has a few limitations. The sample size was relatively small. A prospective multicenter study design is needed in the future. There are other endoscopic approaches to treat gallstones, like the endoscopic transmural gallbladder-preserving cholecystolithotomy procedure or endoscopic transmural cholecystectomy. The comparisons among these methods need to be verified in the future.

Conclusion

In conclusion, we have demonstrated that the EUS-assisted per-oral cholecystoscopy technique with ECE-LMAS is an efficient and safe procedure. For the EUS-GBD procedure, a RA could significantly increase the success rate compared with the guidewire (92.9% vs. 70%, $P<0.05$). The stent indwelling time should be no less than 10 days before the following endoscopic transmural operations. This conclusion still needs to be further proved by conducting long-term multicenter prospective studies.

Abbreviations

EUS-GBD: endoscopic ultrasound guided gallbladder drainage

RA: retrievable anchor

LAMS: lumen apposing metal stent

ECE-LAMS: electrocautery-enhanced delivery of LAMS

Declarations

Ethics approval and consent to participate:

The informed consent obtained was written. The protocol to perform retrospective revision of the cases was approved by the Medical Ethics Committees of Shengjing Hospital.

Consent for publication: Not Applicable

Availability of data and material:

The datasets used and/or analyzed during the current study are available from the corresponding manuscript.

Competing interest:

No conflict of interest has been declared by N Ge, J Hu, F Yang, F Yang K Zhang, and S Sun.

Author's Contributions:

NG and SS: planning the study and drafting the manuscript; JH, FY and KZ: collecting the data; FY: interpreting the data. They all approved the final draft submitted.

Funding:

This study was supported by the project of *Technology engineering research center o*f Liaoning Province (Grant No.2018225110) and Natural Science Fund of Liaoning Province (Grant No. 20180530014).

Acknowledgements:

Not Applicable

References

1. James TW, Baron TH. Converting percutaneous gallbladder drainage to internal drainage using EUS-guided therapy: A review of current practices and procedures. Endosc Ultrasound 2018;7:93-96.
2. Ge N, Wang Z, Sun S, et al. EUS assisted transmural cholecystogastrostomy fistula creation as a bridge for endoscopic internal gallbladder therapy using a novel fully covered metal stent. BMC Gastroenterol 2014;14:164.
3. Ge N, Wang S, Wang S, et al. Endoscopic ultrasound-assisted cholecystogastrostomy by a novel fully covered metal stent for the treatment of gallbladder stones. Endosc Ultrasound 2015;4:152-5.
4. Ge N, Sun S, Sun S, et al. Endoscopic ultrasound-assisted transmural cholecystoduodenostomy or cholecystogastrostomy as a bridge for per-oral cholecystoscopy therapy using double-flanged fully covered metal stent. BMC Gastroenterol 2016;16:9.
5. Zhang K, Sun S, Guo J, et al. Retrievable puncture anchor traction method for EUS-guided gallbladder drainage: a porcine study. Gastrointest Endosc 2018;88:957-963.
6. Small AJ, Irani S. EUS-guided gallbladder drainage vs. percutaneous gallbladder drainage. Endosc Ultrasound 2018;7:89-92.
7. Saumoy M, Novikov A, Kahaleh M. Long-term outcomes after EUS-guided gallbladder drainage. Endosc Ultrasound 2018;7:97-101.
8. Perez-Miranda M. Technical considerations in EUS-guided gallbladder drainage. Endosc Ultrasound 2018;7:79-82.
9. Itoi T, Tsuchiya T, Sofuni A, et al. Development of EUS-guided gallbladder drainage and current indications. Endosc Ultrasound 2018;7:76-78.
10. Jain D, Bhandari BS, Agrawal N, et al. Endoscopic Ultrasound-Guided Gallbladder Drainage Using a Lumen-Apposing Metal Stent for Acute Cholecystitis: A Systematic Review. Clin Endosc 2018;51:450-462.

11. Liu B, Du B, Pan Y. Video of the Month: Transrectal Gallbladder-Preserving Cholecystolithotomy via Pure Natural Orifice Transluminal Endoscopic Surgery: First Time in Humans. Am J Gastroenterol 2015;110:1655.
12. Oh D, Song TJ, Cho DH, et al. EUS-guided cholecystostomy versus endoscopic transpapillary cholecystostomy for acute cholecystitis in high-risk surgical patients. Gastrointest Endosc 2018.
13. Ligresti D, Cipolletta F, Amata M, et al. Buried lumen-apposing metal stent (LAMS) following endoscopic ultrasound-guided gallbladder drainage: the LAMS-in-LAMS rescue treatment. Endoscopy 2018;50:822-823.
14. Chan JHY, Teoh AYB. The development of peroral cholecystoscopy and advanced gallbladder interventions. Endosc Ultrasound 2018;7:85-88.
15. Adler DG. EUS-guided gallbladder drainage: Current status and future prospects. Endosc Ultrasound 2018;7:1-3.
16. Chen SA, Feng ZN, Li S, et al. EUS-guided gallbladder polyp resection: A new method for treatment of gallbladder polyps. Hepatobiliary Pancreat Dis Int 2018.
17. Tian L, Yang Y, Xiao D, et al. Resection of gallbladder polyps following endoscopic ultrasound-guided cholecystoduodenostomy using a lumen-apposing metal stent. Endoscopy 2018;50:E307-e308.
18. Carrilho-Ribeiro L, Serra D, Pinto-Correia A, et al. Quality of life after cholecystectomy and after successful lithotripsy for gallbladder stones: a matched-pairs comparison. Eur J Gastroenterol Hepatol 2002;14:741-4.
19. Tan YY, Zhao G, Wang D, et al. A new strategy of minimally invasive surgery for cholecystolithiasis: calculi removal and gallbladder preservation. Dig Surg 2013;30:466-71.

Figures

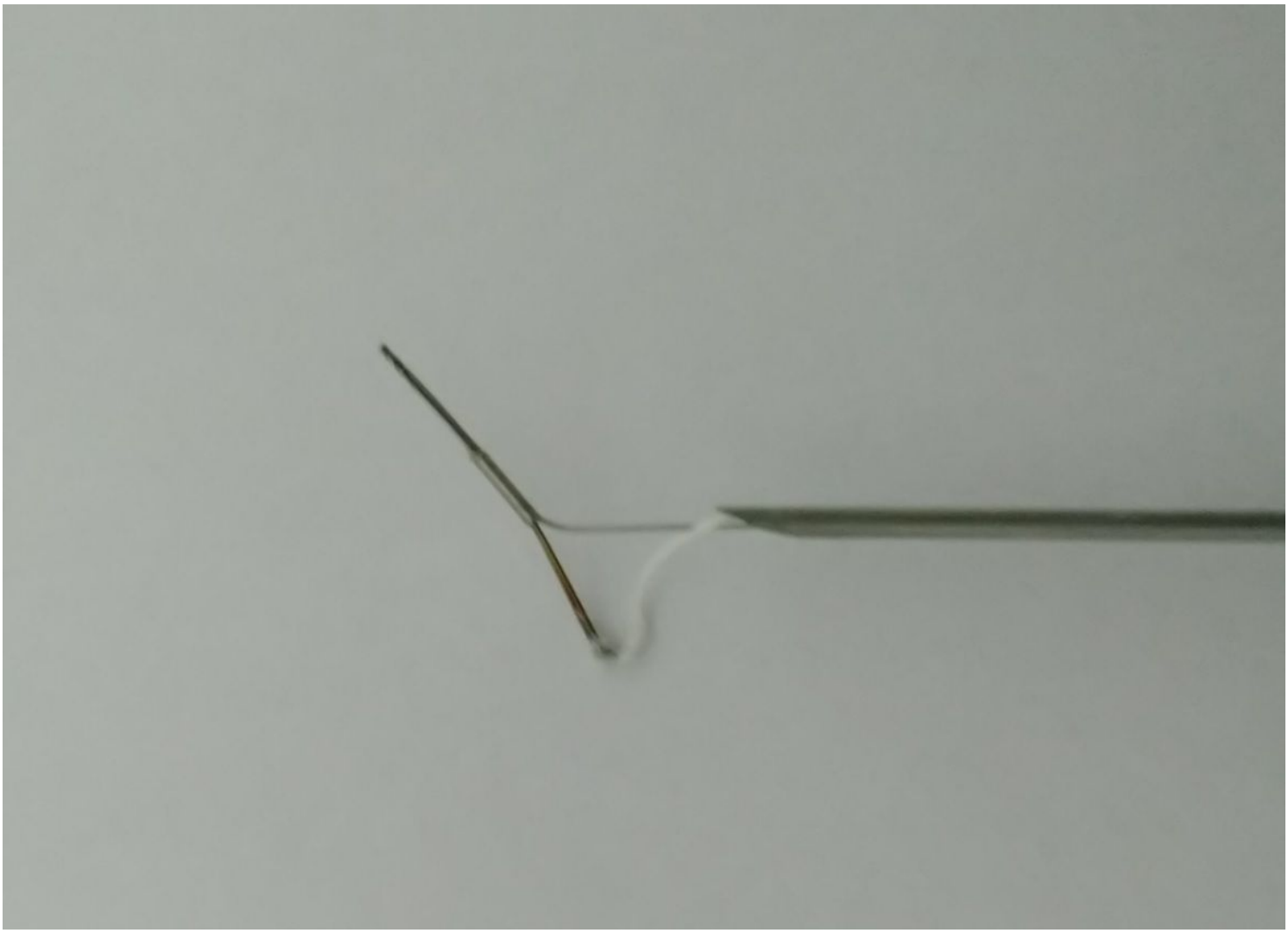

Figure 1

The retrievable puncture anchor. The soft white string is the retrieval cord.

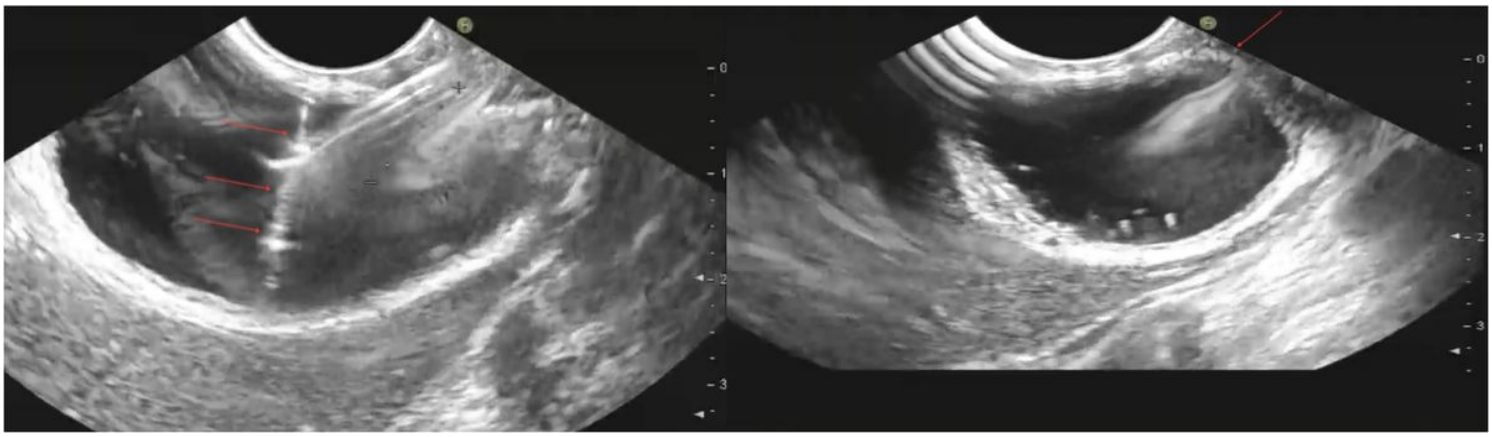

Figure 2

a. After the needle puncture, the retrievable anchor is passed along the needle into the GB. b. After needle withdrawal, the GB is pulled with the anchor in the EUS Image.

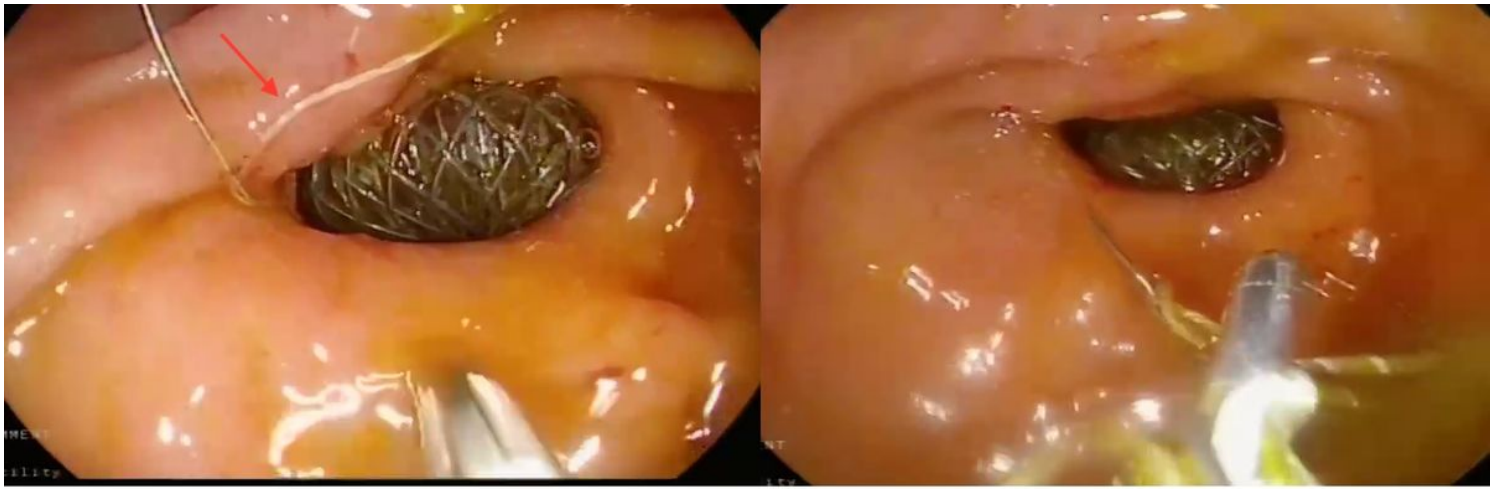

Figure 3

a. The endoscopic view of the retrieval cord. b. The anchor is removed by pulling the retrieval cord by the forceps.

Figure 4

a. A stone basket is inserted into the gallbladder to retrieve the stones b. The endoscopic view of the fistula after stent removal.

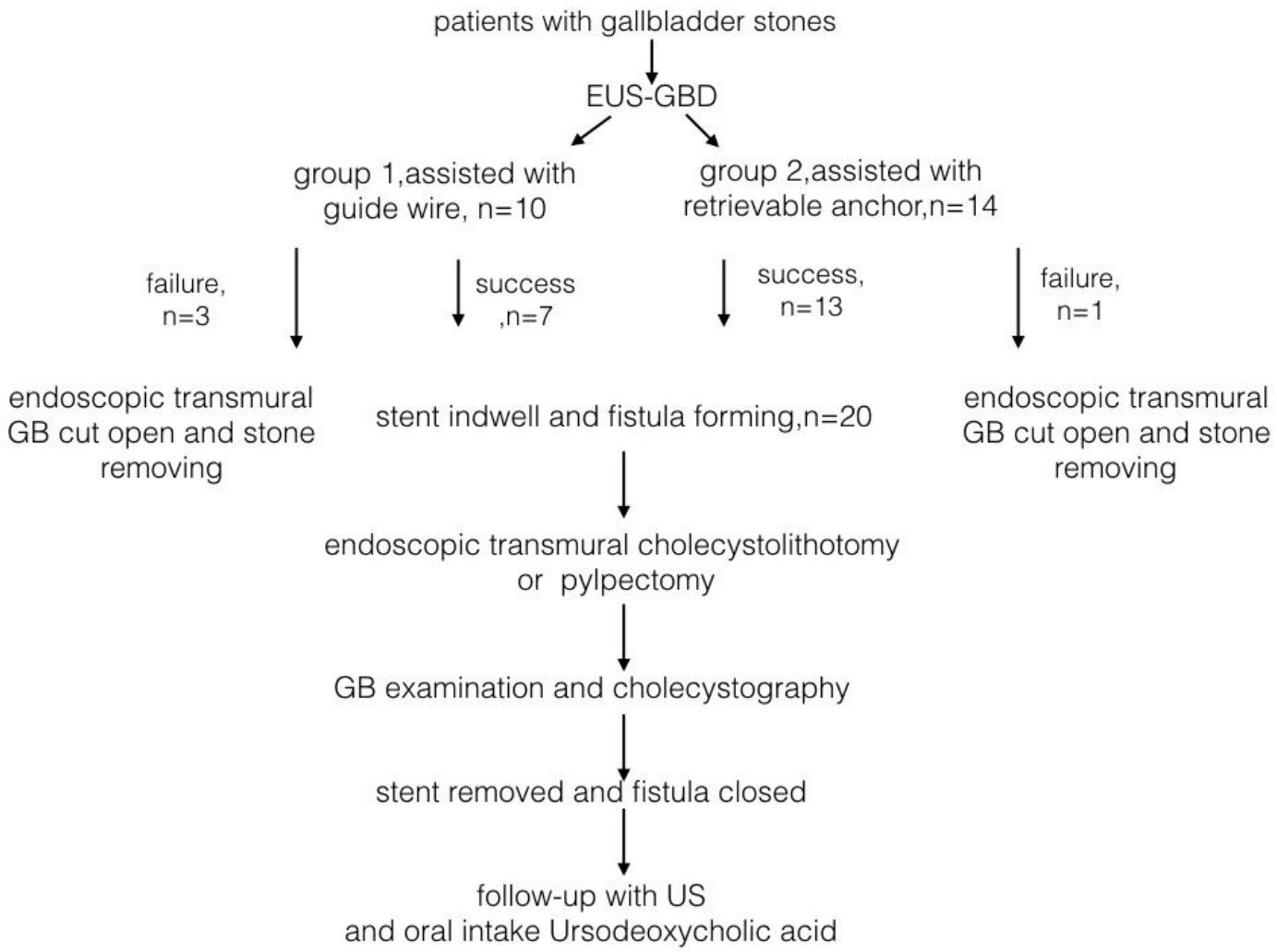

Figure 5

The flow chart of patient selection and the procedure

Supplementary Files

This is a list of supplementary files associated with this preprint. Click to download.

- Table2.pdf
- Table1.pdf
- Table3.pdf