Lymph node metastasis around the entrance point to recurrent laryngeal nerve in papillary thyroid carcinoma

Tian Lv
Shanghai Jiao Tong University Medical School Affiliated Ruijin Hospital https://orcid.org/0000-0003-3305-6310

Zhuoran Liu
Shanghai Jiao Tong University Medical School Affiliated Ruijin Hospital

Jiqi Yan (yanjiqi2000@163.com)
https://orcid.org/0000-0002-5287-4960

Research article

Keywords: Lymph nodes of entrance point to recurrent laryngeal nerve Papillary thyroid carcinoma Central lymph node dissection

Posted Date: July 16th, 2019

DOI: https://doi.org/10.21203/rs.2.11444/v1

Version of Record: A version of this preprint was published at Scientific Reports on March 25th, 2020. See the published version at https://doi.org/10.1038/s41598-020-62031-w.

Abstract

Background There were few reports on the lymph nodes of entrance point to recurrent laryngeal nerve (LN-epRLN) in patients with papillary thyroid carcinoma (PTC). Therefore, we aimed to increase awareness of LN-epRLN. Methods A prospective analysis including 878 consecutive patients with PTC who underwent thyroidectomy from April 2016 to March 2017 was performed. We explored the surrounding tissue of entrance point to recurrent laryngeal nerve, during routine central lymph node dissection (CLND). The lymph node specimens were sent separately for routine histopathological examination, and the complications and follow-ups were recorded. Results LN-epRLN was found in 73 of the 878 patients and the metastasis rate was 3.76%. In univariate analysis, LN-epRLN metastasis was correlated with further central nodal metastasis, tumor location in the upper third of the thyroid and tumor multifocality. Conclusions LN-epRLN can be the site of metastasis of PTC. CLND scope should include the surrounding tissue of entrance point to recurrent laryngeal nerve. LN-epRLN metastasis in PTC is associated with tumor location in the isthmus or upper third of the thyroid, tumor multifocality and further central nodal metastasis.

Background

As is known, papillary thyroid carcinoma (PTC) is the most common type of endocrine malignancy[1]. Taken collectively, these studies[2-4] show that the most common metastases and local recurrences of PTC nodal disease were in the central neck compartment. In particular, it would cause problems for surgeons to reoperate on patients who have regional recurrence in the surrounding tissue of entrance point to recurrent laryngeal nerve (RLN); this reoperation can become complicated[5]. In clinics, there were two metastatic lesions in the central compartment and the two patients suffered a second operation, which both resulted in the overlooked lymph nodes of entrance point to recurrent laryngeal nerve (LN-epRLN). The purpose of this study was to call our attention of LN-epRLN metastasis in PTC patients.

Methods

In the current study, a total of 878 consecutive PTC patients were received initial thyroidectomy at Shanghai Ruijin Hospital between April 2016 and March 2017. A prophylactic or therapeutic central lymph node dissection (CLND) was routinely performed in PTC patients. Exclusion criteria: underwent previous thyroid surgery, pathological types of thyroid carcinomas other than PTC, with lateral neck lymph node matastases and gross extrathyroidal extension invading the surrounding tissue of entrance point to RLN. According to the guidance of the 2010 Tumour Node Metastasis (TNM) staging system of American Joint Committee on Cancer/International Union Against Cancer (AJCC/UICC)[6], we identified all the sample as $T_{1\text{-}3}N_{0\text{-}1a}M_0$ PTC. Informed consent has been obtained from all participants, and the study was approved by the medical ethics review committee in Shanghai Ruijin Hospital.

All operations in our study were performed by the same group of surgeon JQ Y. Central lymph nodes included the Delphian, pretracheal, and paratracheal lymph nodes (LNs). We defined that LN-epRLN was

the lymph adipose tissue located within the distance from the outer edge of the lymph node to RLN entrance point less than 5 mm. Dissection of central LNs was performed as follows. Dissection of the lymph nodes around thyroid was completed at the same time as thyroidectomy. After thyroidectomy, the full length of RLN in the neck was revealed, and paratracheal lymph nodes were removed, including LN-epRLN. Carbon nanoparticles were injected into the lobe during the operation to help identify LNs (Fig.1).

All specimens of thyroid lesions were confirmed to be PTCs by postoperative pathological examination. The pre-operative and postoperative clinicopathological features were recorded and included the following variables: age, gender, TgAb and TPOAb levels, primary tumor size and location, LN-epRLN laterality, thyroid nodules in primary lobe, and lymph node metastasis based on the final pathology report. 73 cases all had completed follow-up data (follow-up period from 12 to 24 months). The present study included the postoperative US examination and procedure-related complications.

Statistical Analysis

To identify differences between groups for specific variables, SPSS version 16 software (SPSS Inc, Chicago, IL) was used for statistical analysis. Univariate analysis was performed using Chi-square test. A *P*-value of <0.05 was considered to represent statistical significance.

Results

LN-epRLN was found in 73 of all the 878 patients and the metastasis rate was 3.76% (33/878). In the present study, we found that there were inconstant nodes, 1 to 4 (1 in average), and that the positive rate was 46.84% (37/79). There was no significant difference in gender (P =0.114) and age (P =0.118) between the two groups (Table 1).

Other central nodal metastasis was more common in the positive LN-epRLN group (93.9 vs. 42.5 %, P <0.001). In univariate analysis, a tumor located in the upper third and tumor multifocality showed a P <0.05 (Table 2). However, no significant relation was found between LN-epRLN metastasis and LN-epRLN laterality (P =0.424), tumor size (P =0.288), or serum TgAb and TPOAb levels (P =0.704).

No patient had permanent RLN injury or permanent hypoparathyroidism in this study, and no patient had a second operation during the follow-up period. Seven (0.8%) patients had transient hoarseness (4-6 weeks), which were checked under fiberlaryngoscopy at one month and 6 months after surgery. Six (0.7%) patients had postoperative transient hypoparathyroidism (5-14 days).

Discussion

Previous literatures[2-4] have shown that lymph node involvement is relevant to local recurrence, in fact. This is controversial according to the current American Thyroid Association (ATA) guidelines for a routine

prophylactic or therapeutic CLND in patients with PTC[7-8].

The anatomic boundaries of a CLND include the carotid arteries from the hyoid bone superiorly to the innominate artery inferiorly. An appropriate range of CLND should both reduce the local recurrence rate and the incidence of post-operative complications. Paratracheal LNs are the most commonly involved central LNs. For PTC, a precise range of paratracheal LN dissection is still controversial. There have been none articles written on the significance of the LN-epRLN, as part of paratracheal LNs. In the current study[9-10], therefore, LN-epRLN did not fall under the normal subdivisions of the central compartment.

The LN-epRLN was defined as the lymph node located within the distance from outer edge of the lymph node to the RLN entrance point less than 5 mm (Fig.1). In our study, there were inconstant nodes, 1 to 4 (1 in average), in diameter between 6 mm and 10 mm. In the present study, LN-epRLN was found in 73 of 878 patients and the metastasis rate was 3.76% (33/878). Thinking only about involved thyroid lobes, the positive LN-epRLN rate was 46.84% (37/79), and the incidence of the right side was slightly higher than that on the left side. The univariate analysis showed that the factors affecting LN-epRLN involvement were the other central cervical lymph node metastasis, the upper third tumor location and tumor multifocality.

The LN-epRLN receives afferent lymphatic drainage from the thyroid gland[11]. Considering the anatomical location of the LN-epRLN, it may be expected that tumors located in the upper third will spread to the LN-epRLN more frequently than other.

In our study, the rate of other central neck node metastasis in the presence of LN-epRLN metastasis was 93.9%. Supporting our results, the positive LN-epRLN was highly predictive of other central nodal metastasis. However, this tendency merits further investigation. On the other hand, the exploration and removal of LN-epRLN should be included in CLND for clinically node positive PTC.

Usually, most patients with PTC obtain a 10-year survival rate of 80–90%, but the regional recurrence rate after surgery is 5-20%[12]. Therefore, it’s important to improve the thoroughness of CLND. In our study, two PTC patients suffered second operation as a consequence of the presence of metastatic LN-epRLN, which may mistake for a parathyroid gland or give consideration to recurrent laryngeal nerve injury, and be reserved during the primary operation. After the second operation, the two patients both had transient hoarseness. Our results mirror the data from literature: Reoperative CLND has been shown to have rates of RLN injury 21% transiently and postoperative hypocalcemia with a large range of 0-24%[13-20]. PTC patients with clinically involved lymph nodes in the central compartment should be managed with a LN-epRLN dissection procedure as the time of CLND, taking into consideration RLN and parathyroid glands which are closely related to the nodal basins.

Our prospective study was limited by small samples, which means our results may not be as powerful as a randomized clinical trial with a large population. Moreover, patients with lateral neck lymph node matastases were excluded due to inclusion criteria. These patients may have experienced worse

outcomes than patients enrolled in our study. However, to our knowledge, this is the first article in English to progress our understanding of LN-epRLN metastases in PTC patients.

Conclusions

In summary, we pioneered the confirmation of the significant involvement of LN-epRLN in metastasis. In PTC patients, especially in suspicious presence of central cervical lymph node metastasis, attention should be given to excising the nodal tissue in the surrounding tissue of entrance point to RLN.

Abbreviations

PTC: papillary thyroid carcinoma

RLN: recurrent laryngeal nerve

LN-epRLN: lymph nodes of entrance point to recurrent laryngeal nerve

CLND: central lymph node dissection

TNM: Tumour Node Metastasis

AJCC/UICC: American Joint Committee on Cancer/International Union Against Cancer

LN: lymph node

ATA: American Thyroid Association

Declarations

Ethics approval and consent to participate: Informed consent has been obtained from all participants and clearly state this in your manuscript.

Consent for publication: Not applicable.

Availability of data and material: Not applicable.

Competing interests: None.

Funding: None.

Authors' contributions: TL recorded the data and drafted the manuscript. ZL participated in the design of the study and performed the statistical analysis. JY conceived of the study, and participated in its design and coordination and helped to draft the manuscript. All authors read and approved the final manuscript.

Acknowledgements: Address all correspondence and requests for reprints to: Jiqi Yan, Department of General Surgery, Ruijin Hospital, Shanghai Jiao Tong University School of Medicine, No.197 Ruijin er Road, Shanghai 200025, China. E-mail: yanjiqi2000@163.com

References

1. SiegelRL, MillerKD, JemalA. Cancer statistics. 2017.CA Cancer J Clin. 2017;67:7–30.
2. Lundgren CI, Hall P, Dickman PW, Zedenius J. Clinically significant prognostic factors for differentiated thyroid carcinoma: a population-based, nested case-control study. Cancer. 2006;106:524–531.
3. Rotstein L. The role of lymphadenectomy in the management of papillary carcinoma of the thyroid. J Surg Oncol. 2009;99:186–188.
4. Sakorafas GH, Sampanis D, Safioleas M. Cervical lymph node dissection in papillary thyroid cancer: current trends, persisting controversies, and unclarified uncertainties. Surg Oncol. 2010;19:e57–e70.
5. Salari B, Ren Y, Kamani D, Randolph GW. Revision neural monitored surgery for recurrent thyroid cancer: Safety and thyroglobulin response. Laryngoscope. 2016;Apr;126(4):1020-1025.
6. Edge SB, Compton CC. The American joint committee on cancer: the 7th edition of the AJCC cancer staging manual and the future of TNM. Ann Surg Oncol. 2010;2010:1471-
7. Sanziana A. Roman, Julie Ann Sosa, Carmen C. Solórzano. Management of Thyroid Nodules and Differentiated Thyroid Cancer. Springer International Publishing, 2017.
8. HaugenBR, AlexanderEK, BibleKC, et al. 2015 American Thyroid Association management guidelines for adult patients with thyroid nodules and differentiated thyroid cancer: the American Thyroid Association guidelines task force on thyroid nodules and differentiated thyroid cancer. 2016;26:1–133.
9. Chai YJ, Kim SJ, Choi JY, Koo do H, Lee KE, Youn YK. Papillary thyroid carcinoma located in the isthmus or upper third is associated with Delphian lymph node metastasis. World J Surg. 2014;38(6):1306-1311.
10. Sun G1, Wang Y, Zhu Y, et al. Lymph node metastasis between sternocleidomastoid and sternohyoid muscle in clinically node-positive papillary thyroid carcinoma. Head Neck. 2013;35(8):1168-1170.
11. Roh JL, Kim JM, Park CI. Lateral cervical lymph node metastases from papillary thyroid carcinoma: pattern of nodal metastases and optimal strategy for neck dissection. Ann Surg Oncol. 2008;15:1177–1182.
12. Grebe SK, Hay ID. Thyroid cancer nodal metastases: biologic significance and therapeutic considerations. Surg Oncol Clin N Am. 1996;5:43–63.
13. Park CH, Song CM, Ji YB, et al. Significance of the extracapsular spread of metastatic lymph nodes in papillary thyroid carcinoma. Clin Exp Otorhinolaryngol. 2015;8:289–294.
14. Farrag TY, Agrawal N, Sheth S, et al. Algorithm for safe and effective reoperative thyroid bed surgery for recurrent/persistent papillary thyroid carcinoma. Head Neck. 2007;29:1069–1074.

15. Onkendi EO, McKenzie TJ, Richards ML, et al. Reoperative experience with papillary thyroid cancer. World J Surg. 2014;38:645–652.
16. Shah MD, Harris LD, Nassif RG, Kim D, Eski S, Freeman JL. Efficacy and safety of central compartment neck dissection for recurrent thyroid carcinoma. Arch Otolaryngol Head Neck Surg. 2012;138:33–37.
17. Alvarado R, Sywak MS, Delbridge L, Sidhu SB. Central lymph node dissection as a secondary procedure for papillary thyroid cancer: is there added morbidity? Surgery. 2009;145:514–518.
18. Tufano RP, Bishop J, Wu G. Reoperative central compartment dissection for patients with recurrent/persistent papillary thyroid cancer: efficacy, safety, and the association of the BRAF mutation. Laryngoscope. 2012;122:1634–1640.
19. Lang BH, Lee GC, Ng CP, Wong KP, Wan KY, Lo CY. Evaluating the morbidity and efficacy of reoperative surgery in the central compartment for persistent/recurrent papillary thyroid carcinoma. World J Surg. 2013;37:2853–2859.
20. Shen WT, Ogawa L, Ruan D, et al. Central neck lymph node dissection for papillary thyroid cancer: comparison of complication and recurrence rates in 295 initial dissections and reoperations. Arch Surg. 2010;145:272–275.

Tables

Table 1 Analysis on the involved patients of risk factors

for LN-epRLN metastasis

		LN-epRLN (+)	LN-epRLN (-)	P-value
Total (patients)		33	40	
Age(years)		34.20±10.34	40.00±10.25	0.118
Gender	**Male**	9(27.3%)	5(12.5%)	0.114
	Female	24(72.7%)	35(87.5%)	
TgAb and TPOAb levels	**Elevated**	18(54.5%)	20(50.0%)	0.704
	Normal	15(45.5%)	20(50.0%)	
Other Lymph node metastases	□+□	31(93.9%)	17(42.5%)	0.000
	□-□	2(6.1%)	23(57.5%)	

Table 2 Analysis on the involved thyroid lobes of risk factors for LN-epRLN metastasis

		LN-epRLN(+)	LN-epRLN(-)	P-value
Total (involved thyroid lobes)*		37	42	
Laterality	**Left**	16(43.2%)	22(52.4%)	0.424
	Right	21(56.8%)	20(47.6%)	
Multifocality	**+**	25(67.6%)	14(33.3%)	0.033
	-	12(32.4%)	28(66.7%)	
Tumor Size	**<10 mm**	9(24.3%)	17(40.5%)	0.288
	10-20 mm	15(40.5%)	15(35.7%)	
	>20 mm	13(35.1%)	10(23.8%)	
Tumor Location	**upper 1/3**	25(67.6%)	15(35.7%)	0.044
	lower 2/3	12(32.4%)	27(64.3%)	

* LN-epRLN was found in 73 of the 878 patients. Because of 6 cases involved in both thyroid lobes, there was 79 cases in total.

Figures

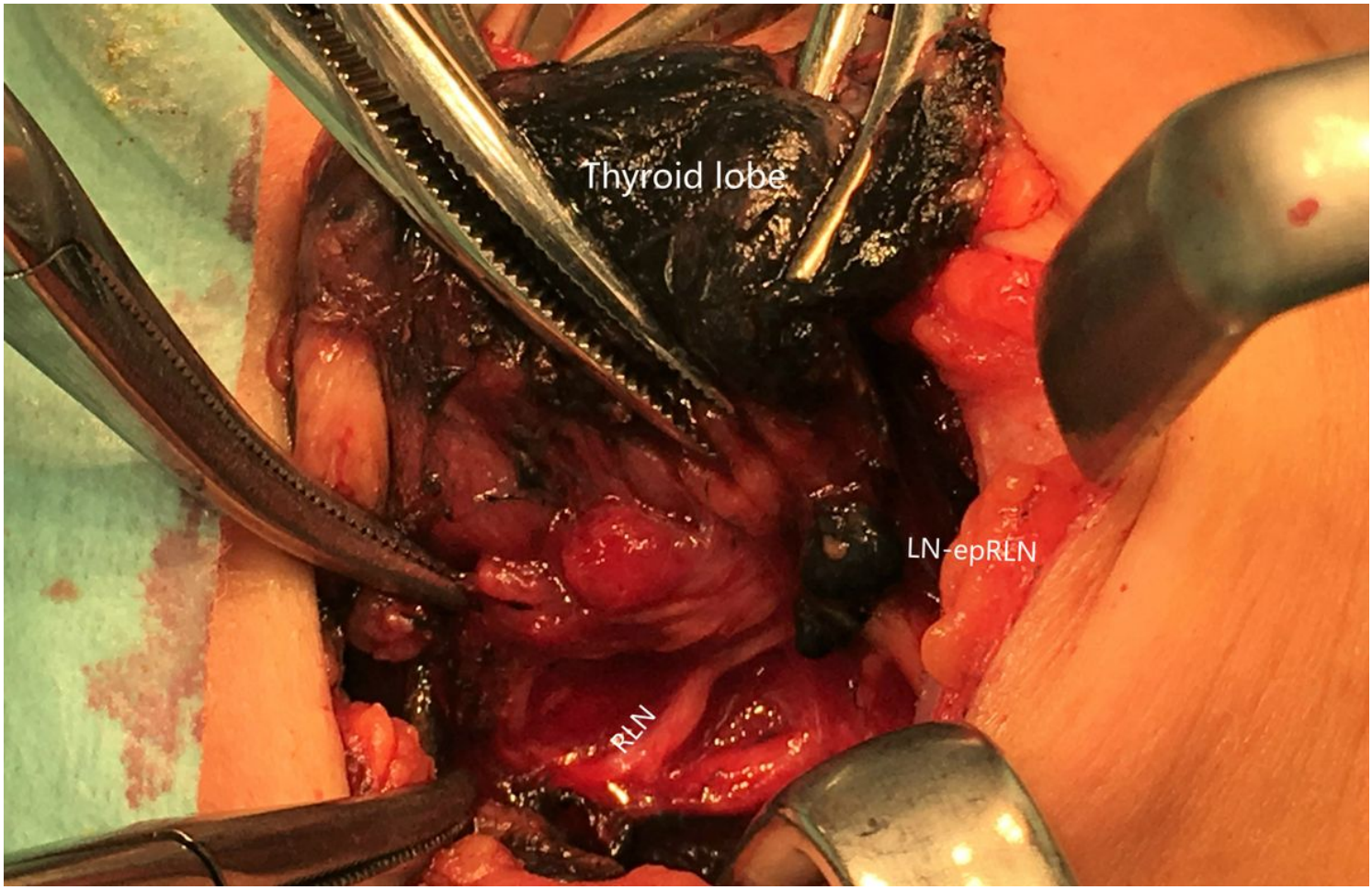

Figure 1

LN-epRLN area coverage. LN-epRLN, lymph node located within the distance from outer edge of the lymph node to RLN entrance point less than 5 mm