Neutrophil-to-Lymphocyte Ratio may Replace Chest Computed Tomography to Reflect the Degree of Lung Injury in Patients with Corona Virus Disease 2019 (COVID-19)

Yang Zhang
Department of Radiology, Southwest Hospital, Third Military Medical University (Army Medical University)

Wenjing Wu
Department of Radiology, Southwest Hospital, Third Military Medical University (Army Medical University)

Mingshan Du
Department of Radiology, Southwest Hospital, Third Military Medical University (Army Medical University)

Wei Luo
Department of Radiology, Southwest Hospital, Third Military Medical University (Army Medical University)

Wenjing Hou
Department of Radiology, Southwest Hospital, Third Military Medical University (Army Medical University)

Yanshu Shi
Department of Radiology, Southwest Hospital, Third Military Medical University (Army Medical University)

Lin Cheng
Department of Radiology, Southwest Hospital, Third Military Medical University (Army Medical University)

Bing Ji
Department of Radiology, Southwest Hospital, Third Military Medical University (Army Medical University)

Jingling Mei
Department of Radiology, Southwest Hospital, Third Military Medical University (Army Medical University)

Fengxi Chen
Department of Radiology, Southwest Hospital, Third Military Medical University (Army Medical University)

Xiang Li
Department of Radiology, Chongqing Three Gorges Central Hospital
Hongnian Xiang
Chongqing Wuxi County People's Hospital
Yang Cao
Dianjiang People's Hospital of Chongqing
Ming Xu
Chongqing Tongnan County People's Hospital
Wei Chen (cwjxl_2006@163.com)
Department of Radiology, Southwest Hospital, Third Military Medical University (Army Medical University)
Jian Wang (wangjian_811@yahoo.com)
Department of Radiology, Southwest Hospital, Third Military Medical University (Army Medical University)

Research Article

Keywords: COVID-19,Neutrophil,Lymphocyte,Tomography,X-ray computed,Lung injury

Posted Date: April 16th, 2020

DOI: https://doi.org/10.21203/rs.3.rs-23201/v1

Abstract

Objectives To investigated the relationship between the neutrophil-to-lymphocyte ratio (NLR) and the severity of lung injury in corona virus disease 2019 (COVID-19) patients.

Methods The clinical data, laboratory examination, and chest computed tomography (CT) findings of 167 patients with confirmed COVID-19 admitted to 5 hospitals in Chongqing, China from January 2020 to February 2020 were retrospectively reviewed. According to the diagnostic criteria sixth edition of the “Diagnosis and Treatment of New Coronavirus Pneumonitis” published by the China National Health Commission, the patients were stratified by the severity of their illness to 3 groups: mild (n = 17), moderate (n = 119), or severe (n = 31).

Results Differences of the NLR among the three groups and between each of the groups were significant (all $p < 0.001$). The NLR and CT severity score were positively correlated ($r = 0.823$, $p < 0.001$). Receiver operating characteristic (ROC) curve analysis found that NLR had diagnostic and prognostic value in COVID-19 patients with either negative or positive CT results. The area under curve (AUC) was 0.819 (95% CI: 0.729-0.910, $p < 0.001$), the sensitivity was 61.3%, specificity was 94.1%, and the optimal NLR cutoff value was 3.634.

Conclusion NLR reflected the degree of lung injury and predicted the progression of COVID-19. NLR is a low-cost, convenient, bedside alternative to chest CT scanning to indicate the severity of lung injury in patients with COVID-19, especially in relatively underdeveloped areas.

Keypoints

- Neutrophil-to-lymphocyte ratio has important clinical significance in predicting severity of either lung injury or illness in COVID-19 patients, and could be a powerful complement to chest CT scans.
- If the NLR is > 3.634, we should be alert to the possibility of emerging lung lesions in patients with previous negative CT findings.
- Clinical use of the NLR may help to alleviate shortages of medical resources during the outbreak in relatively underdeveloped areas and can serve as a novel infection marker in other countries experiencing this COVID-19 pandemic.

Introduction

Corona virus disease 2019 (COVID-19) is a highly infectious emerging disease that has infected more than 80,000 people and caused over 3000 deaths in China since its appearance in late December 2019 in Wuhan, Hubei Province [1, 2]. COVID-19 has spread to many other countries, posing a serious threat to people and public health worldwide. Clinical experience and autopsy evidence show that the lungs are the most important target organ, with infection resulting from severe acute respiratory syndrome coronavirus

2 (SARS-CoV-2) [3]. Chest computed tomography (CT) is useful for screening, diagnosis, quantitative grading, evaluation of curative effect, and follow-up of COVID-19 pneumonia, but it is relatively expensive, requires transport to a radiology department, and involves radiation exposure [4-6]. Access to CT may be limited during infectious disease outbreaks in underdeveloped countries because of a lack of medical resources.

Evaluation of blood-cell counts is a routine bedside clinical procedure that is easy to perform and nearly universally available. There have been few studies on COVID-19 specific indicators, and the clinical value of some indicators may be underestimated. The neutrophil-to-lymphocyte ratio (NLR) is an inflammatory marker that is widely used to evaluate the severity of bacterial infections, to describe the immune response to stress stimuli, and it may have prognostic value in pneumonia and malignancies [7-9]. Recent studies have shown that changes in the NLR may reflect damage to T-lymphocytes caused by SARS-CoV-2 that may be responsible for worsening of the disease [10]. The most recent imaging findings characteristic of COVID-19 pneumonia indicate severe destruction of the lung parenchyma including interstitial inflammation and extensive consolidation similar to previously reported coronavirus infections [11-13]. CT severity scores have been used to assess the degree of lung injury. In this study, we investigated the relationship between the NLR and the severity of lung injury in COVID-19 patients.

Materials And Methods

Patients

We collected epidemiological, clinical, laboratory, and CT data of COVID-19 patients admitted to 5 hospitals in Chongqing, China between January and February 2020. All patients satisfied the diagnostic criteria sixth edition of the “Diagnosis and Treatment of New Coronavirus Pneumonitis” published by the China National Health Commission, and they were stratified by disease severity to mild, with mild clinical symptoms and no evidence of pneumonia on imaging (n = 17); moderate or common, with fever, respiratory tract and/or other symptoms and pneumonia on imaging (n = 119); severe, with clinical and/or imaging manifestations of severe pneumonia (n = 31) [14]. The inclusion criteria were a nasopharyngeal swab or sputum sample positive for SARS-CoV-2 by real-time fluorescence polymerase chain reaction (RT-PCR), an interval of no more than 1 day between laboratory examination on admission and a chest CT scan, and a complete medical record. The Ethics Committee of Southwest Hospital waived written informed consent for this retrospective study that evaluated anonymous data and involved no potential risk to patients.

Laboratory Results and CT Evaluation

Laboratory data, including white blood cell, neutrophil, and lymphocyte counts and C-reactive protein level on the day of hospital admission were retrieved from patient medical records. The NLR was calculated by dividing the neutrophil count by the lymphocyte count in peripheral blood samples. Chest high-resolution (HR) CT was performed with the slice thickness ranging from 1.25 to 1.5 mm. All HRCT images were evaluated in the unified lung window (width 1200 HU, level -600 HU) by 2 fellowship-trained radiologists with 6 and 9 years of experience in thoracic radiology using a viewing console. Analysis of the distribution of lesions, the extent of lung involvement, and the CT imaging findings was double-blinded. The total lung CT severity score was calculated following assessment of the involvement of each of the five lung lobes as none (0%, score = 0), minimal (1%-25%, score = 1), mild (26%-50%, score = 2), moderate (51%-75%, score = 3), or severe (76%-100%, score = 4). The total severity score was the sum of the five lobe scores, and it ranged from 0 to 20 [6, 11]. In case of disagreement, the 2 radiologists reached an agreement through consultation. A third senior radiologist with 25 years of experience in thoracic radiology reviewed the results.

Statistical Analysis

Categorical data were reported as numbers and percentages. Continuous data were tested for normal distribution using the Kolmogorov-Smirnov test and reported as mean ± standard deviation. Data that did not have a normal distribution were reported as medians (upper quartile, lower quartile). Continuous variables were compared by one-way analysis of variance. Pairwise comparisons were performed by Tamhane's test. Spearman's correlation coefficient was used for correlation analysis. Receiver operating characteristic (ROC) curve analysis was used to determine the optimal NLR cutoff value for differentiating negative and positive CT finding in the COVID-19 patients. Statistical analysis was performed with SPSS, version 20.0 (IBM Corp., Armonk, NY, USA). All the statistical tests 2-tailed, and p-values < 0.05 were considered statistically significant.

Results

Clinical Characteristics

The clinical records of 180 consecutive patients were reviewed. Thirteen patients were excluded from the analysis, 7 for an interval of > 1 day between the laboratory examination and chest CT scan, and 6 for incomplete medical records. The remaining 167 patients had a median age of 46 (range 20-90) years, 100 (60.0%) were men and 67 (40.0%) were women. Prior to the start of their illness, 159 (95.2%) had traveled to epidemic areas or had close contact with COVID-19 patients. and 8 (4.8%) had an uncertain exposure history. Twenty-three (13.8%) had comorbidities, 13 (7.8%) had chronic obstructive pulmonary disease (COPD), 5 (3.0%) had bronchiectasis, 3 (1.8%) had type 2 diabetes, and 2 (1.2%) had hypertension. Seventy-eight (46.7%) had an elevated body temperature (> 37.3°C) when admitted，and the axillary temperature was measured. The body temperatures were < 37.3°C in 89 patients (53.3%), between 37.3°C and 38°C in 57 (34.1%), between 37.3°C and 38°C in 17 (10.2%), and > 39°C in 4 (2.4%). Other admitting symptoms included cough (111, 66.4%), fatigue (37, 22.2%), shortness of breath (33, 19.8%), dyspnea (9, 5.4%), and diarrhea (5, 3.0%). Peripheral blood white blood cell counts were normal or decreased in 158 patients (94.6%), the lymphocyte count was decreased in 108 (64.7%), and C-reactive protein was increased in 94 (56.3%). As of March 5, 2020, none of the patients had died (Table 1).

CT Imaging

Representative CT images are shown in Fig. 1-3. The CT findings of most patients (70.7%) included both lungs, with involvement of the lower lobe of the right lung in (80.8%). Multiple (77.8%), rounded (38.9%), or fan-shaped (31.1%) lesions were observed, with consolidation plus ground-glass opacities (GGOs, 46.7%) and pure GGO (39.5%). Most lesions were (64.1%) were subpleural. The images included interlobular septal thickening (44.9%), air bronchograms (37.7%), organization or fibrosis (30.0%), vascular enlargement (28.1%), crazy-paving patterns (24.6%), bronchial wall thickening (21.6%), and halo signs (17.4%). The total CT severity scores ranged from 0 (all in patients with mild involvement) to a maximum of 18 (in patients with severe lung involvement). The median score was 5, including 4.50 ± 2.25 in the moderate group and 12.52 ± 3.31 in the severe group (Table 2). The patient with a score of 0 had a negative CT result. The patient with the highest lung severity score had a CT appearance similar to "white lung".

ROC Curve Analysis

The mean NLR was 2.38 ± 1.10 in patients with negative (i.e., mild), 3.74 ± 1.49 moderate, and 9.26 ± 2.76 severe CT findings. Differences in the NLR values among the three groups and between each of the groups were significant (all $p < 0.001$). The NLR in the severe group was higher than that in the moderate group and the NLR in the moderate group was higher than that of the mild group (Fig. 4). There was a significant positive correlation between the NLR and the CT severity score ($r = 0.823$, $p < 0.001$). The higher the NLR, the more severe the lung injury (Fig. 5). ROC curve analysis showed that NLR was of diagnostic value in differentiating negative and positive CT findings in the COVID-19 patients. The area under curve (AUC) was 0.819 (95% CI: 0.729-0.910, $p < 0.001$), with a sensitivity of 61.3%, a specificity of 94.1%, and an optimal cutoff value of 3.634 (Fig. 6).

Discussion

The most common clinical symptoms of COVID-19 are fever and cough, with other nonspecific symptoms including shortness of breath, dyspnea, headache, muscle soreness, and fatigue [15]. The latest diagnosis and treatment guidelines state that patients with severe or critical type COVID-19 may present with moderate or low fever, or even without an elevated body temperature [16]. Only 4 patients in this series presented with a body temperature of > 39°C. As the temperature on the day of admission may not reflect recent fluctuations, patients with mild or moderate (i.e., common type) infections may also present with moderate, low, or no fever. About 20% of the reported cases have been severe, and the reported overall mortality is approximately 3% [17]. Our results were in line with that trend, and a severe disease rate of 18.6% indicated that most patients were manageable and treatable. Fortunately, no deaths have occurred in any of the three study groups, which might be a consequence of the few patients with severe disease and comorbidities. Reducing the fatality rate remains a top priority in the current campaign against COVID-19.

The predominant features of COVID-19 pneumonia on CT imaging were bilateral and subpleural GGOs and consolidative pulmonary opacities that were manifestations of lung injury [18]. The autopsy report of the first case of COVID-19 in China noted severe lung injury with gross pathology that was consistent with the distribution of the CT imaging findings. The COVID-19 lesions primarily involved the lungs with little evidence of damage to other organs. Therefore, the overall CT severity scores comprising the sum of the scores of the affected lung lobes can be used to evaluate the degree of lung injury in COVID-19 patients.

In this study, the NLR was higher in patients with severe lung injury than in those with moderate injury, similarly, it was higher in those with moderate injury than in those with mild injury. NLR values were positively correlated with CT severity scores, with the NLR increasing along with the increasing severity of lung injury as shown in Fig. 1-3. This finding indicates that like the CT severity score, NLR was an objective indicator of the severity of lung injury and in line with a recent report of 5 COVID-19 patients with rising neutrophil and falling lymphocyte counts before their death [15]. Lymphocytopenia has been reported in biopsies of patients with COVID-19 and may be a significantly related to disease severity and mortality [19]. The NLR has been identified as an independent risk factor for severe COVID-19 [10]. As it easy to monitor and easier to apply than some other more complex models it may be useful for identifying patients whose prognosis would be improved by early intervention. Positive RT-PCR and negative CT findings or positive CT findings with negative RT-PCR results are both seen in COVID-19 patients [12, 20]. In a large retrospective study, 147 of 308 of patients (48%) with negative RT-PCR results and positive CT findings were reconsidered as highly suspect cases [21]. COVID-19 patients with positive RT-PCR results and negative CT findings have not been extensively studied, but cannot be taken lightly. It is possible that in the early stage of infection the detectable viral load is not sufficient to cause visual pneumonia. Some cases may not progress because of self-limiting infections with a clinical diagnosis of mild type. Other patients may experience infections with visible lesions on follow-up CT scans and progress to common- or severe-type disease [5]. Negative CT findings in patients with PCR-confirmed infections suggests that that chest CT scans are lacking in sensitivity and cannot alone reliably exclude COVID-19, especially in the early stages of infection [11]. We used ROC curve analysis to estimate an optimal NLR cutoff value of 3.634 to differentiate negative and positive CT findings in confirmed COVID-19 patients. If the NLR is > 3.634, we should be alert to the possibility of emerging lung lesions in patients with previous negative CT findings. We believe that NLR has important clinical significance in predicting the severity of either lung injury or illness in COVID-19 patients, and could be a powerful complement to chest CT scans.

If medical resources are lacking, then follow-up CT scans may be available only for patients with evolving disease status under outbreak conditions. Bedside chest radiographs are possible for immobilized or weak patients. Neither is as convenient as routine blood counts, and plain radiographs do not have the high spatial and density resolution provided by chest CT images [22].

There are several limitations to our study. Firstly, none of the patients were given pulmonary function tests as a baseline reference because of the high risk of infection. Secondly, the clinical and laboratory data were limited during this emergency period as the participating hospitals were fully occupied. Finally, as this was a cross-sectional, retrospective study and we could not evaluate ongoing changes in the NLR and CT images. Longitudinal studies are needed.

In conclusion, the NLR objectively reflected the degree of lung injury and predicted the progress of COVID-19. We recommend giving priority to the economy and convenience of this monitoring method. Clinical use of the NLR may help to alleviate shortages of medical resources during the outbreak in relatively underdeveloped areas and can serve as a novel infection marker in other countries experiencing this COVID-19 pandemic.

Abbreviations

AUC	Area under the curve
COPD	Chronic obstructive pulmonary disease
COVID-19	Corona virus disease 2019
CT	Computed tomography
GGO	Ground-glass opacity
HRCT	High-resolution computed tomography
NLR	Neutrophil-to-lymphocyte ratio
ROC	Receiver operating characteristic
SARS-CoV-2	Severe acute respiratory syndrome coronavirus 2

Declarations

1. ***[Acknowledgements]***

The authors thank Chongqing Three Gorges Central Hospital, Chongqing Yunyang County People's Hospital, Chongqing Wuxi County People's Hospital, Dianjiang People's Hospital of Chongqing, Chongqing Tongnan County Peoples Hospital for their assistance in recruiting patients for our studies.

2. ***Funding***

This study has received funding by the Technology Innovation Program of Southwest Hospital, Third Military Medical University (SWH2019QNWQ-04) and the Local science and technology innovation project demonstration of central government guided local science and technology development special fund (WX2017-007-05).

Compliance with Ethical Standards

3. ***Guarantor:***

The scientific guarantor of this publication is Prof. Jian Wang.

4. ***Conflict of Interest:***

The authors of this manuscript declare no relationships with any companies, whose products or services may be related to the subject matter of the article.

5. ***Statistics and Biometry:***

No complex statistical methods were necessary for this paper.

6. ***Informed Consent:***

Written informed consent was waived by the Institutional Review Board.

7. ***Ethical Approval:***

Institutional Review Board approval was obtained.

8. ***Methodology***

- Retrospective
- Case-control study
- Multicenter study

References

1. Wu F, Zhao S, Yu B et al (2020) A new coronavirus associated with human respiratory disease in China. Nature 579:265-269
2. Huang C, Wang Y, Li X et al (2020) Clinical features of patients infected with 2019 novel coronavirus in Wuhan, China. Lancet 395:497-506
3. Li X, Wang L, Yan S et al (2020) Clinical characteristics of 25 death cases infected with COVID-19 pneumonia: a retrospective review of medical records in a single medical center, Wuhan, China. medRxiv. 10.1101/2020.02.19.20025239:2020.2002.2019.20025239
4. Kong W, Agarwal PP (2020) Chest Imaging Appearance of COVID-19 Infection. Radiology: Cardiothoracic Imaging 2:e200028
5. Lei J, Li J, Li X, Qi X (2020) CT Imaging of the 2019 Novel Coronavirus (2019-nCoV) Pneumonia. Radiology 295:18
6. Pan F, Ye T, Sun P et al (2020) Time Course of Lung Changes On Chest CT During Recovery From 2019 Novel Coronavirus (COVID-19) Pneumonia. Radiology. 10.1148/radiol.2020200370:200370
7. Neul-Bom Y, Choonhee S, Soo-Jung U (2013) Role of the Neutrophil-Lymphocyte Count Ratio in the Differential Diagnosis between Pulmonary Tuberculosis and Bacterial Community-Acquired Pneumonia. Annals of Laboratory Medicine 33:105-110

8. Chen XQ, Xue CR, Hou P, Lin BQ, Zhang JR (2019) Lymphocyte-to-monocyte ratio effectively predicts survival outcome of patients with obstructive colorectal cancer. World J Gastroenterol 25:4970-4984
9. Peng J, Zhang R, Zhao Y et al (2017) Prognostic value of preoperative prognostic nutritional index and its associations with systemic inflammatory response markers in patients with stage III colon cancer. Chin J Cancer 36:96
10. Liu J, Liu Y, Xiang P et al (2020) Neutrophil-to-Lymphocyte Ratio Predicts Severe Illness Patients with 2019 Novel Coronavirus in the Early Stage. medRxiv. 10.1101/2020.02.10.20021584:2020.2002.2010.20021584
11. Chung M, Bernheim A, Mei X et al (2020) CT Imaging Features of 2019 Novel Coronavirus (2019-nCoV). Radiology 295:202-207
12. Wu J, Wu X, Zeng W et al (2020) Chest CT Findings in Patients with Corona Virus Disease 2019 and its Relationship with Clinical Features. Invest Radiol. 10.1097/RLI.0000000000000670
13. Müller NL, Ooi GC, Khong PL, Zhou LJ, Tsang KWT, Nicolaou S (2004) High-Resolution CT Findings of Severe Acute Respiratory Syndrome at Presentation and After Admission. Ajr American Journal of Roentgenology 182:39-44
14. Commission NH (2020) Chinese clinical guidance for COVID-19 pneumonia diagnosis and treatment (6th edition). National Health Commission, China. Available via http://www.nhc.gov.cn/yzygj/s7653p/202002/8334a8326dd94d329df351d7da8aefc2.shtml
15. Wang D, Hu B, Hu C et al (2020) Clinical Characteristics of 138 Hospitalized Patients With 2019 Novel Coronavirus-Infected Pneumonia in Wuhan, China. JAMA. 10.1001/jama.2020.1585
16. Commission NH (2020) Chinese clinical guidance for COVID-19 pneumonia diagnosis and treatment (7th edition). National Health Commission, China. Available via http://www.nhc.gov.cn/yzygj/s7653p/202002/8334a8326dd94d329df351d7da8aefc2.shtml
17. Wang C, Horby PW, Hayden FG, Gao GF (2020) A novel coronavirus outbreak of global health concern. Lancet 395:470-473
18. Song F, Shi N, Shan F et al (2020) Emerging 2019 Novel Coronavirus (2019-nCoV) Pneumonia. Radiology 295:210-217
19. Xu Z, Shi L, Wang Y et al (2020) Pathological findings of COVID-19 associated with acute respiratory distress syndrome. Lancet Respir Med. 10.1016/S2213-2600(20)30076-X
20. Xie X, Zhong Z, Zhao W, Zheng C, Wang F, Liu J (2020) Chest CT for Typical 2019-nCoV Pneumonia: Relationship to Negative RT-PCR Testing. Radiology. 10.1148/radiol.2020200343:200343
21. Ai T, Yang Z, Hou H et al (2020) Correlation of Chest CT and RT-PCR Testing in Coronavirus Disease 2019 (COVID-19) in China: A Report of 1014 Cases. Radiology. 10.1148/radiol.2020200642:200642
22. Ng M-Y, Lee EY, Yang J et al (2020) Imaging Profile of the COVID-19 Infection: Radiologic Findings and Literature Review. Radiology: Cardiothoracic Imaging 2:e200034

Tables

Table 1 Characteristics of the 167 COVID-19 patients included in the study

Characteristics	Patients(n = 167)
Age(y)	46(35, 54)
Gender	
Male	100(60.0%)
Female	67(40.0%)
Exposure History	159(95.2%)
COPD	13(7.8%)
Bronchiectasis	5(3.0%)
Type 2 diabetes	3(1.8%)
Hypertension	2(1.2%)
Signs and symptoms	
Body Temperature, (°C)	
<37.3	89(53.3%)
37.3-38.0	57(34.1%)
38.1-39.0	17(10.2%)
>39.0	4(2.4%)
Fever	78(46.7%)
Cough	111(66.4%)
Fatigue	37(22.2%)
Shortness of breath	33(19.8%)
Dyspnea	9(5.4%)
Diarrhea	5(3.0%)
Blood laboratory results	
White blood cell count, (× 10^9 /L)	5.35(4.65, 6.80)
Normal or Decreased	158(94.6%)
Lymphocyte count, (× 10^9 /L)	1.17(0.82, 1.88)
Decreased	118(70.6%)
C-reactive protein (mg/L)	22.16(2.67, 73.50)
Increased	94(56.3%)

Data are n (%) or medians (lower quartile, upper quartile); COPD, chronic obstructive pulmonary disease; Increased means above the upper limit of normal range, and Decreased means below the lower limit of normal range

Table 2 Computed tomography on admission

	Patients (n = 167)
Lung lobe involved	
Left upper lobe	120(71.9%)
Left lower lobe	127(76.0%)
Right upper lobe	110(65.9%)
Right middle lobe	102(61.1%)
Right lower lobe	135(80.8%)
None	17(10.2%)
Bilateral lung involvement	118(70.7%)
Total lung severity score	
Median	5(2, 8)
Range	0-18
Mild group	0
Moderate group	4.50 ± 2.25
Severe group	12.52 ± 3.31
Distribution	
Subpleural distribution	107(64.1%)
Mixed distribution	37(22.2%)
Multiple lesions	130(77.8%)
Morphology	
Rounded	65(38.9%)
Fan-shaped	52(31.1%)
Main CT feature	
Consolidation and GGO	78(46.7%)
GGO without Consolidation	66(39.5%)
Interlobular septal thickening	75(44.9%)
Air bronchogram	63(37.7%)
Organization or Fibrosis	50(30.0%)
Vascular enlargement	47(28.1%)
Crazy-paving pattern	41(24.6%)
Bronchial wall thickening	36(21.6%)

Halo sign	29 (17.4%)

Data are n (%), medians (lower quartile, upper quartile) or means ± standard deviation; GGO, ground-glass opacity

Figures

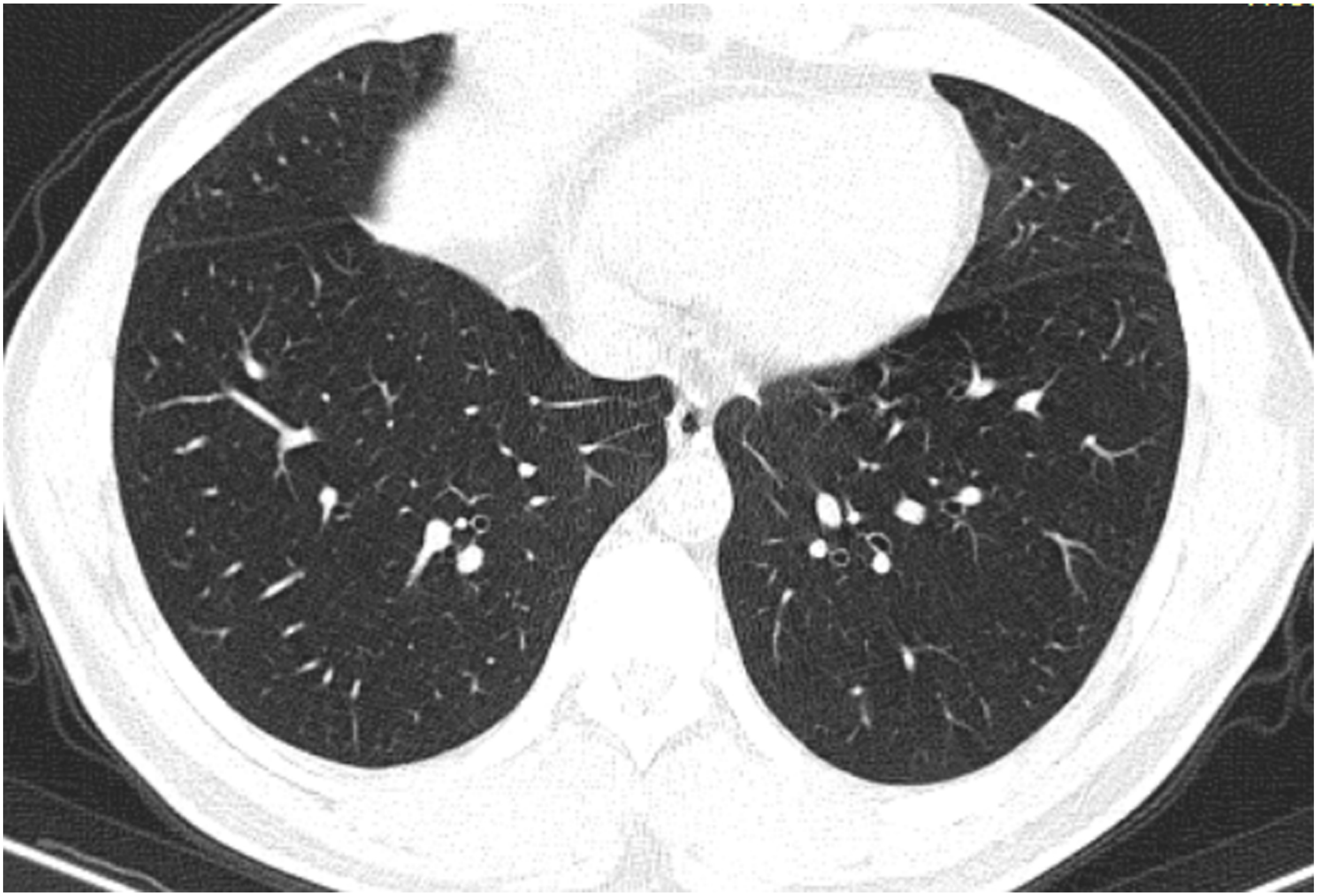

Figure 1

Representative high-resolution CT findings in the mild group. A 34-year-old man with negative findings; the CT severity score was 0 and the NLR was 1.55

Figure 2

Representative high-resolution CT findings in the moderate group. a A 52-year-old man with solitary ground-glass opacity and fan-shaped morphology (black arrow), air bronchograms (coarse yellow arrow), and vascular enlargement (yellow arrow) in the left lower lobe; the CT severity score was 1 and the NLR was 3.67. b A 22-year-old man with multiple ground-glass opacities and rounded morphology (black arrows) in the bilateral lower lobe; the CT severity score was 3 and the NLR was 3.75. c A 32-year-old woman with consolidative pulmonary opacities (black arrows) and air bronchograms (coarse yellow arrow) in the bilateral lower lobes, a subpleural distribution, and ground-glass opacities with irregular morphologies (black arrow) in the left upper lobe; the CT severity score was 5 and the NLR was 4.16

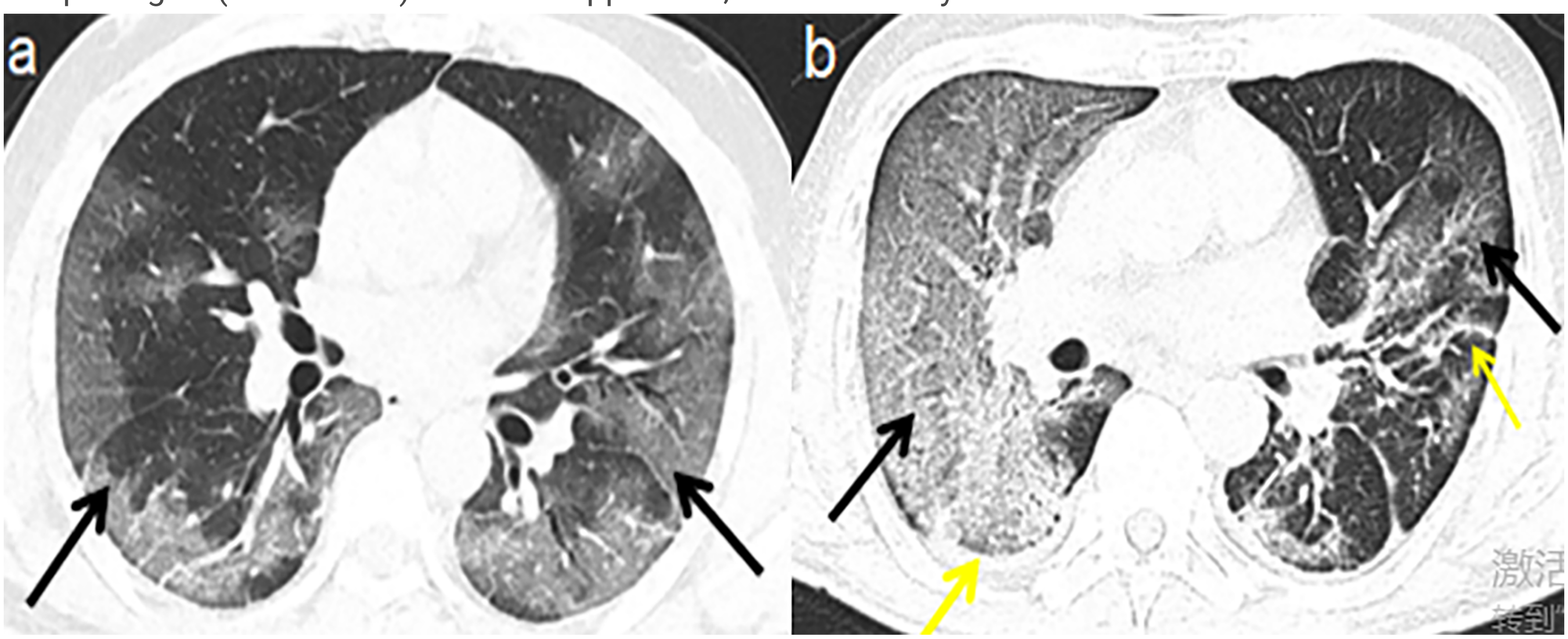

Figure 3

Representative high-resolution CT findings in the severe group. a A 34-year-old man with large bilateral ground-glass opacities, and a subpleural distribution (black arrows); the CT severity score was 12 and the NLR was 9.23. b A 60-year-old man with totally diffuse ground-glass opacities in the right lung with an appearance like “white lung” (black arrow), a small amount of pleural effusion (coarse yellow arrow), and patchy ground-glass opacities (black arrow), fibrosis (yellow arrow) in the left lung; the CT severity score was 18 and the NLR was 14.61

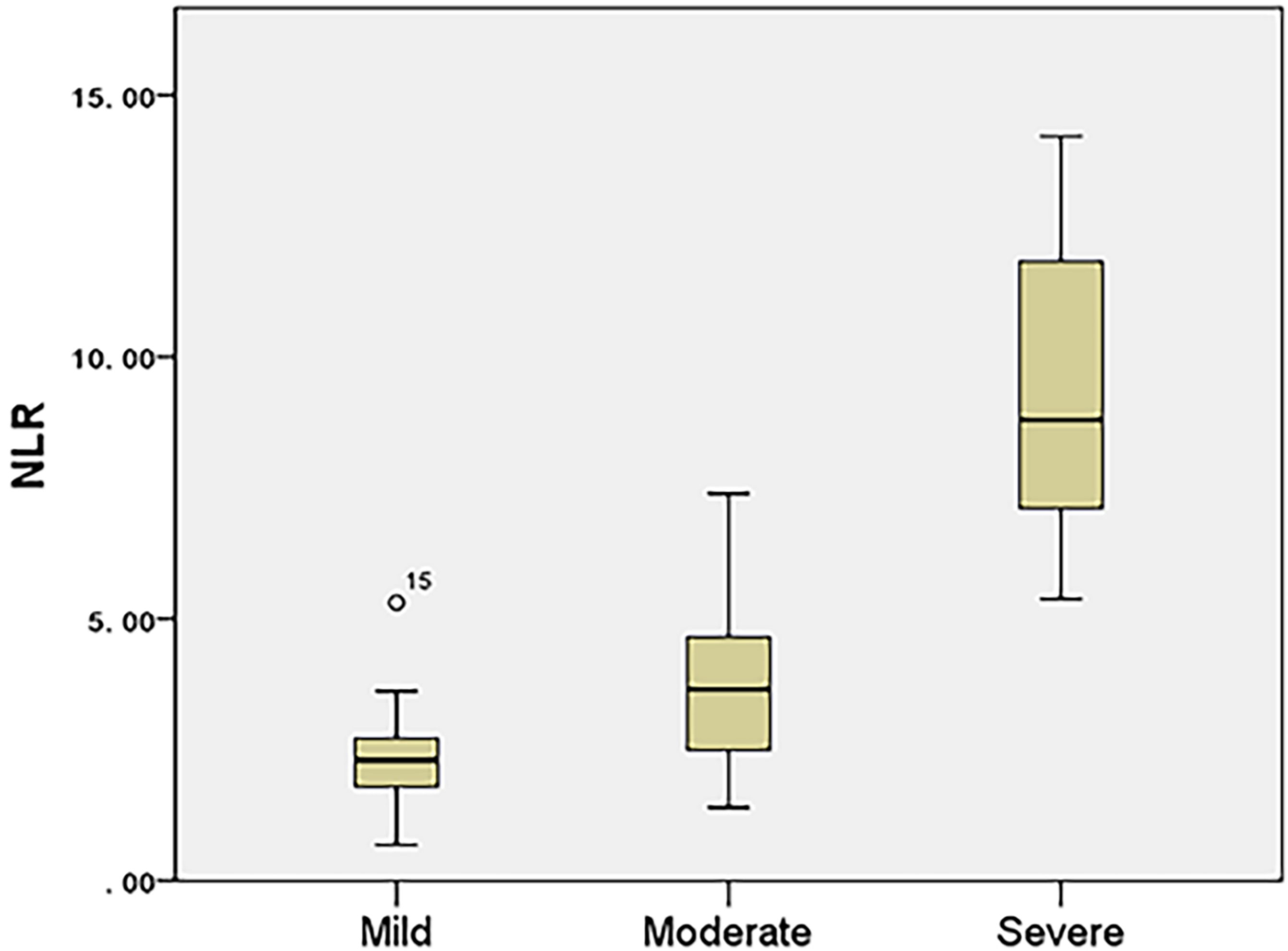

Figure 4

Box and whisker plots of NLR in the three groups

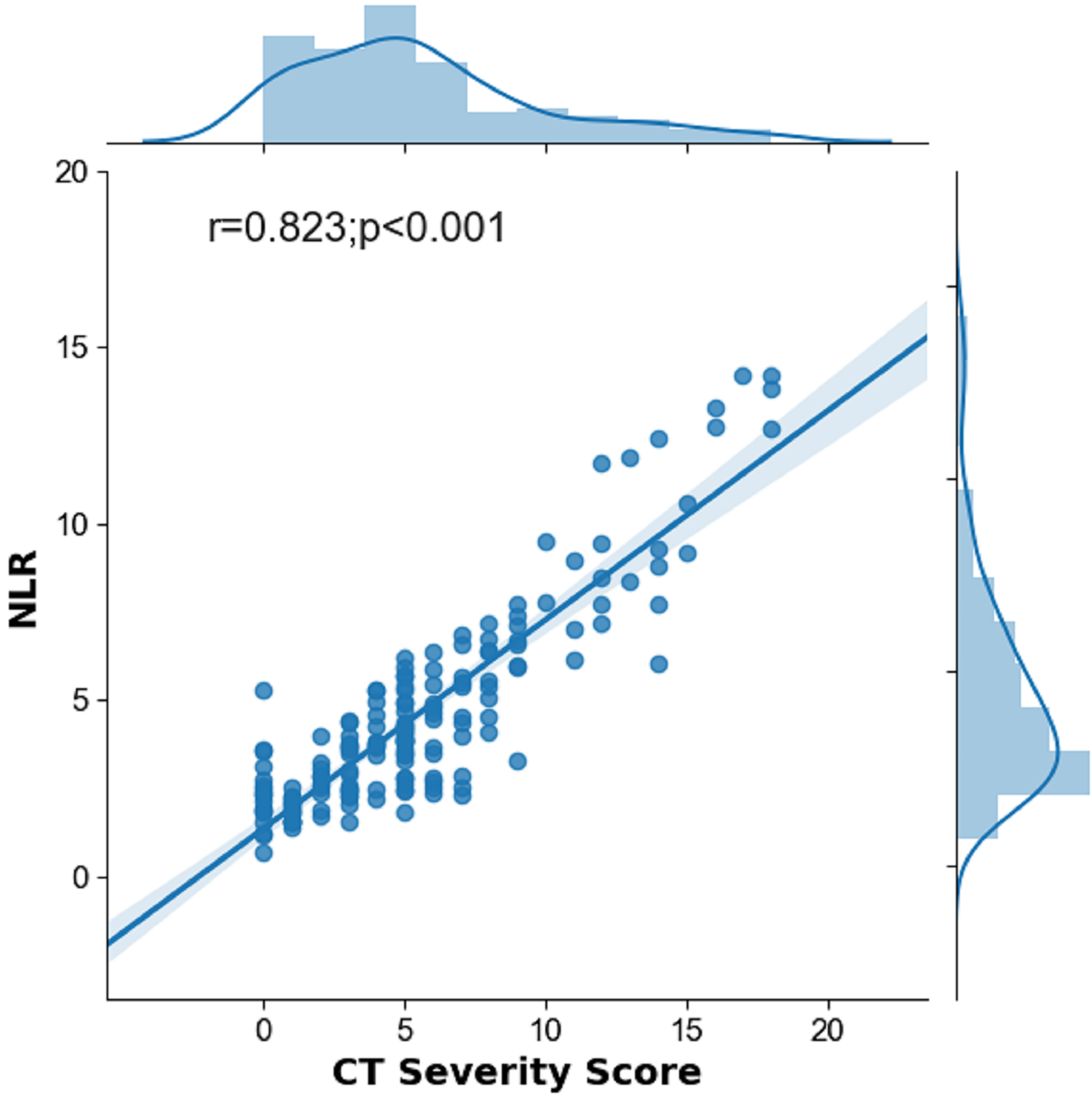

Figure 5

Correlation of NLR and CT severity score in the 167 COVID-19 patients

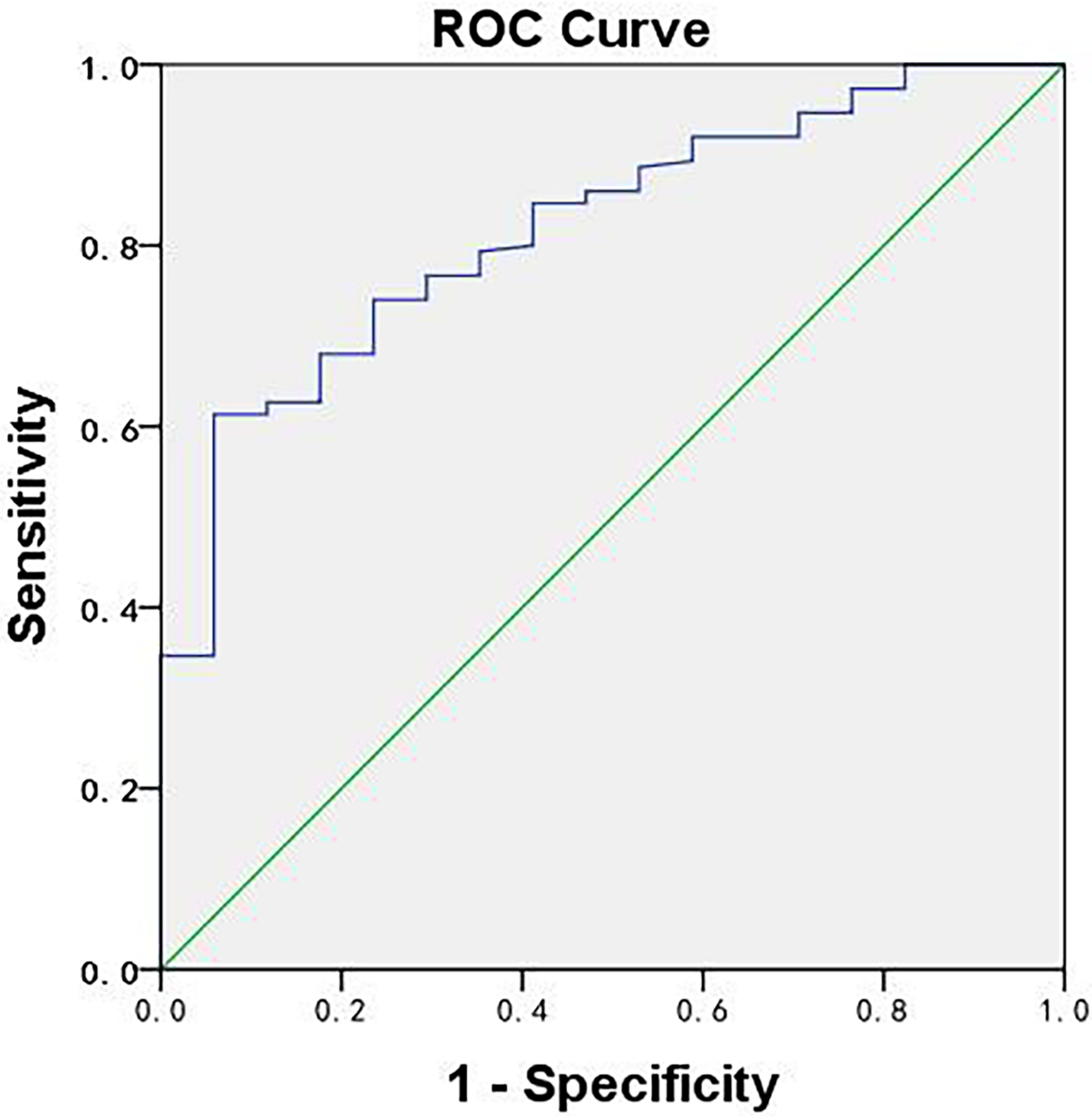

Figure 6

ROC curve of NLR for differentiating negative and positive CT findings in the 167 COVID-19 patients. The AUC was 0.819, with a sensitivity of 61.3% and a specificity of 94.1%