Bilateral Terrible Triad Elbow the rare injury, an Operative challenge: A case report

Dheeraj somanath Attarde (dheerajattarde@yahoo.co.in)
Sancheti Institute for Orthopaedics and Rehabilitation https://orcid.org/0000-0002-7670-6443

Atul Patil
Sancheti Institute for Orthopaedics and Rehabilitation

Parag Sancheti
Sancheti Institute for Orthopaedics and Rehabilitation

Ashok Shyam
Sancheti Institute for Orthopaedics and Rehabilitation

Research Article

Keywords: bilateral terrible triad, terrible triad injury, MCL, LCL, coronoid

Posted Date: February 23rd, 2021

DOI: https://doi.org/10.21203/rs.3.rs-236876/v1

Abstract

Terrible triad of the elbow are a part of rare complex injury around elbow and consists of posterior dislocation combined with the fractures of the radial head and coronoid process of the ulna. Variable outcome has been reported in such injuries, we report a case of a 44-year-old man presenting with bilateral terrible triad of the elbow joints injured due to fall from height. Our surgical procedure included fixation of the radial head through a lateral approach on one side and excision of fractured fragment on another along with lateral collateral ligament (LCL) repair bilaterally, also fixation of the coronoid process and repair of medial collateral ligament (MCL) done on both sides through an anteromedial incision. Bone union was achieved 3 months after surgery. Patient resumed his routine activities at end of 5 months with good functional outcome.

Introduction

Hotchkiss first described terrible triad [1] as “a fracture of the radial head associated with the fracture of the coronoid process of the ulna and posterior dislocation of the elbow”. This type of injury usually occurs from falling on the extended arm, in supination position of the forearm and exercising a valgus stress on the elbow. Surgical intervention is advised in such injury because it is off paramount importance to reconstruct the ligamentous structures in order to obtain the stability of the joint to permit early motion and stable joint. The challenge is to avoid various complications such as elbow stiffness to allow good functional recovery. There is a consensus among the literature that this injury represents a challenge because of its high instability of the elbow, which is prone to joint stiffness and secondary arthrosis, leading to an unfavorable prognosis. [2] Furthermore, the reduced amount of studies published in literature, and not yet a known protocol, makes it harder to choose the proper technique in solving this type of pathology.

Therefore, a better knowledge of the biomechanics and anatomy, with a good stability and early motion is necessary when expecting a good outcome.

Case Report

A 44 years old Right hand dominant civil engineer male without any known medical co-morbidities was brought the trauma department after sustaining a fall from ladder with upper limbs straight and touched the ground using his palms. In fall from height injuries patient sustains axial skeleton fractures, but as patient landed on his palms body weight was transferred to elbows leading to elbow injury. Same pattern of bilateral elbow injury with this mode of fall is very rare in literature. Plain radiographs taken (Fig. 1) showed bilateral dislocation of both elbows, with radial head and coronoid process associated fractures. There was no external wound but considerable swelling was present. 3D- CT scan was done to identify fracture morphology. CT scan showed Hotchkiss modified Mason type 2 radial head fracture constituting > 30% articular area on right side and type 1 on left side. A type II Regan Morrey fracture of the coronoid

process was also present bilaterally. (Fig. 1) Above elbow slab was applied and surgery was done in the same sitting on both sides 2 days after injury.

Planning of surgery was is important in such case as bilateral elbow involvement was there and with young age and high functional demand careful execution of surgical plan should be done. Surgery was performed under regional anesthesia in supine position. On the right side owing to nature and displacement of radial head decision of radial head fixation was taken with lateral approach. Radial head was fixed with two Herbert screws. Once radial head was fixed, elbow instability was found out under image intensifier and with anteromedial approach coronoid was fixed with suture anchor and MCL was repaired. LCL was repaired and elbow was stable clinically as well as on image intensifier. On the left side, lateral approach was taken, due to < 10 % articular involvement and comminuted nature of radial head fragment, fractured fragment was excised. Anteromedial approach was taken to fix coronoid fracture and later LCL was also repaired with Suture anchor. Elbow stability was checked clinically as well as under image intensifier. Above elbow posterior slab support was given bilaterally for two weeks to allow soft tissue healing and after that gradual active elbow rehabilitation was done. We started with gradual prono-supination exercises as well as elbow flexion and extension exercise after two weeks of surgery. Indomethacin was given to prevent myositis ossificans. Patient was advised not to lift heavy weight with right arm while gradual weight lifting started at left side, after reasonable strength was achieved on left side, right arm was allowed to lift weight from post-operative 6 weeks. At the end of three months good functional and radiological result was obtained bilaterally. (Fig. 2) Right side range of motion was 30 to 130 degree and left side 10 to 150 degree, bilaterally pronation supinations were 50 and 80 degrees respectively. Patient resumed his working activities at end of 5 months, post-operatively. (Fig. 3)

Discussion

The mechanism of injury is important determinant of the terrible triad. Mechanism this complex injury can be explained by the following sequence of events. The patient straightened the elbows with forearm supination when he fell from standing height. The axial force transmitted to the ulnohumeral joint contributed to posterior dislocation and led to the radial head and coronoid fractures. In this case, the patient touched the ground first on right side with excessive abduction of the elbow, and the valgus stress drove the fragments of the radial head to the ulnar side and probably caused the MCL injury simultaneously. As initial impact was more on right side that explains more comminution of radial head on right as compared to left elbow. The purposes of treatment of terrible triad injury is to recover the congruency of the elbow joint, restore stability, and allow early joint mobility of the elbow to avoid complications.[3] Both the standard protocols proposed by Pugh et al. for treating the terrible triad of the elbow have consists of restoration of the anatomical structure of humeroradial joint, Reduction and fixation of the coronoid process fracture, Repaired or restoration of joint capsular injuries to the lateral stability of the LCL complex and repairing the MCL when needed.

There are various approaches have been reported to treat the terrible triad of the elbow. We chose a combination of lateral (Kocher approach) and anteromedial approaches, which is less traumatic, more

effective for fracture exposure and more directly to check the capsuloligamentous structures. On Radial head is important in giving posterolateral stability of elbow joint. In literature it is suggested that mason type 2 radial head fracture when fixed gives better functional outcome compared to arthroplasty. [4] Therefore, we decided to fix radial head with two Herbert screw to prevent soft tissue irritation because of implant and to give more rigid fixation. But at the same time controversy remains for minimally displaced and small fragment of radial head. Fixation of small fragment remains challenge due to shattering of fragment while passing screw, back-out of implant because of joint forces. Radial head fracture fragment also dictates mode of treatment, as in our case radio-ulnar articulation was not affected, small anterior portion of radial head was excised as it involved difficult to fix. Terrible triad injuries have bone as well as soft tissue component. Soft tissue repair is important to give stability to elbow, MCL and LCL repair is important to stabilize joint and allow functional recovery. [5] A gradual rehabilitation protocol makes sure reasonable elbow range of motion can be achieved and patient returns to functional activity as early as possible. As injury was severe on right side, range of motion was observed less as compared to left. This can be attributed to various factors ranging from soft tissue component to radial head comminution on right side. The most common complication after terrible triad injury is stiffness, in our patient we observed same. Additionally, we did not observe any complication with screw fixation of the radial head fracture that reported in the literature such as loss of forearm rotation, nonunion, and implantation failure.

We report a rare case of bilateral terrible triad of the elbow joints with uncommon mode of injury and treated with different protocols on each side. The combination of 3 D- CT scan study, bio-mechanics and anatomy of fracture fragment dictates surgical plan. The individualized fixation plan along with combination of lateral and anteromedial approaches is a reliable method for the management and good functional outcome can be obtained in such complex rare injuries.

Declarations

Funding

There is no funding source.

Ethical approval

Ethical approval obtained.

Informed consent

Informed consent was obtained.

Disclosure

None of the authors received payments or services, either directly or indirectly (i.e., via his or her institution), from a third party in support of any aspect of this work. No author has had any other

relationships, or has engaged in any other activities, that could be perceived to influence or have the potential to influence what is written in this work.

References

1. Hotchkiss RN. Fractures and dislocations of the elbow. Fractures in adults. 1996: 929-1024.
2. Pugh DM, McKee MD. The "terrible triad" of the elbow. *Tech Hand Up Extrem Surg*. 2002; 6(1): 21–9.
3. Mathew PK, Athwal GS, King GJ. Terrible triad injury of the elbow: current concepts. *J Am Acad Orthop Surg*. 2009;17: 137–151.
4. Domos P, Griffiths E, White A. Outcomes following surgical management of complex terrible triad injuries of the elbow: a single surgeon case series. *Shoulder Elbow*. 2018; 10(3): 216-22.
5. Singh J, Elvey MH, Hamoodi Z, Watts AC. Current perspectives on elbow dislocation and instability. *Ann Joint*.

Figures

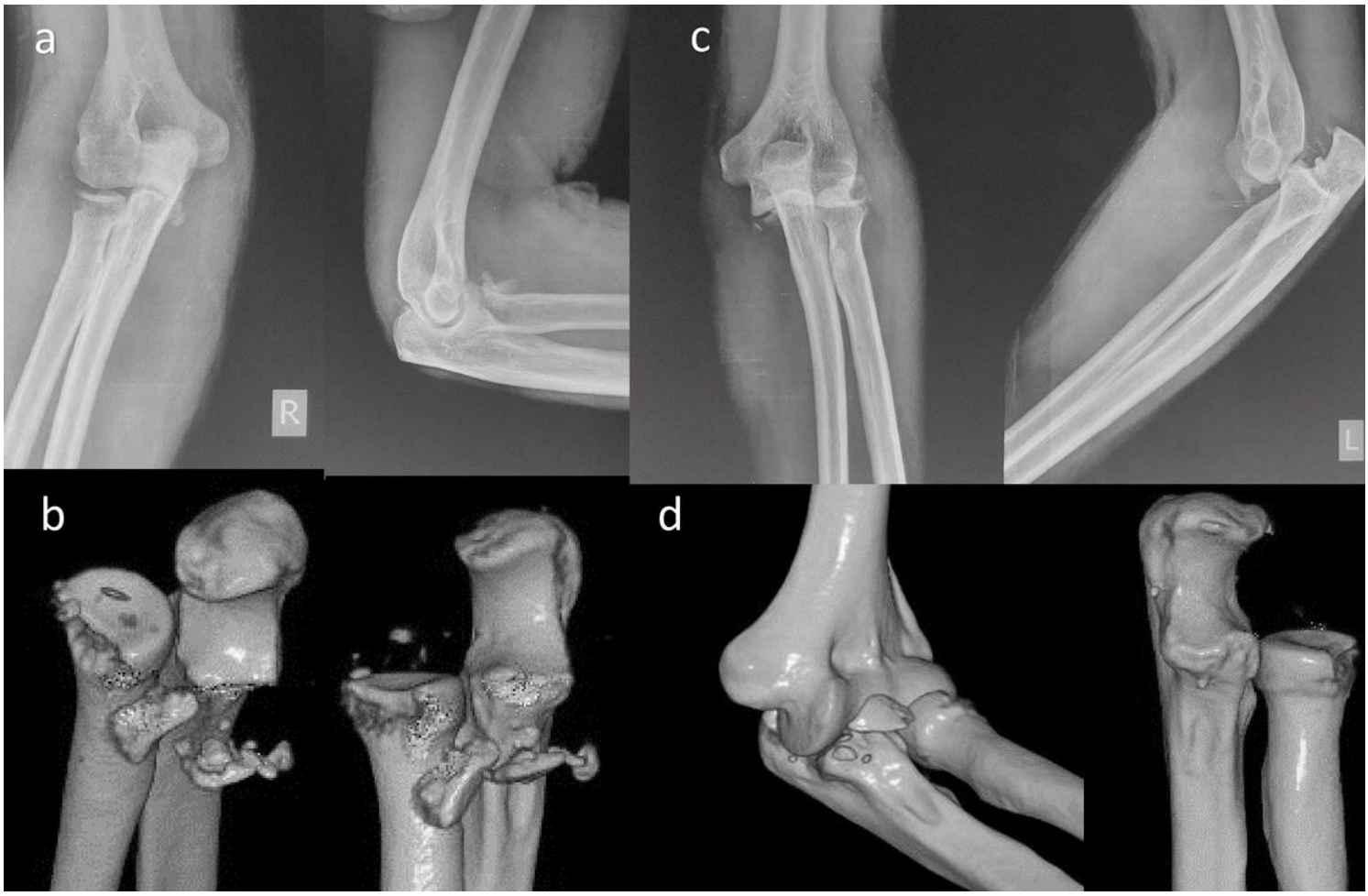

Figure 1

Above elbow slab was applied and surgery was done in the same sitting on both sides 2 days after injury.

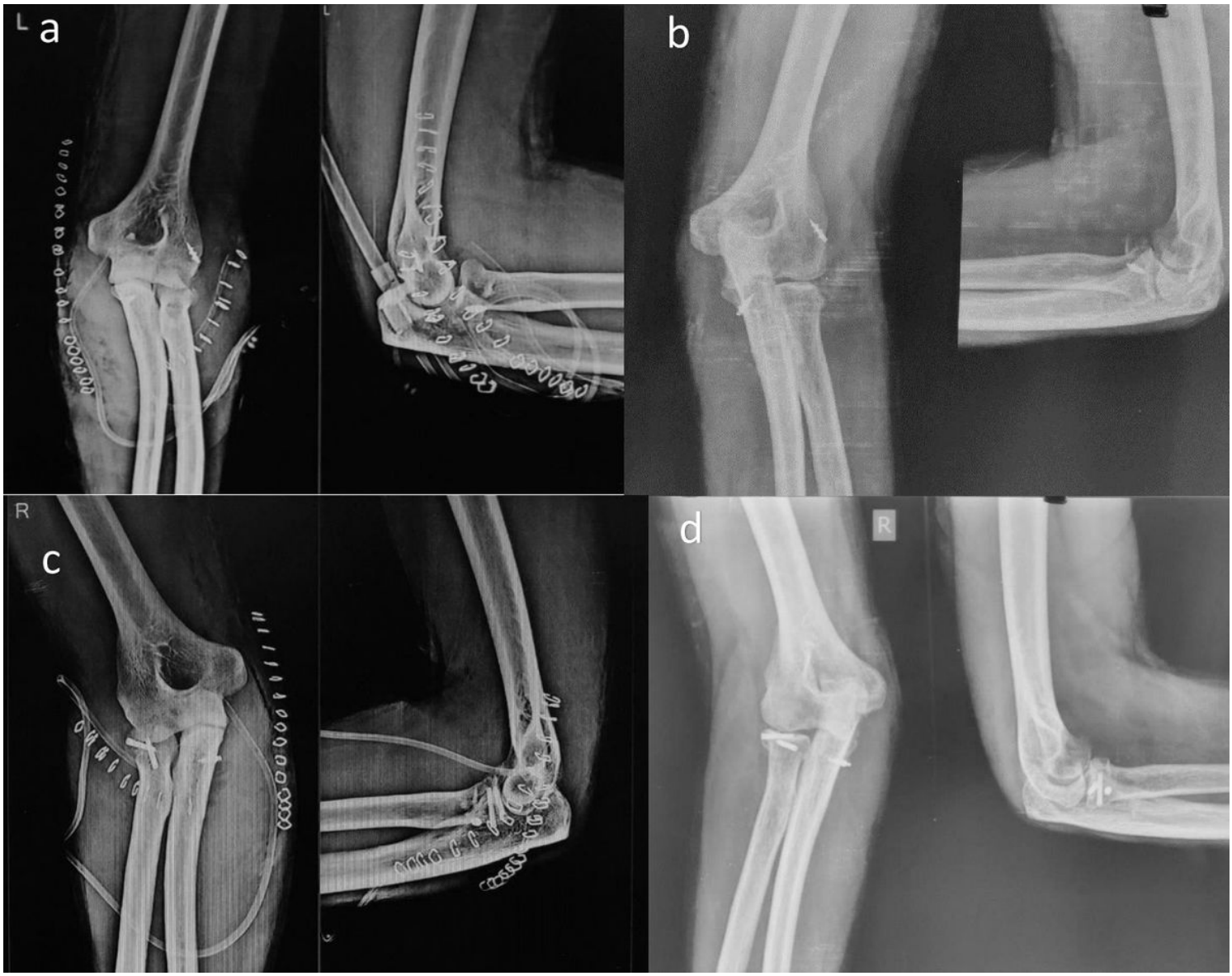

Figure 2

Right side range of motion was 30 to 130 degree and left side 10 to 150 degree, bilaterally pronation supinations were 50 and 80 degrees respectively.

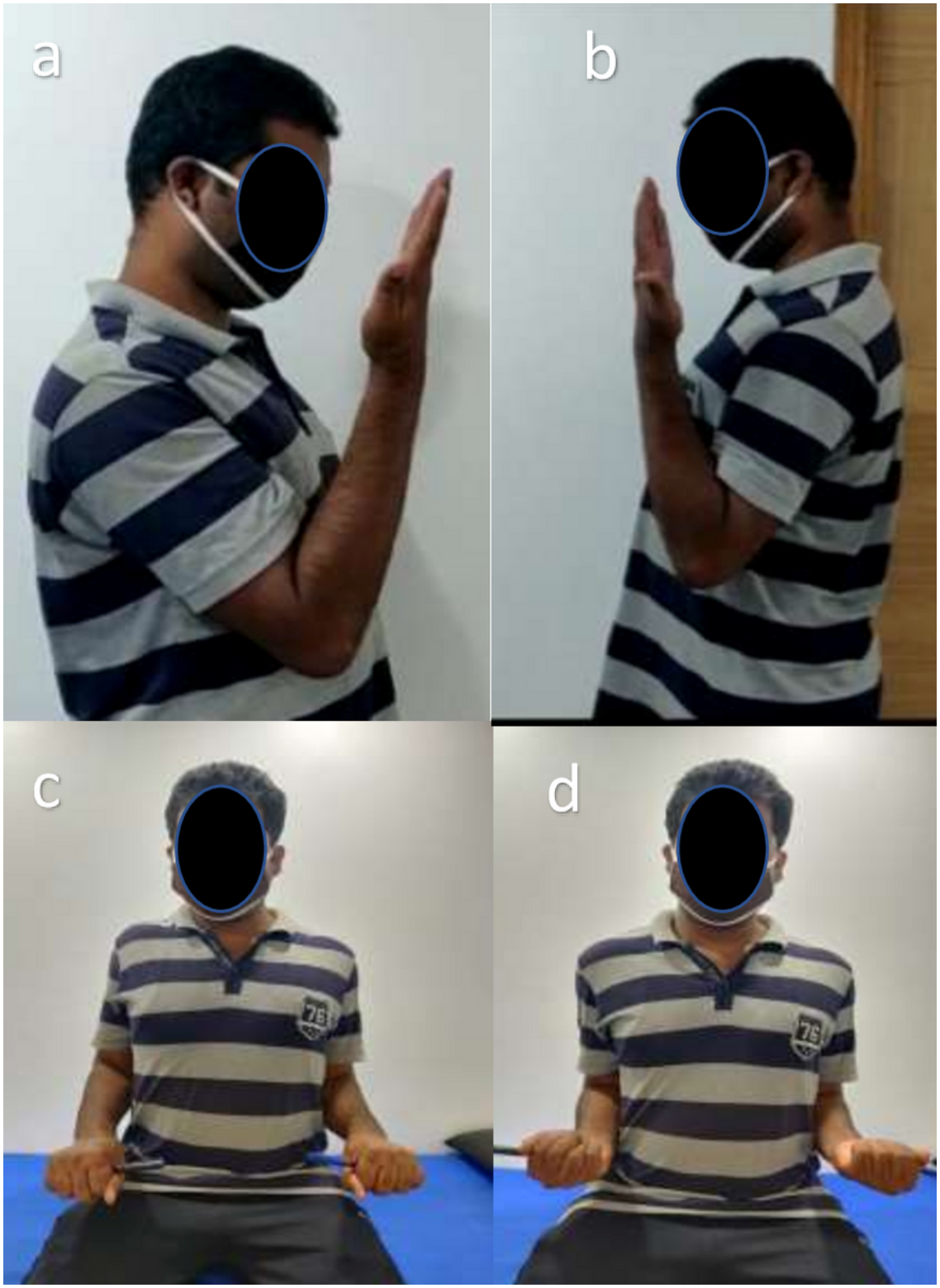

Figure 3

Patient resumed his working activities at end of 5 months, post-operatively. (Fig. 3)