^{18}F-FDG PET/CT uptake in COVID-19: case report of a patient with lung metastases after treatment of nasal cavity malignancy

Hongyan Feng
PET-CT/MRI Center & Molecular Imaging Center, Wuhan University Renmin Hospital

Lihong Bu (bulihongs@whu.edu.cn)
PET-CT/MRI Center & Molecular Imaging Center, Wuhan University Renmin Hospital

Case Report

Keywords: 18F-FDG PET/CT, Corona Virus Disease 2019 (COVID-19), severe acute respiratory syndrome corona virus 2 (SARS-CoV-2), lung metastases; Case report

Posted Date: April 22nd, 2020

DOI: https://doi.org/10.21203/rs.3.rs-23861/v1

Abstract

Background: In high COVID-19 prevalence region, COVID-19 disease may be incidental found in non-specific symptoms or asymptomatic patient with history of tumor who underwent ^{18}F-FDG-PET/CT for standard oncologic indications.

Case presentation: A 51-year-old woman with a 4-year history of adenoid cystic carcinoma of nasal cavity underwent ^{18}F-FDG PET/CT for restaging during COVID-19 outbreak in Wuhan. Pneumonia lesions were characterized by 18F-FDG uptake ground-glass opacities (GGOs) and multifocal high 18F-FDG-avid patchy consolidation, and without lymph node involvement and pleural effusion. Furthermore, multiple 18F-FDG-positive lung and lumbar metastases were observed. Finally, a diagnosis of COVID-19 was made based on a positive real-time fluorescent polymerase chain reaction (RT-PCR) test of SARS-CoV-2 nucleic acid.

Conclusion: The non-specific symptoms or asymptomatic cancer patients presenting 18F-FDG-positive GGOs and patchy consolidation lesions in lung may favor COVID-19, who should be quickly SARS-CoV-2 nucleic acid tested and monitored.

Background

A worldwide epidemic of aggressive acute respiratory disease COVID–19 outbreak in Wuhan, China, during the past 3–4 months, which caused by a novel coronavirus SARS-CoV–2 [1,2]. The common clinical symptoms of COVID–19 such as fever, cough, dyspnea, pharyngalgia, headache and nausea, but someone may present with non-specific symptoms or may entirely remain asymptomatic, which are deemed to be significant problem for control propagate infection in the population [3,4]. CT typically characteristic including ground-glass opacities (GGOs) or bilateral pulmonary consolidations in multiple lobular were reported in literature [5–7]. Viral RNA detection is considered as the gold standard for the diagnosis of COVID–19. Because of a high false negative rate of reverse transcriptase-polymerase chain reaction (RT-PCR) test, clinical diagnosis is generally based on exposure history, clinical manifestations, laboratory characteristics, and findings on chest CT [5, 8].

Case Presentation

A 51-year-old woman living in Wuhan with a 4-year history of adenoid cystic carcinoma of nasal cavity underwent ^{18}F-FDG PET/CT for restaging during COVID–19 outbreak, who underwent tumorectomy, and remove of mandibular recurrent and cervical lymph node metastasis later, following postoperative concurrent chemoradiotherapy. On admission, she was afebrile and complained of slight cough and chest tightness for three days. Laboratory testing revealed lymphopenia (LYM; 0.3×10^9 /L), monocytopenia (Mono; 0.03×10^9 /L), and elevation of C-reactive protein (CRP; 152 mg/L, reference range 0–10mg/L). Chest CT scans (12–25–2019) identified GGOs in the left lower lung lobe (Fig.1a, black arrowhead) and lung consolidations in the right lower lung lobe (Fig.1a, black arrows). There were several

5–10mm solid nodules suspected lung metastases in the bilateral lung (Fig.1a and b, white arrowheads). 18F-FDG PET/CT was then suggested for restaging. PET/CT (12–27–2019) revealed 18F-FDG-avid GGOs (SUVmax 3.2–3.8; Fig.2b) and consolidations (SUVmax range 7.6–11.1; Fig.2c) in the lower lung lobe, which considered as highly likely COVID–19, and there was no evidence for lymph node involvement and pleural effusion. Multiple 18F-FDG-positive solid nodules in bilateral pulmonary were considered as lung metastases (SUVmax range 2.9–3.4; Fig. 2d). 18F-FDG-positive lumbar metastasis in L4 was also identified for the first time (SUVmax 6.9; Fig. 2f, white arrow). The only good news is there was no evidence for tumor recurrence in operative region of left nasal cavity (Fig. 2e).

Despite optimal anti-inflammation therapy, she developed a fever (38.5℃–39.4℃) and the respiratory symptoms including chest distress and dyspnea aggravated gradually. Chest CT imaging (01–12–2020 and 01–19–2020; Fig.3a and 3b) showed multiple GGOs and consolidative opacities. When compared with the results of previous PET/CT, a greater number of lesions and an increased extent and density of lesions indicated disease progression. Finally, the diagnosis of COVID–19 was made based on a positive real-time RT-PCR assay of SARS-CoV–2 nucleic acid (01–23–2020). Then, additional antivirus therapy, interferon-α2 and immunoglobulin, as well as high-flow oxygen were given. Subsequently, two chest CT scans (02–03–2020 and 02–27–2020, Fig.3c and 3d) showed significantly absorption of bilateral COVID–19 lesions after effective treatment, but the suspected metastasis lesions enlarged with increasing numbers, and were further proved to be lung metastasis (Fig. 3d, black arrowhead).

Discussion And Conclusion

COVID–19 outbreak initially in Wuhan, China, during December 2019 and then Europe and America were severely affected. By April 9, 2020, COVID–19 had existing infected about 2122 people and asymptomatic infection about 1097 people in China by effective prevention and control measures [9]. PET/CT scans are suggested offered to oncological patients to guarantee the reasonable clinical practice. Thus, attention should be paid on the number of non-specific symptoms or asymptomatic cancer patients who underwent PET/CT. The aim of this case is to illustrate the 18F-FDG PET/CT findings of patients with COVID–19. We observed all GGOs and patchy consolidations lesions in the lung on PET/CT were high FDG-avid, and/or interstitial changes with a peripheral distribution, without lymph node involvement and pleural effusion. This metabolically active behaviour of COVID–19 in 18F-FDG PET/CT is verified in literature [10–12], meanwhile Polverari et al. [11] and Qin et al. [13] revealed lymph node may involvement in COVID–19 pneumonia. Notably, existing disease, especially cancer, may increase the chance of infection and/or mask some of the symptoms of COVID–19, while COVID–19 complicated with existing critical basic diseases usually associated with poor prognosis [14]. Because COVID–19 cases need special infection control, differential diagnosis is therefore critical in such a complex situation. Whole-body PET/CT can accurately define the occurrence, number, size and location of lesions, with reliable anatomical and metabolic information for distinguish malignant lesions from COVID–19 pneumonia in cancer patients. PET/CT may be useful in the evaluation of complex patients, but is not recommended for routine use in COVID–19 diagnosis because of PET/CT scans is complex and might be

a possible risk of COVID–19 spreading attribute to long period of procedure in a relatively confined space [15].

However, this case highlights the non-specific symptoms or asymptomatic cancer patients presenting CT typically characteristic and positive 18F-FDG-avid may favor COVID–19, who should be quickly SARS-CoV–2 nucleic acid tested and monitored, in case COVID–19 pneumonia sudden progression.

Abbreviations

COVID–19: Corona Virus Disease 2019; SARS-CoV–2: severe acute respiratory syndrome corona virus 2; ^{18}F-FDG: 18F-fluorodeoxyglucose; PET: positron emission tomography; CT: computed tomography; GGOs: ground-glass opacities; RT-PCR: real-time fluorescent polymerase chain reaction; LYM: lymphopenia; Mono: monocytopenia; CRP: C-reactive protein; L4: lumbar vertebra 4.

Declarations

Ethics approval and consent to participate

Not Applicable.

Consent for publication

Written informed consent was obtained from the patient for publication of this this case and accompanying image.

Availability of data and materials

Data sharing is not applicable to this article as no datasets were generated or studied during the current study (as this is a case report).

Competing interests

The authors declare that they have no competing interests.

Funding

This work was partially supported by the National Natural Science Foundation of China (grant 81701735 to Dr Feng and grant 81871419 to Dr. Bu,) and Seed project in Sino foreign joint research platform of Wuhan University (2309-413100006 to Dr. Bu). These funds provided financial support for the research work of our article but had no role in the study.

Authors' contributions

FH was responsible for collecting clinical data, finding and reading the Cover Letter literature, and manuscript preparation. BL was responsible for the design of article, interpretation results and the revision of the manuscript.

Acknowledgements

Not Applicable.

Authors' information (optional)

PET-CT/MRI Center & Molecular Imaging Center, Wuhan University Renmin Hospital, Wuhan 430060, Hubei, China.

References

1. Zhu N, Zhang D, Wang W, Li X, Yang B, Song J, Zhao X, Huang B, Shi W, Lu R, Niu P, Zhan F, Ma X, Wang D, Xu W, Wu G, Gao GF, Tan W; China Novel Coronavirus Investigating and Research Team. A novel corona virus from patients with pneumoniain China, 2019. *N Engl J Med.* 2020; 382: 727-33.
2. World Health Organization. Novel Coronavirus(2019-nCoV) Situation Report - 80. https://www.who.int/docs/default-source/coronaviruse/situation-reports/20200409-sitrep-80-covid-19.pdf?sfvrsn=1b685d64_4. Accessed Jan. 30, 2020.
3. Chen N, Zhou M, Dong X, Qu J, Gong F, Han Y, Qiu Y, Wang J, Liu Y, Wei Y, Xia J, Yu T, Zhang X, Zhang L. Epidemiological and clinical characteristics of 99 cases of 2019 novel coronavirus pneumonia in Wuhan, China: a descriptive study. *Lancet*. 2020; 395: 507-13.
4. Huang C, Wang Y, Li X, Ren L, Zhao J, Hu Y, Zhang L, Fan G, Xu J, Gu X, Cheng Z, Yu T, Xia J, Wei Y, Wu W, Xie X, Yin W, Li H, Liu M, Xiao Y, Gao H1, Guo L, Xie J, Wang G, Jiang R, Gao Z, Jin Q, Wang J, Cao B. Clinical features of patients infected with 2019 novel coronavirus in Wuhan, China. *Lancet*. 2020; 395: 497-506.
5. Ai T, Yang Z, Hou H, Zhan C, Chen C, Lv W, Tao Q, Sun Z, Xia L. Correlation of Chest CT and RT-PCR Testing in Coronavirus Disease 2019 (COVID-19) in China: A Report of 1014 Cases. *Radiology*. 2020; doi: 10.1148/radiol.2020200642.
6. Xu X, Yu C, Qu J, Zhang L, Jiang S, Huang D, Chen B, Zhang Z, Guan W, Ling Z, Jiang R, Hu T, Ding Y, Lin L, Gan Q, Luo L, Tang X, Liu J. Imaging and clinical features of patients with 2019 novel coronavirus SARS-CoV-2. *Eur J Nucl Med Mol Imaging.* 2020; doi: 10.1007/s00259-020-04735-9.
7. Chung M, Bernheim A, Mei X, Zhang N, Huang M, Zeng X, Cui J, Xu W, Yang Y, Fayad ZA, Jacobi A, Li K, Li S, Shan H. CT Imaging Features of 2019 Novel coronavirus (2019-nCoV). *Radiology*. 2020; 295: 202-7.
8. Lan L, Xu D, Ye G, Xia C, Wang S, Li Y, Xu H. Positive RT-PCR Test Results in Patients Recovered From COVID-19. JAMA. 2020; doi: org/10.1001/jama.2020.2783

9. National Health Commission of the People's Republic of China. http://www.nhc.gov.cn/xcs/yqfkdt/202004/6b7e8905b62f4cf89517cb0ebdf24d00.shtml. Accessed April. 10, 2020.
10. Albano D, Bertagna F, Bertolia M, Bosio G, Lucchini S, Motta F, Panarotto MB, Peli A, Camoni L, Bengel FM, Giubbini R. INCIDENTAL FINDINGS SUGGESTIVE OF COVID-19 IN ASYMPTOMATIC PATIENTS UNDERGOING NUCLEAR MEDICINE PROCEDURES IN A HIGH PREVALENCE REGION. J Nucl Med. 2020; doi: 10.2967/jnumed.120.246256.
11. Polverari G, Arena V, Ceci F, Pelosi E, Ianniello A, Poli E, Sandri A, Penna D. 18F-FDG uptake in Asymptomatic SARS-CoV-2 (COVID-19) patient, referred to PET/CT for Non-Small Cells Lung Cancer restaging. J Thorac Oncol. 2020; doi: 10.1016/j.jtho.2020.03.022.
12. Zou S, Zhu X. FDG PET/CT of COVID-19. Radiology. 2020; doi: 10.1148/radiol.2020200770.
13. Qin C, Liu F, Yen TC, Lan X. ^{18}F-FDG PET/CT findings of COVID-19: a series of four highly suspected cases. Eur J Nucl Med Mol Imaging. 2020, 47(5): 1281-6.
14. Wang D, Hu B, Hu C, Zhu F, Liu X, Zhang J, Wang B, Xiang H, Cheng Z, Xiong Y, Zhao Y, Li Y, Wang X, Peng Z. Clinical Characteristics of 138 Hospitalized Patients With 2019 Novel Coronavirus-Infected Pneumonia in Wuhan, China. *JAMA*. 2020; doi: 10.1001/jama.2020.1585.
15. Joob B, Wiwanitkit V. 18F-FDG PET/CT and COVID-19. Eur J Nucl Med Mol Imaging. 2020; doi: 10.1007/s00259-020-04762-6.

Figures

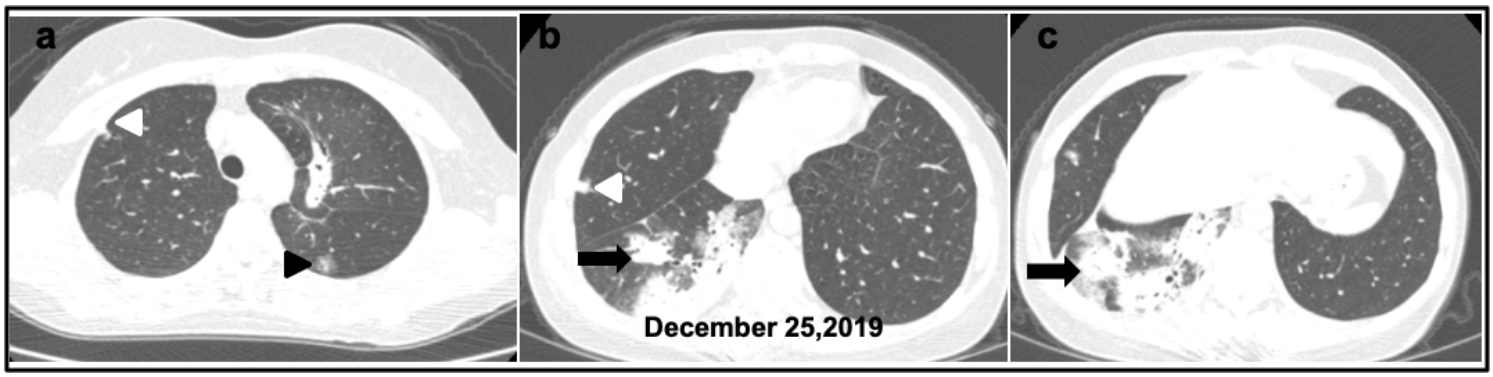

Figure 1

Chest CT images in a 51-years old female with a 4-year history of adenoid cystic carcinoma of nasal cavity. a-c: Chest CT images showed GGOs (black arrowhead), consolidative opacities (black arrows) and solid nodules in the bilateral lung (white arrowheads).

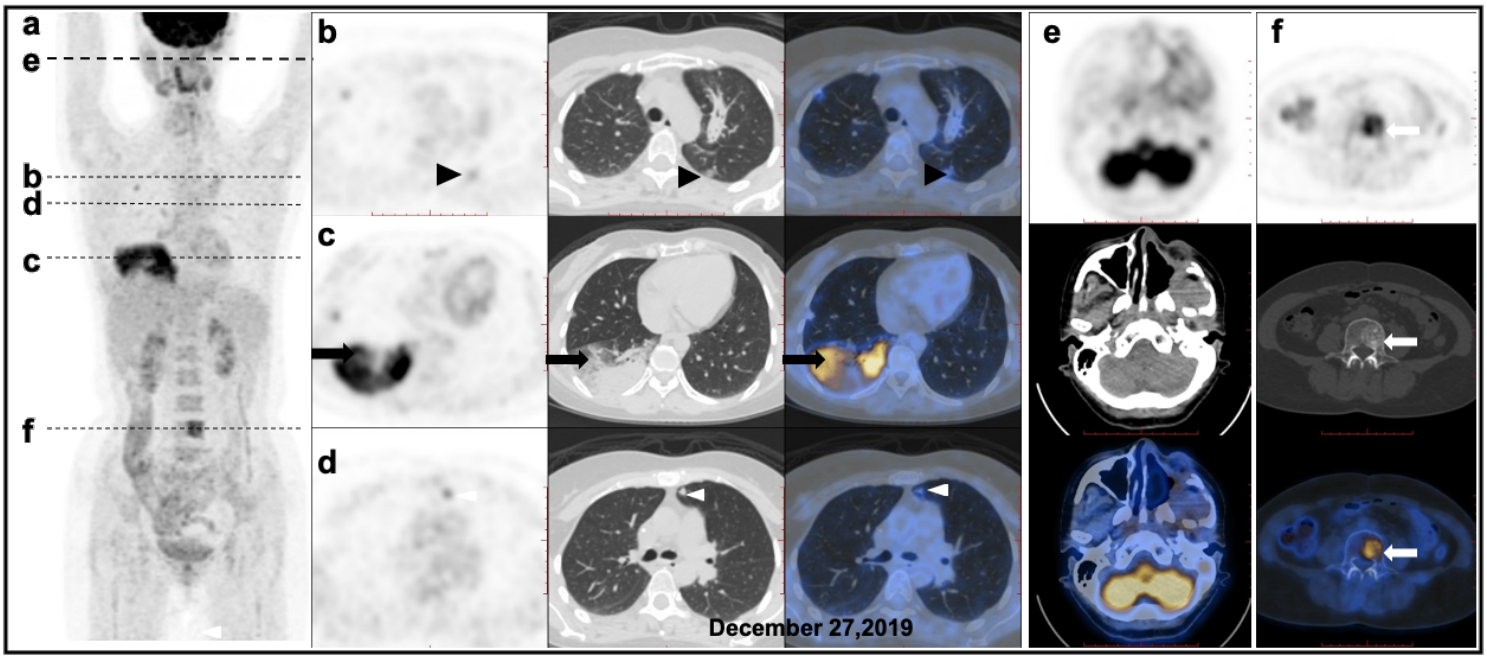

Figure 2

18F-FDG PET/CT images of maximum intensity projection(a), axial PET, CT and fused PET/CT of lungs (b-d), nasal cavity (e) and the lumbar vertebra 4 (f). PET/CT showed FDG-avid GGOs and consolidative opacities in both lungs (b-c), multiple FDG-positive solid nodules were considered as lung metastases (d) and FDG-positive lumbar metastasis in L4 (f).

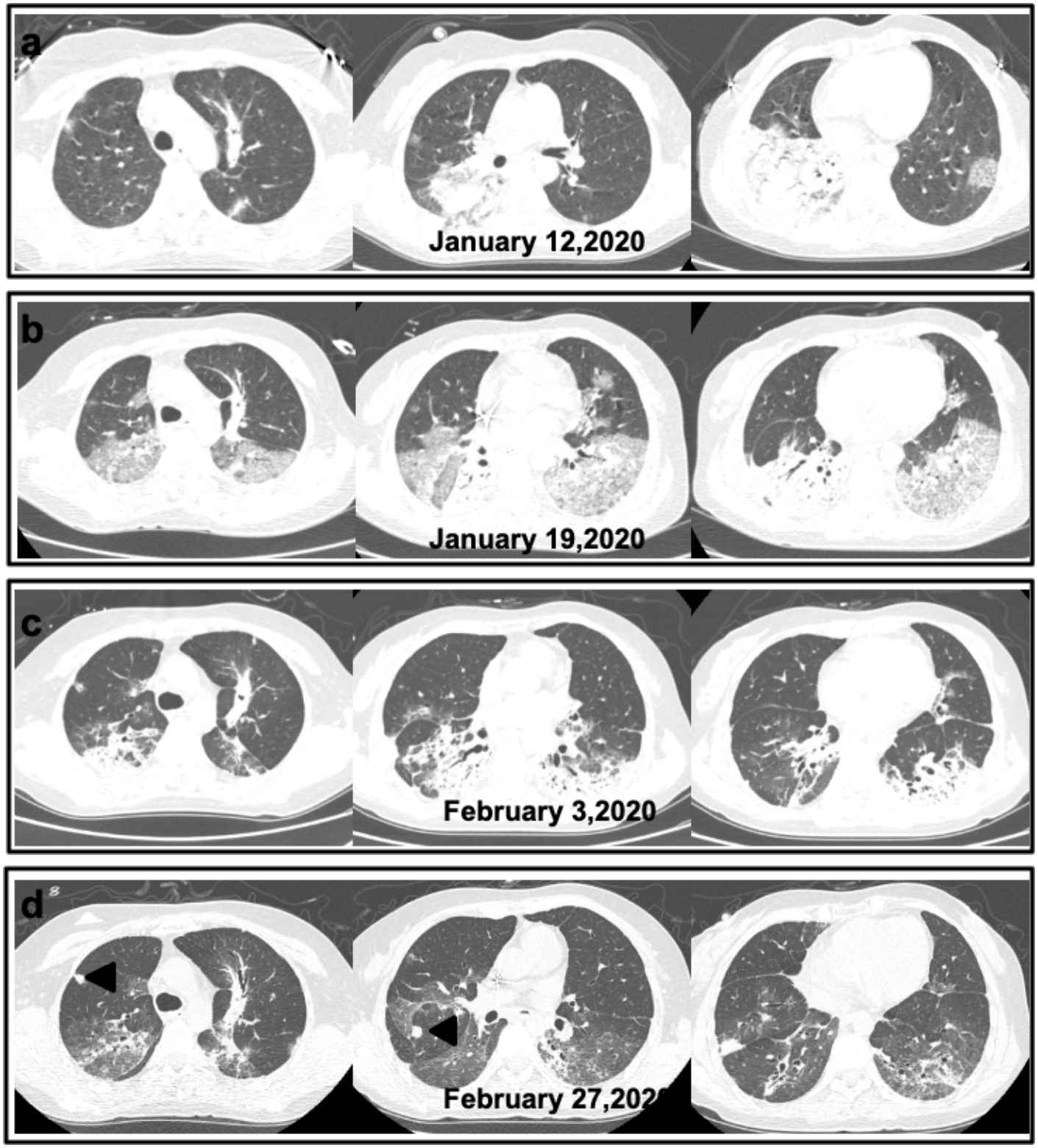

Figure 3

Chronologically CT during the treatment of COVID-19. a-b: Chest CT images suggested multiple GGOs and consolidative opacities lesions more and bigger than the results of previous PET/CT. c-d: Chest CT images showed significantly absorption of bilateral COVID-19 lesions.