Intrathecal or Extracapuslar Lymph Nodes Dissection For Patients With Rectal and Sigmoid Colon Cancer

Wei Ge

Department of general surgery, Nanjing Drum Tower Hospital, the affiliated Hospital of Nanjing University Medical School, Nanjing 210008, Jiangsu Province, P. R. China.

Li-hua Shao

Department of general surgery, Nanjing Drum Tower Hospital, the affiliated Hospital of Nanjing University Medical School, Nanjing 210008, Jiangsu Province, P. R. China.

Hai-yan Gong

Physical examination center, Nanjing Drum Tower Hospital, the affiliated Hospital of Nanjing University Medical School, Nanjing 210008, Jiangsu Province, P. R. China.

Gang Chen (331812195@qq.com)

Department of general surgery, Nanjing Drum Tower Hospital, the affiliated Hospital of Nanjing University Medical School, Nanjing 210008, Jiangsu Province, P. R. China.

Research Article

Keywords: Colorectal cancer, intrathecal dissection, extracapuslar dissection, lymph nodes dissection, rectal cancer

Posted Date: March 1st, 2021

DOI: https://doi.org/10.21203/rs.3.rs-239007/v1

Abstract

Aim: To investigate that whether intrathecal lymph nodes dissection is superior to extracapsular lymph nodes dissection for patients with rectal and sigmoid colon cancer.

Methods: We performed a retrospective clinical study between August, 2017 and October, 2019 at the department of general surgery, the affiliated hospital of Nanjing University Medical School. According to the ways of lymph nodes dissection, these patients were divided into extracapuslar group and intrathecal group. We then compared the curative effect and safety between the two groups.

Results: A total of 211 patients were recruited in this retrospective study and assigned as follows: 62 cases to the intrathecal group and 149 patients to extracapuslar group. There were no statistic differences in the total number of lymph nodes, number of positive lymph nodes, and nodal staging between the two groups. However, the amount of bleeding in intrathecal group was significantly higher than that in extracapuslar group (p=0.000) and the operation time in intrathecal group was also significantly longer than that in extracapuslar group (p=0.000).

Conclusion: Dissecting lymph nodes by extracapuslar dissection is preferred in radical resection of patients with rectal and sigmoid colon cancer.

Statement: This paper compared the curative effect and safety between intrathecal and extracapsular lymph nodes dissection for patients with rectal and sigmoid colon cancer. This topic has never been reported in the literature and has great clinical significance.

Introduction

Colorectal cancer (CRC) is one of the most common gastrointestinal malignancies in the world, accounting for the second largest number of gastrointestinal tumors. Nowadays, the incidence of CRC is increasing by 4% every year, threatening the human health seriously. At present, radical resection of CRC is the main treatment method for CRC. With the gradual development of radical surgical techniques for CRC, the resection rate and radical treatment rate of CRC increased significantly, and the morality rate of patients also decreased significantly [1, 2]. However, the 5-year survival rate of CRC is still low owing to the metastasis and recurrence after operation. The most common route of metastasis of CRC is through lymph nodes, therefore, complete lymph nodes dissection and accurate assessment of lymph node metastasis in patients with CRC is crucial for the development of reasonable postoperative chemo-radiotherapy regimens and cycles, which can improve the prognosis and the five-year survival rate [3, 4].

For patients with rectal and sigmoid colon cancer, dissecting 253 lymph nodes and preserving the left colic artery are the essentials of radical surgery. In clinical work, some surgeons prefer to dissect lymph nodes by intrathecal dissection and they think lymph nodes could be dissected completely by this method. While, the other surgeons like to dissect lymph nodes by extracapsular dissection. They think their method could not only dissect lymph nodes completely but also ensure safety of patients. However,

up to now, there were no studies showing that whether intrathecal lymph nodes dissection is superior to extracapuslar. The aim of this study is to explore this problem.

Materials And Methods

We performed a retrospective clinical study between August, 2017 and October, 2019. The inclusion criteria were as follows: diagnosed as rectum or sigmoid colon adenocarcinoma by electronic colonoscopy and histopathology, 18-80 years of age, underwent radical resection. Exclusion criteria were received neoadjuvant therapy before surgery or combined with distant metastasis. The patients underwent intrathecal lymph nodes dissection between August, 2017 and August, 2018 were assigned in intrathecal group. The patients between September, 2018 and October, 2019 underwent extracapuslar lymph nodes dissection were assigned in extracapuslar group. For enrolled patients, we collected age, gender, diagnosis, operation, the number of lymph nodes harvested, the number of positive lymph nodes harvested, amount of bleeding, operation time, deputy injury and so on. All methods were carried out in accordance with relevant guidelines and regulations. This study was approved by the IRB of Nanjing Drum Tower Hospital, the affiliated hospital of Nanjing University Medical School. The written informed consent was obtained from all subjects.

Procedures

Participants in intrathecal group underwent radical operation. The vagina vasorum was excised completely when cleaning the 253 lymph nodes as in figure 1. The left colic artery was preserved in all patients. While in extracapuslar group, the vagina vasorum was preserved when cleaning the 253 lymph nodes as figure 2. All the operations were made by the same group of surgeons.

Outcome

We compare the two groups in curative effect and safety. The primary endpoints of curative effect are total number of lymph nodes, number of positive lymph nodes, and nodal staging. The primary endpoints of safety are amount of bleeding and operation time. The nodal staging is according to the guideline of Chinese Society of Clinical Oncology CSCO2019. Patients with no lymph node metastasis are regarded as N0, with one to three lymph nodes metastasis as N1, and with more than three lymph nodes metastasis as N2.

Statistical analysis

Data are presented as mean (±SD) for continue variables and as frequency (%) for categorical variables. For comparisons, we used two-tailed student *t* test to evaluate the continuous variables and the Chi-square test or Fisher's exact test for categorical variables. $P < 0.05$ was considered statistically significant. All statistical calculations were performed using SPSS software (version 19.0).

Results

Clinical characteristics of the patients

A total of 211 patients were recruited in this retrospective study and assigned as follows: 62 cases to the intrathecal group and 149 patients to extracapuslar group. The intrathecal group included 36 men and 26 women, ages ranging from 39 to 80 years, with mean age 61.6 years. Similarly, there were 92 men and 57 women in extracapuslar group, ages ranging from 23 years to 80 years, with mean age 64.2 years. The diagnoses of recruited patents were sigmoid cancer in 78 cases and rectal cancer in 133 cases. There were 21 cases with sigmoid cancer and 41 cases with rectal cancer in intrathecal group. The remaining 57 cases with sigmoid cancer and 92 cases with rectal cancer were classified into extracapuslar group. Of all these patients, 207 cases (98%) underwent laparoscopic surgery and the remaining 4 cases underwent open operation. All patients underwent radical resection with D3 lymph node dissection and preserving the left colic artery. The patients' clinicopathologic characteristics were shown in table1 and there were no statistic differences between the two groups.

The comparison of the primary endpoints between the two groups

The mean number of lymph nodes harvested from patients in intrathecal group was 16.2±6.2 (range from 5 to 31), which was higher than that in extracapuslar group (14.7±5.8, range from 3 to 40) without statistic difference (p=0.082). The mean number of positive lymph nodes got from patients in intrathecal group was 2.3±4.3 (range from 0 to25), which was also higher than that in extracapuslar group (1.5±2.9, range from 0 to 22) without statistic difference (p=0.097). However, the amount of bleeding in intrathecal group was significantly higher than that in extracapuslar group (p=0.000) and the operation time in intrathecal group was also significantly longer than that in extracapuslar group (p=0.000). All these details were summarized in table 2.

The comparison of nodal staging between the two groups

In intrathecal group, there were 30 patients proved to be N0, 22 patients to be N1, and 10 patients to be N2. Correspondingly, there were 89 patients to be N0, 45 patients to be N1, and 15 patients to be N2 in extracapuslar group. The constituent ratio of N0, N1, and N2 in the two groups showed no statistic difference (p=0.254). All these details were summarized in table 3.

Discussion

Lymph node metastasis is an important factor affecting postoperative local recurrence and 5-year survival rate of colorectal cancer, as well as an important basis for determining the operation mode of colorectal cancer [5, 6]. Complete lymph node dissection is an effective method to improve the cure rate of colorectal cancer. For patients with colorectal cancer, 253 lymph nodes should be removed completely to achieve D3 dissection [7, 8]. Previously, we severed the inferior mesenteric artery at the root to clean the 253 lymph nodes. Recently, to provide better blood supply at the anastomosis, we retain the left colic artery and then severed the inferior mesenteric artery, which improved the difficulty of dissecting 253

lymph nodes [9, 10]. Sometimes lymph nodes were left owing to the difficulty of the operation, especially for fat patients.

In actual clinical work, some surgeons prefer to dissect lymph nodes by intrathecal dissection. They think that the 253 lymph nodes could be cleaned completely by this method, specially lymph nodes behind the arteries. Besides, the surgical picture is very beautiful and has a high appreciation value. However, there was no published papers reporting this conclusion. Of course, there were disadvantages of this method, for example, stripping away the sheath of blood vessels may damage the vascular wall easily by the thermal damage of ultrasonic scalpel. In our study, there was one patient with rectal cancer underwent laparoscopic radical resection and the 253 lymph nodes were removed by intrathecal dissection. This patient present with anastomotic leakage and intra-abdominal bleeding after operation. Then he underwent a second operation, during which a defect was found in the inferior mesenteric artery. This patient died owing to hemorrhagic shock. The reason may be that there was vascular wall injury by ultrasonic scalpel and intestinal fluid eroded vascular wall following anastomotic leakage, resulting in vascular wall damage and bleeding.

Some other surgeons prefer to dissect lymph nodes by extracapuslar dissection, also named choroidal cleaning. This method is relatively safe as it retains the vascular sheath. These surgeons argue that this method could also clean the 253 lymph nodes completely. Up to now, there was no study to compare the results of these two methods.

As we known, our study is the first one to compare the curative effect and safety of these two methods. Our study showed that there were no statistic differences in the mean number of lymph nodes and positive lymph nodes harvested from the patients between the two groups. Besides, there was also no statistic differences in the nodal staging between the two groups. Therefore, we could conclude that dissecting lymph nodes by extracapuslar dissection had a similar curative effect compared to intrathecal dissection. However, the amount of bleeding in intrathecal group was significantly higher than that in extracapuslar group and the operation time in intrathecal group was also significantly longer. As a result, it was more traumatic to dissect lymph nodes by extracapuslar dissection than intrathecal dissection.

Conclusion

For patients with rectal and sigmoid colon cancer, dissecting lymph nodes by intrathecal dissection does not improve the curative effect compared to extracapuslar dissection. However, the amount of bleeding and operation time in intrathecal group are more than those in extracapuslar group. So dissecting lymph nodes by extracapuslar dissection is preferred in radical resection of patients with rectal and sigmoid colon cancer.

Declarations

Funding statement

This paper was funded by National natural science foundation of China (021414380047)

Competing interests

The authors declare that they have no competing interests.

Ethics approval

This study was approved by the IRB of Nanjing Drum Tower Hospital, the affiliated hospital of Nanjing University Medical School.

Consent to participate

We thank the patients for giving us written consent for publishing their details.

References

1. Tang, J. W. C. *et al.* Dietary changes adopted by Chinese colorectal cancer patients: A qualitative study. *Eur J Cancer Care (Engl).***30**, e13159 (2019).
2. Wieldraaijer, T. *et al.* Introducing a time out consultation with the general practitioner between diagnosis and start of colorectal cancer treatment: Patient-reported outcomes. *Eur J Cancer Care (Engl).***30**, e13141 (2019).
3. Betge, J. *et al.* Lymph node retrieval in colorectal cancer: determining factors and prognostic significance. *Int J Colorectal Dis.***32** (7), 991–998 (2017).
4. Balducci, G. *et al.* Lymph node assessment in colorectal cancer surgery: laparoscopic versus open techniques. *G Chir.***38** (1), 23 (2017).
5. Miyachi, H. *et al.* Tumor location and patient sex are novel risk factors of lymph node metastasis in T1 colorectal cancer. *J Gastroenterol Hepatol.*https://doi.org/10.1111/jgh.15242 (2020).
6. Wang Liming, H. *et al.* Prognostic Utility of Apical Lymph Node Metastasis in Patients with Left-sided Colorectal Cancer. *In Vivo.***34**, 2981–2989 (2020).
7. Newland, R. C. *et al.* Relative effects of direct spread, lymph node metastasis and venous invasion in relation to blood borne distant metastasis present at the time of resection of colorectal cancer. *Pathology.***52**, 649–656 (2020).
8. Law, B. Z. Y. *et al.* Does adding lateral pelvic lymph node dissection to neoadjuvant chemotherapy improve outcomes in low rectal cancer? *Int J Colorectal Dis.***35**, 1387–1395 (2020).
9. Singh Dujanand, L. *et al.* The long-term survival benefits of high and low ligation of inferior mesenteric artery in colorectal cancer surgery: A review and meta-analysis. *Med. (Baltim).***96**, e8520 (2017).
10. Chun-Dong, F. Y. C. N. F. L. Z. *et al.* Preservation versus non-preservation of left colic artery in sigmoid and rectal cancer surgery: A meta-analysis. *Int J Surg.***52**, 269–277 (2018).

Tables

Table 1. The clinical characteristics of the patients stratified by groups

	Intrathecal group	Extracapuslar group	t/Chi-square value	*p* value
Age mean years	61.6±10.6	64.2±11.9	-1.475	0.142
Gender			0.249	0.645
Male	36	92		
Female	26	57		
Diagnosis			0.361	0.639
Sigmoid cancer	21	57		
Rectal cancer	41	92		
Hypertension	6	17	0.135	0.713
Diabetes	4	11	0.057	0.811
Operation			0.56	0.323
Laparoscopy	62	145		
Laparotomy	0	4		
Tumor size	3.25±1.12	3.55±1.40	-1.497	0.136
TNM stage			0.552	0.907
I	8	20		
II	20	50		
III	28	69		
IV	6	10		
Anastomotic leak	3	5	0.264	0.695
Hospital stay	7.9±2.0	8.1±2.5	-0.59	0.556

Table 2. The comparison of the primary endpoints between the two groups

	Intrathecal group	Extracapuslar group	t value	*p* value
Total number of lymph nodes	16.2±6.2	14.7±5.8	-1.748	0.082
Number of positive lymph nodes	2.3±4.3	1.5±2.9	-1.67	0.097
Amount of bleeding	179.8±227.4	101.7±56.4	-3.927	0.000
Operation time	251.8±71.4	211.4±55.3	-4.427	0.000

Table 3 The comparison of nodal staging between the two groups

Nodal staging	Intrathecal group	Extracapuslar group	Chi-square value	*p* value
N0	30	89	2.742	0.254
N1	22	45		
N2	10	15		

Figures

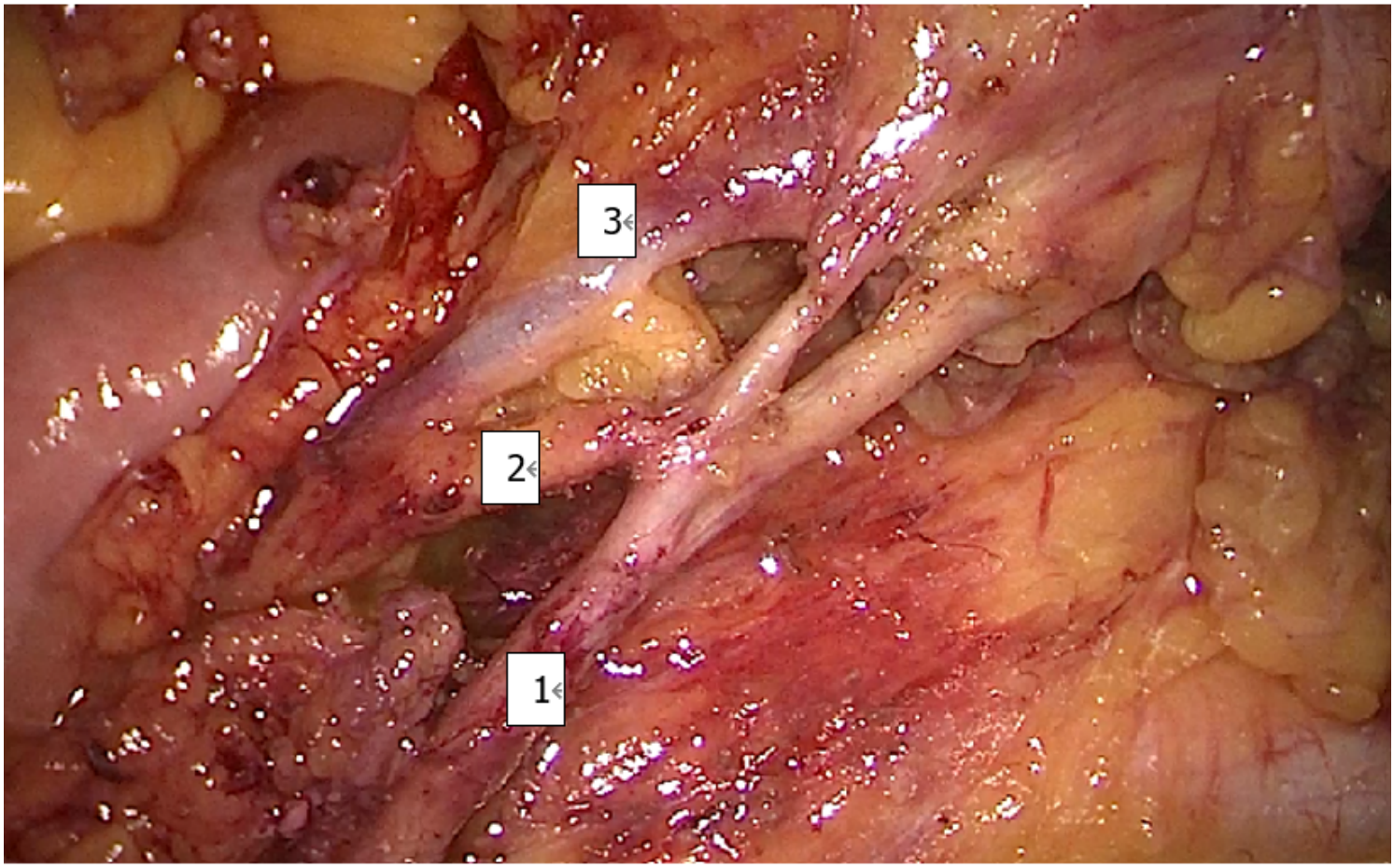

Figure 1

The vagina vasorum was excised completely when cleaning the 253 lymph nodes (1: inferior mesenteric artery; 2: left colonic artery; 3: inferior mesenteric vein)

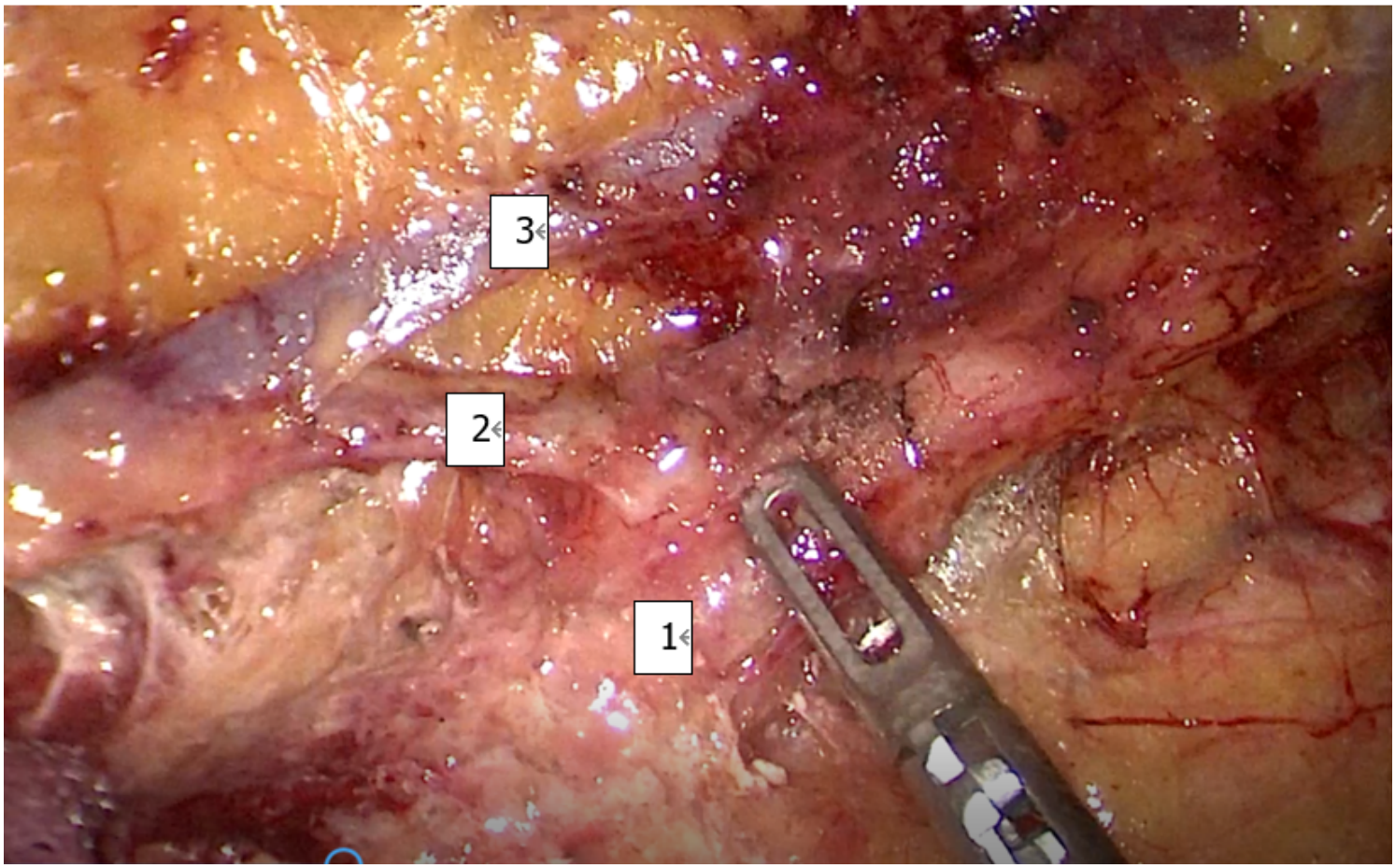

Figure 2

The vagina vasorum was preserved when cleaning the 253 lymph nodes (1: inferior mesenteric artery; 2: left colonic artery; 3: inferior mesenteric vein)