A newly revised pivot knee prosthesis for peri-knee malignant bone destruction tumor management

jie tan
Sichuan University West China Hospital https://orcid.org/0000-0003-2498-8642
Qingyi Zhang
Sichuan University West China Hospital
Wu Wu
Sichuan University West China Hospital
Yaxing Li
Sichuan University West China Hospital
Kai Huang
Sichuan University West China Hospital
Lin Wang
Chendu first affiliated hospital school of nursing
Yong Rao
The Affiliated Hospital of Southwest Medical University
Yue Zhang
The Affiliated Hospital of Southwest Medical University
Hao Xue
Southwest Medical University
Longfei Zou
Southwest Medical University
Shuling Zheng
Southwest Medical University
Zhi Wang
The Affiliated Hospital of Southwest Medical University
Huiqi Xie (xiehuiqi@scu.edu.cn)

Research article

Keywords: malignant bone tumor, newly revised pivot knee prosthesis, knee arthroplasty, outcome research

Posted Date: May 7th, 2020

DOI: https://doi.org/10.21203/rs.3.rs-24068/v1

Abstract

Background

This study evaluated the effectiveness of a newly revised pivot knee prosthesis in patients with peri-knee malignant bone destruction tumors.

Methods

Medical records of patients who were admitted to our hospital from January 2014 to February 2020 and underwent the newly revised pivot knee prosthesis operations were retrospectively collected and analyzed. Visual analogue scale (VAS), hospital special surgery (HSS) knee score, American knee society knee score (KSS), and ROM for pre-operation, discharge, and last follow-up were applied to assess the effectiveness of this surgery. Meanwhile, the results of musculoskeletal tumor society system (MTSS) and radiographs were observed and analyzed at last follow-up.

Results

The average operation time was 174.0 ± 35.5 min, and intraoperative bleeding volume was 271.2 ± 127.3 ml. The follow-up time was 33.8 ± 14.9 months. The scores of VAS, HSS, and KSS at pre-operation, discharging, and last follow-up were all comparable (p 0.05), ROM was only comparable between discharging and last follow-up (p 0.05), while ROM between preoperative and discharging had no significance (p 0.05). MTSS at last follow-up was22.6 ± 2.4. All patients were alive with their prosthesis in good condition except for one patient who underwent revision surgery for misalignment of prosthesis and two patients who died of systemic metastasis.

Conclusion

The newly revised pivot knee prosthesis is a good alternative limb-salvage strategy for patients who suffered from bone destruction tumors, although patient tumor stage and health condition should be fully assessed before surgery to reduce the mortality rate of patients who are not eligible.

Background

Bone destruction due to malignant tumor around the knees is very common in the clinical setting [1]. Malignant tumors that may cause bone destruction such as osteosarcoma, chondrosarcoma, Ewing sarcoma, and osteoclastoma [2–5] are generally intractable and difficult to treat because of their malignancy and metastatic nature. Previously, amputation was generally the only available method for treating malignant limb bone tumor to save people’s life. However, amputation surgery may bring a series of inconveniencies and lower quality of life post-surgery [1]. Recently, the increasing demand for retaining a good quality of life makes amputation no longer an optimal option. With technological development and improved understanding of bone tumor, prosthesis arthroplasty coupled with pre- and post-operational chemotherapies could serve as an alternative limb-salvage method for bone tumor patients

and there has already been some clinical progress in this regard [6, 7]. There are many types of bone tumor prostheses such as single-axis hinged prosthesis [8], rotating hinged prosthesis [9], condyle constrained prosthesis [10], and a newly revised pivot knee prosthesis developed by Beijing Chunlizhengda Medical Equipment Co., LTD; each prosthesis has its merits and deficiencies. Hence, we studied the outcomes of patients admitted to our hospital from January 2014 to February 2020 who underwent the newly revised pivot knee prosthesis operations.

Methods

In this study, patients who were admitted to our hospital from January 2014 to February 2020 and underwent the newly revised pivot knee prosthesis operations were retrospectively collected as protocols set. Inclusion criteria were: 1)peri-knee bone destruction and pathology manifested as malignant tumor, 2) no lymphatic and systemic metastases, 3) no disease in other organs, and 4) willingness to provide informed consent. Exclusion criteria were: 1) benign type tumor that can be cured by methods other than bone tumor arthroplasty, 2) lymphatic and systemic metastases and not healthy enough to undergo surgery, 3) ineligible for surgery because of important vessel and nerve invasion, and 4) data not fully available and patients lost to follow-up.

All surgeries were performed by the same surgeon. Imaging data of patients before operation were collected and the length and extent of osteotomy were determined and the dimension size of tumor prosthesis were confirmed, then the data were sent to Beijing Chunlizhengda Medical Equipment Co., LTD for custom tumor prosthesis design (newly revised pivot knee prosthesis, patent NO. CN200910088381.2). Patients staged Enneking B underwent chemotherapy to shrink the tumor into the tumor capsular, to make tumor resection more radical. Surgical protocols for osteosarcoma arthroplasty in upper segment of tibia were as follows: patient laid in supine position after anesthesia was administered and tourniquet was also applied to prevent excessive bleeding; patient was disinfected with povidone-iodine. A curved skin incision approximately 20 cm was made upon the medial knee, subcutaneous tissue, and fascia. The muscles were dissected by layers, and after the bone tumor was exposed, the vessels around the tumor were meticulously separated and ligated, then the upper tibia at the proper location as planned before operation was amputated carefully and the whole tumor tissue were radically resected. If soft tissue and skin upon the tumor were invaded, all the affected tissues should be removed. Then femur side was exposed, and cartilage layers were resurfaced, flexing the knee in 90°. Navigation systems of the femur were installed, and osteotomy of the distal femur was performed. The surface of distal femur was trimmed, and the medullary space was expanded to proper dimension. After extra-medullary navigation on tibia was installed, resurfacing the residual proximal tibia and expansion tibia medullary space to proper size was also done. Subsequently, the operation area was flushed with a large amount of povidone-iodine and 0.9% saline water. The prostheses on the tibia and femur were installed successively. Thereafter, excess bone cement was cleaned, and the spacer was inserted, followed by checking the range of motion (ROM) and stability of the prosthesis after knee reduction. Lastly, after the tourniquet was released, bleeding vessels were cauterized, and the operation area was irrigated again, residual tendons around the knee were repaired completely, closing the incision

site with interrupted suture and wrapping the knee with elastic bandage after plasma drainage tube had been placed. All the bone tumor tissues sampled during surgery were sent for subsequent pathology examination.

All patients received antibiotic therapy after operation, and quadriceps femoris exercises were initiated after plasma drainage tube was removed, patients could actively move the knee joint 1 week after surgery except in situations in which knee tendon reconstructions were performed; in such casestheir functional exercises were delayed to 3 weeks postoperatively. Meanwhile, oncology department counseling was also prescribed to determine the postoperative chemotherapy time and program based on the tumor stages and classifications.

Patients' demographic data such as age, sex, onset time, BMI, follow-up time, tumor type, and Enneking stage were recorded and calculated. The hospital special surgery (HSS)[11], American knee society knee score (KSS)[12] and Visual analogue scale (VAS)[13], and ROM at pre-operation, discharging, and last follow-up were recorded and analyzed. Musculoskeletal tumor society system (MTSS)[14] scores were also observed, and the MTSS scoring system composed of six parts: pain, limb function, satisfaction degree, brace support, walking and gait, every part had 5 points, totaling to a score of 30. This scoring system could also be adapted as percentile for comparison.

Statistical analysis

All statistical data were calculated and analyzed by IBM SPSS statistical software version 20.0 (IBM Corporation, Armonk, New York, USA). Continuous demographical variables were presented as mean ± standard deviation, categorical variables were presented as number (percentile), differences within groups in VAS, HSS, KSS, and ROM at pre-operation, discharging, and last follow-up were statistically analyzed by Wilcoxon signed-rank test. The p value less than 0.05 was considered to have statistical significance.

Results

Twenty-one cases of newly revised pivot knee prosthesis surgery were enrolled in this study, among which two patients died of systemic metastasis, two failed for prosthesis loosening and fracture and underwent revision surgery, no one got infection. All 21 cases were included for subsequent comparison and analysis. There were twelve men and nine women, and their average age at operation was 45.1 ± 15.5 years, disease time onset was 3.7 ± 1.9 months, follow-up time was 33.8 ± 14.9 months. The general demographic data were summarized in Table 1, and the detailed information on the 21 patients are shown in Table 2.

Table 1
Demographic characteristics (n = 21 patients)

Patients demographics	Mean ± SD or n(%)
Age at surgery, year	45.1 ± 15.5
Sex, male	12 (57.1%)
Disease time, month	3.7 ± 1.9
Follow-up time, month	33.8 ± 14.9
Operation time, min	174.0 ± 35.5
Bleeding volume, ml	271.2 ± 127.3
BMI, kg/m^2	23.8 ± 3.1
BMI, body mass index; SD, standard deviation	

Table 2
Demographical information in detail (n = 21 patients)

Case NO.	Age, year	Sex	Follow-up time, month	Tumor type	BMI	Enneking stage	outcome	Involved part
1	17	male	3	osteoclastoma	25	□A	alive	distal femur
2	32	male	12	osteoclastoma	23	□A	alive	proximal tibia
3	52	male	24	chondrosarcoma	19	□B	alive	distal femur
4	69	female	46	Ewing sarcoma	28	□B	alive	proximal tibia
5	42	female	22	chondrosarcoma	22	□B	alive	distal femur
6	33	female	62	osteoclastoma	25	□B	fracture	distal femur
7	60	male	5	osteosarcoma	20	□A	alive	proximal tibia
8	26	female	12	leiomyosarcoma	30	□B	alive	distal femur
9	66	male	33	osteoclastoma	25	□B	alive	proximal tibia
10	59	male	28	osteosarcoma	22	□B	alive	distal femur
11	23	male	34	osteosarcoma	22	□B	dead	distal femur
12	34	female	23	leiomyosarcoma	24	□A	alive	proximal tibia
13	35	male	45	osteosarcoma	26	□A	alive	proximal tibia
14	37	male	35	chondrosarcoma	28	□A	losening	distal femur
15	48	female	46	osteosarcoma	25	□B	alive	proximal tibia
16	64	female	36	osteosarcoma	27	□B	alive	distal femur

BMI, body mass index

Case NO.	Age, year	Sex	Follow-up time, month	Tumor type	BMI	Enneking stage	outcome	Involved part
17	56	male	37	osteosarcoma	27	□B	dead	proximal tibia
18	58	female	42	Ewing sarcoma	19	□A	alive	distal femur
19	62	male	44	osteosarcoma	25	□A	alive	proximal tibia
20	41	male	46	osteosarcoma	23	□A	alive	distal femur
21	34	female	49	osteosarcoma	24	□B	alive	distal femur
BMI, body mass index								

Typical case was a 48 year old male, with bone destruction, and cyst-like changes on distal femur found in X-ray in Fig. 1. Subsequent MRI also further confirmed the bone destruction and cyst-like changes, with typical sarcoma hyperplasia, although restricted in the chamber of the distal femur (Fig. 2). After surgery, the follow-up radiographs taken at 1 month and the last follow-up (4 years) suggested that the prosthesis was in good condition with no obvious position moving or loosening (Figs. 3 and 4).

VAS, HSS, and KSS scores at each time point were also statistically improved when compared with scores at preoperative time point, which were 7.0 ± 1.5 vs 2.9 ± 0.9 vs 2.1 ± 0.7, p□0.05 for VAS, 45.0 ± 7.7 vs 64.5 ± 6.1 vs 75.1 ± 5.9, p□0.05 for HSS, and 44.9 ± 9.1 vs 66.5 ± 4.7 vs 75.4 ± 4.6, p□0.05 for KSS, respectively. ROM was only comparable between discharging and last follow-up (53.8 ± 27.0 vs 67.2 ± 26.0, p□0.05), while ROM between preoperative and discharging had no significance (p□0.05)(Table 3, Fig. 5-**Figure8**). MTSS scores at last follow-up were 22.6 ± 2.4 in this case series which also demonstrated knee joint in good condition.

Table 3
comparison of VAS, HSS and KSS scores at preoperative, discharging and last follow-up time point

	VAS	HSS	KSS	ROM
Preoperative	7.0 ± 1.5	45.0 ± 7.7	44.9 ± 9.1	61.6 ± 22.5
Discharging	2.9 ± 0.9 [a]	64.5 ± 6.1[a]	66.5 ± 4.7[a]	53.8 ± 27.0[c]
Last follow-up	2.1 ± 0.7[ab]	75.1 ± 5.9[ab]	75.4 ± 4.6[ab]	67.2 ± 26.0[bc]
VAS, Visual analogue scale ; HSS, The hospital special surgery; KSS, American knee society knee score; a, vs preoperative time point, p□0.05; b, vs discharging time point, p□0.05; c, vs preoperative time point, p□0.05				

Discussion

Malignant bone carcinomas are uncommon clinically, although their malignancy and high metastatic potential can be life-threating. Thus, radically removing the invasion area has been agreed upon as the best treatment option [1, 15, 16]. Amputation can completely remove all tumor tissue and radically prevent tumor relapse; however, this method can also bring patients and their relatives heavy postoperative fiscal and life burdens, which may reduce quality of life [17]. Technological development and improved understanding of the mechanism of carcinoma progression, together with improved staging and classification of the carcinoma could make some important impacts on treatment and prognosis. Presently, radically removing the tumor [4], bone grafting [18], and prosthesis arthroplasty [3, 19] coupled with preoperative and postoperative chemotherapy [7] have all established advantages, although deficiencies exist in each method. One of the merits of this newly revised pivot knee prosthesis is that it could preserve the knee joint function, which may make the patient live more conveniently and confidently.

The principles for this newly revised pivot knee prosthesis arthroplasty are patient Enneking stage classified as equal or below ⅡB, with good topical condition, no metastasis and no important vessels or nerves involved [1, 3]. A small number of patients who have heavy bone destruction of benign tumors or who have distant metastasis but are in good and healthy condition could also choose this strategy to improve their quality of life and limb functions despite reports of rare cases. Tumor prosthesis arthroplasty has huge advantages in improving patient's postoperative life quality, allowing patients to move freely and reducing fiscal burden substantially when compared to amputation.

Presently, bone tumor prostheses of knee have three types: 1)single-axis hinged prosthesis [8], 2)rotating hinged prosthesis [9, 20], and 3) this newly revised pivot knee prosthesis. Single-axis type has restricted movement only in sagittal plane, so rotating movements are not afforded, which makes its application limited. Partially the same structures as in singe-axis hinged prosthesis, rotating hinged ones also have hinge locking system; however, it endows some movements both in sagittal and rotating, high molecular polyethylene spacer between tibia and femur is also more biologically adapted to biomechanics of the knee. Moreover, components in both single-axis hinged prosthesis or rotating hinged prosthesis are metallic, not bionic structure. Thus, heavy metal gravity may lead the prosthesis to collapse and further failure. Meanwhile, gravity in these designs is mostly focused on the hinge structure, so strain and shear force may concentrate and distribute all on the hinge which could contribute to subsequent tumor prosthesis loosening, displacement, and infection [21]. In this new design, the newly revised pivot knee prosthesis has replaced the traditional hinge structure with new "T" pivot component which could confer this new prosthesis free sagittal and rotating movement. Meanwhile, the polyethylene spacer on tibia plateau and sleeve on distal femur are also new gadgets to acquire large contacting area between patients' knee joint which could diffuse the shear and strain force from femur and make this design more bionic to sustain stability.

Some surgical techniques also need our attention as tendon and muscle structures around the knee are complicated, which could make this surgery very demanding. In this study, tumor tissue may inevitably invade some soft tissues, such as tendons and muscles. Thus, partial resection of the tendons and muscles of adductor magnus and gastrocnemius in distal femur tumor and semitendinosus, semimembranosus, and patellar tendon in proximal tibia is possible during surgery, although these structures are crucial in maintaining the knee function. Hence, carefully reconstructing these components is extremely necessary.

Preoperative and postoperative chemotherapy are very valuable in managing malignant bone tumor, too. Preoperative chemotherapy can kill tumor cells effectively and shrink tumor size, which may provide a favorable environment for subsequent surgical intervention, especially for some carcinomas which are sensitive to chemotherapy, such as Ewing sarcoma and osteosarcoma[2, 22]. Postoperative chemotherapy also has its benefits such as its reported improving of the 5-year survival rate [7]. Recently, as biological technology has evolved, targeted therapy becomes possible and has already made some achievements [23, 24]. Rutkowski et al. [25] found Denosumab had excellent therapeutic effect in patients whose surgery intervention were not suitable at present time and could create favorable environment for later surgery. Some certain cytokines and proteins were also found to be valuable in improving the prognosis of some musculoskeletal carcinomas[5]. In our study, there were two patients who died of tumor relapse and metastasis. The Enneking stages were all in stage B, all were osteosarcomas, the death time was 3 and 6 months after surgery, respectively, and the cause of death was irregular chemotherapy. Therefore, chemotherapies in pre- and post-operation are very beneficial which should not be ignored.

Limitation

In this study, the sample size was small as we only included 10 cases, which may cause some statistical biases. Moreover, we only statistically compared the VAS, HSS, and KSS scores at preoperative, discharging, and last follow-up time points with Wilcoxon signed-rank test, making this study a self-control research, thus lacking comparison with other types of tumor prostheses. Additionally, other prostheses in our hospital were also insufficient, even lacking for cohort study. The ROMs of the knee varied largely because the reconstruction programs were different in each patient, which ultimately made the ROM comparison partly unreliable. The bone tumors in this article also partially vary which may bring some statistical inconsistencies to the outcome comparisons. Further, the last the follow-up time is different and insufficient for observing the long-term results of the prostheses. Therefore, more samples and a longer follow-up are needed in a future study.

Conclusion

This newly revised pivot knee prosthesis is a good alternative limb-salvage strategy for patients who suffer from bone destruction tumors. The scores of VAS, HSS, and KSS improved significantly at discharging and last follow-up when compared with scores before surgery. Patients’ tumor stages and

health conditions should be fully assessed before this surgery is performed to reduce the mortality rate of patients who are not the right candidates.

Abbreviations

HSS, hospital special surgery; KSS, knee society score; MTSS, musculoskeletal tumor society system; ROM, range of motion; VAS, visual analogue scale

Declarations

Ethics approval and consent to participate

The Ethics Committee of West China Hospital have approved this study. Informed consent was obtained from all patients participated in this research.

Consent for publication

All patients have signed an institutional consent for publication of all their clinic materials for scientific research study, and all the author have agreed to publish this article.

Availability of data and materials

The datasets used in this study are available from the corresponding author on reasonable request.

Competing interests

There is not competing interests in this article

Funding

This work was supported by funding from the Science and Technology Department in Sichuan Province (No. 2017FZ0045).

Authors' contributions

Dr. Jie Tan and Qingyi Zhang were the first authors and were responsible for manuscript writing; Dr. Huiqi Xie and Zhi Wang were the corresponding authors and were responsible for conceiving, reviewing and finalizing this article; Dr. Wu Wu, Yaxing Li, and Kai Huang were responsible for patients follow-up and

data collections; Dr. Lin Wang, Yue Zhang, and Yong Rao were responsible for statistical analyses; Dr. Hao Xue, Longfei Zou, and Shuling Zheng were responsible for patients radiographs collections.

Acknowledgements

We sincerely thank all the patients participated and all the workmates involved in our study.

References

1. Guo W. Limb-salvage treatment of malignant pelvic bone tumor in China for past 20 years[J]. Chin Med J (Engl). 2019;132(24):2994–7.
2. Gill KS, Fernandes P, Bird B, et al. Combination of electroporation delivered metabolic modulators with low-dose chemotherapy in osteosarcoma[J]. Oncotarget. 2018;9(59):31473–89.
3. Ma XL, Wang DB, Ma JX, et al. Custom-made Prosthesis for Reconstruction after Radical Resection for Chondrosarcoma of Manubrium[J]. Orthop Surg. 2018;10(3):272–5.
4. Jamshidi K, Bahrabadi M, Bagherifard A, et al. Surgical treatment outcome of giant cell tumor of distal ulna: En bloc resection vs. curettage and bone graft[J]. Med J Islam Repub Iran. 2018;32:44.
5. Morii T, Tajima T, Aoyagi T, et al. D-dimer Level Changes During Systemic Chemotherapy Can Predict Prognosis of High-grade Musculoskeletal Sarcoma Patients[J]. Anticancer Res. 2015;35(12):6781–6.
6. Luo W, Huang L, Liu H, et al. Customized Knee Prosthesis in Treatment of Giant Cell Tumors of the Proximal Tibia: Application of 3-Dimensional Printing Technology in Surgical Design[J]. Med Sci Monit. 2017;23:1691–700.
7. Zhang Y, He Z, Duan Y, et al. Does intensified chemotherapy increase survival outcomes of osteosarcoma patients? A meta-analysis[J]. J Bone Oncol. 2018;12:54–60.
8. Yasunaga Y, Goto T, Hisatome T, et al. Bone-preserving prosthesis with a single axis for treating osteonecrosis of the femoral head: midterm results for the thrust plate hip prosthesis[J]. J Orthop Sci. 2003;8(6):818–22.
9. Abdulkarim A, Keane A, Hu SY, et al. Rotating-hinge knee prosthesis as a viable option in primary surgery: Literature review & meta-analysis[J]. Orthop Traumatol Surg Res. 2019;105(7):1351–9.
10. Lim JBT, Pang HN, Tay KJD, et al. Increased constraint of rotating hinge knee prosthesis is associated with poorer clinical outcomes as compared to constrained condylar knee prosthesis in total knee arthroplasty[J]. Eur J Orthop Surg Traumatol, 2019.
11. Narin S, Unver B, Bakirhan S, et al. Cross-cultural adaptation, reliability and validity of the Turkish version of the Hospital for Special Surgery (HSS) Knee Score[J]. Acta Orthop Traumatol Turc. 2014;48(3):241–8.
12. Silva AL, Demange MK, Gobbi RG, et al. Translation and Validation of the Knee Society Score - KSS for Brazilian Portuguese[J]. Acta Ortop Bras. 2012;20(1):25–30.

13. Dannenbaum E, Chilingarian G, Fung J. Validity and Responsiveness of the Visual Vertigo Analogue Scale[J]. J Neurol Phys Ther. 2019;43(2):117–21.
14. Albergo JI, Gaston CL, Aponte-Tinao LA, et al. Proximal Tibia Reconstruction After Bone Tumor Resection: Are Survivorship and Outcomes of Endoprosthetic Replacement and Osteoarticular Allograft Similar?[J]. Clin Orthop Relat Res. 2017;475(3):676–82.
15. Chalopin A, Tellez-Gabriel M, Brown HK, et al. Isolation of circulating tumor cells in a preclinical model of osteosarcoma: Effect of chemotherapy[J]. J Bone Oncol. 2018;12:83–90.
16. Liu T, Zhang X, Zhang Q, et al. Total femoral reconstruction with custom prosthesis for osteosarcoma[J]. World J Surg Oncol. 2016;14:93.
17. Punyaratabandhu T, Lohwongwatana B, Puncreobutr C, et al. A Patient-Matched Entire First Metacarpal Prosthesis in Treatment of Giant Cell Tumor of Bone[J]. Case Rep Orthop, 2017, 2017: 4101346.
18. Mihara A, Muramatsu K, Hashimoto T, et al. Combination of Extracorporeally-irradiated Autograft and Vascularized Bone Graft for Reconstruction of Malignant Musculoskeletal Tumor[J]. Anticancer Res. 2020;40(3):1637–43.
19. Lu H, Shen H, Chen Q, et al. Artificial finger joint replacement due to a giant cell tumor of the tendon sheath with bone destruction: A case report[J]. Oncol Lett. 2015;10(6):3502–4.
20. Wang CS, Wu PK, Chen CF, et al. Bone-prosthesis composite with rotating hinged-knee prosthesis in limb salvage surgery for high-grade sarcoma around the knee[J]. J Arthroplasty. 2015;30(1):90–4.
21. Biswas D, Haughom B, Mayle RE Jr, et al. Case report: Failure of rotating-hinge total knee prosthesis by disengagement of the hinge-post extension[J]. Clin Orthop Relat Res. 2013;471(4):1389–92.
22. Kawai A. Musculoskeletal Tumor Adjuvant Chemotherapy for Malignant Bone and Soft Tissue Tumors[J]. Gan To Kagaku Ryoho. 2018;45(3):428–9.
23. Agarwal A, Larsen BT, Buadu LD, et al. Denosumab chemotherapy for recurrent giant-cell tumor of bone: a case report of neoadjuvant use enabling complete surgical resection[J]. Case Rep Oncol Med, 2013, 2013: 496351.
24. Fabris S, Maclean DA. Doxorubicin chemotherapy affects the intracellular and interstitial free amino acid pools in skeletal muscle[J]. PLoS One. 2018;13(4):e0195330.
25. Rutkowski P, Gaston L, Borkowska A, et al. Denosumab treatment of inoperable or locally advanced giant cell tumor of bone - Multicenter analysis outside clinical trial[J]. Eur J Surg Oncol. 2018;44(9):1384–90.

Figures

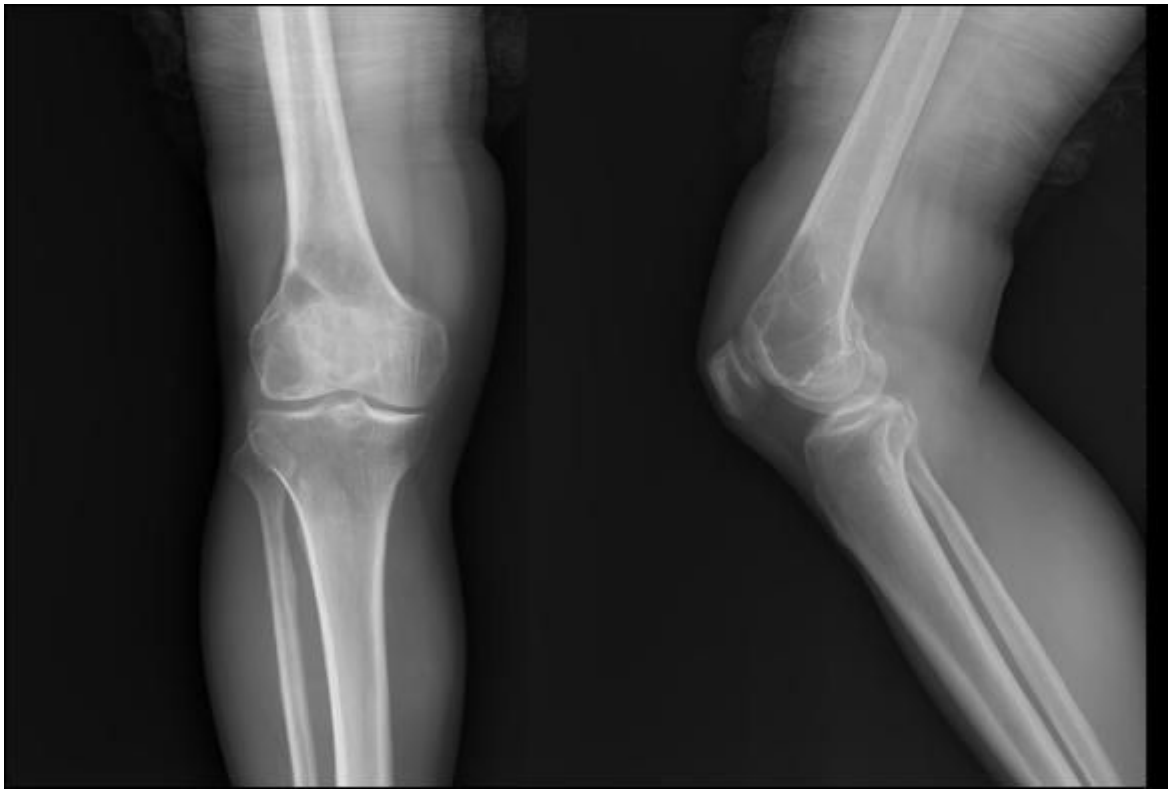

Figure 1

Bone destruction and cyst-like changes on distal femur were found in X-ray

Figure 2

MRI further confirmed the bone destruction and cyst-like changes, with typical sarcoma hyperplasia but restricted in the chamber of distal femur

Figure 3

Tumor prosthesis in favorable alignment and good condition in 1 month

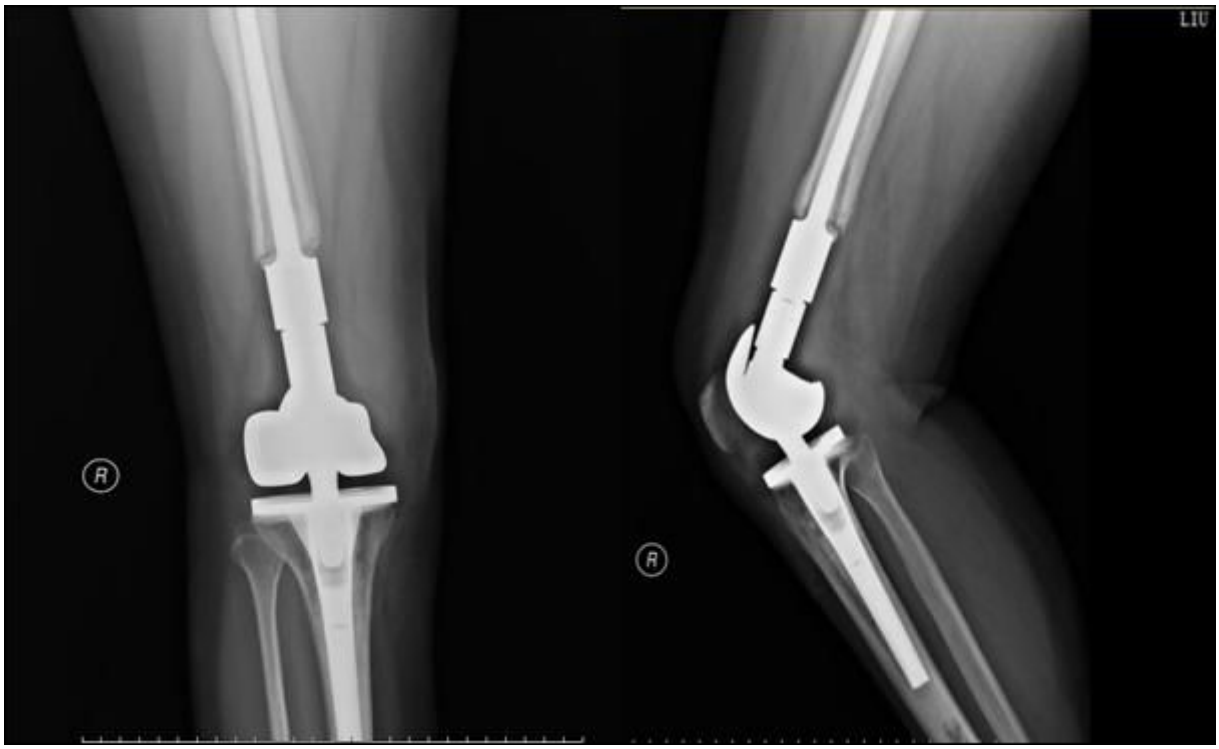

Figure 4

Tumor prosthesis in good condition with no obvious moving and loosening after 4 year

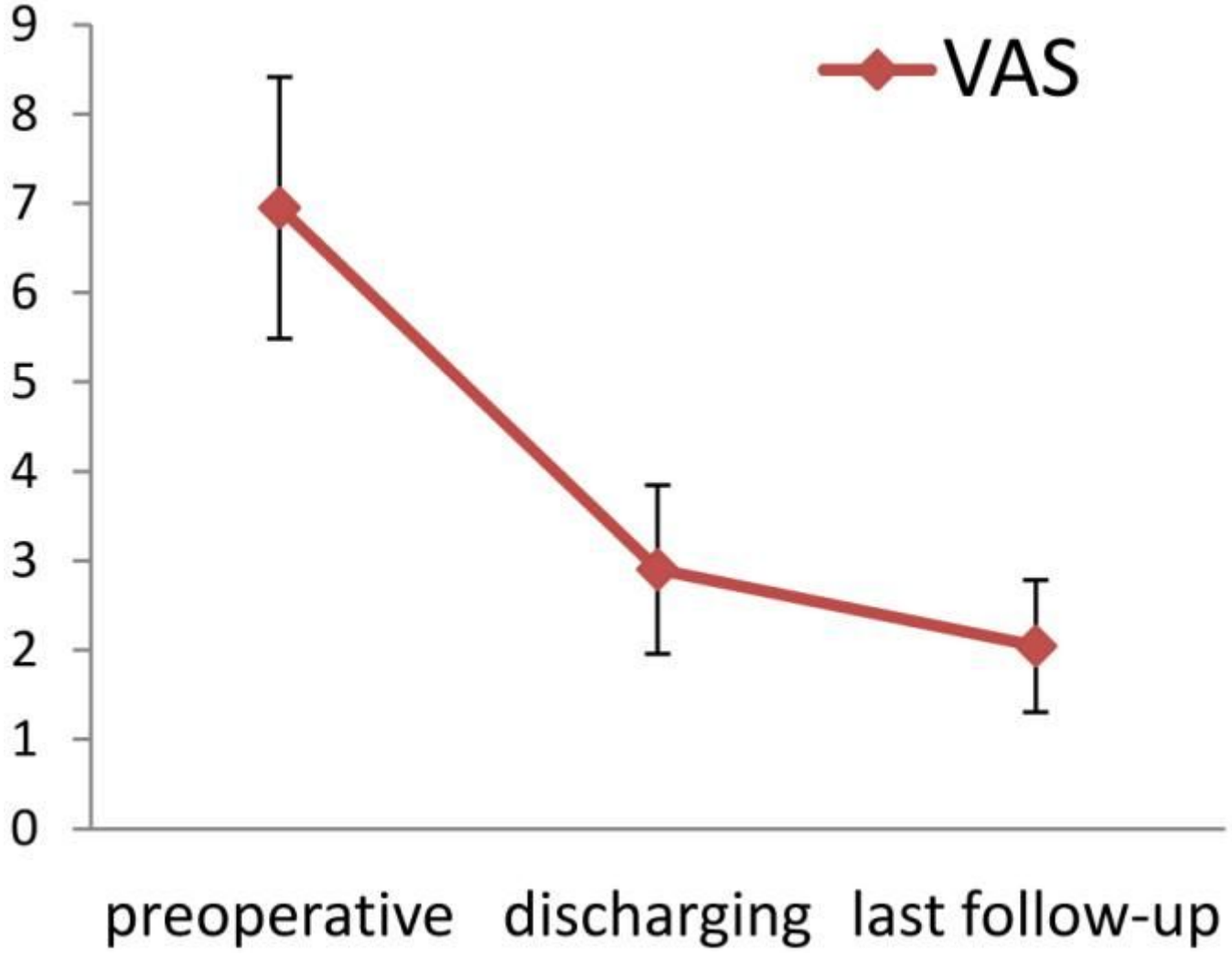

Figure 5

VAS score at different time point within group

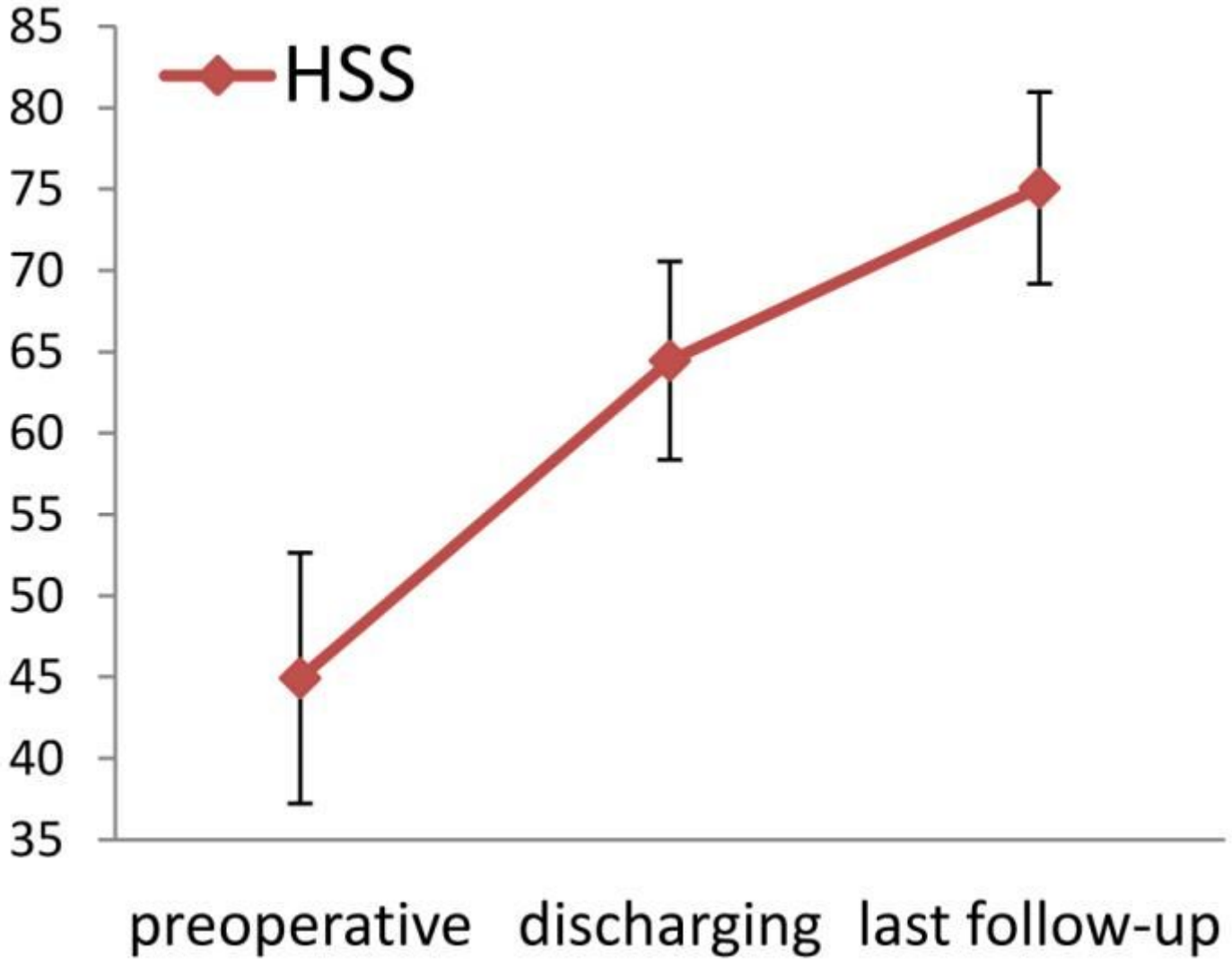

Figure 6

HSS score at different time point within group

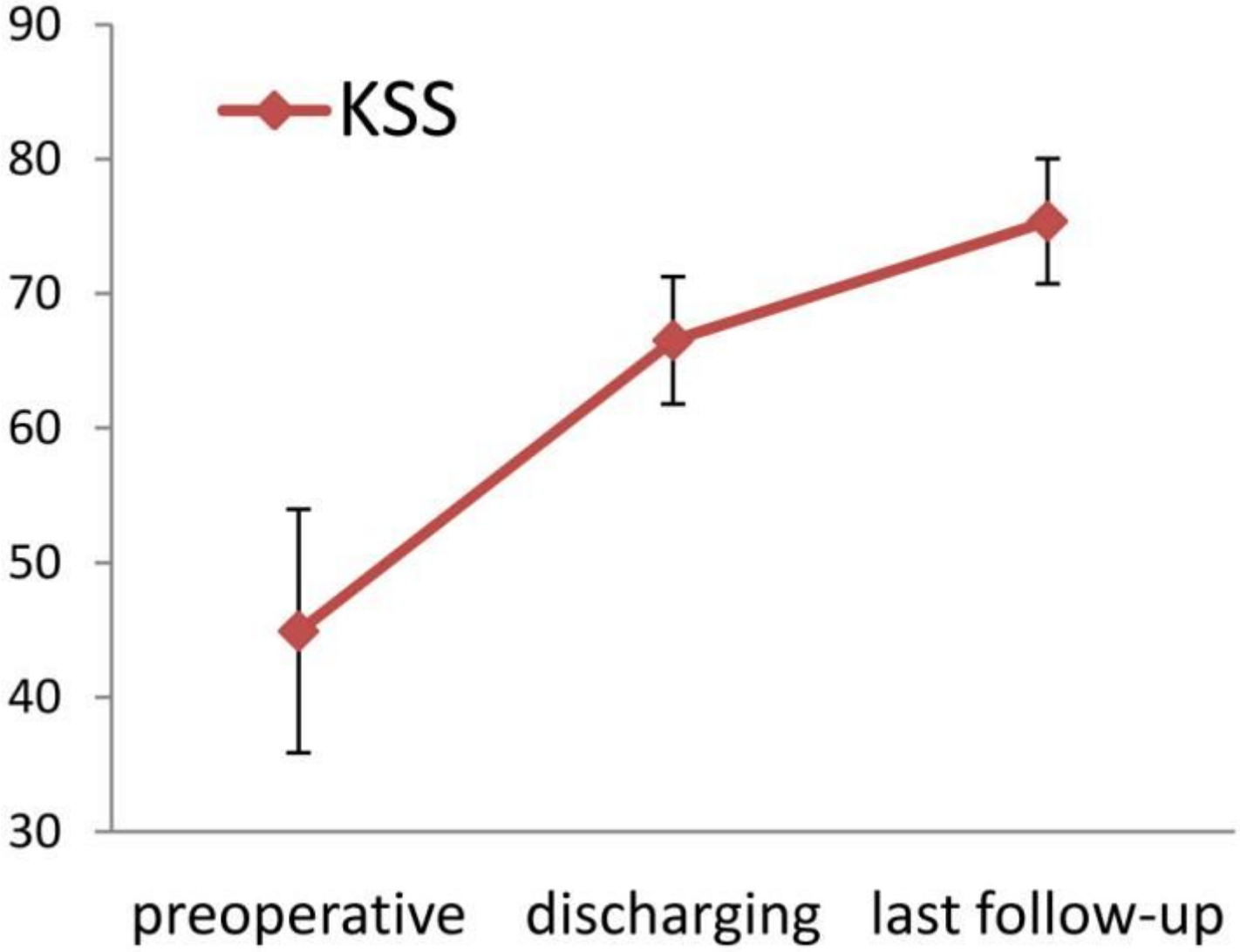

Figure 7

KSS score at different time point within group

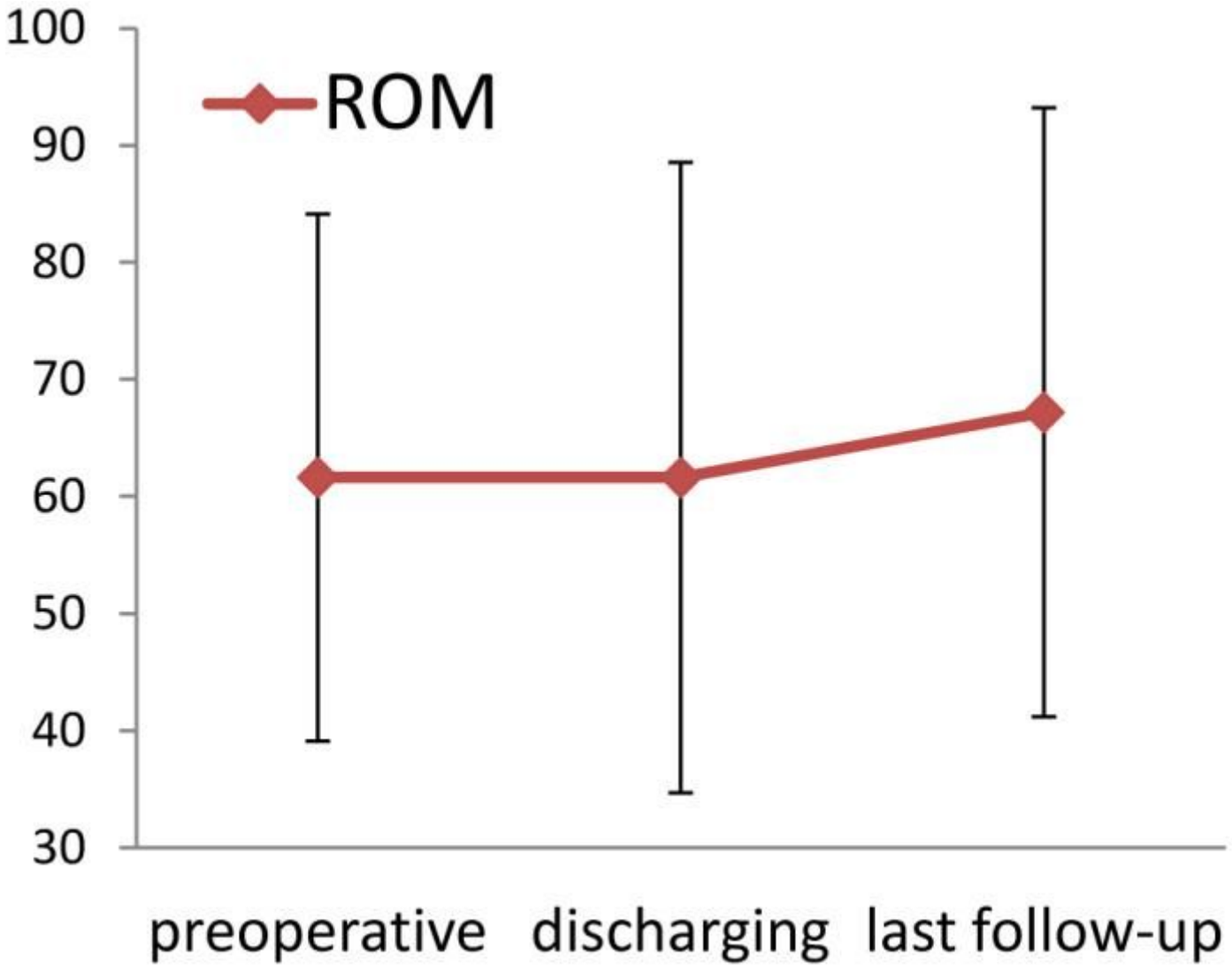

Figure 8

ROM at different time point within group