Self-Expanding Metal Stent Insertion by Colorectal Surgeons Using a Two-Person Approach Colonoscopy Without Fluoroscopic Monitoring in the Management of Acute Colorectal Obstruction: A 14-Year Experience

feihu Yan
shang hai chang hai yi yuan: Changhai Hospital https://orcid.org/0000-0003-4227-0757
Yao Zhang
Shanghai Jiao Tong University Medical School Affiliated Ruijin Hospital
Cheng-ling Bian
shang hai chang hai yi yuan: Changhai Hospital
Xiao-shuang Liu
Shang hai zhong yi yao da xue
Bing-chen Chen
shang hai chang hai yi yuan: Changhai Hospital
Zhen Wang
shang hai chang hai yi yuan: Changhai Hospital
Hao Wang
shang hai chang hai yi yuan: Changhai Hospital
Ji fu E
shang hai chang hai yi yuan: Changhai Hospital
En-da Yu (fei1989hu@163.com)
shang hai chang hai yi yuan: Changhai Hospital

Research Article

Keywords: Colorectal stenting, No fluoroscopy-guiding, Large bowel obstruction, Colorectal cancer, Extra-luminal compression, Benign colorectal diseases, Recurrent tumor, Learning curve

Posted Date: March 1st, 2021

DOI: https://doi.org/10.21203/rs.3.rs-240980/v1

Abstract

Background Placement of a self-expanding metal stent (self-expanding metal stent, SEMS) in patients presenting with kinds of colorectal disease as an acute colorectal obstruction (acute colorectal obstruction, ACO) may obviate emergency surgery(emergency surgery, ES), potentially effectively palliating incurable tumours, acting as a bridge to surgery (bridge to surgery, BTS) in patients with operable or potentially operable tumours and achieving effective decompression of other colorectal obstruction diseases. We present our experience with SEMS insertion by colorectal surgeons without fluoroscopic monitoring for ACO especially for acute malignant colorectal obstruction (acute malignant colorectal obstruction, AMCO) nearly a 14-year period (2007–2020).

Methods We retrospectively reviewed the medical records of patients to identify all patients presenting to our unit with ACO especially with AMCO who had stenting carried out to achieve colonic decompression. All 434 procedures were performed by colorectal surgeons using a two-person approach colonoscopy and a conventional endoscope without fluoroscopic monitoring.

Results The overall technique success rate by SEMS insertion was (428/434, 98.6%), the overall clinic success rate by SEMS insertion was (412/434, 94.9%), and the overall incidence of complications was (19/434, 4.4%). The complications included clinical perforation (6/434, 1.4%), stent migration (2/434, 0.5%), one of which re-stent; stent detachment (fell off)(3/434, 0.7%), none of them with re-stent; stool impaction (6/434, 1.4%), 1 of which re-stent; abdominal pain or anal pain (2/434, 0.5%). There was no hemorrhage in any of the 434 patients.

Conclusions SEMS insertion is a relative safe and effective technique for colonic decompression in the dealing with ACO as either a bridge to subsequent resection surgery or as palliative measure, or solution to other causes such as recurrent tumor benign diseases or extra-luminal compression. Therefore, ES was largely avoided.

What Does This Paper Add To The Literature?

This study provides a successful decompression experience of self-expanding metal stent insertion in the management of acute colorectal obstruction, using a two-person approach colonoscopy without fluoroscopic monitoring.

Background

Colorectal cancer is the most common cancer, approximately 10%-20% of the patients with colorectal cancer present with large bowel obstruction, and those who present with ACO require urgent decompression because ACO can cause electrolytic fluid imbalance, colonic necrosis, bacterial translocation, and death[1]. Placement of colonic SEMS for ACO is a major and standard endoscopic treatment that has been available since1991[2]. The placement of colonic SEMS for palliation and for BTS in patients with AMCO has been increasingly reported in the past 30 years. Substantial concerns of tumor seeding following SEMS placement, especially in case of perforation, have been raised in numerous studies. Actually, no significant differences are reported in oncologic long-term survival between patients undergoing stent placement as a BTS and those undergoing ES[3, 4]. ES is associated with several disadvantages such as increased postoperative morbidity and mortality rates[5], higher stoma rate and lower rates of curative resection than patients who have elective resection[6]. The use of SEMS to restore luminal patency is a more reasonable alternative to ES in patients presenting with AMCO who are urgent to getting intestinal decompression. It can better avoid the risks and disadvantages associated with ES. Relieving the ACO in

this approach has following advantages: 1.Stenting essentially makes the surgical intervention more like an elective one-stage procedure for patients in whom curative resection is more possible, significantly reducing the need for temporary stoma[7]; 2.Stenting can serve as definitive palliative treatment in patients unfit for surgery, especially who have disseminated, metastatic disease precluding curative resection, so the management of cancer-associated intestinal obstruction near the end of life has changed over time with the increased use of stents and decreased use of surgery[8]; 3.Effective decompression enables full oncologic staging to be undertaken, which can help patients to choose more suitable further treatment[9]; 4.Effective decompression can provide opportunity to correct metabolic disturbances and malnutrition; 5.Effective decompression makes neoadjuvant therapy possible, without surgical intervention; 6.It is effective approach in extra-luminal tumors causing bowel obstruction[10];7. It is a solution to other ACO causes such as recurrent tumor□benign diseases et al.

With the recommendation of stent and the current clinical practice situation, it has been gradually widely used as one of the preferred intestinal decompression schemes. Although recent studies have reported low complication rates related to colonic stents, complications may still occur, highlighting the importance of good preparation, adequate staffing, backup systems, and informed consent[1]. Actually, due to the variations in the reported experience, we need to pay more attention to sum up the application experience, improve the success rate and reduce the incidence of complications, reduce the radiation exposure and the dependence on objective conditions, make it easy to carry out and promote.

We describe our experience with SEMS insertion for ACO especially for AMCO nearly a 14-year period (2007–2020) in a tertiary referral centre, where all colorectal stents were carried out by colorectal surgeons, using a two-person approach colonoscopy and a conventional endoscope without fluoroscopic guiding.

Materials And Methods

Patients

Between October 2007 and January 2020, 434 consecutive patients (302 males and 132 females) presenting with ACO mainly from primary colorectal malignancy were considered for decompression by SEMS insertion at the Changhai Hospital of Naval Military Medical University.

Treatment strategy

Since the introduction of colorectal stent to our department in 2007-10-11, it has almost been our policy to undertake this treatment strategy in all patients presenting with ACO. The ACO was defined by the presence of clinical symptoms or signs of bowel obstruction caused by colorectal related diseases, including kinds of tumors, benign disease and extra-luminal compression disease et al. Those patients who were admitted to Chang-Hai Hospital, doctors, patients, and families had a conversation about the treatment options and risks before operation. Based on the previous results and experiences, SEMS was the first considered option for patients with ACO in our center. We suggested patients to receive SEMS as a BTS or a palliative treatment option. However, some patients and families rejected our suggestions for the reasons such as the cost of treatment (in China, SEMS is not included in Healthcare Insurance)□the risk of decompression failure or the relatively longer treatment period. As a result, ES was done for some patients, and SEMS were placed as a BTS on the remaining patients. These remaining patients with ACO were included in this study. The signs of obstruction were defined as (1) distended proximal bowel, liquid surface, transitional zone or collapsed distal bowel on abdominal CT scans (Fig.

1), which can also demonstrate the level of obstruction、position and length of the stricture; or (2) in the colonoscopic evaluation, it is impossible to pass through the stenotic area. The clinical symptoms of obstruction were defined as (1) constipation, (2) abdominal bloating, (3) vomiting, or (4) abdominal pain[3], and the patients who had at least three of the four symptoms were enrolled.

Following SEMS insertion, a plain chest Computed tomography (Computed tomography,CT) scan、a enhanced abdominal CT scan、a enhanced liver MRI examination were performed to complete the tumour TNM staging, and the CEA and CA199 level was measured. The biopsy of the tumour was taken for confirmation of malignant histology at the time of SEMS insertion or in 2 weeks following stent placement by a further colonoscopy. Following discussion at a multidisciplinary team (multidisciplinary team, MDT) meeting or MDT outpatient clinic, patients with curable or potentially curable cancers were offered curative resection、neoadjuvant therapy. Resection was done for those patients at a median 18.5 days (14, 29 days) post-stenting, and the other patients were offered palliative treatment.

SEMS insertion technique

In our center, we use a two-person approach to colonoscopy. SEMS insertions were performed using a conventional endoscope (CF-H260, Olympus, Tokyo, Japan) by experienced、qualified endoscopists (en-da Yu, rong-gui Meng, wei Zhang, hao Wang, zheng Lou, li-qiang Hao et al)without fluoroscopic monitoring. Patients underwent cleansing enemas for bowel preparation and accepted insertion without sedation. Before stent insertion, general condition of patients need to be evaluated、and three indicators associated with tumor (the site, length, and degree of obstruction) were assessed by conventional CT. The stent size(diameter, 18–24 mm, the most commonly used were 20mm、22mm and 25mm) and length (80–170 mm, the most commonly used were 90mm) were chosen according to the measured length of the obstruction on the CT images, and uncovered SEMS were mainly used. The length of the stent was at least 1-2cm longer than the stenosis at both sides to allow for adequate margins. Specific methods of operation: Inserted endoscope to the obstruction position, repeatedly washed using NS in order to expose the narrow hole of tumor. A flexible guide-wire was inserted through the endoscope channel, then passed through the obstructive lesion under endoscopic guidance without fluoroscopy[11]. Once the stent had been inserted along the guide-wire across the obstruction by endoscopy through the endoscope channel, the stent was deployed through direct endoscopic guidance. After placement, the correct position and expansion of the stents were confirmed by simple abdominal radiography if necessary. One more stent was used in only one procedure at the day of insertion.

Definition of outcome

Technical success was defined as: 1. The flexible guide-wire pass through the obstructive lesion without resistance; 2. The stent should be inserted along the guide-wire across the obstruction without resistance; 3. The stent should be deployed smoothly, the distal end of the stent should be within a normal lumen below the tumour and with a appropriate margin, neither too long nor too short (Fig.2); 4. The correct position and expansion of the stent can be confirmed by simple abdominal radiography if necessary (Fig.3). Clinical success was defined as decompression of the obstructed proximal bowel and restoration of luminal patency, without further interventions before the next stage of treatments, such as radical operation、neoadjuvant therapy、palliative treatment et al.

Data retrieval and collected

We reviewed 3 data systems to confirm and to identify that all SEMS patients were included in this study Database, including the electronic medical record system the endoscopy department record system and operating theatre register system.

We collected the following data: patient demographics such as age sex et al, basic diseases, indications, site of obstruction, technical and clinical success of SEMS insertion, clinical TNM stage, length of hospital stay, details of subsequent surgery resection, post-stenting complications including requirement for further emergency surgery interventions.

Statistical methods

Continuous variables are presented as mean (standard deviation) and dichotomous variables are presented as number and percentage values. All analyses were performed with SPSS version 22.0 statistical software package (SPSS, Inc., Chicago, IL).

Results

1.Demographics and obstruction distribution

Between October 2007 and January 2020, 434 consecutive patients (302 males and 132 females) presenting with ACO mainly from primary colorectal malignancy were considered for decompression by SEMS insertion. The mean age was 63.49±15.10 years. 126(29.0%) patients had comorbidities (Table 1). 386 patients (88.9%) had left-sided disease (tumour located at or distal to the splenic flexure). 15 patients (3.5%) had transverse colon disease. 33 patients (7.6%) had more proximal tumours—27 at the hepatic flexure and 6 in the ascending colon (Table 2).

2.Clinic results

The overall technique success rate was (428/434, 98.6%). The overall clinic decompression rate was (412/434, 94.9%) by SEMS insertion. The overall complication rate was (19/434, 4.4%). The overall emergency surgery required was (21/434, 4.8%) (Table 2).

Palliative stenting

In 124 patients (124/434, 28.6 %), the indication for SEMS was palliation. The overall technique success rate was (121/124, 97.6%). The overall clinic decompression rate was (118/124, 95.2%) by SEMS insertion. The overall complication rate was (4/124, 3.2%). The overall emergency surgery required was (6/124, 4.8%) (Tables 1, 3, 4). The location of obstruction points was as follow: ascending colon(1, 0.8%), hepatic flexure(10, 8.1%), transverse colon(7, 5.7%), splenic flexure(6, 4.8%), descending colon(18, 14.5%), descending-sigmoid colon(5, 4.0%), sigmoid colon(37, 29.8%), recto-sigmoid(37, 29.8%), rectal (23, 18.6%)(Tables 3).

In the 3 technical failure patients, the tumour was found to be so tightly occluding the lumen of the colon that the narrow hole of tumor could not be exposed so the guide-wire could not be passed and emergency transverse colostomy was performed for those 3 patients. The other 3 patients were technical success but clinic failure: emergency transverse colostomy was carried out for 2 patients with incomplete decompression and a Hartmann's procedure was performed for another rectal tumour patient with sigmoid spontaneous perforation, which might be caused by the use of bevacizumab.

Stenting as a BTS

The stenting as a BTS was undertaken for 277 patients (277/434, 63.8 %). The overall technique success rate was (274/277, 98.9%). The overall successful clinic decompression rate was (261/277, 94.2%) by SEMS insertion. The overall complication rate was (13/277, 4.7%). The overall emergency surgery required was (15/277, 5.4%) (Tables 1, 3, 4), one more stent was used in only one patient in BTS group at the day of insertion because of the failure of decompression. The location of obstruction points was as follow: ascending colon(5/277, 1.8%), hepatic flexure(17/277, 6.1%), transverse colon(6/277, 2.2%), splenic flexure(22/277, 7.9%), descending colon(44/277, 16.0%), descending-sigmoid colon(28/277, 10.1%), sigmoid colon(84/277, 30.3%), recto-sigmoid(31/277, 11.2%), rectal(40/277, 14.4%)(Tables 3).

15 of the 277 patients (5.4%) in whom stent insertion was attempted as a BTS did not have successful decompression, although technique success rate was higher (274/277, 98.9%) (Table 4). In the 3 technical failure patients, the tumour was found to be so tightly occluding the lumen of the colon that the narrow hole of tumor could not be exposed so the guide-wire could not be passed and emergency transverse colostomy was performed for two, emergency right hemicolectomy was performed for another. The other 13 patients were technical success but clinic failure. In 6 patients, it was due to very tight angulation or constrictive tumor of the colon at the obstruction site precluding stent fully open post-deployment: anterior resection with primary anastomosis and defunctioning loop transverse colostomy was performed for a sigmoid tumour; two emergency Hartmann's procedure was performed; three emergency transverse colostomy was carried out. One re-stent, the decompression effect was satisfactory. After 200 days neoadjuvant chemotherapy, a recto-sigmoid colon cancer patient combined liver metastases developed incomplete obstruction one day before surgery, then another stent was inserted to achieve decompression but mal-positioning result in acute obstruction because of stent occlusion, so a emergency loop sigmoid colostomy was carried out under transverse abdominal fascial block (Fig. 4). In another 5 perforation patients, one emergency transverse colostomy was carried out; two emergency Hartmann's procedure was performed; one subtotal colectomy was carried out for a patient with perforation after administration of avermectin, the perforation point was far from obstruction sigmoid; anterior resection with primary anastomosis and defunctioning loop ileostomy was performed for a sigmoid tumour.

261 of the 277 patients (94.2%) in whom stent insertion was attempted as a BTS had successful decompression. Except 4 patients who refused surgery, the remaining 257(92.8%) patients plus one successful re-stenting patient in BTS group proceeded to resection (Table 4) at a median 18.5 days (14, 29 days) post-stenting, with no anastomotic leaks observed. It was consist with most of the evidences reported that an interval of over 15 days is recommended to minimize postoperative complications. The specific operation modes were as follows: right hemicolectomy(23/258, 8.9%), transverse colon resection(3/258, 1.1%), left half colon resection(83/258, 32.2%), anterior resection(132/258, 51.2%), subtotal colectomy(3/258, 1.1%), Hartmans(10/258, 3.9%), Miles(3/258, 1.1%), stoma only(1/258, 0.4%) (Table 5).

The total stoma rate was 8.5% (22/258, 8.5%): a defunctioning loop ileostomy was performed for a patient with abdominal abscess who accepted left half colon resection; two defunctioning loop ileostomy was carried out for two patients who accept subtotal colectomy out of plan; a palliative loop transverse colostomy was performed for a patient of sigmoid tumour with extensive abdominal metastasis; the other eighteen patients with low or ultra-low rectal cancer accepted loop ileostomy as a routine surgery.

For those 258 patients, 55 accepted laparoscopic assisted operation (one hand assisted laparoscopy, one Da Vinci) (55/258, 21.3%), 68 accepted minilaparotomy operation (68/258, 26.4%) (Fig. 5), 135 accepted open operation (135/258, 52.3%), so the overall minimally invasive surgery rate was 47.7% (2007-2020) (Table 5). In fact, the rate of minimally invasive surgery in recent years is much higher than this average value from 2007 to 2020.In addition, since 2015, we have carried out combined organ resection for obstructive colorectal cancer patients with liver metastasis after successful stent decompression. A total of 6 patients in this study had successfully received this treatment approach.

Stenting for benign diseases、recurrent tumor and extra-luminal compression disease

The stent was undertaken for the other 33 patients (33/434, 7.6 %) with benign diseases、recurrent tumor and extra-luminal compression disease et al (Tables 1,3,4). Technical and clinical success was achieved in all these 33 patients as a decompression measure (33/33, 100%). The complication rate was (2/33, 6.1%). No emergency surgery was required (Table 4). The composition of the lesions leading to obstruction was as follow: recurrent tumor(10/33, 30.3%); benign diseases(10/33, 30.3%); extra-luminal compression(13/33, 39.4%). The distribution of recurrent tumor(10/33, 30.3%): 2 sigmoid colon、8 rectal. The classification of benign diseases(10/33, 30.3%): 1 SLE、7 anastomotic stenosis、1 inflammatory stenosis, 1 foreign-body granuloma. The distribution of extra-luminal compression (13/33, 39.4%): 1 transverse colon、3 splenic flexure、1descending colon、1 descending-sigmoid colon、1 Sigmoid colon and 6 rectal(Tables 3, 4). The primary lesion of extra-luminal compression (13/33, 39.4%): 1 gastric stromal tumor、2 pancreatic cancer、3 retroperitoneal and pelvic tumors、3 gastric cancer、4 gynecologic tumor.

3.Follow-up

Palliative stents

Of the 124 patients who had stenting as a palliative measure, 5 subsequently required palliative transverse colostomy formation (90, 148, 185, 270 and 545 days after stenting respectively) under epidural anesthesia or laryngeal mask anesthesia and 1 subsequently required palliative sigmoid colostomy formation (86 days after stenting) under transverse abdominal fascial block due to local tumour progression and ingrowth which was not amenable to further endoscopic management. One patient developed small intestinal obstruction 2 months following initial successful stent placement due to extensive abdominal metastasis and made a loop ileostomy under transverse abdominal fascial block. The overall rate of subsequent recurrent obstruction necessitating an surgical intervention in this group was thus 5.6% (7/124). One further patient required re-stent(337 days after stenting) due to re-obstruction caused by local tumour ingrowth (Fig. 6). However, we noted one incidence of stent migration in our series, which were solved by placing another stent, one incidence of stent detachment without re-stent and re-obstruction.

Stents for benign diseases、recurrent tumor and extra-luminal compression disease

Two patients in recurrent tumor group accepted subsequent surgery(2/10, 20%): transverse colostomy was carried out for one and anterior resection for another, the rest 8 patients in this group had accepted adjuvant radiotherapy or chemotherapy only. 5 patients in benign diseases group accepted subsequent surgery (5/10, 50%): three transverse colostomy and one left half colon resection were carried out for 4 anastomotic stenosis; one patient with foreign-body granuloma accepted right hemicolectomy. the rest five patients in this group had accepted medical treatment such as improve microcirculation、anti-rheumatic immunotherapy et al. 2 patients in extra-

luminal compression group accepted subsequent surgery(2/13, 15.4%): gastro-intestinal short circuit surgery was carried out for a gastric stromal tumor; right appendectomy + greater omental excision+Hartmann's surgery was carried out for a gynecologic tumor(Table 4). The rest 11 patients in this group had accepted symptomatic treatment adjuvant radiotherapy and chemotherapy et al.

Stenting as a BTS

Both of the 30-day mortality rate and 30-day readmission rate of 258 patients proceeded to resection successfully in BTS were 0%. Except for common mild complications like wound infection, there were no other significant and serious postoperative complications such as pulmonary embolism anastomotic leakage abdominal hemorrhage et al occurred.

Discussion

In 1991, placement of SEMS in the obstructed large bowel was first described by Dohmoto[2] and is an attractive alternative method to achieve colonic decompression without operation. In a recent review in patients with incurable colorectal cancer presenting with acute obstruction, who are not suitable for surgery, stent insertion has been confirmed as definite palliation approach[12], and has been recommended by European Society of Gastrointestinal Endoscopy (ESGE) Guideline as the preferred treatment, strong recommendation, high quality evidence[13], obviating more invasive surgical interventions, in particular avoiding a stoma and facilitating early administration of other treatments such as neoadjuvant radiotherapy neoadjuvant chemotherapy or chemotherapy et al. For patients with potentially curable disease, stent placement as a BTS to avoid emergency surgery is one of the relatively recognized indications[14, 15], the subsequent operative risk is significantly reduced and allowing adequate oncological staging, good colonic preparation, a quicker initiation of chemotherapy, higher elective single-stage surgical resection rate without the need for stoma[4, 16] and the possibility of a laparoscopic approach[17] minilaparotomy or Da Vinci radical resection. As one of the few guidelines available, ESGE recommends stenting as a bridge to surgery to be discussed, within a shared decision-making process, as a treatment option in patients with potentially curable left-sided obstructing colon cancer as an alternative to emergency resection, ESGE Guideline also suggests consideration of colonic stenting for malignant obstruction of the proximal colon as a bridge to surgery[13]. The Guideline suggests that it should be considered carefully, instead of no recommended. Furthermore, palliative management of extra colonic tumors causing ACO has already become one of the recognized indications of stent placement[10, 18].

This strategy for managing ACO may be associated with SEMS-related complications and other short-term outcomes. Concerns and controversy surrounding SEMS relate to their likelihood of technique and clinic success, potential complications and efficacy. A multicenter, prospective, clinical study conducted by Japan Colonic Stent Safe Procedure Research Group reported technical and clinical success rates of 97.9% and 95.5%, respectively, with a perforation rate of 2%, demonstrating that colonic stents can be safely inserted[19], consistent with our own data(98.6% 94.9% 1.4%, respectively). There were 4 patients (4/434, 0.9%) later required a second stent (1 tumour ingrotwth in palliative group, 1 migration in palliative group, 1 failure decompression in BTS group, 1 stool impaction in BTS group).

Migration or progressive tumour growth may result in a subsequent episode of obstruction. Although many patients treated with palliative intent die of systemic disease or tumor progression before tumour growth into stent

becomes clinically apparent, the above clinical manifestations occurred in 6 cases (86, 148, 185, 270, 545 and 337 days after stenting respectively) in our study and were solved by 5 palliative colostomy formation or 1 re-stenting. We had been to undertake endoscopic stent surveillance at 3–6 monthly intervals, enabling early identification of tumour growth into the stent and pay attention to whether the patient has obstruction symptoms or incomplete obstruction symptoms. Symptoms or colonoscopic findings were the indications for palliative colostomy or re-stenting before complete intestinal obstruction occurs again for those patients. We have experienced 2 stent migrations, one stent migration in BTS group occured the day before operation and were prolapsed under endoscopy, without re-stent; another stent migration in palliative group occured 90 days after palliative stenting and palliative chemotherapy with re-stent to restore patency. We have experienced 3 stent migration related detachments, two detachments in BTS group occurred 15 days post-stenting after the intestinal wall edema subsided without re-stent and re-obstruction another patient with detachment in palliative group was sensitive to palliative chemotherapy, the stent detachment 360 days after stenting without re-stent and re-obstruction, consistent with the opinion that chemotherapy is considered a significant risk factor for long-term complications such as stent migration[4]. So the overall rate of migration and migration related detachment in technique success stent insertions was 1.2% (5/428), less than some series which had a combined dislodgement and migration rate of 4-10%[20, 21]. This was likely to be attributable to the use of CT to confirm de length of obstruction site, chose stents longer than the obstruction, and the stents present with a "bilateral opening speaker sample" style, which may improve stent retention. This shows that the significance of CT evaluation may far greater than that of fluoroscopy guidance. Meanwhile, stenting carried out by colorectal surgeons, using a two-person approach colonoscopy may more convenient for teamwork and stent deploy. In general, when re-obstruction occurs, our principle of treatment is to intervene as little as possible to solve the problem. The priority of intervention: re-stenting, stoma formation, Hartmann's, resection and anastomosis. If surgical intervention is needed, the priority of anesthesia methods is as follows: transverse abdominal fascial block, epidural anesthesia, laryngeal mask anesthesia, general anesthesia. Since 2019, we began to perform loop sigmoid colostomy loop ileostomy under transverse abdominal fascial block for some patients such as poor basic condition sine aged more longer sigmoid et al. Those work achieved surprised clinic outcome, not only technique succeed but also decompression succeed avoiding the influence of anesthesia on general condition.

Stent-related perforation is a kind of serious complication. In a recent meta-analysis of studies finding stent-related perforation is associated with an increased risk of global and locoregional recurrence by Izaskun Balciscueta et al[22]. Although some studies suggest that no negative effects on survival were observed for stent-related perforations[23], perforation itself is a dangerous event necessitating an emergency surgical intervention[24]. We report a 1.4% (6/434) perforation rate and contend that a flexible guide-wire should insert through the endoscope channel, pass through proximal to the obstructive lesion under endoscopic guidance, then the stent can insert along the guidewire across the obstruction by endoscopy through the endoscope channel prior to deployment of the SEMS. It can be considered that "the successful insertion of the guide wire is half of the success". Based on the experience of our center and the literature reports, we have the following suggestions and tips about stent-related perforation: 1. It is strictly dependent from operator expertise[4]; 2. satisfactory bowel preparation to expose the narrow hole of tumor, smoothly guidewire insertion can avoid mal-positioning[3]; 3. violence placement of stent can induce perforation (tumor and nontumor local perforation)[4]; 4. pay more attention to inadequate colonic decompression after stenting[4]; 5. pay attention to chemotherapy especially bevacizumab and radiotherapy before and after stenting[4]; 6. use carbon dioxide instead of air as possible and avoid excessive insufflations; 7. a two-person approach to colonoscopy may be more conducive to stenting[3]. In

addition, it is reported that perforation can increase up to 12% during BV treatment in patients with obstructing advanced colorectal cancer that would benefit from SEMS, and it is suggested that we should consider the risks associated with systemic therapies, taking into account the improvement in survival observed with bevacizumab[25].

There was one incidence of abdominal pain after SEMS insertion, but only for observing and the patient did not need special handling. Not all lesions are anatomically amenable to stenting, including those in the distal rectum that preclude deployment in normal bowel distal to the tumor[26], and even if stent is released and decompression successfully, the rectal irritation can also be very severe. Many distal rectum obstruction patients who accepted stent insertion complained of obvious discomfort, and one patient chose to remove the stent for transverse colostomy because of serious rectal irritation symptom. Therefore we always excluded rectal cancers within 6 to 8 cm of the anal verge in our center, except for very special and necessary cases. There were 6 left hemicolon patient had stool impaction, one of these patient required a second stent, but decompression failed. Our effective routine treatment approach for these symptom was: 50% magnesium sulfate 50 ml plus warm saline 200 ml was injected for retention enema through colonoscopy. From our point of view, forbidden to eat crude fiber food is one of the important and key points to prevent re-obstruction, of course, small dose of laxatives such polyethylene glycol is necessary.

It is suggested that there is no statistically significant difference in 30-day mortality between the BTS group and ES group in AMCO of 5 randomized controlled trials[27] similar to data from our center that both of the 30-day mortality rate and 30-day readmission rate of 258 patients successfully proceeded to resection in BTS were 0%. In a recent retrospective longitudinal cohort study using the NYS SPARCS Database compared stenting as a BTS with immediate resection, found that colonic stenting as a bridge to surgery lead to less stoma creation a significant quality of life advantage[28] and lower complication rate[24], consistent with the results of our study that no significant and serious postoperative complications.

In addition, a comparative study in our center found that there were no significant differences in terms of the long-term oncological outcomes between SEMS group and ES group in the 3-year OS rate (55.6% versus 39.4%; P = 0.2119) and the 5-year OS rate (48.1% versus 36.4%; P = 0.3570), but with less operation time and short mean length of hospitalization in the SEMS group[3].

Recent studies found that after SEMS placement as BTS therapy, the laparoscopic approach can be a safe alternative to ES, if the procedure is precociously applied[29]. Since the first case of laparoscopic surgery in BTS group on 2012-08-27, we can now carry out combined organ resection for obstructive colorectal cancer patients with liver metastasis after successful stent decompression, under laparoscopic approach.

Indication of postoperative anastomotic stenosis and extra-luminal compression disease. Postoperative strictures at the anastomotic site are reported to occur in approximately 3%–30% of patients who underwent colonic resection[30], leaking due to inappropriate anastomosis at the time of reconstruction, radiation therapy, ileus, infection, and ischemia due to improper blood supply at the site might be possible causes[31]. In patients with stenosis at the lower rectum (below peritoneal reflexes), balloon dilatation under colonoscopy or anastomotic plasty transanal is the first choice in our center. In patients with stenosis located above peritoneal reflexes, balloon dilatation under colonoscopy should be chosen carefully because once the balloon water injection is too much, violent expansion will tear the intestinal wall, resulting in perforation, which had happened in our center. For those

patients SEMS insertion should be used primarily rather than resection and anastomosis as the consequent morbidity and mortality rates owing to surgery are high. Of course, surgery should be considered for patients with recurrent obstruction after stenting. Stenting is appropriate for strictures if there are no previous radiation therapy and no postoperative anastomotic leak or if the stenosis is short and soft. It is difficult to treat anastomotic stenosis or intestinal segment stenosis caused by radiotherapy by any method mentioned above. It is reported in some study that SEMS for extrinsic malignant colon obstruction is associated with lower technical and clinical success rates compared with intrinsic colon malignancy[32]. However, the clinical and technical success rates were 100% (13/13) in our study. Evaluating strictly and narrowing indications in our center might be the guarantee of successful decompression. CT scan must be performed to confirm the lesion location and the lesion length before the procedure in order to exclude extensive metastasis and multiple site obstruction. For the obstruction caused by extraluminal compression, single site lesions especially the lesions infiltrating the whole intestinal wall were considered as the best indications in our center. In addition, clinical sensitivity of endoscopic treatment is more necessary for other benign lesions that cause large bowel obstruction.

In extreme ACO cases, stent placement is the first choice for decompression avoiding stoma making. There were some cases in our study. One was severe systemic lupus erythematosus syndrome with poor basic condition, standard rheumatic immunotherapy was performed for this patient after stenting to relieve obstruction. One patient with coronary heart disease developed intestinal obstruction after 2 days of cardiac stent implantation, Aspirin and Plavix could not be stopped, so the risk of operationg related bleeding was high. After careful evaluation and MDT discussion the obstruction was successfully relieved by stent insertion.

As mentioned above, because the technique success rate and clinic success rate of stent doesn't have to be 100% always, and if the patient is not a candidate for colonic stenting or when stenting expertise is not available, it is necessary to evaluate and prepare for emergency surgery decompression before attempting stent implantation, and it is recommended to stay in the ward. Stay in the ward and a decompressing stoma are the guarantee of patient safety.

Limitations of this study

This is a retrospective study, which may have its own limitations. In the future, prospective observational studies, prospective cohort studies and prospective randomized controlled trials are needed to further explore the application value of SEMS implantation in the treatment of ACO.

Conclusions

The clinical advantages of SEMS insertion in the management of ACO combined with the little negative oncological consequences makes stent a effective clinical method[4]. The limitation of the use of SEMS is the high perforation rate in several randomised controlled trials[24, 33, 34], other complications, technical and clinical success rate need to improve for some units, long term exposure under X-ray environmental threats health to operators, especially young doctor[1] et al. The variation in the rates of success of SEMS insertion and associated complications reported in the literature suggests that individual expertise institutional experience and available resources[26] has a significant bearing on the clinical application of SEMS.

According to our experience, in addition to highly recommended CT (sensitivity 96 %, specificity 93 %) evaluation[13], perhaps we can have the following revelation: (1)A two-person approach to colonoscopy may be

more suitable for SEMS insertions than one-person approach, because good cooperate makes more conducive to succeed; (2)It could be done without fluoroscopic monitoring, reducing the manpower cost, avoiding the radiation exposure to operator and patient;(3) All SEMS insertions should be carried out by colorectal surgeons, adhering to a consistent technique[24];(4) General condition and tumor characteristic of patients need to be evaluated well this is the foundation of success;(5) Make bowel preparation as well as possible, repeatedly washed using NS in order to expose the narrow hole of tumor is a key procedure;(6) Avoid excessive air insufflations, and carbon dioxide is highly recommended; (7) A two-person approach to colonoscopy is more conducive to the assistant of colonoscopy to carry out abdominal compression, assist in inserting the endoscopy and stabilizing the endoscopy body .

Operator experience has been shown to be a determinant factor to ensure appropriate stent placement and restoration of bowel function. It suggested that the adoption of this approach as standard practice only in highly specialized centers. In order to ensure the safety of stent insertion, there are the following recommendations. First, it has been recognized a learning curve including more than 20-30 colonic stent procedures to improve technical and clinical success rate and to achieve an adequate level of technical skills needed to manage the challenging settings of emergency colonic stent insertion[35, 36]. Before entering the training, our center requires the operator to complete at least 2000 cases of colonoscopy independently and the training programs aims to improve skills in the specific setting of emergency endoscopy. Secondly, a tailored approach based on patient condition, surgical risk and disease presentation seems to be the most reasonable method to define indications. In addition, emergency colonic stenting is not available in all hospitals, therefore protocols regarding management of ACO should be organized to specify whether a tertiary level centers can undergo this approach in emergenc condition with their available resources.

At least, stent insertion is a relative less invasive safe and effective technique for colonic decompression in the setting of ACO in selected patients. It may not apply to all situations and should be interpreted in the setting of specific clinical situations and resource availability[13]. Although ESGE suggests that colonic stenting should be performed with the combined use of endoscopy and fluoroscopy, with weak recommendation, low quality evidence[13]. So stent insertion without fluoroscopic monitoring is a powerful attempt to reduce the dependence on objective conditions. It can be used as palliative measures, bridge to subsequent resection and measures for benign diseases recurrent tumor and extra-luminal compression disease. Specific guidelines on the management of ACO could be useful to clarify several controversial issues.

Abbreviations

SEMS:self-expanding metal stent; ACO:acute colorectal obstruction; ES:emergency surgery; BTS:bridge to surgery AMCO:acute malignant colorectal obstruction; CT:computed tomography; MDT:multidisciplinary team ESGE:European Society of Gastrointestinal Endoscopy

Declarations

Acknowledgements

Not applicable

Authors’contributions

Fei-hu Yan, Ji-fu E and En-da Yu designed the study, carried out the majority of treatment, such as surgery and endoscopy. Fei-hu Yan, Yao Zhang, Cheng-ling Bian, Xiao-shuang Liu, Bing-chen Chen, Hao Wang, Zhen Wang collected□analyzed and interpreted the clinical data. Fei-hu Yan drafted the manuscript. Fei-hu Yan, Yao Zhang, Cheng-ling Bian and Xiao-shuang Liu were involved in editing the manuscript. Bing-chen Chen and Zhen Wang carried out the follow-up work.Fei-hu Yan, Yao Zhang, Cheng-ling Bian and Xiao-shuang Liu contributed equally to this work and are considered co-first authors. Ji-fu E□En-da Yu reviewed and edited the manuscript. All authors read and approved the final manuscript.

Funding

1.Youth program of National Natural Science Foundation of China, 81802434

2.General program of National Natural Science Foundation of China, 81870455

3.General program of National Postdoctoral Science Foundation of China, 45862

4.Project establishment and cultivation of teaching achievements of PLA Naval Military Medical University□JPY2020B29

5.Project establishment and cultivation of teaching achievements of Changhai Hospital, PLA Naval Military Medical University□CHJG2020023

6."Deep blue" talent project, "sailing program" funding of PLA Naval Military Medical University□202128

Availability of data and materials

The datasets generated and/or analyzed during the current study are not publicly available due to protecting individual patient privacy but are available from the corresponding author on reasonable request.

Ethics approval and consent to participate

Approval and written consent to compile data from those Database for the purpose of reviewing our experience with this technique was obtained from the Medical Ethics Board/ Institutional Review Board of Chang-hai Hospital (CHEC2013-145). The study was conducted in accordance with the Declaration of Helsinki.

Consent for publication

Not applicable.

Competing interests

The authors declare no competing interests or financial ties to disclose.

Author details

[1]Department of Colorectal Surgery, Changhai Hospital, Naval Military Medical University, Shanghai, 200433, China.

[2]Department of Gastroenterology, Ruijin Hospital, Shanghai JiaoTong University School of Medicine, Shanghai, 200025, China.

[3]Department of Radiology, Changhai Hospital, Naval Military Medical University, Shanghai, 200433, China.

[4]Department of general Surgery, Shuguang Hospital, Shanghai University of Traditional Chinese Medicine, 201203, Shanghai, China.

[5]Department of General Surgery, Eastern Theater Naval Hospital, Zhoushan, 316000, China

References

1. Saida Y. Current status of colonic stent for obstructive colorectal cancer in Japan; a review of the literature. Journal of the anus, rectum and colon. 2019;3(3):99-105.
2. M D. New method: Endoscopic implantation of rectal stent in palliative treatment of malignant stenosis. Endosc Dig. 1991;3:1507–12.
3. Yan FH, Lou Z, Liu XS, Wang Z, Xu XD, Gao YJ, He J, Wang H, Fu CG, Zhang W, He HY, Cai BL, Yu ED. Long-Term Oncological Outcomes of Endoscopic Stenting as a Bridge to Surgery Versus Emergency Surgery for Malignant Colorectal Obstruction: A Comparative Study. Journal of laparoendoscopic & advanced surgical techniques Part A. 2017;27(6):611-7.
4. Ormando VM, Palma R, Fugazza A, Repici A. Colonic stents for malignant bowel obstruction: current status and future prospects. Expert review of medical devices. 2019;16(12):1053-61.
5. Iversen LH BlS, Christensen IJ, Laurberg S, Harling H. Danish Colorectal Cancer Group (2008) Postoperative medical complications are the main cause of early death after emergency surgery for colonic cancer. Br J Surg. 2008;95:1012-9.
6. Cuffy M AF, Audisio RA, Longo WE. (2004) Colorectal cancer presenting as surgical emergencies. Surg Oncol. 2004;13:149-57.
7. Gibor U, Perry Z, Tirosh D, Netz U, Rosental A, Fich A, Man S, Ariad S, Kirshtein B. Comparison of the Long-Term Oncological Outcomes of Stent as a Bridge to Surgery and Surgery Alone in Malignant Colonic Obstruction. Isr Med Assoc J. 2017;19(12):736-40.
8. Merchant SJ, Brogly SB, Booth CM, Goldie C, Peng Y, Nanji S, Patel SV, Lajkosz K, Baxter NN. Management of Cancer-Associated Intestinal Obstruction in the Final Year of Life. Journal of palliative care. 2020;35(2):84-92.
9. Amelung FJ, Consten ECJ, Siersema PD, Tanis PJ. A Population-Based Analysis of Three Treatment Modalities for Malignant Obstruction of the Proximal Colon: Acute Resection Versus Stent or Stoma as a Bridge to Surgery. Ann Surg Oncol. 2016;23(11):3660-8.
10. Faraz S, Salem SB, Schattner M, Mendelsohn R, Markowitz A, Ludwig E, Zheng JT, Gerdes H, Shah PM. Predictors of clinical outcome of colonic stents in patients with malignant large-bowel obstruction because of extracolonic malignancy. Gastrointest Endosc. 2018;87(5):1310-7.
11. Baron TH, Rey JF, Spinelli P. Expandable metal stent placement for malignant colorectal obstruction. Endoscopy. 2002;34(10):823-30.
12. Fugazza A, Galtieri PA, Repici A. Using stents in the management of malignant bowel obstruction: the current situation and future progress. Expert Rev Gastroent. 2017;11(7):633-41.
13. van Hooft JE, Veld JV, Arnold D, Beets-Tan RGH, Everett S, Gotz M, van Halsema EE, Hill J, Manes G, Meisner S, Rodrigues-Pinto E, Sabbagh C, Vandervoort J, Tanis PJ, Vanbiervliet G, Arezzo A. Self-expandable metal

stents for obstructing colonic and extracolonic cancer: European Society of Gastrointestinal Endoscopy (ESGE) Guideline - Update 2020. Endoscopy. 2020;52(5):389-407.

14. Ribeiro IB, de Moura DTH, Thompson CC, de Moura EGH. Acute abdominal obstruction: Colon stent or emergency surgery? An evidence-based review. World journal of gastrointestinal endoscopy. 2019;11(3):193-208.
15. Baron TH, Wong Kee Song LM, Repici A. Role of self-expandable stents for patients with colon cancer (with videos). Gastrointest Endosc. 2012;75(3):653-62.
16. GJ. AYCJHBLRGSGSM. Self-expanding metallic stents for the management of emergency malignant large bowel obstruction: a systematic review. J Gastrointest Surg. 2016;20(2):455–62.
17. Bonin EA BT. Update on the indications and use of colonic stents. Curr Gastroenterol Rep. 2010;12(5):374-82.
18. Lin JL, David D, Lee B. Efficacy of Self-Expandable Metallic Stents for Colonic and Extracolonic Malignant Obstruction. Gastrointest Endosc. 2017;85(5):Ab401-Ab.
19. Matsuzawa T, Ishida H, Yoshida S, Isayama H, Kuwai T, Maetani I, Shimada M, Yamada T, Saito S, Tomita M, Koizumi K, Hirata N, Sasaki T, Enomoto T, Saida Y. A Japanese prospective multicenter study of self-expandable metal stent placement for malignant colorectal obstruction: short-term safety and efficacy within 7 days of stent procedure in 513 cases. Gastrointest Endosc. 2015;82(4):697-+.
20. Athreya S, Moss J, Urquhart G, Edwards R, Downie A, Poon FW. Colorectal stenting for colonic obstruction: the indications, complications, effectiveness and outcome–5 year review. European journal of radiology. 2006;60(1):91-4.
21. Young CJ, Suen MK, Young J, Solomon MJ. Stenting large bowel obstruction avoids a stoma: consecutive series of 100 patients. Colorectal Dis. 2011;13(10):1138-41.
22. Balciscueta I, Balciscueta Z, Uribe N, Garcia-Granero E. Long-term outcomes of stent-related perforation in malignant colon obstruction: a systematic review and meta-analysis. International journal of colorectal disease. 2020;35(8):1439-51.
23. van Silfhout L, Smeekens EAJ, van Eekeren RRJP, Burger JPW. Outcomes of Stenting as a Bridge to Surgery in Malignant Colonic Obstruction, With Emphasis on Perforation Rate and Clinical Success. Surg Laparo Endo Per. 2020;30(4):332-8.
24. Larkin JO, Moriarity AR, Cooke F, McCormick PH, Mehigan BJ. Self-expanding metal stent insertion by colorectal surgeons in the management of obstructing colorectal cancers: a 6-year experience. Techniques in coloproctology. 2014;18(5):453-8.
25. Pacheco-Barcia V, Mondejar R, Martinez-Saez O, Longo F, Moreno JA, Rogado J, Donnay O, Santander C, Carrato A, Colomer R. Safety and Oncological Outcomes of Bevacizumab Therapy in Patients With Advanced Colorectal Cancer and Self-expandable Metal Stents. Clinical colorectal cancer. 2019;18(3):e287-e93.
26. Hsu J, Sevak S. Management of Malignant Large-Bowel Obstruction. Diseases of the Colon & Rectum. 2019;62(9):1028-30.
27. Sagar J. Colorectal stents for the management of malignant colonic obstructions. Cochrane Db Syst Rev. 2011(11).
28. Dolan PT, Abelson JS, Symer M, Nowels M, Sedrakyan A, Yeo HL. Colonic Stents as a Bridge to Surgery Compared with Immediate Resection in Patients with Malignant Large Bowel Obstruction in a NY State Database. J Gastrointest Surg. 2020.

29. Berselli M, Borroni G, Livraghi L, Quintodei V, Sambucci D, Cortelezzi C, Segato S, Carcano G, Cocozza E. Laparoscopic Approach to Large Bowel Neoplastic Obstruction After Self-Expandable-Metal-Stent (SEMS) Placement. Surgical laparoscopy, endoscopy & percutaneous techniques. 2019;29(2):133-7.
30. Luchtefeld MA, Milsom JW, Senagore A, Surrell JA, Mazier WP. Colorectal anastomotic stenosis. Results of a survey of the ASCRS membership. Diseases of the colon and rectum. 1989;32(9):733-6.
31. Schlegel RD, Dehni N, Parc R, Caplin S, Tiret E. Results of reoperations in colorectal anastomotic strictures. Diseases of the colon and rectum. 2001;44(10):1464-8.
32. Weston BR, Patel JM, Pande M, Lum PJ, Ross WA, Raju GS, Lynch PM, Coronel E, Ge PS, Lee JH. Efficacy of uncovered colonic stents for extrinsic versus intrinsic malignant large bowel obstruction. Surg Endosc. 2020.
33. van Hooft JE, Fockens P, Marinelli AW, Timmer R, van Berkel AM, Bossuyt PM, Bemelman WA, Dutch Colorectal Stent G. Early closure of a multicenter randomized clinical trial of endoscopic stenting versus surgery for stage IV left-sided colorectal cancer. Endoscopy. 2008;40(3):184-91.
34. van Hooft JE, Fockens P, Marinelli AW, Bossuyt PM, Bemelman WA, Dutch Stent-In study g. Premature closure of the Dutch Stent-in I study. Lancet. 2006;368(9547):1573-4.
35. Williams D, Law R, Pullyblank AM. Colorectal stenting in malignant large bowel obstruction: the learning curve. International journal of surgical oncology. 2011;2011:917848.
36. Lee HJ, Park SJ, Cheon JH, Kim TI, Kim WH, Hong SP. What is the necessity of endoscopist for successful endoscopic stenting in patients with malignant colorectal obstruction? International journal of colorectal disease. 2015;30(1):119-25.

Tables

Table 1 Patient demographics (n/434, %)

Characteristic	**Overall (n=434)**	**BTS (n=277, 63.8%)**	**Palliative stents (n=124, 28.6%)**	**Others (n=33, 7.6%)**		
				Recurrent tumor (n=10)	benign diseases (n=10)	extra-luminal compression (n=13)
Mean Age	63.49±15.10	61.26±14.04	69.62±16.17	58.50±13.88	58.70±12.28	60.15±14.06
Gender						
male	302, 69.6%	205, 74.0%	78, 62.9%	19, 57.6%		
female	132, 30.4%	72, 26.0%	46, 37.1%	14, 42.4%		
Comorbidities						
yes	126, 29.0%	82, 29.6%	39, 31.5%	5, 15.2%		
no	308, 71.0%	195,70.4%	85, 68.5%	28, 84.8%		

Table 2 Overall clinic outcomes of stenting (n, %)

Characteristic	(434, %)
Overall technique success rate	428, 98.6%
Overall clinic success rate	412, 94.9%
Overall complication rate	19, 4.4%
Overall perforation rate	6, 1.4%
Overall emergency surgery required	21, 4.8%
Distribution area of obstruction	
Right hemicolon	33, 7.6%
Transverse colon	15, 3.5%
Left hemicolon	386, 88.9%

Table 3 Indications for stenting and tumour location respectively (n, %)

Location of obstruction	Indications
	BTS (277/434, 63.8%)
Ascending colon	5, 1.8%
Hepatic flexure	17, 6.1%
Transverse colon	6, 2.2%
Splenic flexure	22, 7.9%
Descending colon	44, 15.9%
Descending-sigmoid colon	28, 10.1%
Sigmoid colon	84, 30.3%
Recto-sigmoid colon	31, 11.2%
Rectal□1NEC□	40, 14.4%
	Palliative stents (124/434, 28.6%**)**
Ascending colon	1, 0.8%
Hepatic flexure	10, 8.1%
Transverse colon	7, 5.6%
Splenic flexure	6, 4.8%
Descending colon	18, 14.5%
Descending-sigmoid colon	5, 4.0%
Sigmoid colon	37, 29.8%
Recto-sigmoid	17, 13.7%
Rectal	23, 18.5%
	Others (33/434, 7.6%)
Recurrent tumor	10, 30.3%
Sigmoid colon	2
Rectal	8
Benign diseases	10, 30.3%
SLE	1
Anastomotic stenosis	7
Inflammatory stenosis	1
Foreign-body granuloma	1
Extra-luminal compression	13, 39.4 %
Transverse colon	1

Splenic flexure	3
Descending colon	1
Descending-sigmoid colon	1
Sigmoid colon	1
Rectal	6

Table 4 Clinic outcomes of stenting (n/N, %)

Characteristic	**Palliative stents** (n=124)	**BTS** (n=277)	**Others** (n=33)		
			Recurrent tumor (n=10)	Benign diseases (n=10)	Extra-luminal compression (n=13)
Technique success rate	121, 97.6%	274, 98.9%	10, 100%	10, 100%	13, 100%
Clinic success rate	118, 95.2%	261, 94.2%	10, 100%	10, 100%	13, 100%
Complication rate	4, 3.2%	13, 4.7%	0, 0%	2, 20%	0, 0%
Emergency surgery required	6, 4.8%	15, 5.4%	0, 0%	0, 0%	0, 0%
Subsequent surgery required	7, 5.6%	258, 93.1%	2, 20%	5, 50%	2, 15.4%
Re-stenting	2, 1.6%	2, 0.7%	0, 0%	0, 0%	0, 0%

Table 5 Clinic outcomes of BTS (258, %)

Characteristic	Number(n)	**Stoma** (n, %)	**Operation method** (n, %)		
			Laparoscopic assisted	Minilaparotomy	Open
Right hemicolectomy	23, 8.9%	0	5(1 hand assisted laparoscopy)	10	8
Transverse colon resection	3, 1.1%	0	0	0	3
Left half colon resection	83, 32.2%	1	19	23	41
Anterior resection	132, 51.2%	18	27	32	73
Subtotal colectomy	3, 1.1%	2	1	0	2
Hartmann's	10, 3.9%		3	3	4
Miles	3, 1.1%		0	0	3
Stoma	1, 0.4%	1	0	0	1
Over all	258, 100%	22, 8.5%	55, 21.3%	68, 26.4%	135, 52.3%

Figures

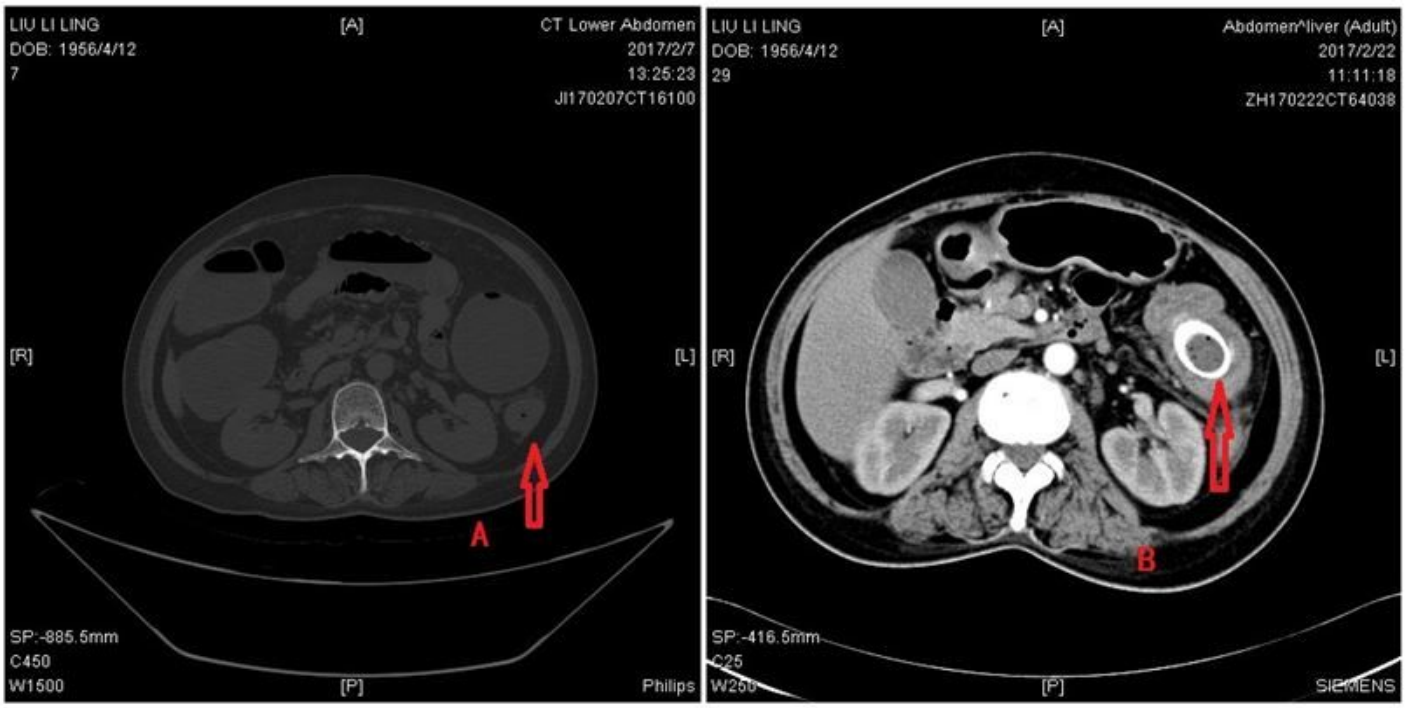

Fig.1 (a) **Fig.1 (b)**

Figure 1

Axial computed tomography images demonstrating an obstructing carcinoma with gross proximal colonic dilatation (a). After successful decompression by stenting (b).

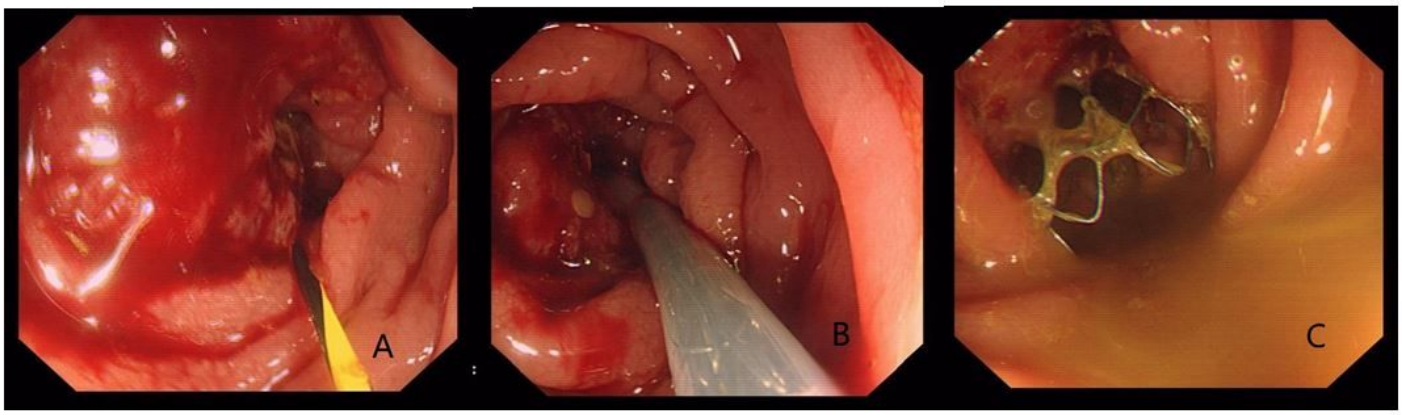

Fig.2 (a) Fig.2 (b) Fig.2 (c)

Figure 2

Flexible guide-wire pass through the obstructive lesion (a). Stent be inserted along the guide-wire across the obstruction (b). Endoscopic confirmation of appropriate stent placement, with visualisation of the distal end of the stent within a normal lumen below the tumour (c).

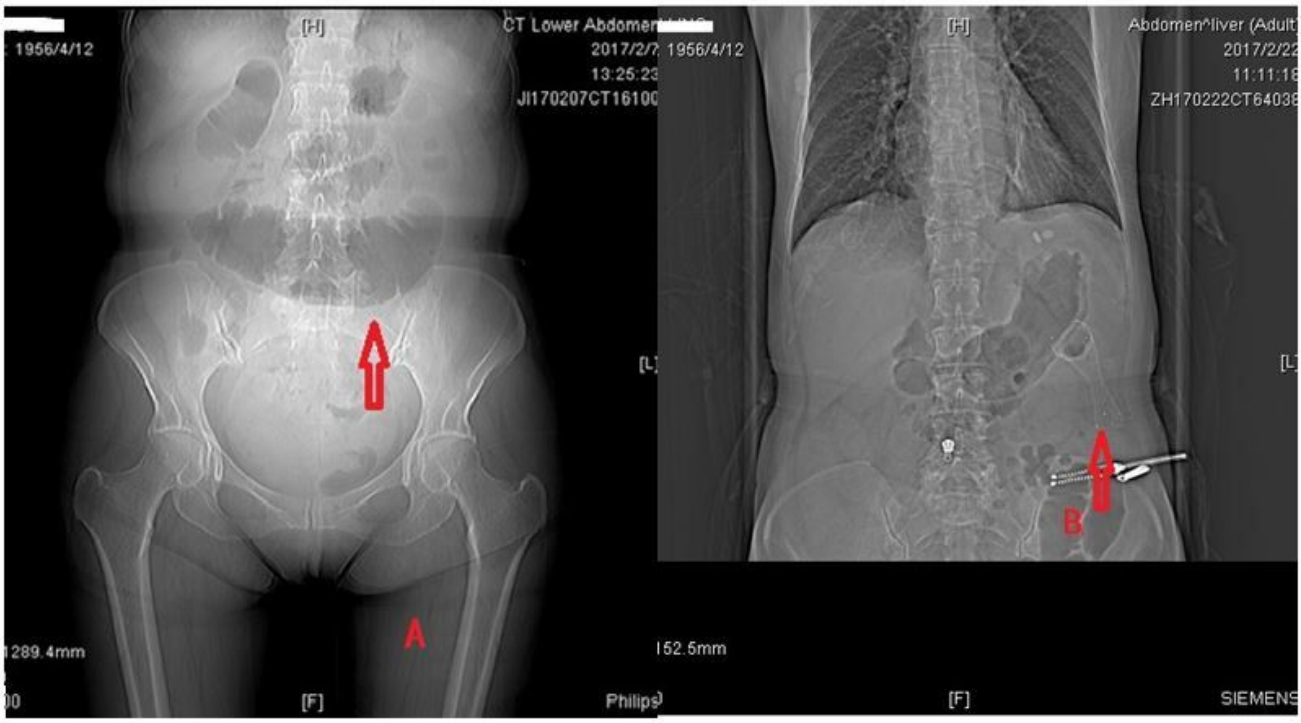

Fig.3(a) Fig.3(b)

Figure 3

Fluoroscopic image: obstructive state before stent implantation (a). Depicting the correct position and the expansion of stent (b).

Fig.4(a) Fig.4(a)

Figure 4

Mal-positioning result in stent occlusion related iatrogenic acute obstruction.

Fig.5(a) Fig.5(b) Fig.5(c) Fig.5(d)

Figure 5

Surgical incision of Left hemicolectomy by minilaparotomy operation in our center: 4-6cm incision length (a). Successful decompression without intestinal wall edema (b). Removed bowel (c). Stent in the correct position (d).

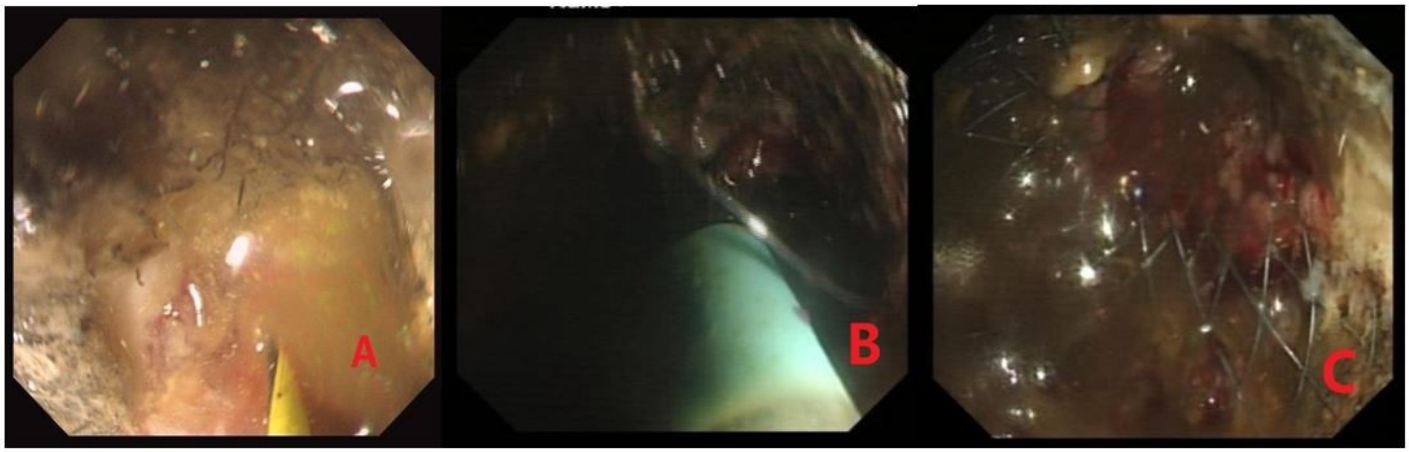

Fig.6(a) Fig.6(b) Fig.6(c)

Figure 6

Re-stent for re-obstruction caused by local tumour ingrowth: Flexible guide-wire passed through the fist stent (a). A second stent be inserted along the guide-wire across the original stent (b). State of the deployed second stent (c).