Direct Anterior Versus Anterolateral and Posterolateral Approaches to Total Hip Replacement: Comparative Accuracy of Acetabular Implant Placement and Early Clinical Outcomes

Ying-Lin Chen
China Medical University Hospital
Chi-Horng Horng
China Medical University Hospital
Shang-Lin Hsieh
China Medical University Hospital
Chin-Jung Hsu
China Medical University Hospital
Chien-Chun Chang
China Medical University Hospital
Yi-Chin Fong
China Medical University Hospital
Hsien-Te Chen
China Medical University Hospital
Li-Ting Su
China Medical University Hospital
Tsung-Li Lin
China Medical University Hospital
Chun-Hao Tsai (D7940@mail.cmuh.org.tw)
China Medical University Hospital

Research article

Keywords: Total hip arthroplasty, Direct anterior approach, Posterior approach, Anterolateral approach, Radiographic outcomes, Acetabular inclination angle

Posted Date: February 16th, 2021

DOI: https://doi.org/10.21203/rs.3.rs-241587/v1

Abstract

Background

Different surgical approaches used in total hip arthroplasty (THA) include direct anterior approach (DAA), anterolateral approach (AL), and posterolateral approach (PL). However, the acetabular cup position varies according to surgical view, surgical table, and patient position for each approach. This study is aimed to compare acetabular cup position in THA under different approaches, including surgical time, blood loss, and postoperative complications.

Methods

Between Jan 2017 and Dec 2018, 231 patients who underwent THA (64 DAA, 96 AL, and 71 PL THAs) were analyzed retrospectively. Intraoperative blood loss, operation time, preoperative and postoperative WOMAC score, cup anteversion, inclination angle, and postoperative complications were analyzed.

Results

DAA showed longer operation time and more blood loss, but shorter hospital stays. The cup was found in the safe zone for 97% of DAA patients, 74% of AL patients, and 56% of PL patients. PL showed the highest complication rate (9.9%), followed by DAA (3.1%) and AL (1%). There was no statistically significant difference in preoperative and postoperative WOMAC scores.

Conclusion

THA by DAA using a special table is a more reliable procedure to achieve safe cup position. Although DAA showed fewer outliers in cup position, it resulted in longer operation time and greater blood loss compared to other groups.

Trial registration: Retrospective study

Background

Total hip arthroplasty (THA) is one of the most successful and widely used orthopedic procedures, featuring early recovery and shorter rehabilitation [1]. Several techniques have been developed for THA, including direct anterior approach (DAA), anterolateral (AL), and posterolateral (PL) [2].

Cup alignment plays a critical role in successful THAs due to complications associated with implant impingement, bearing wear, and dislocation [3]. However, different surgical approaches influence the view cup placement. DAA for THA is an intermuscular approach with less surgical trauma, faster recovery, and more accurate prosthesis placement [4, 5]. Historically, many surgeons have performed DAA THA with or without a specific orthopedic table or intraoperative fluoroscopy. Yuya et al. compared DAA with AL and showed that the AL group had a better safe zone than the DAA group [6]. Hu et al. reported that DAA allowed better cup orientation than PL [7], while Maeda et al. found no difference in cup alignment

between DAA and PL [8]. Based on the above studies and the known advantages and disadvantages of the three surgical approaches, the ideal surgical approach for THA still remains controversial, and no direct comparisons exist in the literature. Therefore, the aim of this study was to compare and analyze differences in cup alignment among these three surgical approaches.

Methods

This study was a retrospective data using a database from the China Medical University which covered patients who underwent THA using DAA, AL and PL approaches for the period Jan 2017 to Dec 2018. We collected 231 primary THAs performed at our hospital. The inclusion criteria consisted of patients with avascular necrosis, osteoarthritis, infection, DDH and post-traumatic arthritis, such as acetabular fracture or hip fracture, and surgery performed by several experienced surgeons (12 surgeons) willing to partake in the study. Exclusion criteria consisted of prior revision surgery or cancer metastasis reconstruction. Post-operative follows up was at least one year.

The clinical evaluation retrospectively recorded operation time, blood loss, length of stay, and complications (postoperative infection, dislocation, and intraoperative fractures) for each group. Patient clinical outcomes were assessed using the Western Ontario and McMaster Universities Arthritis Index (WOMAC) which is recorded and evaluated by telephone contact all the patients one year post-operatively, imaging follow-up, and if any complications arose at one year post surgery. The modern uncemented cup (Trilogy Acetabular Hip) and M/L Taper Hip Prosthesis (Zimmer Biomet,Warsaw, IN, USA) were used for all hips.

Standing anteroposterior (AP) pelvic radiographs for hips and lateral radiographs of the proximal femur were routinely obtained on postoperative day 1 and at 3–12 months. The 3-month standing AP and lateral radiographs were used to evaluate cup inclination angle, while cup anteversion was assessed using the Cup Anteversion Inclination App (OrthoGate CC, Western Cape, South Africa) (https://itunes.apple.com/us/app/cupanteversioninclinationapp/id1448919739). The app is based on Widmer's method [9], which has been shown to be accurate compared with other methods [10]. Evaluation was performed by two independent junior orthopedic surgeons (Ying-Lin Chen and Shang Lin Hsieh) in a blinded fashion. Cup positioning within the safe zone was defined following Lewinnek et al [11], who found an increased dislocation rate in cups placed outside anteversion angles of 5°–25° and 30°–50° of inclination. Therefore, we defined this range as the safe zone and all other ranges as outliers.

The surgical approach was assessed individually by each surgeon. However, we did not use DAA for cases with deformed femoral neck-shaft, hip contracture, stiff lower lumbar spine, Crowe grade III or IV hip dysplasia, any history of hip osteotomy or osteosynthesis.

Surgical technique for minimal invasive anterolateral (AL) approach

We placed patients in a lateral decubitus position, then exposed their hip joint using the Watson-Jones interval, as suggested by Rottinger et al [12]. The anteversion and inclination of the cup were determined by aligning the guide rod [13]. Fluoroscopy was not used intraoperatively throughout this course.

Surgical technique for posterolateral (PL) approach

We first placed patients in a lateral decubitus position and then made a posterior skin incision. Tensor fascia lata, piriformis tendon, and the short external rotator muscles were released to expose the joint capsule. After assessing the direction of the femoral axis using a canal finder, femoral rasping and trial stem insertion were performed. We checked the stability and lower limb length without fluoroscopy. Cup anteversion and inclination were assessed using a mechanical acetabular alignment guide rod [13]. After cup and stem insertion, the muscle-capsular flap and short external rotators were repaired as suggested by Pellicci et al [14].

Surgical technique for direct anterior approach

All DAA patients were placed in a supine position on the Judet-type orthopedic table (Hana table, OSI, USA) and intraoperative fluoroscopy was used for confirmation of the following steps: final acetabular reaming, acetabular cup placement, trial stem insertion, confirmation of leg length discrepancy after temporary reduction, and final implant placement, as suggested by Matta et al. and Nakamura et al [4, 15].

Statistical analysis

We compared implant alignment and clinical outcomes among DAA, AL, and PL groups. Data are presented as raw numbers and percentage (%), mean (SD), or odds ratio (OR), with 95% confidence interval (CI) where applicable. Continuous scales were compared with a one-way ANOVA followed by Scheffe's post hoc test and categorical variables were compared with a Fisher’s exact probability test. A univariate logistic regression was performed to estimate the odds ratio of cup alignment in the safe zone among all groups. SAS version 9.4 (SAS Institute, Cary, NC, USA) was used for all analyses. A two-sided P value < 0.05 was considered statistically significant.

Results

We assessed 121 females and 110 males. The mean age at surgery was 60.2 years old (range: 20–92 years). The primary diagnosis was osteoarthritis in 139 cases, osteonecrosis in 68 cases, rheumatoid arthritis in 15 cases, traumatic arthritis in 7 cases, and Crowe type III/IV in 2 cases. DAA, AL, and PL were used for 64, 96, and 71 patients, respectively. The patient’s demographic data, BMI, perioperative factor, and outcome for these different approaches are shown in Table 1.

Table 1
Preoperative demographic data.

	DAA group (64 hips)	AL group (96 hips)	PL group (71 hips)	
Characteristic	n (%)	n (%)	n (%)	P-value
Age (year), mean (SD)	58.4 (13.7)	58.4 (17.0)	64.3 (13.9)	0.0271[a]
Gender, n (%)				
Male	34 (53.1)	53 (55.2)	23 (32.4)	0.0136 [b]
Female	30 (46.9)	43 (44.8)	48 (67.6)	
Diagnosis, n (%)				
Osteoarthritis	52 (81.2)	49 (51.0)	38 (53.5)	0.0034 [b]
Osteonecrosis	11 (17.2)	30 (31.3)	27 (38.0)	
Rheumatoid arthritis	1 (1.6)	14 (14.6)	0 (0)	
Post hip /acetabular traumatic arthritis	0 (0)	3 (3.1)	4 (5.6)	
Crowe type III/IV	0 (0)	0 (0)	2 (2.8)	
Major Complication, n (%)				0.0473 [b]
Yes	2 (3.1)	1 (1.0)	7 (9.9)	
Deep periprosthetic joint infection	0	0	2	
Greater trochanteric fracture	0	0	1	
Calcar fracture	1	1	2	
Postoperative dislocation	0	0	1	
Post-operative femoral fracture	1	0	0	
Leg length discrepancy (> 2cm)	0	0	2	

1. Values are given as the mean (standard deviation) or number (percentage)

2. DAA direct anterior approach, AL anterolateral approach, PL posterolateral approach

3. Hip Western Ontario and McMaster Universities Arthritis Index (WOMAC)

4. [a] One way ANOVA followed by Scheffe's post hoc test

5. [b] Fisher’s exact probability test

	DAA group (64 hips)	AL group (96 hips)	PL group (71 hips)	
No	62 (96.9)	95 (99.0)	64 (90.1)	
BMI, mean(SD)	24.3(4.4)	25.0(4.8)	25.2(4.2)	0.5014
Op time (min), mean (SD)	115.6 (31.1)	110.3 (37.1)	105.7 (21.2)	0.1930[a]
Blood lost (ml), mean (SD)	407.4 (304.0)[1,2;1,3]	301.4 (246.8)[2,1]	249.7 (129.0)[3,1]	0.0007[a]
Length of stays (day), mean (SD)	5.0 (2.8)[1,2;1,3]	7.7 (2.3)[2,1]	7.4 (2.4)[3,1]	< 0.0001[a]
Pre-operative WOMAC	86.6 (10.3)	86.2 (2.8)	86.4 (2.7)	0.9626[a]
Post-operative WOMAC	22.1 (9.7)[1,3]	27.4 (16.1)	30.3 (12.9) [3,1]	0.0015[a]
1. Values are given as the mean (standard deviation) or number (percentage)				
2. DAA direct anterior approach, AL anterolateral approach, PL posterolateral approach				
3. Hip Western Ontario and McMaster Universities Arthritis Index (WOMAC)				
4. [a] One way ANOVA followed by Scheffe's post hoc test				
5. [b] Fisher's exact probability test				

Operation time

The mean procedure duration was 115.6 minutes (range: 71–270 min) in the DAA group, 110.3 minutes (range: 67–231 min) in the AL group, and 105.7 minutes (range: 74–185 min) in the PL group (p = 0.193). Although not statistically significant, the mean surgical time in the DAA group was greater than in the other groups (Table 1).

Blood loss

Mean intraoperative blood loss was 407.4 mL (range: 50–1600 mL) in the DAA group, 301.4 mL (range: 50–1500 mL) in the AL group, and 249.7 mL (range: 50–600 mL) in the PL group (p = 0.0007; Table 1). Patients in the DAA group showed the most blood loss, while the PL group showed the least. There were 19 patients in the DAA group, 20 patients in the AL group, and 6 patients in the PL group with blood loss greater than 500 mL.

Hospitalization

The mean length of hospital stay was 5.0 days in the DAA group (range: 3–23 days), 7.7 days in the AL group (range: 6–22 days), and 7.4 days in the PL group (range: 5–19 days). The length of hospital stay

was significantly shorter in the DAA group ($p < 0.0001$; Table 1).

Clinical outcomes

Preoperative WOMAC scores were similar among groups, indicating no statistically significant differences. The mean duration of the procedure was 115.6 minutes (range: 71–270 min) in the DAA group, 110.3 minutes (range: 67–231 min) in the AL group and 105.7 minutes (range: 74–185 min) in the PL group ($p = 0.193$). There was no statistically significant difference in WOMAC scores clinical outcome between the DAA group and the PL, AL group. However, there was lower outcome in PL than in DAA group (Table 1).

Complications

We found two periprosthetic joint infections, one greater trochanteric fracture, two calcar fractures, one postoperative dislocation, one post-operative femoral fracture, and two symptomatic leg length discrepancies. For overall complication rate, PL showed the highest complication rate (9.9%), followed by DAA (3.1%) and AL (1%) groups had the least (Table 1). The larger complication rate in the PL group may be due to patients that were older, more likely to be female, had more traumatic arthritis, and more complicated Crowe type deformity compared with other groups.

Cup position

The mean inclination angle of the acetabular cup was 40.7° (range: 30°–49°) in the DAA group, 37.7° (range: 25°–58°) in the AL group, and 41.2° (range: 25°–62°) in the PL group. Inclination angles were significantly higher in DAA and PL groups compared with the AL group. The mean anteversion angle of the acetabular cup was 16.6° (range: 9°–29°) in the DAA group, 19.8° (range: 7°–33°) in the AL group, and 24.4° (range: 10°–39°) in the PL group ($p < 0.0001$). Anteversion angles were significantly different among all groups ($p < 0.001$; Table 2). The cup was in the safe zone in 96.7% of the DAA group, 74% of the AL group, and 56.3% of the PL group.

Table 2
Post-operative data and implant alignment.

	DAA group[1] (64 hips)	**AL group[2] (96 hips)**	**PL group[3] (71 hips)**		**Post hoc test**
Variable	Mean (range)	Mean (range)	Mean (range)	P-value	
Cup alignment					
Inclination angle (°)	40.7 (30–49)	37.7 (25–58)	41.2 (25–62)	0.0008	2 vs. 1 2 vs. 3
Anteversion angle (°)	16.6 (9–29)	19.8 (7–33)	24.4 (10–39)	< 0.0001	1 vs.2 1 vs.3 2 vs.3
DAA, direct anterior approach; AL, anterolateral approach; PL, posterolateral approach					

Table 3 presents the odds ratio and 95% confidence intervals for cup alignment in the safe zone associated with all groups. Compared with DAA group, AL group had the odds ratio of 2.2 out of the safe zone (95% CI 1.1–4.2). Furthermore, the odds ratio of PL group falling outside the safe zone was 24 (95% CI 5.4–106.0).

Table 3
Risk of outlier in different THA approaches according to the Lewinnek's safe zone of cup position.

	Cup positioning outside the safe zone (Inlier vs. Outlier)		
Variable	OR	(95% CI)	P-value
Group			
DAA group	1.0	(reference)	
AL group	10.9	(2.5–48.0)	0.0015
PL group	24.0	(5.5–106.0)	< 0.0001
Safe zone: Inclination angle (30°–50°) and anteversion angle (5°–25°).			
Data were analyzed by univariate logistic regression.			

Discussion

Our study indicates that DAA with a special table was a reliable approach to reduce variation in cup position during inclination, anteversion angle, and comparing lateral lying in PL and AL approaches. Acetabular component anteversion may vary among surgical approaches. Variable cup position for AL or PL approaches may be due to the floppy and tiling lateral lying posture. The lateral lying position is the most common position during THA surgery and the patient should be well fixed to limit intraoperative motion. However, it is difficult to accurately measure pelvic direction on the table [16]. Schwarzkopf et al. found that intraoperative roll resulted in implant placement outside the safe zone [17–19]. The supine position can provide a more predictable pelvic orientation, particularly when using fluoroscopy to check the position of the pelvis and acetabular implants during surgery. Further, the acetabular alignment guide is not always accurate [20, 21]. Minoda et al. tested 15 alignment guides from 7 manufacturers and found that alignment guides can decrease cup anteversion (mean of 6° and maximum of 12°) and increase cup abduction angle (mean of 2° and maximum of 4°) [22].

We assessed DAA-THA using both a specific orthopedic table and standard operation table. A systematic review conducted by Sarraj et al [23] that collected 44 studies concluded that specific orthopedic tables and standard operation tables present similar outcomes and complications. However, intraoperative blood loss, surgical time, and intra-operative fracture rate were greater in the specific orthopedic table group than in the standard operation table group [23].

Intraoperative fluoroscopy may play a critical role in influencing cup position. Goodman et al. [24] showed cup position in DAA-THA results in lower cup angle variation in groups with intraoperative fluoroscopy compared to those without. Another study established by Joshua et al. evaluated acetabular cup position and limb length discrepancy in 265 patients who underwent surgery with or without fluoroscopy and found no significant difference in acetabular inclination, anteversion, and postoperative limb length discrepancy (LLD) between the two DAA-THA groups [24].However, due to immediate feedback of final acetabular reaming, acetabular cup placement, trial stem insertion, confirmation of leg length discrepancy after temporary reduction, and final implant placement, we consider intraoperative fluoroscopy has significant influence in the variation of cup alignment in our study, and it may explain why prolonged surgical time in DAA at the same time.

A previous study found that DAA was associated with a larger percentage of acetabular cups placed within the “safe” zone of alignment when using fluoroscopy [25], which corroborates our findings. However, there is no clear hierarchy in clinical outcomes of surgical approaches to THA. Current evidence comparing outcomes with anterior versus posterior THA demonstrates no clear superiority of either approach. A multi-center prospective cohort study by Meneghini et al. tested whether surgical approach was associated with early THA failure [26]. They found that early femoral component loosening was commonly associated with DAA and direct lateral approaches compared with the posterior approach. Although the differences were not significant, early femoral periprosthetic fractures were more common with DAA than posterior and direct lateral approaches [27]. Anterolateral approach showed fewer

dislocation rate than posterolateral approach, but due to violation of abductor mechanism, patients who underwent AL may lead to postoperative limp [28]. Due to above, each approaches have pros and cons, preoperative evaluation to choose suitable approach for patients is required. In our study, there were fewer fracture occurrence which may be due to the continuous intraoperative fluoroscopy which also lengthens DAA surgery time.

Based on Lewinnek et al. defined the safe zone of cup alignment, the dislocation rate increases while cup alignment anteversion over 5°–25° and 30°–50° of inclination [28]. Besides, some studies have demonstrated increased linear wearing rate, impingement and limited range of motion if cup alignment surpass the safe zone [11, 29], which may have influence on patients' daily activities and quality of life; However, in our study, although with more outliers in AL and PL groups, the WOMAC score after one year follow up did not show significantly difference, further follow up may be needed for analysis.

DAA used intermuscular plane to approach femoral head, and should have lesser blood loss. But in our study, DAA demonstrated most blood loss. Yonghan et al. collected several studies that also found the same outcome in DAA compared with PL or AL [30], and this may be due to huge anterior capsulectomy or unintentionally detachment of surrounding soft tissue. So experienced surgeons can improve THA surgery procedures, including exposure of the acetabulum and femur [31]. And an effective team familiar with the workflow, a stable position during operation, intraoperative imagery, such as fluoroscopy or navigation to confirm implant position, and checkpoints for each surgical procedure can improve outcomes and reduce complications in hip arthroplasty.

A limitation of this study was that it was retrospective. Besides, within the same group of surgeons, biased patient selection, lack of randomness, and varying learning curves in surgical techniques among different surgeons may have biased our results. For complex femoral or acetabular deformity, we chose the PL approach. Many professionals argue that posterior capsulectomy causes posterior dislocation, while skilled repairing of the capsule can lower dislocation rate [32]. Our data are somewhat contradictory to this notion since only one dislocation occurred in our group. Finally, our follow-up period was one year, which is relatively short to identify definitive long-term outcomes.

Conclusion

We conclude that muscle-preserving THA by DAA using a special table is a reliable procedure for achieving safe cup position. Compared with AL or PL, DAA showed fewer outliers regarding cup position. However, DAA requires longer operation time and causes greater blood loss than AL or PL approaches. We found no statistical difference in overall postoperative results and complications in short term follow-up.

Abbreviations

THA: Total hip arthroplasty; DAA: Direct anterior approach; AL: Anterolateral approach; PL: Posterolateral approach; DDH: Developmental dysplasia of hip; AP: Anteroposterior; SD: Standard deviation; OR: Odds

ratio; CI: Confidence interval; ANOVA: Analysis of variance; LLD: Limb length discrepancy; WOMAC: Western Ontario and McMaster Universities Osteoarthritis Index

Declarations

Acknowledgements

This study was supported in part by the Taiwan Ministry of Health and Welfare Clinical Trial Center (MOHW1098-TDU-B-212-11433004). We would like to thank Uni-edit (www.uni-edit.net) for editing and proofreading this manuscript.

Authors' contributions

YLC and CHH contributed to data collection and writing the manuscript. TLL and CHT contributed to the study design. CHH , YCF, HTC, TLL, and CHT performed the surgery. LTS contributed to the acquisition of the data. SLH, CCC, and CJH contributed to writing the manuscript. All authors have read and approved the final manuscript.

Funding

This research received no specific grant from any funding agency in the public, commercial, or not-for-profit sectors.

Availability of data and materials

The dataset supporting the conclusions of this article is included within the article.

Ethics approval and consent to participate

This retrospective study was approved by the local IRB/Research Ethics Committee, CMUH104-REC2-115.

Consent for publication

All authors agreed to the publication of this article.

Competing interests

The authors declare that they have no competing interests.

References

1. Higgins BT, Barlow DR, Heagerty NE, Lin TJ. Anterior vs. posterior approach for total hip arthroplasty, a systematic review and meta-analysis. J Arthroplasty. 2015;30(3):419–34.
2. Moretti VM, Post ZD. Surgical Approaches for Total Hip Arthroplasty. Indian J Orthop. 2017;51(4):368–76.

3. Shon WY, Baldini T, Peterson MG, Wright TM, Salvati EA. Impingement in total hip arthroplasty a study of retrieved acetabular components. J Arthroplasty. 2005;20(4):427–35.
4. Matta JM, Shahrdar C, Ferguson T. Single-incision anterior approach for total hip arthroplasty on an orthopaedic table. Clin Orthop Relat Res. 2005;441:115–24.
5. Jewett BA, Collis DK. High complication rate with anterior total hip arthroplasties on a fracture table. Clin Orthop Relat Res. 2011;469(2):503–7.
6. Kawarai Y, Iida S, Nakamura J, Shinada Y, Suzuki C, Ohtori S. Does the surgical approach influence the implant alignment in total hip arthroplasty? Comparative study between the direct anterior and the anterolateral approaches in the supine position. Int Orthop. 2017;41(12):2487–93.
7. Hu F, Shang X, Zhang X, Chen M. Direct anterior approach in lateral position achieves superior cup orientation in total hip arthroplasty: a radiological comparative study of two consecutive series. Int Orthop. 2020;44(3):453–9.
8. Maeda Y, Sugano N, Nakamura N, Hamawaki M. The Accuracy of a Mechanical Cup Alignment Guide in Total Hip Arthroplasty (THA) Through Direct Anterior and Posterior Approaches Measured with CT-Based Navigation. J Arthroplasty. 2015;30(9):1561–4.
9. Widmer K-H. A simplified method to determine acetabular cup anteversion from plain radiographs. J Arthroplast. 2004;19(3):387–90.
10. Nomura T, Naito M, Nakamura Y, Ida T, Kuroda D, Kobayashi T, Sakamoto T, Seo H. An analysis of the best method for evaluating anteversion of the acetabular component after total hip replacement on plain radiographs. Bone Joint J. 2014;96-B(5):597–603.
11. Lewinnek GE, Lewis JL, Tarr R, Compere CL, Zimmerman JR. Dislocations after total hip-replacement arthroplasties. The Journal of bone joint surgery American volume. 1978;60(2):217–20.
12. Bertin KC, Röttinger H. Anterolateral Mini-incision Hip Replacement Surgery: A Modified Watson-Jones Approach. Clinical Orthopaedics Related Research®. 2004;429(429):248–55.
13. DeChenne CL, Jayaram U, Lovell T, Dong N, Cusick M. A novel acetabular alignment guide for THR using selective anatomic landmarks on the pelvis. Journal of biomechanics. 2005;38(9):1902–8.
14. Pellicci PM, Bostrom M, Poss R. Posterior approach to total hip replacement using enhanced posterior soft tissue repair. Clinical Orthopaedics and Related Research (1976–2007). 1998; 355:224–228.
15. Nakamura J, Hagiwara S, Orita S, Akagi R, Suzuki T, Suzuki M, Takahashi K, Ohtori S. Direct anterior approach for total hip arthroplasty with a novel mobile traction table -a prospective cohort study. BMC Musculoskelet Disord. 2017;18(1):49.
16. Bhandari M, Matta JM, et al. Outcomes following the single-incision anterior approach to total hip arthroplasty: a multicenter observational study. The Orthopedic clinics of North America. 2009;40:329–42.
17. MCCOLLUM DE and GRAY WJ. Dislocation after total hip arthroplasty causes and prevention. Clinical Orthopaedics Related Research®. 1990;261:159–70.

18. Schwarzkopf R, Muir JM, Paprosky WG, et al. Quantifying pelvic motion during total hip arthroplasty using a new surgical navigation device. The Journal of Arthroplasty. 2017;32:3056–60.
19. Asayama I, Akiyoshi Y, Naito M, et al. Intraoperative pelvic motion in total hip arthroplasty. J Arthroplast. 2004;19:992–7.
20. Blondel B, Parratte S, Tropiano P, et al. Pelvic tilt measurement before and after total hip arthroplasty. Orthopaedics Traumatology: Surgery Research. 2009;95:568–72.
21. DiGioia AM III, Jaramaz B, Plakseychuk AY, et al. Comparison of a mechanical acetabular alignment guide with computer placement of the socket. J Arthroplast. 2002;17:359–64.
22. Minoda Y, Ohzono K, Aihara M, et al. Are acetabular component alignment guides for total hip arthroplasty accurate? J Arthroplast. 2010;25:986–9.
23. Sarraj M, Chen A, Ekhtiari S, et al. Traction table versus standard table total hip arthroplasty through the direct anterior approach: a systematic review. Hip Int. 2020;30:662–72.
24. Goodman GP, Goyal N, Parks NL, et al. Intraoperative fluoroscopy with a direct anterior approach reduces variation in acetabular cup abduction angle. Hip Int. 2017;27:573–7.
25. Bingham JS, Spangehl MJ, Hines JT, et al. Does Intraoperative Fluoroscopy Improve Limb-Length Discrepancy and Acetabular Component Positioning During Direct Anterior Total Hip Arthroplasty? J Arthroplasty. 2018;33:2927–31.
26. Rathod PA, Bhalla S, Deshmukh AJ, et al. Does fluoroscopy with anterior hip arthroplasty decrease acetabular cup variability compared with a nonguided posterior approach? Clin Orthop Relat Res. 2014;472:1877–85.
27. Meneghini RM, Elston AS, Chen AF, et al. Direct Anterior Approach: Risk Factor for Early Femoral Failure of Cementless Total Hip Arthroplasty: A Multicenter Study. The Journal of bone joint surgery American volume. 2017;99:99–105.
28. Ritter MA, Harty LD, Keating ME, et al. A clinical comparison of the anterolateral and posterolateral approaches to the hip. Clin Orthop Relat Res. 2001: 95–99.
29. Hirakawa K, Mitsugi N, Koshino T, et al. Effect of acetabular cup position and orientation in cemented total hip arthroplasty. Clin Orthop Relat Res. 2001: 135–142.
30. Patil S, Bergula A, Chen PC, et al. Polyethylene wear and acetabular component orientation. J Bone Joint Surg Am. 2003; 85-A Suppl 4: 56–63.
31. Cha Y, Yoo JI, Kim JT, et al. Disadvantage during Perioperative Period of Total Hip Arthroplasty Using the Direct Anterior Approach: a Network Meta-Analysis. J Korean Med Sci. 2020;35:e111.
32. Tarasevicius S, Robertsson O, Wingstrand H. Posterior soft tissue repair in total hip arthroplasty: a randomized controlled trial. Orthopedics. 2010;33:871.

Figures

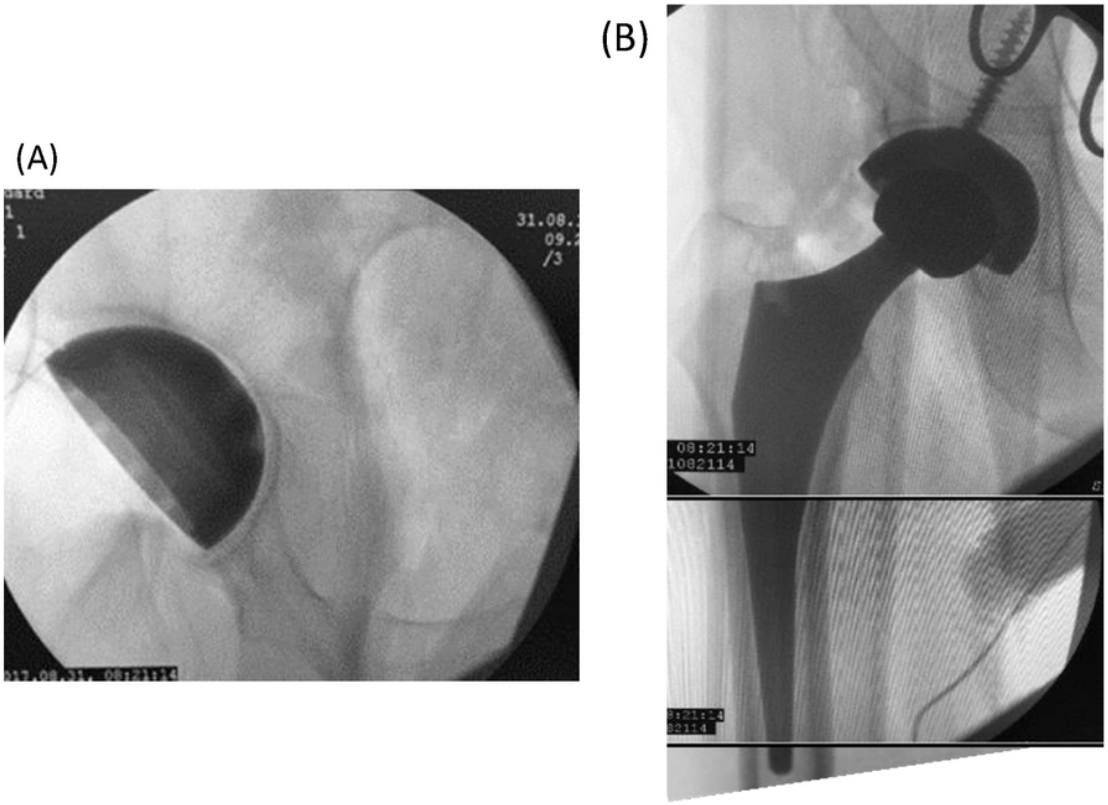

Figure 1

DAA-THA applied fluoroscopy to identify cup position alignment intraoperatively. (A) Checking alignment after stem insertion and awareness of peritrochanteric fracture or over stem tip after stem insertion (B).

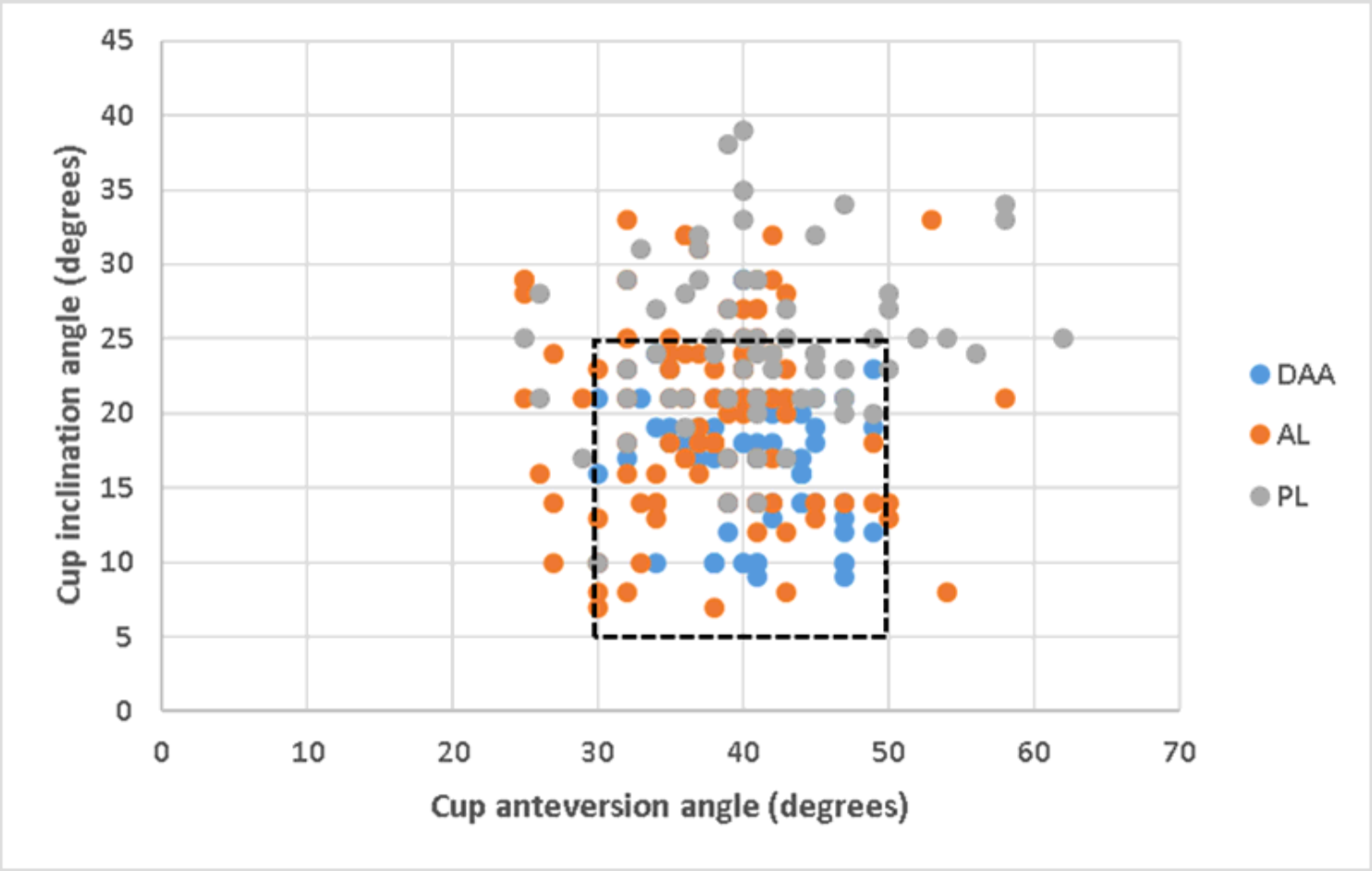

Figure 2

Scatterplot of cup alignment in AL, PL, and DAA groups. Square box with dotted lines reflects Lewinnek's safe zone. The outsider cup was 43% in the PL group, 26% in the AL group, and 2% in the DAA group, according to the safe zone ($p < 0.001$). Fisher's exact probability test was used to calculate the p-value.