A Significant Correlation Between Osteoarthritis of the Atlantoaxial Facet Joint and a High-riding Vertebral Artery

Tomoaki Shimizu (tomoaki.shimizu.96@gmail.com)
Department of Orthopedic Surgery, Faculty of Medicine, University of Tsukuba

Masao Koda
Department of Orthopedic Surgery, Faculty of Medicine, University of Tsukuba

Tetsuya Abe
Department of Orthopedic Surgery, Faculty of Medicine, University of Tsukuba

Yosuke Shibao
Department of Orthopedic Surgery, Faculty of Medicine, University of Tsukuba

Mamoru Kono
Department of Orthopedic Surgery, Faculty of Medicine, University of Tsukuba

Fumihiko Eto
Department of Orthopedic Surgery, Faculty of Medicine, University of Tsukuba

Kosei Miura
Department of Orthopedic Surgery, Faculty of Medicine, University of Tsukuba

Kentaro Mataki
Department of Orthopedic Surgery, Faculty of Medicine, University of Tsukuba

Hiroshi Noguchi
Department of Orthopedic Surgery, Faculty of Medicine, University of Tsukuba

Hiroshi Takahashi
Department of Orthopedic Surgery, Faculty of Medicine, University of Tsukuba

Toru Funayama
Department of Orthopedic Surgery, Faculty of Medicine, University of Tsukuba

Masashi Yamazaki
Department of Orthopedic Surgery, Faculty of Medicine, University of Tsukuba

---

Research Article

Keywords: High riding vertebral artery, prevalence, subaxial cervical spine surgery, C2 pedicle screw, posterior instrumentation surgery, osteoarthritis of C1/2 facet joints

Posted Date: March 9th, 2021

DOI: https://doi.org/10.21203/rs.3.rs-243596/v1

Abstract

Background A high-riding vertebral artery (HRVA) is an intraosseous anomaly that narrows the trajectory for C2 pedicle screws. The prevalence of a HRVA is high in patients who need surgery at the craniovertebral junction, but reports about HRVAs among subaxial cervical spine disorders are limited. We sought to determine the prevalence of HRVAs among patients with subaxial cervical spine disorders to elucidate the potential risk for VA injury in subaxial cervical spine surgery.

Methods We included 215 patients, 94 were with a main lesion from C3 to C7 (subaxial group) and 121 were with a main lesion from T1 to L5 (thoracolumbar group). A HRVA was defined as a maximum C2 pedicle diameter of <3.5mm on axial CT. The sex, age of patients, body mass index (BMI), osteoarthritis of the atlantoaxial (C1/2) facet joints and prevalence of a HRVA in the 2 groups were compared and logistic regression was used to identify the factors correlate with a HRVA.

Results The patients of subaxial group were younger than those of the thoracolumbar group but the sex and BMI didn't differ significantly between the 2 groups. The osteoarthritis grade of C1/2 facet joints of the subaxial group was statistically higher than the thoracolumbar group. A HRVA was found in 26 patients of 94 (27.7 %) in the subaxial group and in 19 of 121 (15.7%) in the thoracolumbar group. The prevalence of a HRVA in the subaxial group was statistically higher and logistic regression analysis indicated that osteoarthritis of C1/2 facet joints significantly correlated with HRVA.

Conclusions The prevalence of a HRVA in patients with subaxial cervical spine disorders is higher than in those without cervical spine disorders, and osteoarthritis of C1/2 facet joints significantly correlated with a HRVA.

Background

Cervical pedicle screws (CPSs) have enabled us to perform rigid internal fixation [1]. In particular, PS for the axis (C2 PS) have been used more frequently because they are the most feasible and reliable anchor for posterior instrumentation surgery in the cervical spine. However, they have to be applied carefully because of the possibility of injury to the vertebral artery (VA) caused by the misposition of a CPS, which could develop into serious complications, such as cerebellar infarction or brain stem infarction [2]. Thus, it is very important to evaluate the course of the VA preoperatively and select appropriate instruments for surgery.

A high riding vertebral artery (HRVA) is an intraosseous anomaly that unusually courses too medially, too posteriorly, and/or too superiorly at the isthmus of C2, resulting in narrowing of the trajectory for C2 PS. There is a significantly higher risk of VA injury by C2 PS insertion in patients with a HRVA [3]. The prevalence of a HRVA is high in surgery at the craniovertebral junction [4] and it is already known that rheumatoid arthritis (RA) is a risk factor of a HRVA [5-6]. However, the number of reports of a HRVA among patients with subaxial cervical spine disorders is limited despite posterior fixation is frequently performed for subaxial cervical spine including C2. The aim of this study was to determine the prevalence

of HRVAs among patients with subaxial cervical spine disorders to elucidate the potential risk for VA injury in subaxial cervical spine surgery and to investigate the risk factors for a HRVA.

Material And Methods

We analyzed the medical records of 325 consecutive patients who underwent subaxial cervical spine surgery (subaxial group) and who underwent myelography for thoracolumbar disorders (thoracolumbar group) at our institute from December 2012 to June 2020. The study's protocol was approved by the institutional review board and informed consent was obtained from all participants. The subaxial group included those with their main lesion from C3 to C7, and the thoracolumbar group included those with their main lesion from T1 to L5. In both groups, those with rheumatoid arthritis and congenital skeletal anatomy were excluded because they had been already known as risk factors of a HRVA. In addition, those with pyogenic spondylitis, spinal tumor, spinal injury, and patients with previous cervical spine surgery were excluded (39 patients in the subaxial group and 71 patients in the thoracolumbar group, Figure 1).

Ultimately, the subaxial group included 94 patients (67 men, 27 women, mean age 61.9 years) and the thoracolumbar group included 121 patients (71 men, 50 women, mean age 67.1 years).

The subaxial group included 48 patients with ossification of the posterior longitudinal ligament (OPLL), 38 with cervical spondylosis, 3 with cervical spondylotic radiculopathy, 3 with cervical spine kyphosis, and 2 with cervical spondylotic amyotrophy. The surgical method in the subaxial group was posterior fixation including C2 (46 patients), posterior fixation above C3 (25 patients), anterior fusion (16 patients), and posterior laminoplasty without fixation (7 patients). In 46 patients who underwent posterior fixation including C2, the instruments used for C2 were as follows: PS was applied bilaterally to 20 patients, unilaterally to 2 patients, PS and laminar screw on each side to 21 patients, pars screw and laminar screw on each side to 2 patients, and laminar screw bilaterally to 1 patient.

The thoracolumbar group included 82 patients with lumbar spinal canal stenosis, 17 with degenerative lumbar kyphoscoliosis, 15 with thoracic ossification of the yellow ligament (OYL), and 7 with thoracic spondylotic myelopathy.

We performed preoperative 3-dimensional computed tomographic angiography (3D CTA) for all the patients in the subaxial group and CT myelography for all the patients in the thoracolumbar group. For all the patients in each group, we searched for HRVAs in axial slices (1 mm of thickness) that were along the orthogonal horizontal plane (Figure 2). We defined a HRVA as a maximum C2 pedicle diameter of <3.5 mm on the axial image, because the minimal diameter of the commonly used screw is 3.5 mm.

In addition, we evaluated osteoarthritis of the atlantoaxial (C1/2) facet joints in coronal plane of CT of all the patients in each group. Assessment of facet joint osteoarthritis was carried out with a grading scale as described previously [8,9]. Grade 0 indicates a normal facet joint, grade 1 shows joint space narrowing,

grade 2 shows narrowing and sclerosis of facet joint, and grade 3 shows narrowing, sclerosis and osteophytes (Figure 3).

The sex, age of patients, body mass index (BMI), osteoarthritis grade of C1/2 facet, and prevalence of a HRVA in the 2 groups were compared using an unpaired Student *t* test, a Pearson χ^2 test and a Mann-Whitney U test as appropriate. Logistic regression was used to identify the risk factor for a HRVA. Age, sex, BMI, and osteoarthritis grade of C1/2 facet joints were added as independent variables for multiple logistic regression analysis. Statistical significance was considered established at $p < 0.05$ and all the analyses were performed using IBM SPSS Statistics for Windows (version 26.0).

The instruments used for C2 pedicles with a HRVA in the subaxial group were analyzed. For all the patients in the subaxial group, we analyzed neurovascular injury as a complication of surgery derived from screw insertion.

Results

The age of the patients differed significantly between the 2 groups, but the sex ratio and BMI did not differ significantly between the 2 groups (Table 1).

As to osteoarthritis of the atlantoaxial (C1-2) facet joints, of 94 patients in the subaxial group, 17 patients presented with grade 0 (18.1 %), 24 with grade 1 (25.5 %), 45 with grade 2 (47.9 %), and 8 with grade 3 (8.5 %). Of 121patients in the thoracolumbar group, 24 patients presented with grade 0 (19.8 %), 46 with grade 1 (38.0 %), 47 with grade 2 (38.8 %), and 4 with grade 3 (3.3 %). When we compare osteoarthritis grades between the subaxial group and the thoracolumbar group, the osteoarthritis grade of the subaxial group was statistically higher than the thoracolumbar group ($p = 0.037$; Table 1).

In 45 (20.9 %) of the 215 patients, a HRVA was detected. Of 94 patients in the subaxial group, 26 (27.7 %) had a HRVA. Of 121 patients in the thoracolumbar group,19 (15.6 %) had a HRVA. The prevalence of a HRVA in patients in the subaxial group was statistically higher than in the thoracolumbar group ($p = 0.033$; Table 1).

Table 1

Data summary for patients in the subaxial and thoracolumbar groups

	subaxial group (94 patients)	thoracolumbar group (121 patients)	p value
sex †	male 67 female 27	male 71 female 50	0.06
age †	61.9±11.1	67.1±10.2	0.001*
BMI †	25.6±5.8	24.8±4.5	0.29
diagnosis	cervical OPLL 48 cervical spondylosis 38 cervical spondylotic radiculopathy 3 cervical spine kyphosis 3 cervical spondylotic amyotrophy 2	lumbar spinal canal stenosis 82 degenerative lumbar kyphoscoliosis 17 thoracic OYL 15 thoracic spondylotic myelopathy 7	
OA grade of C1/2 facet joints†	Grade 0 17 Grade 1 24 Grade 2 45 Grade 3 8	Grade 0 24 Grade 1 46 Grade 2 47 Grade 3 4	0.037*
HRVA †	26 cases (27.7 %)	20 cases (15.6 %)	0.033*

†Sex and the prevalence of a high-riding vertebral artery (HRVA) were compared using a Pearson χ^2 test. Age and BMI were compared using an unpaired Student *t* test. OA grade of C1/2 facet joints was compared using a Mann-Whitney U test.

*$p < 0.05$

BMI: body mass index

OPLL: ossification of the posterior longitudinal ligament

OYL: ossification of the yellow ligament

OA: osteoarthritis

Multiple logistic regression indicated that the osteoarthritis of C1/2 facet joints was a significant risk factor for a HRVA (odds ratio1.66, 95% confidence interval 1.05-2.63, $p = 0.031$; Table 2).

Table 2

Multiple logistic regression of risk factors for a high-riding vertebral artery (HRVA)

variable †	odds ratio	95% confidence interval	p value
sex (female: male)	1.19	0.59 -2.34	0.64
age	0.98	0.95 -1.02	0.36
BMI	0.98	0.91-1.05	0.53
OA grade of C1/2 facet joints	1.82	1.17-2.84	0.008*

†For this analysis, male = 0 and female = 1

*$p < 0.05$

BMI: body mass index

OA: osteoarthritis

For those with a HRVA in the subaxial group (31sides of 26 patients), 9 sides had a laminar screw inserted, and in 22 sides no screw was inserted (Table 3). No PS was applied to those with a HRVA. No neurovascular injury derived from screw insertion occurred in any patient.

Table 3

Data for instruments used for the C2 pedicle in patients with a HRVA (31 sides of 26 patients)

instrument		
pedicle screw	0	
laminar screw	9	
pars screw	0	
no insertion	anterior fusion	9
	only decompression	1
	fixation above C3	10
	avoid insertion	2
total	31	

Discussion

A HRVA is more frequent in patients with rheumatic arthritis [5-6] and Down syndrome [9]. In addition, Yamazaki et al. reported that the prevalence of a HRVA is higher in patients who have atlantoaxial subluxation and congenial skeletal anomaly at the craniovertebral junction [4]. Although C2 PS or C1-2 transarticular screws are usually needed for instrumentation surgery at the craniovertebral junction, there is a considerable risk of VA injury when they are applied to patients with a HRVA. By contrast, C2 PS is also often used for posterior fixation surgery to subaxial cervical spine disorder as a cranial anchor screw. More than half of the patients who underwent posterior surgery in the subaxial group (46 of the 78 cases) needed fixation including C2 in the present study. To avoid intraoperative VA injury, it is necessary to look carefully for a HRVA using preoperative CT.

In studies using cadavers, the prevalence of a HRVA was 11.7%–20.0% [10–11]; in studies targeting patients with cervical spine disorders the prevalence was 14.5%–31.0% [3–4]; and in those without cervical spine disorders the prevalence was 10.1%–24.1% [12-13]. In the present study, the prevalence of a HRVA in the subaxial group was 27.7 % and in the thoracolumbar group was 15.6 %, as consistent with previous studies. The prevalence of a HRVA in the subaxial group was significantly higher than that in the thoracolumbar group. This means that a HRVA is more frequent in patients with a subaxial cervical spine disorder than in normal individuals, and that the prevalence of a HRVA might be lower in patients with thoracolumbar disorders.

While it is already known that RA and Down syndrome that cause the deformity of C1/2 joint could be risk factors of a HRVA, the present study suggests that the subaxial cervical spine disorder could have some factor of the presence of a HRVA. Vanek et al. reported that female sex and age >70 years were significant risk factors for a HRVA [14], which was not confirmed in the present study, nor was BMI. Rather, logistic regression using the present data indicated that osteoarthritis of C1/2 facet was a significant risk factor for HRVA. It was suggested that osteoarthritis of C1/2 facet joints could affect the forming of a HRVA and the prevalence of a HRVA in the subaxial cervical spine disorders of which C1/2 facet joints tend to be degenerative was more frequent than in normal individuals. Therefore, we should be vigilant for a HRVA when we perform surgery not only for those with rheumatic arthritis, Down syndrome, the main lesion at the craniovertebral junction, but also for those patients with a subaxial cervical spine disorder.

In general, C2 PSs are considered safer than subaxial (C3–C6) PSs in patients without a HRVA because the trajectory of a C2 PS can be confirmed directly and the insertion angle for a C2 PS is significantly less mediolaterally than the angle for a subaxial PS. Therefore, C2 PSs tend to be used frequently for posterior fixation surgery. However, insertion of C2 PSs in patients with a HRVA bears a considerable risk of VA injury. Yoem et al. reported that among the C2 PSs inserted for patients with a HRVA, about half violated the VA groove [3], which indicates that C2 PSs are not appropriate for patients with a HRVA. We did not use a C2 PS in any patients with a HRVA, but used a laminar screw instead or avoided inserting screws entirely. As a result, we had no neurovascular injury as a complication of surgery in these patients. When instrumentation for C2 is needed for patients who will undergo subaxial cervical spine surgery, we should

look carefully for a HRVA using preoperative CT, and apply instruments other than PSs in those with a HRVA.

There are several limitations to our study. First, the patients examined in this study were all Japanese admitted to a single university hospital. Thus, it may not be possible to generalize the result of our study to other races. Second, the sample size of our study was relatively small. To solve these problems, multi-center study with lager sample size will be needed in the future.

Conclusion

The prevalence of a HRVA in patients with subaxial cervical spine disorders is higher than in those without cervical spine disorders, and osteoarthritis of C1/2 facet joints significantly correlates with a HRVA.

Abbreviations

CPS: cervical pedicle screw

HRVA: high riding vertebral artery

OPLL: ossification of the posterior longitudinal ligament

OYL: ossification of the yellow ligament

BMI: body mass index

RA: rheumatoid arthritis

Declarations

Ethics approval and consent to participate:

All procedures used in this research were approved by the institutional review board of University of Tsukuba Hospital and written informed consents were obtained from all patients to participate in this study.

All procedures were performed in accordance with relevant guidelines.

Consent for publication:

Written informed consents were obtained from all patients for publication of this study.

Availability of data and materials:

The datasets generated during and analyzed during the current study are available from the corresponding author on reasonable request.

Competing interest:

The authors declare that they have no competing interests.

Funding:

None.

Author Contribution:

TS, MK and TA conceived and designed the study. TS, MK, TA, YS, MK, FE, KM, KM, HN, HT, and TF gathered and analyzed the data. TS, MK, and TA drafted the paper. MY significantly revised the drafted paper. All the authors gave final approval of the version to be published.

Acknowledgements:

None.

References

1. Abumi K, Ito H, Taneichi H et al. Transpedicular screw fixation for traumatic lesions of the middle and lower cervical spine: description of the techniques and preliminary report. J Spinal Disord 1994; 7:19-28.
2. Wright NM, Lauryssen C. Vertebral artery injury in C1-2 transarticular screw fixation: results of a survey of the AANS/CNS section on disorders of the spine and peripheral nerves. J Neurosurg 1998; 88: 634-640.
3. Yeom JS, Buchowski JM, Kim HJ et al. Risk of vertebral artery injury: comparison between C1-C2 transarticular and C2 pedicle screws. Spine J 2013; 13:775-785.
4. Yamazaki M, Okawa A, Furuya T, et al. Anomalous vertebral arteries in the extra- and intraosseous regions of the craniovertebral junction visualized by 3-dimensional computed tomographic angiography: analysis of 100 consecutive surgical cases and review of the literature. Spine (Phila Pa 1976) 2012; 37: E1389–E1397. https://doi: 10.1097/BRS.0b013e31826a0c9f.
5. Tomasz K, Jagoda C, Leszek S. Risk of the high-riding variant of vertebral arteries at C2 is increased over twofold in rheumatoid arthritis: a meta-analysis. Neurosurgical Rev. 2020; doi.org/10.1007/s10143-020-01425-w
6. Miyata M, Neo M, Ito H et al. Rheumatoid arthritis as a risk factor for a narrow C2 pedicle: 3D analysis of the C-2 pedicle screw trajectory. J Neurosurg Spine 2008; 9:17-21. https://doi: 10.3171/SPI/2008/9/7/017.

7. Pathria M, Sartoris DJ, Resnick D. Osteoarthritis of the facet joints: accuracy of oblique radiographic assessment. Radiology 1987; 164(1):227-30.
8. Thorsten J, James G, Stefarn MZ et al. Lumbar facet joint arthritis is associated with more coronal orientation of the facet joints at the upper lumbar spine. Radiol Res Pract 2013; doi.org/10.1155/2013/693971
9. Yamazaki M, Okawa A, Hashimoto M et al. Abnormal course of the vertebral artery at the craniovertebral junction in patients with Down syndrome visualized by three-dimensional CT angiography. Neuroradiology 2008; 50:485-490.
10. Mandel IM, Kambach BJ, Petersilge CA et al. Morphologic considerations of C2 isthmus dimensions for the placement of transarticular screws. Spine 2000; 25:1542-1547.
11. Madawi AA, Casey AT, Solanki GA et al. Radiological and anatomical evaluation of the atlantoaxial transarticular screw fixation technique. J Neurosurg 1997; 86:961-968.
12. Wakao N, Takeuchi M, Nishimura M, et al. Vertebral artery variations and osseous anomaly at the C1-2 level diagnosed by 3D CT angiography in normal subjects. Neuroradiology 2014; 56:843-849.
13. Wajanavisit W, Lertudomphonwanit T, Fuangfa P et al. Prevalence of high-riding vertebral artery and morphometry of C2 pedicles using a novel computed tomography reconstruction technique. Asian Spine J 2016; 10:1141-1148.
14. Vanek P, Bradac O, Lacy P, et al. Vertebral artery and osseous anomalies characteristic at the craniocervical junction diagnosed by CT and 3D CT angiography in normal Czech population: analysis of 511 consecutive patients. Neurosurg Rev 2017; 40:369-376.

Figures

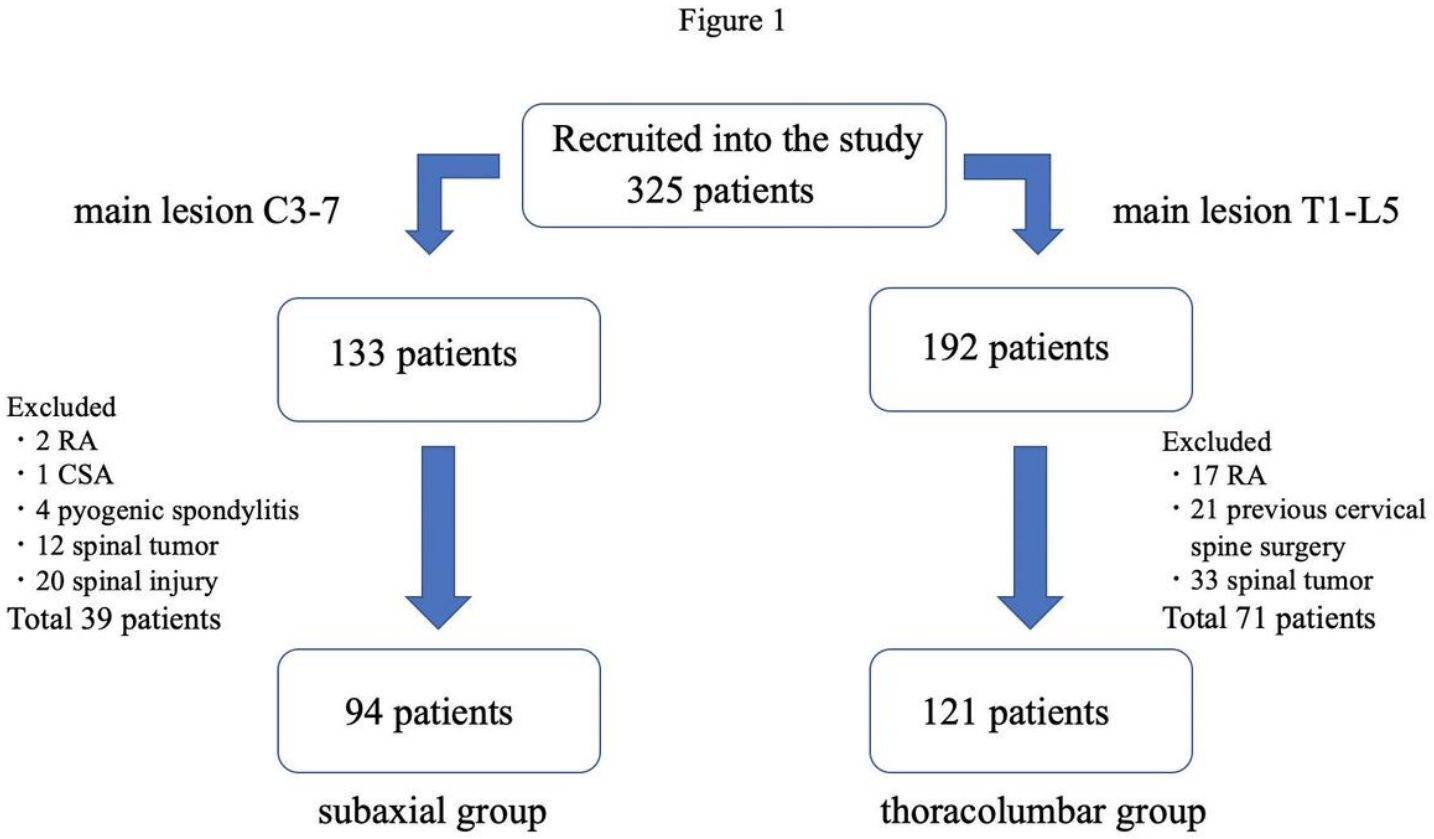

Figure 1

Patient flow chart. RA: rheumatoid arthritis CSA: congenital skeletal anatomy

Figure 2

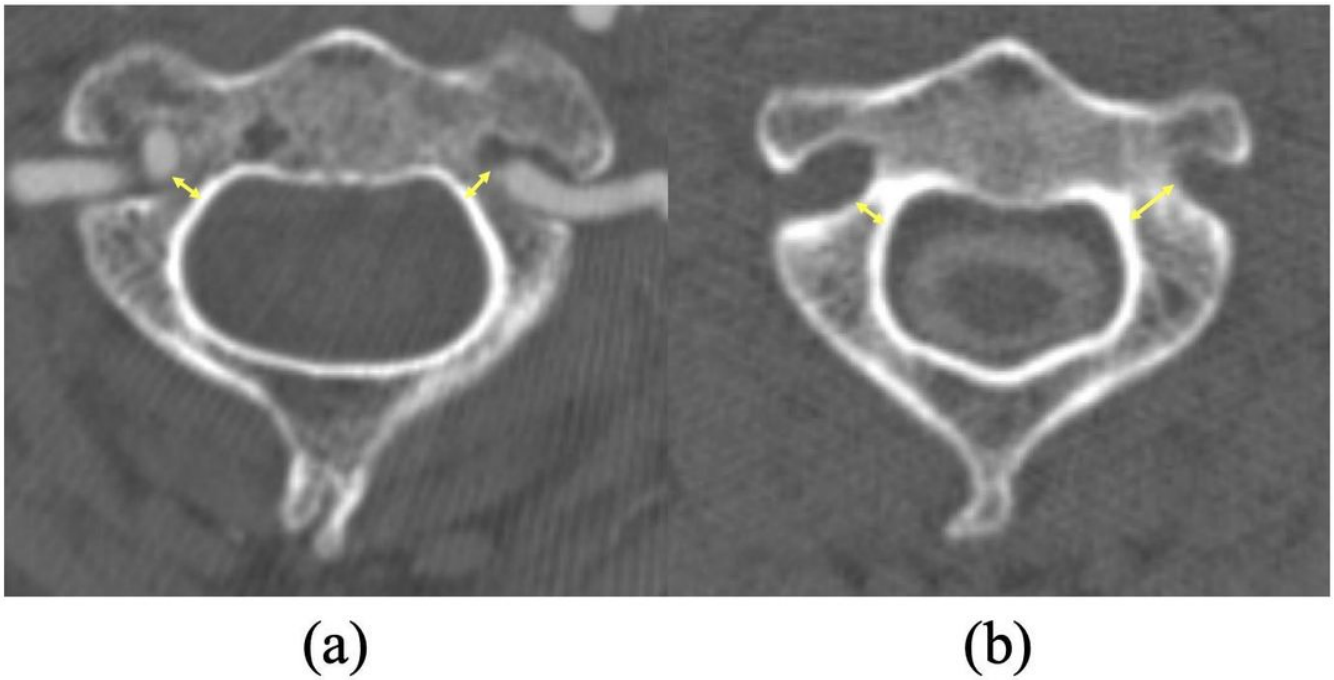

Figure 2

Pedicle diameter of the axis (C2) measured on axial computed tomography (CT). (a) Axial CT angiography. The pedicle diameter on both sides was <3.5 mm. (b) Axial CT myelography. The pedicle diameter on the left side was >3.5 mm, but <3.5 mm on the right side.

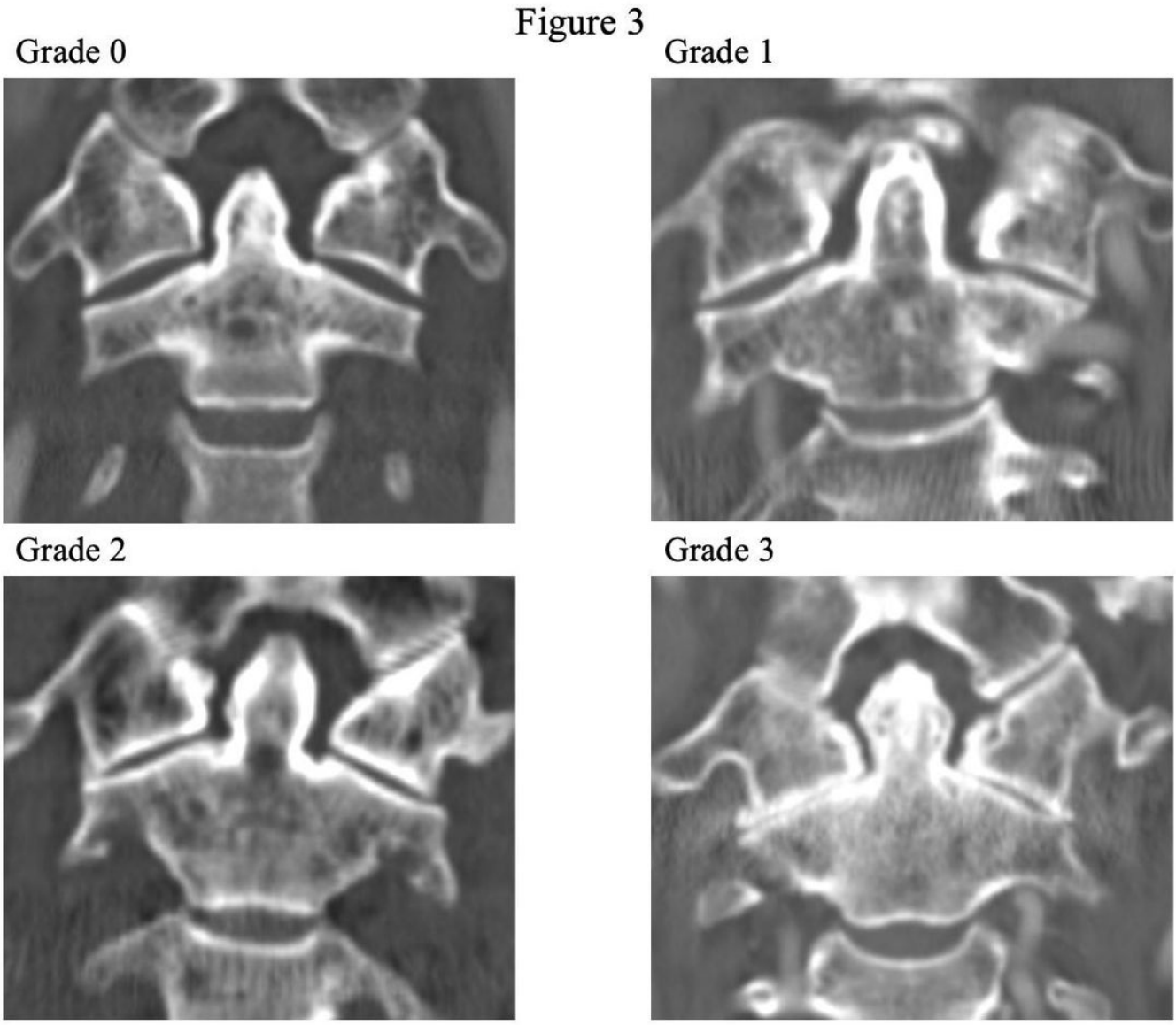

Figure 3

Grading scale for osteoarthritis of the atlantoaxial (C1/2) facet joints. Grade 0 = normal. Grade 1 = joint space narrowing. Grade 2 = narrowing plus sclerosis. Grade 3 = severe osteoarthritis with narrowing, sclerosis, and osteophytes.