Removal of Sticky Silicone Oil Adhered to the Retinal Surface: Comparison of Methodological Safety and Effectiveness

Ziqi Wang
Wenzhou Medical College: Wenzhou Medical University
Zongduan Zhang
Wenzhou Medical College: Wenzhou Medical University
Xuting Hu
Wenzhou Medical College: Wenzhou Medical University
Zhaoliang Zhang
Wenzhou Medical College: Wenzhou Medical University
Qintuo Pan (panqintuo@qq.com)
Wenzhou Medical College: Wenzhou Medical University

Research Article

Keywords: sticky silicone oil, silicone oil removal, 22-gauge venous indwelling cannula, internal limiting membrane peeling

Posted Date: March 2nd, 2021

DOI: https://doi.org/10.21203/rs.3.rs-248384/v1

Version of Record: A version of this preprint was published at International Ophthalmology on July 21st, 2021. See the published version at https://doi.org/10.1007/s10792-021-01958-z.

Abstract

Purpose: To compare safety and effectiveness among methods to remove sticky silicone oil bubbles adhered to the retinal surface.

Methods: This retrospective nonrandomised case series included 14 eyes of 14 patients who had sticky silicone oil residue during silicone oil removal surgery. For small sticky silicone oil bubbles (<2-disc diameter), aspiration was performed with a 23-gauge vitreous cutter. Residual tiny oil bubbles were then removed with a silicone-tipped flute needle or internal limiting membrane (ILM) peeling. For large sticky silicone oil bubbles (≥2-disc diameter) that could not be removed with a 23-gauge vitreous cutter, we devised a more efficient active removal method involving a modified 22-gauge venous indwelling cannula device.

Results: The mean preoperative best-corrected visual acuity (BCVA; logarithm of the minimum angle of resolution [logMAR]) significantly improved from 1.28±0.63 logMAR to 0.77±0.58 logMAR (p=0.014). The postoperative BCVA and improvement in BCVA were significantly better in the ILM peeling group than in the non-ILM peeling group (p=0.004 and p=0.045, respectively). Postoperative complications included residual sticky silicone oil bubbles in seven eyes without ILM peeling (50.0%), retinal neuroepithelial layer damage in two eyes (14.3%), and temporary hypotony in five eyes (35.7%).

Conclusion: Various methods can safely and efficiently remove sticky silicone oil bubbles adhered to the retinal surface. A 22-gauge venous indwelling cannula enabled simple and safe removal of large sticky silicone oil bubbles, while small residual sticky silicone oil bubbles could be completely removed by ILM peeling.

Introduction

Since the 1960s, silicone oil tamponade has gradually become a standard technique in intraocular surgeries, especially in the treatment of complex retinal detachment.[1] Because of its specific density and optical clarity, it is suitable for the repair of a detached retina.[2] Some complications (e.g., cataract, elevated intraocular pressure [IOP], and postoperative keratopathy) develop in relation to the duration of tissue exposure to silicone oil.[2, 3] Because of the immiscible phase between silicone oil and intraocular liquid content, the dioptre of silicone oil may change and cause blurred vision. Therefore, some clinicians recommend all silicone oil must be removed as quickly as possible once the retina heals.[4] With the aim of achieving balance between redetachment and other potential complications, successful silicone oil tamponade is usually achieved in 1 to 3 months; nevertheless, the timing of silicone oil removal should be determined on individual basis to ensure acceptable anatomical results.[5, 6]

Perfluorocarbon liquid (PFCL) is used as an intraoperative heavy tamponade to flatten the detached retina, then removed by a direct exchange with silicone oil.[7, 8] PFCL reportedly can form a viscous substance with silicone oil because of their direct contact during exchange.[9] Sticky oil bubbles can tightly adhere to the retinal surface within the posterior pole during silicone oil removal. In a retrospective study, Veckeneer et al. found that 28 of 234 eyes (12.0%) had sticky silicone oil bubble remnants.[9] Although these remnants are rare, the presence of silicone oil can case many severe complications during conservative follow-up, such as oil emulsification, cataract, glaucoma and acute toxicity of PFCL.[9–11] However, because of the viscosity of silicone oil, the remnants are difficult to aspirate. Here, we report a case series in which patients underwent less invasive and more efficient techniques for the removal of sticky silicone oil bubbles, with only slight damage.

Methods

Subjects

This retrospective, noncomparative case series included patients with sticky silicone oil adhered to the macular surface. The Eye Hospital and School of Ophthalmology and Optometry ethics committee approved the study protocol. Written informed consent to participate was obtained from all patients. Fourteen eyes of 14 patients who had sticky silicone oil residue during silicone oil removal surgery were included in this study. All eyes had undergone previous pars plana vitrectomy, PFCL (Arcaline; Arcadophtha, Toulouse, France) and silicone oil injection due to retinal detachment. All patients had undergone an ophthalmologic evaluation, including fundus photography and spectral-domain optical coherence tomography (SD-OCT, Spectralis; Heidelberg Engineering, Heidelberg, Germany) at the time of before surgery and at 1 week, 1 month, 3 months, and 6 months postoperatively. Postoperative hypotony was defined as IOP <6 mmHg. Best-corrected visual acuity (BCVA) was converted into logarithm of the minimum angle of resolution (logMAR) for statistical analysis.

Procedures

Following the induction of retrobulbar anaesthesia, transconjunctival three-port 23-gauge pars plana sclerotomies were performed. A balanced salt solution was perfused into the vitreous cavity to maintain IOP and silicone oil was removed from the vitreous cavity through a 23-gauge cannula. When sticky silicone oil adhered to the retinal surface, one of the following methods was chosen.

Small sticky silicone oil bubbles (<2-disc diameter).

Small sticky silicone oil bubbles were aspirated with a -gauge under a plane-concave lens. Any residual tiny oil bubbles were removed with a silicone-tipped flute needle or internal limiting membrane (ILM) peeling. The ILM was stained by indocyanine green (0.125 mg/ml) and removed in a circular manner with a 1–2-disc diameter in the macular area. The ILM was lifted to separate the tightly adhered residual silicone oil and the retina; the oil was then partially aspirated with a 23-gauge vitreous cutter and any remnants were completely removed by ILM peeling.

Large sticky silicone oil bubbles (≥2-disc diameter).

Large sticky silicone oil bubbles were aspirated using a 22-gauge venous indwelling cannula (Tuoren, Inc, Henan, China). Under intraocular illumination, an outer soft needle was placed on the surface of the sticky silicone oil to actively aspirate the oil. The foot pedal of the vitrectomy machine controlled the active aspiration, with pressure ranging from 200 to 300 mmHg. Bubbles were mostly removed using this approach (Video, see Supplemental Video file). Small residual amounts of oil were aspirated with a silicone flute needle or ILM peeling, as described above.

Twenty-two-gauge venous indwelling cannula device

A 22-gauge venous needle was first inserted into the vitreous cavity. The inner steel needle was then removed, leaving the outer silicone needle attached to a 1-ml syringe. Extrusion tubing was linked to the syringe with a Luer slip needle-free connector (NIPRO, Inc, Osaka, Japan). The end of the connector was attached to a conventional vitrectomy machine (Fig 1).

Statistical Analysis

The statistical analyses were performed using SPSS Statistics 23.0 (SPSS Inc., Chicago, IL, USA). Continuous variables were described as mean ± standard deviation, and categorical variables were described as n (%). Paired t-tests were used to compare preoperative and postoperative values of BCVA and IOP. Postoperative retinal injury rates of the silicone tipped flute needle using and non-using silicone groups were compared with the chi-squared test. Differences were considered statistically significant when p-values were <0.05.

Results

This retrospective, noncomparative, interventional case series included fourteen eyes of 14 patients (eight male patients and six female patients). The patient characteristics are shown in Table 1. Nine patients had small sticky silicone oil bubbles (64.3%), six of which were removed by a 23-gauge vitreous cutter combined with ILM peeling; the remaining three were removed by a 23-gauge vitreous cutter combined with silicone-tipped flute needle. Five patients had large sticky silicone oil bubbles (35.7%); a 22-gauge venous indwelling cannula combined with ILM peeling was used in one eye, while a 22-gauge venous indwelling cannula combined with a silicone-tipped flute needle was used in four eyes.

Table 1
The patient characteristics.

No.	Age (years)/Sex/Eye	22G venous indwelling cannula	ILM peeling	Silicone tipped flute needle	23G vitreous cutter	Duration of SO (months)	Follow-up (months)	Postoperative complications
1	28/M/OD	-	+	-	+	4	9	temporary hypotony
2	53/F/OS	-	+	-	+	3	9	-
3	55/F/OS	-	+	-	+	5	10	-
4	46/M/OD	-	+	-	+	4	9	temporary hypotony
5	61/F/OS	-	+	-	+	3	6	temporary hypotony
6	48/M/OD	-	+	-	+	3	12	-
7	60/F/OD	-	-	+	+	6	6	residual SO, retinal injury
8	49/M/OS	-	-	+	+	4	9	residual SO
9	47/F/OS	-	-	+	+	3	12	residual SO, temporary hypotony
10	52/F/OS	+	+	-	-	0.2	8	-
11	63/M/OS	+	-	+	-	6	9	residual SO, retinal injury
12	64/M/OD	+	-	+	-	4	6	residual SO
13	53/F/OD	+	-	+	-	3	7	residual SO
14	57/F/OS	+	-	+	-	3	10	residual SO, temporary hypotony

M, male; F, female; -, no; +, yes; ILM, internal limiting membrane; SO, silicone oil.

Seven patients (50.0%) without ILM peeling had varying amounts of tiny oil bubbles adhered to the retinal surface (Fig. 2d and Fig. 3b). The other seven patients (50.0%) with ILM peeling had no oil bubble postoperatively (Fig. 4d and Fig. 3e). Among seven patients using silicone-tipped flute needles, two (28.6%) exhibited iatrogenic parafoveal damage in the retinal neuroepithelial layer (Fig. 2e and Fig. 3c). The rate of retinal damage in the group using silicone-tipped flute needles was 28.6%, while it was 0% in the group not using silicone-tipped flute needles; this difference was not statistically significant ($p = 0.127$). Temporary hypotony was observed in five eyes (35.7%); it resolved within 1 week in all eyes, following treatment with tobramycin and dexamethasone eye drops. No other complications such as retinal redetachment, cystoid macular oedema, endophthalmitis, or intraocular haemorrhage were detected during follow-up.

The preoperative and postoperative BCVA values are shown in Table 2. The mean preoperative BCVA was 1.28 ± 0.63 logMAR; this improved to 0.77 ± 0.58 logMAR at the last follow-up ($p = 0.014$). When patients were divided into ILM peeling and non-ILM peeling groups, there were no statistically significant differences in preoperative BCVA (p =

0.780). However, postoperative BCVA and improvement in BCVA were significantly better in the ILM peeling group than in the non-ILM peeling group (p = 0.004 and p = 0.045, respectively). The mean IOP was 15.46 ± 2.85 mmHg preoperatively, whereas it was 14.65 ± 2.66 mmHg postoperatively (p = 0.308).

Table 2
Preoperative and postoperative best-corrected visual findings.

BCVA (Log MAR)	Preoperative	Postoperative	Improvement	p* value
Overall	1.28 ± 0.63	0.77 ± 0.58	0.51 ± 0.67	0.014
ILM peeling	1.23 ± 0.68	0.37 ± 0.20	0.86 ± 0.82	0.045
Without ILM peeling	1.33 ± 0.63	1.17 ± 0.56	0.16 ± 0.10	0.021
p†value	0.780	0.004	0.045	
BCVA, best-corrected visual acuity; Log MAR, logarithm of the minimum angle of resolution; ILM, internal limiting membrane; Data are shown as mean ± standard deviation.				
*Comparison of postoperative and preoperative BCVA (logMAR); p-values were calculated by paired t-tests.				
†Comparison of BCVA (logMAR) between groups with and without ILM peeling; p-values were calculated by t-tests.				

Discussion

With the wide application of PFCL and silicone oil in retinal detachment repair, the frequency of sticky silicone oil occurrence is increasing. Ghoraba et al. suggested that the formation of sticky silicone oil bubbles was not related to the viscosity, duration, or brand of silicone oil used; their results indicated that this phenomenon was only related to the usage of PFCL.[10] Notably, PFCL application can reduce the surface tension of the oil interface, forming a hyper-viscous solution. The cohesion of silicone oil is lower than its adhesive force, so the removal of sticky silicone oil from the retinal surface may be difficult due to changes in its properties.[10, 12] An in vitro experiment by Romano et al. showed that the presence of PFCL can cause the silicone oil mixture to become opaque and viscous.[13] Consistent with the previous findings, the formation of sticky silicone oil bubbles in our study was independent of the duration of silicone oil tamponade. All patients in our study had used PFCL, which was not completely cleared, leading to the formation of sticky silicone oil bubbles.

Several surgical techniques have been reported for the successful removal of sticky silicone oil bubbles, such as passive removal in 23-gauge transconjunctival vitrectomy,[14] 25-gauge sutureless system,[15] and 20-gauge cannula.[16] However, these techniques can cause sudden collapse of the eyeball and lead to retinal redetachment.[15] Here, we introduced a less invasive and more efficient method for active removal of sticky silicone oil bubbles with a modified 22-gauge venous indwelling cannula. The use of a large-bore instrument during manual aspiration may cause iatrogenic injuries.[9] We implemented a 22-gauge vacuum soft needle with a foot pedal to control active aspiration on the vitrectomy machine; this generated suction power on sticky silicone oil bubbles, thereby minimising damage to the incision and retina. Using a 1-ml syringe for control improved stability and operator convenience. The entire system can be easily assembled in a few minutes, thereby enabling safe and simple removal of sticky silicone oil.

After most silicone oil bubbles have been removed, tiny oil bubble closely adhere to the retinal surface. Forceful aspiration to remove sticky silicone oil bubbles can lead to peripheral retinal tears and choroidal haemorrhages,

which some doctors may not actively manage.[9] Some studies have shown that silicone oil due to the concentration of low molecular weight components and amphiphilic substances has toxic effects on the anterior segment, trabecular meshwork, ganglion cell complex, and retinal pigment epithelium.[17, 18] Veckeneer et al. reported that the residue caused relative scotomata in four patients. In two of those patients, the symptoms were temporary because the sticky silicone oil bubbles spontaneously detached and migrated upwards to the 12 o'clock position.[9] Parafoveal bubbles caused moderate visual symptoms, whereas foveal bubbles led to central vision loss and scotoma.[9, 10] In our study, the postoperative BCVA was better in the ILM peeling group than in the non-ILM peeling group. In one patient, postoperative BCVA improved to 1.0 (Fig. 4). Therefore, we recommend ILM peeling to remove smaller oil bubbles that are strongly adhered to the retina. This method improves postoperative BCVA, while avoiding the toxicity of silicone oil and the possibility of secondary macular membrane formation.

The main postoperative complication was iatrogenic parafoveal damage to the retinal neuroepithelial layer. In all patients, most sticky silicone oil bubbles were removed by using a 22-gauge venous indwelling cannula or a 23-gauge vitreous cutter, both of which were placed at a safe distance from the retina and associated with a low rate of retinal damage. In patients without ILM peeling, silicone-tipped flute needles were used to remove oil bubbles adhered to the retinal surface. This procedure could cause retinal damage; notably, the only two patients with iatrogenic damage in our study were both treated with a flute needle. The incidence of retinal injury in the group using flute needles (28.6%) tended to be higher than that in the group not using flute needles (0.0%); however, this difference was not statistically significant, presumably because of the small number of included patients. Temporary hypotony was a minor postoperative complication. The mechanism of hypotony is not well understood, although underlying pathologic changes in the ciliary body or surgical procedures may contribute to the development of postoperative transient hypotony by reducing aqueous production, thereby creating aqueous outflow.[19] The range of hypotony following silicone oil removal is 2–39%, some of which is transient and recovers within weeks without any impact on BCVA.[20, 21]

There were some limitations in our study, such as its small sample size; retrospective, uncontrolled design; and relatively short follow-up duration. Further investigations should include larger numbers of patients and longer follow-up to confirm the efficiency and safety of the methods described here.

In summary, we introduced safe and efficient methods for the removal of distinct types of sticky silicone oil bubbles adhered to the retinal surface. A 22-gauge venous indwelling cannula was a simple and safe approach for the removal of large sticky silicone oil bubbles, while small residual sticky silicone oil bubbles could be completely removed by ILM peeling.

Declarations

Funding:

This work received no specific grant from any funding agency in the public, commercial or not-for-profit sectors.

Conflicts of interest/Competing interests:

None declared.

Authors' contributions:

Author Qin-tuo Pan designed the study and wrote the initial draft of the manuscript. Author Zi-qi Wang contributed to the analysis and interpretation of data, and assisted in the preparation of the manuscript. All other authors contributed to data collection and interpretation, and critically reviewed the manuscript. All authors approved the final version of the manuscript, and agree to be accountable for all aspects of the work in ensuring that questions related to the accuracy or integrity of any part of the work are appropriately investigated and resolved.

Availability of date:

Data are available with the corresponding author on request.

Ethics approval:

The Eye Hospital and School of Ophthalmology and Optometry ethics committee approved the study protocol.

Consent to participate:

Written informed consent to participate was obtained from all patients.

Consent for publication:

The consent for publication was obtained from all patients.

References

1. Cibis PA, Becker B, Okun E, Canaan S (1962) The use of liquid silicone in retinal detachment surgery. Arch Ophthalmol 68:590-9.
2. Issa R, Xia T, Zarbin MA, Bhagat N (2020) Silicone oil removal: post-operative complications. Eye (Lond) 34:537-43.
3. Caporossi T, Franco F, Finocchio L, Barca F, Giansanti F, Tartaro R, et al. (2019) Densiron 68 heavy silicone oil in the management of inferior retinal detachment recurrence: analysis on functional and anatomical outcomes and complications. Int J Ophthalmol 12:615-20.
4. Roca JA, Wu L, Berrocal M, Rodriguez F, Alezzandrini A, Alvira G, et al. (2017) Un-explained visual loss following silicone oil removal: results of the Pan American Collaborative Retina Study (PACORES) Group. Int J Retina Vitreous 3:26.
5. Falkner CI, Binder S, Kruger A (2001) Outcome after silicone oil removal. Br J Ophthalmol 85:1324-7.
6. Jonas JB, Knorr HL, Rank RM, Budde WM (2001) Retinal redetachment after removal of intraocular silicone oil tamponade. Br J Ophthalmol 85:1203-7.
7. Gonzalez MA, Flynn HW, Jr., Smiddy WE, Albini TA, Tenzel P (2013) Surgery for retinal detachment in patients with giant retinal tear: etiologies, management strategies, and outcomes. Ophthalmic Surg Lasers Imaging Retina 44:232-7.

8. Chang S (1987) Low viscosity liquid fluorochemicals in vitreous surgery. Am J Ophthalmol 103:38-43.
9. Veckeneer MA, de Voogd S, Lindstedt EW, Menz DH, van Meurs JC (2008) An epidemic of sticky silicone oil at the Rotterdam Eye Hospital. Patient review and chemical analyses. Graefes Arch Clin Exp Ophthalmol 246:917-22.
10. Ghoraba HH, Zaky AG, Abd Al Fatah HM, El Gemai E, Heikal MA (2017) STICKY SILICONE OIL. Retina 37:1599-606.
11. Srivastava GK, Andrés-Iglesias C, Coco RM, Fernandez-Bueno I, Medina J, García-Serna J, et al. (2020) Chemical compounds causing severe acute toxicity in heavy liquids used for intraocular surgery. Regul Toxicol Pharmacol 110:104527.
12. Dresp JH, Menz DH (2007) The phenomenon of "sticky" silicone oil. Graefes Arch Clin Exp Ophthalmol 245:863-8.
13. Romano MR, Vallejo-Garcia JL, Parmeggiani F, Romano V, Vinciguerra P (2012) Interaction between perfluorcarbon liquid and heavy silicone oil: risk factor for "sticky oil" formation. Curr Eye Res 37:563-6.
14. Cekiç O, Cakir M, Yilmaz OF (2011) Passive silicone oil removal in 23-gauge transconjunctival vitrectomy. Ophthalmic Surg Lasers Imaging 42:514-5.
15. Kapran Z, Acar N (2007) Active removal of silicone oil with 25-gauge sutureless system. Retina 27:1133-5.
16. Garodia VK, Kulkarni A (2001) Silicone oil removal using vitrectomy machine: a simple and safe technique. Retina 21:685-7.
17. Raczyńska D, Mitrosz K, Raczyńska K, Glasner L (2018) The Influence of Silicone Oil on the Ganglion Cell Complex After Pars Plana Vitrectomy for Rhegmatogenous Retinal Detachment. Curr Pharm Des 24:3476-93.
18. Lu Y, Chan YK, Lau LH, Wong D, Wong JKW, Shih KC, et al. (2020) Amphiphilic additives in silicone oil tamponade and emulsification: an eye-on-a-chip study. Acta Ophthalmol 98:e232-e7.
19. Arevalo JF, Garcia RA, Fernandez CF (2004) Anterior segment inflammation and hypotony after posterior segment surgery. Ophthalmol Clin North Am 17:527-37, vi.
20. Al-Wadani SF, Abouammoh MA, Abu El-Asrar AM (2014) Visual and anatomical outcomes after silicone oil removal in patients with complex retinal detachment. Int Ophthalmol 34:549-56.
21. Kim SW, Oh J, Yang KS, Kim MJ, Rhim JW, Huh K (2010) Risk factors for the development of transient hypotony after silicone oil removal. Retina 30:1228-36.

Figures

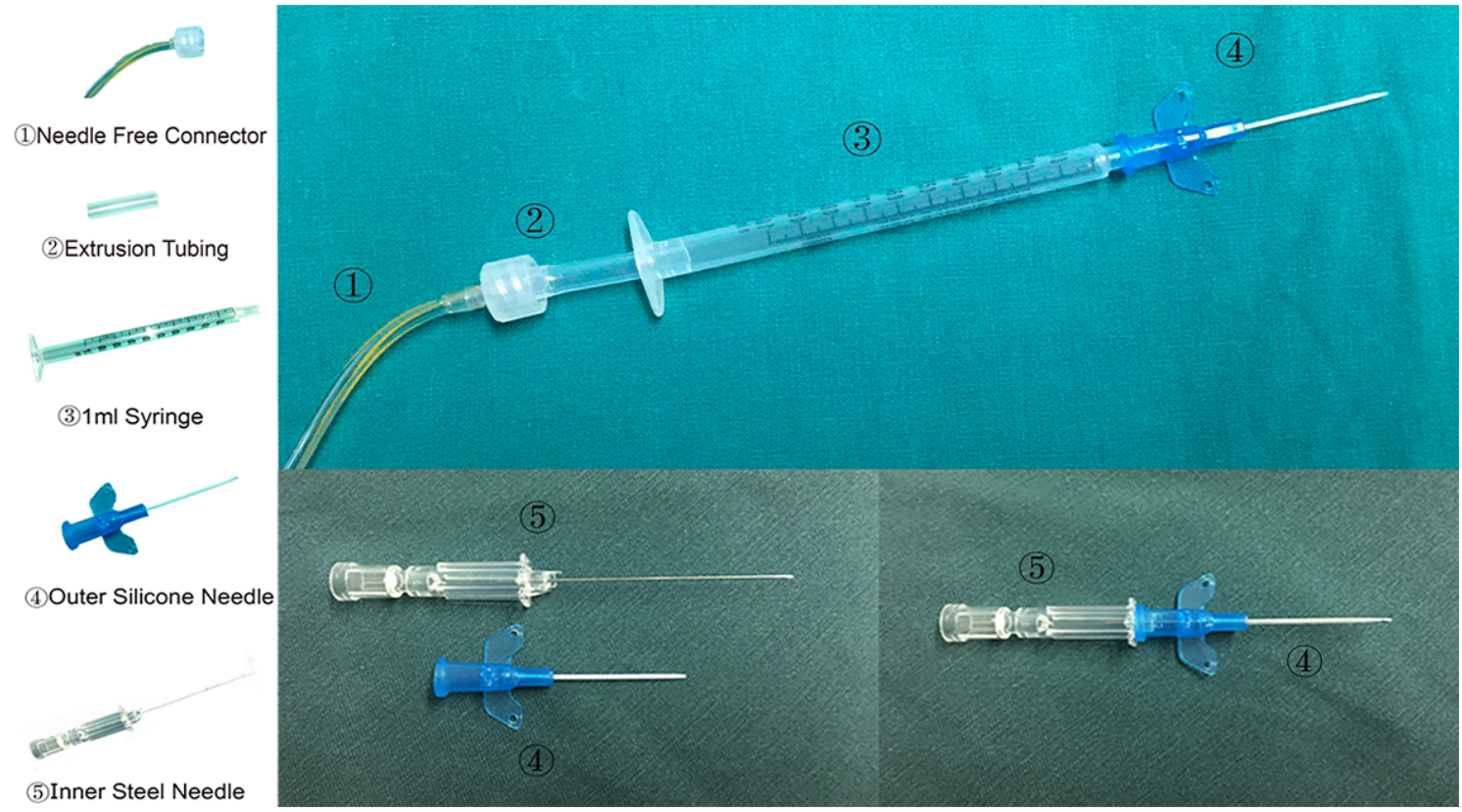

Figure 1

Twenty-two-gauge venous indwelling cannula device.

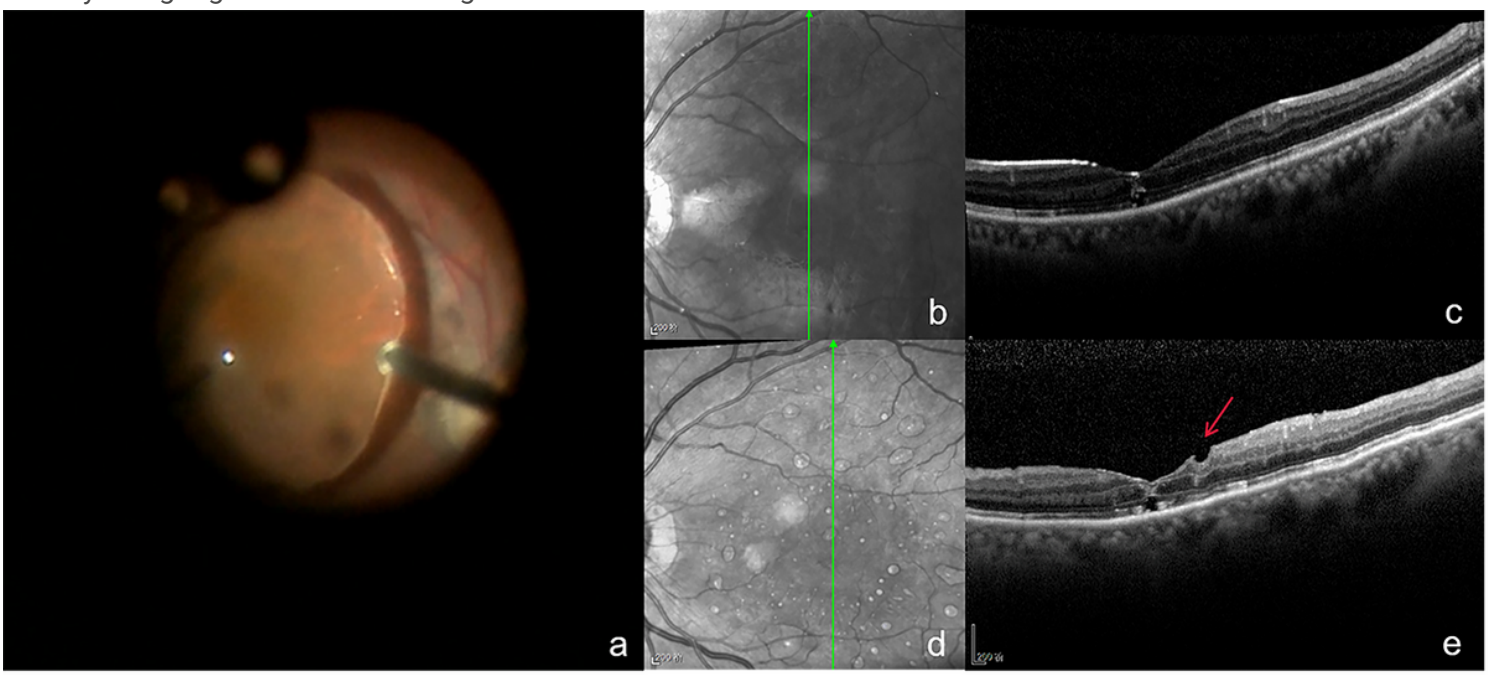

Figure 2

Patient no. 11 underwent sticky silicone oil removal using a 22-gauge venous indwelling cannula combined with a silicone-tipped flute needle. a. Intraoperative fundus photographs under plane-concave lens. b. Preoperative infrared

reflectance images (IR). c. Preoperative macular spectral-domain optical coherence tomography (SD-OCT). d. Postoperative IR showed tiny silicone oil bubbles on the retinal surface. e. Postoperative macular SD-OCT showed iatrogenic parafoveal injury in the retinal neuroepithelial layer (red arrow).

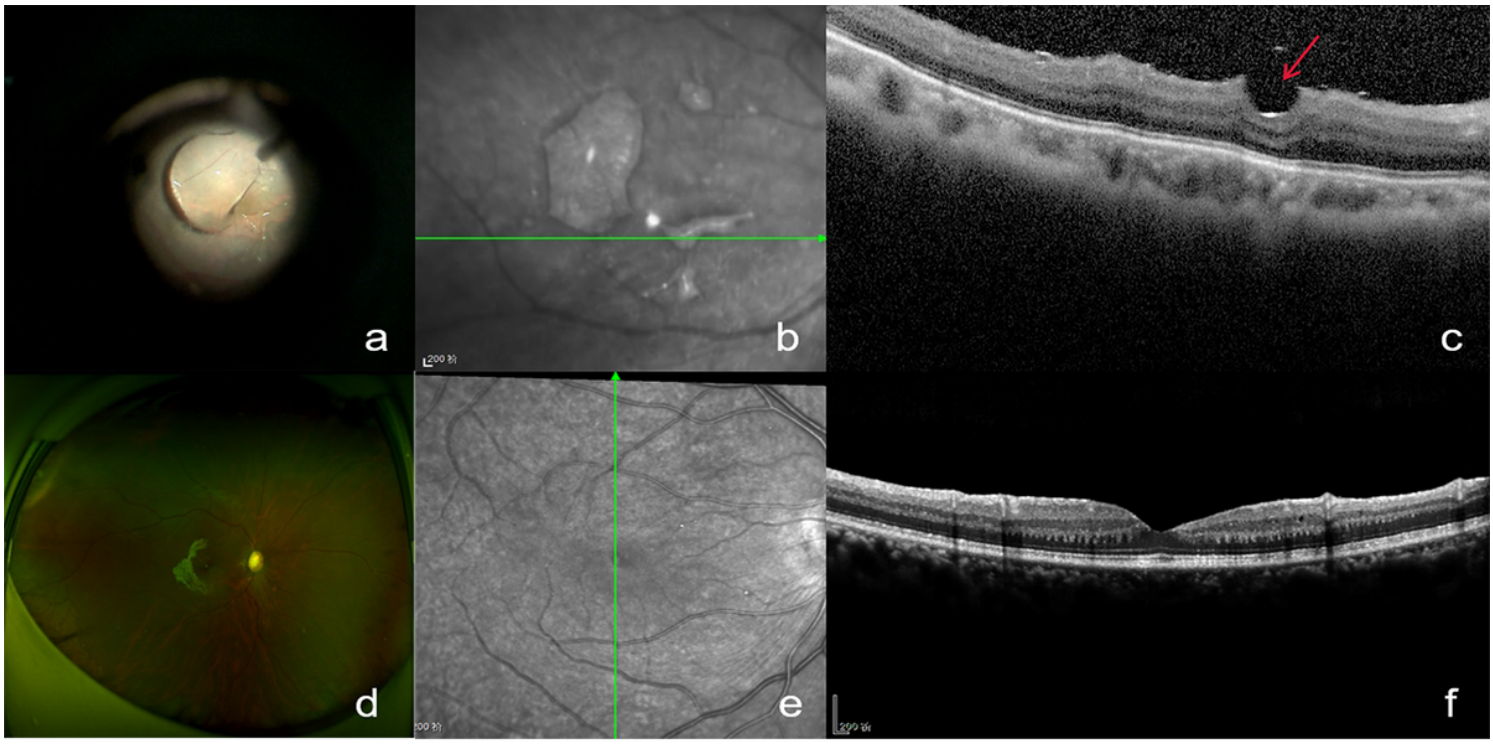

Figure 3

Patient no. 7 underwent sticky silicone oil removal using a 23-gauge vitreous cutter combined with a silicone-tipped flute needle (a–c). Patient no. 1 underwent sticky silicone oil removal using a 23-gauge vitreous cutter combined with internal limiting membrane (ILM) peeling (d–f). a. Intraoperative fundus photographs under plane-concave lens. b. Postoperative IR showed tiny silicone oil bubbles on the retinal surface. c. Postoperative macular SD-OCT showed iatrogenic parafoveal injury in the retinal neuroepithelial layer (red arrow). d. Preoperative wide-field laser scanning image. e. Postoperative IR showed no residual silicone oil bubbles. f. Postoperative macular SD-OCT showed no iatrogenic parafoveal injury.

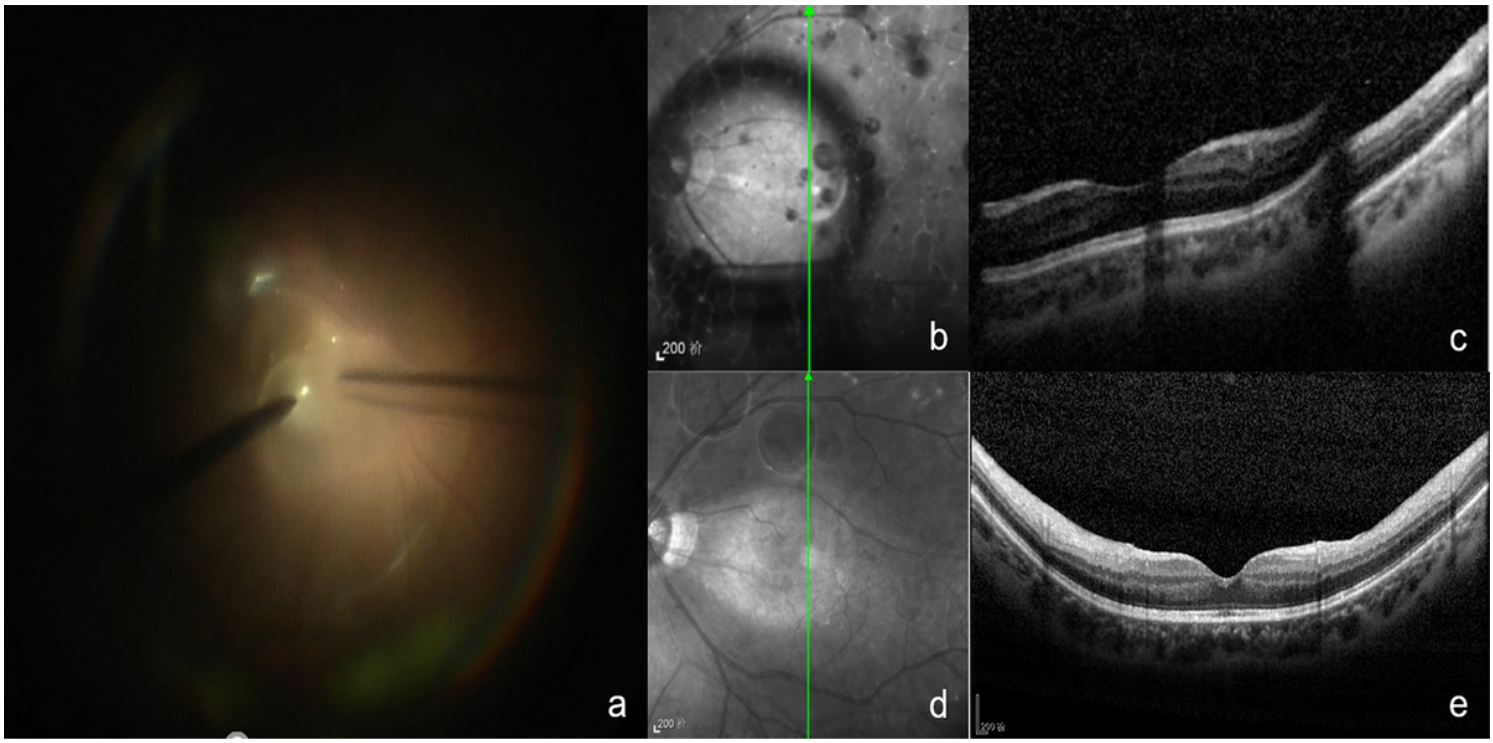

Figure 4

Patient no. 10 underwent sticky silicone oil removal using a 22-gauge venous indwelling cannula combined with ILM peeling. Peripheral retinal detachment was observed at 5 days after initial retinal detachment vitrectomy with silicone oil tamponade. A large sticky silicone oil bubble adhering to the retinal surface was found during reoperation. a. Intraoperative fundus photographs under non-contact wide-angle lens. b. Preoperative infrared reflectance images (IR). c. Preoperative macular SD-OCT. d. Postoperative IR showed no residual silicone oil bubbles. e. Postoperative macular SD-OCT showed no iatrogenic parafoveal injury.

Supplementary Files

This is a list of supplementary files associated with this preprint. Click to download.

- SupplementalVideofile.mp4