T2-weighted Magnetic Resonance Imaging as a novel predictor of surgical remission in newly diagnosed acromegaly

Enes Akkaya
Istanbul University
Mehmet Yigit Akgun
Yuksek Ihtisas Hospital
Emine Sebnem Durmaz
Istanbul University
Seckin Aydin
Istanbul University
Hande Mefkure Ozkaya
Istanbul University
Osman Kizilkilic
Istanbul University
Nurperi Gazioglu
T.C Demiroglu Bilim University
Pinar Kadioglu
Istanbul University
Necmettin Tanriover (nctan27@yahoo.com)
Istanbul University-Cerrahpasa, Cerrahpasa Medical Faculty https://orcid.org/0000-0001-7628-9443

Research Article

Keywords: acromegaly, endoscopic endonasal trans-sphenoidal surgery, magnetic resonance imaging, pituitary adenomas, remission

Posted Date: March 1st, 2021

DOI: https://doi.org/10.21203/rs.3.rs-248719/v1

Abstract

Background

Any preoperative diagnostic assessment that can predict the success of the operation in acromegaly will provide a positive impact on overall remission rates. The aim of this study is to present whether signal intensity on T2-weighted Magnetic Resonance Imaging could predict postoperative results in acromegaly patients.

Methods

We analyzed our surgical results in regard to T2-weighted images in newly diagnosed consecutive 124 patients with acromegaly, operated between 2014 and 2019. The T2-intensity of the pure somatotroph adenomas was correlated with the clinical, radiological, surgical and histopathological characteristics of the acromegaly patients.

Results

We found a predominance of T2-hyperintensity in our series (45%) and the T2-hypointense pure somatotroph adenomas were detected in only 34% of our patients. Total resection was performed in 72% of newly diagnosed acromegaly patients in this series. Accordingly, total resection was achieved in 69% of the T2-hyperintense group, 77% of the T2-hypointense group and 69% of the T2-isointense group. The surgical remission rates for the T2-hyper-, hypo- and isointense groups were 55%, 80%, and 69%, respectively. The surgical remission rate in the T2-hyperintense group was significantly lower than those of hypo- and isointense groups in newly diagnosed acromegaly patients.

Conclusions

This study demonstrates a close relationship between the T2 signal intensity and the surgical remission rates in acromegaly. T2 signal intensity seems to be an indicator of the degree of surgical resection completeness in pure somatotroph adenomas. The implications suggest that preoperative T2-intensity may directly predict the probability of post-surgical remission as an important independent factor in patients with newly diagnosed acromegaly.

Introduction

Acromegaly is a rare disease, characterized by increased release of growth hormone (GH) and, consequently, insulin-like growth factor I (IGF-I) with an incidence of about 3–5/ 1000000/year [6, 8]. Endoscopic endonasal transsphenoidal surgery (EETSS) is a cornerstone and the first line therapy in the management of acromegaly, although postoperative medical treatment with somatostatin analogues

(SSA) may be necessary and a variety of established and novel therapeutic options are available [3, 24, 26, 30]. The preoperative medical treatment with SSA has been an option and depends on the size, invasiveness of the adenoma, co-morbidities, patient and physician preferences [6, 18, 32].

Magnetic resonance imaging (MRI) is a non-invasive diagnostic test that can predict the favorable response to medical treatment in patients with acromegaly [15, 18, 26–28]. The correlation between changes in T2-weighted MRI intensity and tumor granularity, as well as the capacity to predict the response to SSA have been demonstrated in recent studies [15, 18, 26–28]. On the basis of pathological analysis, the granulation pattern seems to predict the response to SSA therapy, with densely granulated better responding to SA therapy [5, 12, 13, 15, 18, 27, 29]. Accordingly, careful evaluation of intensity changes in preoperative sellar MRI has the potential to strengthen the success of clinical management.

Any preoperative diagnostic assessment, such as signal intensity in T2-weighted sellar MRI, that can predict the success of the operation in acromegaly will provide the achievement of better overall remission rates. In this regard, there are no studies in the literature comparing the relationship between T2 signal intensity and surgical remission and resection rates in acromegaly. The aim of this study is to present whether T2 signal intensity could predict postoperative results in acromegaly patients, such as surgical remission, degree of resection, and granulation pattern of the somatotroph adenoma.

Material And Methods

Study Design and Population

All procedures performed in this study were in accordance with the ethical standards of the institutional and national research committee and with the 1964 Helsinki Declaration and its later amendments or comparable ethical standards. A total of 767 patients underwent 851 EETSS for pituitary adenomas (PAs) between October 2007 and December 2019 in our department. Among them, 255 (33.2%) patients were diagnosed with acromegaly.

In this study, we aimed to review our surgical results in newly diagnosed 124 patients with acromegaly, operated between 2014 and 2019. In regard to T2-weighted images, we analyzed our surgical results in consecutive patients with pure somatotroph adenomas, who had undergone EETSS for acromegaly at our clinic between 2014 and 2019. Data regarding routine medical procedures were collected retrospectively.

The exclusion criteria among 124 patients were as follows: i) patients with microadenoma, cystic/hemorrhagic adenoma and plurihormonal tumors that include mammosomatotroph, mixed somatotroph-lactotroph tumors and mature plurihomonal Pit1-lineage tumors, as well as the rare acidophil stem cell tumors and poorly differentiated Pit1-lineage tumors, ii) patients with high preoperative serum pituitary hormone levels other than GH/IGF-1, iii) patients with a history of surgery, radiation or medical treatment for pituitary adenoma. 75 of 124 patients with acromegaly were pure somatotroph adenomas and constituted the final study population according to the above criterias.

Demographic, surgical, clinical, and histopathological characteristics of the patients are recorded (Table 1).

Table 1
Demographical, hormonal, pathological features and surgical treatment outcomes comparing three distinct T2-intensity groups based on preoperative sellar MRI.

	T2W Hyperintense	*T2W Hypointense*	*T2W Isointense*
Number of Patients	33	26	16
Gender (male/female)	10/23	11/15	6/10
Mean Age	24.33 ± 4.23	25.34 ± 3.84	26.04 ± 2.67
Granulation Pattern (densely/sparsely)	11 /22	12 /14	6 /10
GH level (ng/mL) [Mean ± SD / median]	6.53 ± 7.47 /3.8	19.02 ± 17.85 /8.5	6.23 ± 5.54 /4
IGF-1 level (ng/mL) [Mean ± SD / median]	489.59 ± 127.65 /468	977.33 ± 344.84 /900	629.25 ± 238.68 /550
Remission Status (Yes/No/%)	18/15, %54.5	21/5, %80.7	11/5, %68.7
Transient Diabetes Insipitus (Yes/No)	5/28	4/22	3/13
Resection(Total/Subtotal)	23/10	20/6	11/5
Dura Invasion (Yes/No)	15 /18	12 /14	7 /9
Sellar Floor Invasion(Yes/No)	9 /24	6 /20	4 /12

Biochemical and Endocrinological Assessment

Preoperative, postoperative 24-h, and 3-months serum hormone levels were measured using a solid-phase chemiluminescent method (IMMULITE 2000 hGH, Siemens, Erlangen, Germany). Endocrinological history or any previous medical treatments were also recorded, if exist. The diagnosis of acromegaly was established with increased IGF-1 level compared to normal values for age and sex and/or insuppressible GH levels during the 75 g OGTT. The remission status was determined according to the guidelines of Acromegaly Consensus Group [11]. The term “remission” emphasized that the disease is controlled.

Early (surgical) remission was achieved if GH levels during the OGTT were < 1 ng/mL, and if age and sex-adjusted IGF-1 levels were in reference intervals at postoperative third month. All patients were routinely followed-up by the Neurosurgery and Endocrinology Departments within the pre- and postoperative periods.

Immunohistochemical Evaluation

All speciemens underwent assessment by experienced pathologists and the diagnosis of each patient was confirmed via thorough immunohistochemical evaluation. Tissues obtained from pituitary adenomas were subjected to immunohistochemical examinations using antibodies for all pituitary hormones after the routine pathological preparations. Pure somatotroph adenomas were further classified as densely or sparsely granulated according to the presence of keratin aggregates known as ‘fibrous bodies’, and other pathognomonic characteristics [1].

Radiological Evaluation

Preoperative sellar MRIs were performed in all patients (Magnetom Avanto, Siemens, Erlangen, Germany). Suprasellar extension was evaluated according to the relationship between adenoma and planum sphenoidale in sagittal plane. Knosp classification was used to evaluate cavernous sinus invasion [20]. Knosp Grades 3 and 4 were considered to have cavernous sinus invasion in the adenoma [25]. The amount of resections were determined by early postoperative sellar MRI within 24 hours. No tumor on postoperative MRI was considered gross total resection (GTR).

Radiological evaluations (T2-signal intensity, suprasellar extension, Knosp grading, amount of resection) were carried out by a team with a radiologist and a neurosurgeon. The patients were divided into three groups according to the intensities of adenomas on T2-weighted MR imaging: 1) hyperintense group, 2) isointense group, and 3) hypointense group. Calculated SI values were used to classify adenomas. Coronal T2 weighted MRI images (T2W; repetition time [TR]: 2090 ms, echo time [TE]: 104 ms, slice thickness [ST]: 2.5 mm, the field of view [FOV]: 180×180 mm2, number of excitation [NEX]: 4, and matrix: 224×320) were used. The T2-intensity of the solid portion of the adenomas was visually compared with the grey and white matter of the temporal lobe. Adenoma was classified as hypointense when the MRI signal was equal to or lower than white matter and as hyperintense when the signal was equal to or higher than grey matter. Adenoma with MRI signal range between white and gray matter was defined as isointense. In case when only visual assessment could not be enough to categorize adenomas, the region of interests (ROI) were drawn in the solid part of adenomas, the grey and white matter of temporal lobe (Fig. 1).

Statistical Analysis

All statistical analyses were performed using IBM SPSS 20.0 software (SPSS Inc, Chicago, IL, USA). The data are reported as the mean ± SD for normally distributed continuous variables and as the number and percentage for dichotomous variables. Data were compared between groups using the chi-square test for categorical data and the t-test or ANOVA(or Kruskal- Wallis test as a non parametric alternative) for continuous data. A two-tailed $p < 0.05$ was considered to indicate statistically significant differences.

Results

A total of newly diagnosed 75 patients with acromegaly were included in this study, with the mean age of 24.33 ± 4.23 years in T2-hyperintense group, 25.34 ± 3.84 years in T2-hypointense group and 26.04 ± 2.67

years in T2-isointense group. There were 33 patients in the T2-hyperintense group, 26 patients in the T2-hypointense group and 16 patients in the T2-isointense group. Baseline clinical and somatotroph adenoma characteristics of the patients are shown in Table 1.

Among the groups, the percentage of women in the T2-hyperintense group was significantly higher than those of the isointense group ($p = 0.030$), and no statistically significant difference was found between the other groups in terms of gender.

The mean GH (ng/ mL) and IGF-1 (ng/ mL) levels were; 6.53 ± 7.47 and 489.59 ± 127.65 in T2W-hyperintense group, 19.02 ± 17.85 and 977.33 ± 344.84 in T2W-hypointense group, 6.23 ± 5.54 and 629.25 ± 238.68 in T2W-isointense group, respectively. Preoperative GH and IGF-1 values in the T2-hypointense group were found to be significantly higher compared to both the hyperintense and isointense groups ($p < 0.01$). The preoperative IGF-1 value in the T2-isointense group was also found to be significantly higher compared to the T2-hyperintense group ($p = 0.04$), but the difference in GH values was not statistically significant between the two groups ($p = 0.83$).

The preoperative sellar MRI characteristics of 75 newly diagnosed acromegaly cases with pure somatotroph adenomas are detailed in Table 2. No statistically significant difference was found between the groups, defined based on the preoperative T2W-intensity changes, in regard to cavernous sinus invasion, tumor size (according to modified Hardy grades) and suprasellar extension of the somatotroph adenoma ($p = 0,57$; $p = 0,24$; $p = 0,87$, respectively). Some of illustrative cases in this series are illustrated in Figs. 2–4.

Table 2

Radiologic comparison of newly diagnosed consecutive patients with acromegaly in three distinct T2-intensity groups. The table depicts the size, cavernous sinus invasion and suprasellar extension of the pure somatotroph adenomas in three T2-intensity groups.

Radiological Evaluation	**T2WHyperintense(n = 33)**	**T2WHypointense(n = 26)**	**T2WIsointense(n = 16)**
Suprasellar Extension	14	12	7
Grade A	9	8	4
Grade B	6	4	3
Grade C	4	2	2
Grade D			
Knosp Grade	4	6	3
Grade 0	9	7	5
Grade 1	11	8	4
Grade 2	7	4	2
Grade 3	2	1	2
Grade 4			
Modified Hardy's Classification Grade			
Grade 2	11	13	8
Grade 3	10	4	2
Grade 4	10	9	5
Grade 5	2	0	1
Suprasellar Extansion (SSE):			
Grade A: Moderate SSE within 10 mm above the jugum sphenoidale, filling the chiasmatic cistern			
Grade B: Large SSE, up to 20 mm, elevating the anterior recess of the third ventricle			
Grade C: Very large SSE, up to 30 mm, filling the anterior third ventricle			
Grade D: Huge SSE, in excess of 30 mm, above the level of foramina of Monro			
Knosp Grade:			
Grade 0: Adenoma does not extend the medial carotid line			
Grade 1: Adenoma extends the medial line, but does not reach the median line			

Radiological Evaluation	T2WHyperintense(n = 33)	T2WHypointense(n = 26)	T2WIsointense(n = 16)
Grade 2: Adenoma extends beyond the median line, but doesn't extend beyondor tangent to the lateral line			
Grade 3: Adenoma extends beyond the lateral line			
Grade 4: Adenoma totally wraps around the intracavernous carotid artery			
Modified Hardy's Classification:			
Grade 2: 10–20 mm in size			
Grade 3: 20–30 mm in size			
Grade 4: 30–40 mm in size			
Grade 5: >40 mm in size			

46 (61%) of the 75 pure somatotroph adenomas were classified as sparsely granulated and the remaining 29 (39%) were considered as densely granulated depending on the presence of keratin aggregates. When the distribution of the granulation patterns of 75 somatotroph adenomas were correlated with the intensity changes on the T2-weighted preoperative MRI, no statistically significant difference was detected (p = 0.60). Although statistically insignificant, somatotroph adenomas with a sparsely granulated pattern predominated in all three – hyper-, hypo-, and isointense – groups with the intensity changes on the T2-weighted image.

Dural invasion was detected in 15 patients (45%) of the T2-hyperintense group, in 12 patients (46%) within the T2-hypointense group, and in 7 patients (44%) within the T2-isointense group. Pathological examination revealed sellar floor invasion in 9 (27%) of the hyperintense, 6 (23%) of the hypointense and 4 (25%) of the isointense patients, respectively. Moreover, no statistically significant difference was found in regard to dural and/or sellar floor invasion in between the groups with intensity changes on the T2-weighted images (p = 0.54, p = 0.57).

In this study, total resection was performed in 54 (72%) of 75 newly diagnosed acromegaly patients with pure somatotroph adenomas. Accordingly, total resection was achieved in 23 (69%) of the 33 patients in the T2-hyperintense group, 20 (77%) of the 26 patients in the T2-hypointense group and 11 (69%) of the 16 patients in the T2-isointense group.

The surgical remission rates at the 3rd postoperative month for the hyper-, hypo- and isointense groups, determined according to the 2010 guidelines of *Acromegaly Consensus Group* [20], were 54.5%, 80%, and 69%, respectively. Remarkably, the surgical remission rate for T2-hyperintense group in patients with newly diagnosed acromegaly was significantly lower than that of the hypointense group (p = 0.036). There were no statistically significant differences in between the surgical remission rates of hypointense and isointense groups, although the rate of surgical remission was considerably higher in hypointense

somatotroph tumors than either hyperintense or isointense adenomas. In addition, no statistically significant difference was found between three groups in regard to the resection rates ($p > 0.05$).

There were no cases of postoperative cerebrospinal fluid leak, meningitis, cranial nerves palsy, epistaxis, sphenoid sinusitis, internal carotid artery injury and residual tumor bleeding during the postoperative course in this series. The most common postoperative complication was transient diabetes insipidus (DI) which occured in 12 (16%) patients.

Discussion

T2-weighted MRI intensity of GH-secreting adenomas varies depending on the tumoral heterogeneity, however T2-hypointensity predominates in most series of patients with acromegaly [28, 33]. The inconsistency in T2-weighted MRI intensity changes is more pronounced and differs from other types of pituitary adenomas, typically prolactinomas, which are constantly hyperintense on T2-weighted sequences [2, 12, 28]. The acromegaly literature concerning the assessment of preoperative T2-weighted MRI intensity changes to detect the amenability of complete resection and the rate of surgical remission via EETSS is still lacking. This study demonstrates a close relationship between the T2 signal intensity and the surgical remission rates, as an indicator of the degree of surgical resection completeness, in acromegaly. The surgical remission rates in the T2-hyperintense group are significantly lower than those of hypo- and isointense groups in newly diagnosed acromegaly patients. Based on these results, we belive that the T2 signal intensity changes in acromegaly may be a predictor of the degree of surgical resection and rate of remission following EETSS in pure somatotroph adenomas.

The interest in T2-weighted MRI signal intensity in acromegaly was first sparked by Hagiwara et al. [11]. Subsequently, T2W signal intensity was frequently examined as a method of predicting the effectiveness of somatostatin treatment in patients with acromegaly and incongruent data were reported [2, 15, 26]. The preferred reference tissue, in this regard, is decisive in order to standardize the results of T2W MRI intensity measurements across different centers and studies. Potorac *et al*., compared T2W signal intensity of adenomas with that of normal pituitary tissue, and this method was later postulated by Alhambra-Expósito *et al*., who similarly proposed the comparison of the signal intensity of pituitary adenomas to that of normal pituitary tissue whenever possible [2, 28]. In our study, quantitative assessment of T2-weighted signal intensity of GH-secreting adenomas is also employed and these results are compared to that of the temoral lobe cortical gray and subcortical white matter. In fact, the use of the gray matter as a comparator has been suggested because its similar signal intensity to that of the normal pituitary tissue [13]. Contrary to the already compressed and displaced normal pituitary gland due to the presence of the adenoma, the temporal lobe gray matter lacks any abnormality and preserves its natural configuration in cases with GH-secreting adenomas.

Several studies have frequently linked somatotroph adenomas to increased incidence of hypointensity on T2W MRI [2, 12, 28]. Accordingly, Potorac *et al*. and Alhambra-Expósito *et al*. reported a high prevalence of T2-hypointense GH-secreting adenomas, representing over 50% of their cases [2, 28]. This prevalence

increased to 73% in the study of Tortora *et al*., when the T2-isointense group was neglected [33]. Interestingly, we found a predominance of T2-hyperintense group in our series (45%) and the T2-hypointense adenomas were detected in only 34% of our patients. Higher frequency of T2-hyperintensity and associated abundance of aggressive tumors in this series may be linked to the relative younger median age of acromegaly patients at diagnosis.

Hyperintensity on T2W MRI has been correlated with a significantly larger somatotrop adenoma size, more invasive and proliferative tumor behaviour and higher Knosp scores, indicating more frequent cavernous sinus invasion [4, 15, 23, 26]. Also, T2-hyperintense somatotroph adenomas were associated with less GH secretion and lower IGF-1 levels in previous studies [4, 15, 23, 26]. In line with these data, the GH and IGF-1 levels in our series are considerably higher in T2-hypointense group (Table 1). Although not statistically significant, the incidence of large and giant somatotroph adenomas in this study are higher in T2-hyperintense group than those of hypo- and isointense groups, nonetheless the frequency of suprasellar extension of the adenomas are found to be similar in all groups.

The molecular characteristics, although not completely understood, have been correlated with T2-weighted MRI signal intensity through the granulation pattern of the adenoma. Hypointensity on T2W MRI has been previously linked to a densely granulated cell pattern in acromegalic patients as described by Hagiwara *et al*. and the signal hypointensity has been attributed to the abundance of high protein content tissue due to the intense hypersecretory activity of densely granulated somatotropinomas [12, 29]. In this regard, less frequent optic chiasm compression and cavernous sinus invasion have been documented in densely-granulated T2-hypointense group among GH secreting macroadenomas [4]. Studies have also indicated close relationship between T2-hyperintensity on MRI and the sparsely-granulated adenomas in acromegaly [12, 26, 29]. Contrarily, sparsely-granulated somatotroph adenomas are generally considered as a rapidly growing tumor with an invasive nature and are larger at diagnosis, compared to densely-granulated tumors [1, 16]. However, the increased incidence of cavernous sinus invasion in sparsely-granulated somatotroph adenomas compared to densely-granulated tumors has been questioned and the results are inconsistent in the literature [13]. In our series, no statistically significant difference was found in between the T2-intensity groups for the size, the sellar floor and dural invasion and the Knosp grading of adenomas (Table 2). Our findings does not indicate a positive correlation between the granulation pattern of the somatotroph adenomas and the T2W MRI intensity characterisitcs.

The past decade has seen a number of acromegaly studies dealing with the changes in T2 signal intensity in order to predict the therapeutic response to medical treatment [14, 31]. In a a pioneer study evaluating the value of MRI as a predictor of therapeutic response in acromegaly, Puig-Domingo *et al*. demonstrated that T2 signal can identify responsiveness to somatostatin analogs in patients after unsuccessful surgery [29]. Similarly, Heck *et al*. reported that T2-hypointense adenomas had a better hormonal response to presurgically administered somatostatin analogs, suggesting that T2-hypointensity might be a useful pre-operative marker of somatostatin analogs response [13, 15]. An expanding body of evidence has led to the view that the presence of T2-hypointensity on sellar MRI predicts a favorable

response to somatostatin analogs in GH-secreting pituitary adenomas [8, 10, 14, 19, 31, 33]. Accordingly, these findings raise intriguing question about whether T2-hypointense GH-secreting pituitary adenomas could be more amenable to complete resection as compared with T2-hyperintense and T2- isointense adenomas [28].

The literature has been inconsistent regarding correlation of GH tumor subtypes and surgical remission in acromegaly, as a result the surgical response based on GH tumor subtype is still to be determined [13, 17, 21]. In 2001, Mazal *et al*. reported a higher rate of incomplete resection and additional surgical interventions in patients with sparsely-granulated tumors [22]. Recently, Kiseljak-Vassiliades *et al*. emphasized that densely- granulated GH secreting pituitary adenomas had a much higher rate of remission in response to surgery compared to its sparsely granulated counterpart, 66% vs. 14% [19]. Contrarily, Brzana *et al*. did not find any significant difference between sparsely- and densely-granulated tumors [5, 13]. In this regard, the relationship between T2 signal intensity of the pituitary adenoma and the surgical remission rates in acromegaly patients undergoing EETSS has not been reported in the literature.

Our study presents the novel finding regarding the relationship between T2 intensity changes and the results of surgery for acromegaly and clearly demonstrates that the presence of T2-hyperintensity on preoperative sellar MRI predicts a unfavorable response to surgical treatment. In fact, the surgical remission rate for T2-hyperintense GH secreting pituitary adenomas in newly diagnosed acromegaly patients is significantly lower than that of the hypointense group. We believe that T2 signal intensity, apart from the granulation pattern of adenoma, has an independent predictive value for surgical remission acromegaly. In this vein, Potorac *et al*. suggest that T2-isointense GH secreting adenomas might in future be grouped along with hyperintense tumors into a single non-hypointense category that has significantly worse response rates to primary somatostatin analogs not only in terms of hormonal but also anti-tumoral effects [28].

In this study, total resection was performed in 72% of newly diagnosed acromegaly patients and no statistically significant difference was found between three T2 intensity groups in regard to the resection rates. Although all tumors in our study were macroadenomas, the incidence of large and giant adenomas were considerably higher in the T2-hyperintense group. Interestingly, no statistically significant difference was found for tumor size, a potential factor that may affect remission rates, in between the T2-intensity groups. Since the resection rates are not significantly different between the groups, we attribute the significantly lower remission rates in the T2-hyperintense group to the microscopic residues that could not be detected in the post-operative MRI.

In conclusion, preoperative T2-intensity may directly predict the probability of post-surgical remission as an important independent factor in patients with newly diagnosed acromegaly. Further support for this idea comes from recent guidelines for acromegaly management in which the potential utility of using T2 intensity to optimize patient management has been emphasized.

Declarations

Funding

The author(s) received no financial support for the research, authorship, and/or publication of this article

Conflicts Of Interest

On behalf of all authors, the corresponding author states that there is no other conflict of interest.

Availability of data and material

Not applicable

Code availability

Not applicable

Ethics approval

All procedures performed in the studies involving human participants were in accordance with the ethical standards of the institutional and/or national research committee and with the 1964 Helsinki Declaration and its later amendments or comparable ethical standards.

Consent to participate

Informed consent was obtained from all individual participants included in the study. Additional informed consent was obtained from all individual participants for whom identifying information is included in this article.

Consent for publication

Not applicable

Authors' contributions

Enes Akkaya: Methodology, Data curation. Mehmet Yigit Akgun: Conceptualization, Methodology, Data curation, Writing - original draft, Formal analysis. Emine Sebnem Durmaz: Methodology, Data curation. Seckin Aydin: Methodology, Data curation. Hande Mefkure Ozkaya: Methodology, Data curation. Osman Kizilkilic: Methadology. Nurperi Gazioglu: Visualization. Pinar Kadioglu: Visualization. Necmettin Tanriover: Conceptualization, Visualization, Writing - review & editing

References

1. Akirov A, Asa SL, Amer L, Shimon I, Ezzat S. (2019) The Clinicopathological Spectrum of Acromegaly. J Clin Med. Nov 13;8(11):1962.
2. Alhambra-Expósito MR, Ibáñez-Costa A, Moreno-Moreno P, Esther Rivero-Cortés E, Vázquez-Borrego MC, Blanco-Acevedo C, et al. (2018) Association between radiological parameters and clinical and molecular characteristics in human somatotropinomas. Sci Rep. Apr 18;8(1):6173.
3. Aydin S, Ozoner B, Sahin S, Alizada O, Comunoglu N, Oz B, et al. A follow-up study on outcomes of endoscopic transsphenoidal approach for acromegaly. Clin Neurol Neurosurg. 2020 Sep 4;198:106201.
4. Bakhtiar Y, Hanaya R, Tokimura H, Hirano H, Oyoshi T, Fujio S, et al. (2014) Geometric survey on magnetic resonance imaging of growth hormone producing pituitary adenoma. Pituitary. Apr;17(2):142-9.
5. Brzana J, Yedinak CG, Gultekin SH, Delashaw JB, Fleseriu M. (2013) Growth hormone granulation pattern and somatostatin receptor subtype 2A correlate with postoperative somatostatin receptor ligand response in acromegaly: a large single center experience. Pituitary. 16(4):490-8.
6. Cuevas-Ramos D, Carmichael JD, Cooper O, Bonert VS, Gertych A, Mamelak AN, et al. (2015) A structural and functional acromegaly classification. J Clin Endocrinol Metab. 100(1):122-31.
7. Daly AF, Rixhon M, Adam C, Dempegioti A, Tichomirowa MA, Beckers A. (2006) High prevalence of pituitary adenomas: a cross-sectional study in the province of Liege, Belgium. J Clin Endocrinol Metab. 91(12):4769-75.
8. Dogansen SC, Yalin GY, Tanrikulu S, Tekin S, Nizam N, Bilgic B, et al. (2018) Clinicopathological significance of baseline T2-weighted signal intensity in functional pituitary adenomas. Pituitary. Aug;21(4):347-354.
9. Fernandez A, Karavitaki N, Wass JA. (2010) Prevalence of pituitary adenomas: a community-based, cross-sectional study in Banbury (Oxfordshire, UK). Clin Endocrinol (Oxf). 72(3):377-82.
10. Fougner SL, Casar-Borota O, Heck A, Berg JP, Bollerslev J. (2012) Adenoma granulation pattern correlates with clinical variables and effect of somatostatin analogue treatment in a large series of patients with acromegaly. Clin Endocrinol (Oxf). Jan;76(1):96-102.
11. Giustina A, Chanson P, Bronstein MD, Klibanski A, Lamberts S, Casanueva FF, et al. (2010) A Consensus on Criteria for Cure of Acromegaly. J Clin Endocrinol Metab. Jul;95(7):3141-8
12. Hagiwara A, Inoue Y, Wakasa K, Haba T, Tashiro T, Miyamoto T. (2003) Comparison of growth hormone-producing and non-growth hormone-producing pituitary adenomas: imaging characteristics and pathologic correlation. Radiology. 228(2):533-8.
13. Heck A, Emblem KE, Casar-Borota O, Bollerslev J, Ringstad G. (2016) Quantitative analyses of T2-weighted MRI as a potential marker for response to somatostatin analogs in newly diagnosed acromegaly. Endocrine. 52(2):333-43.
14. Heck A, Emblem KE, Casar-Borota O, Ringstad G, Bollerslev J. (2016) MRI T2 characteristics in somatotroph adenomas following somatostatin analog treatment in acromegaly. Endocrine. 53(1):327–330.

15. Heck A, Ringstad G, Fougner SL, Casar-Borota O, Nome T, Ramm-Pettersen J, et al. (2012) Intensity of pituitary adenoma on T2-weighted magnetic resonance imaging predicts the response to octreotide treatment in newly diagnosed acromegaly. Clin Endocrinol (Oxf). 77(1):72-8.
16. Ibáñez-Costa A, Korbonits M. (2017) AIP and the somatostatin system in pituitary tumours. J Endocrinol. Dec;235(3):R101-R116.
17. Kato M, Inoshita N, Sugiyama T, Tani Y, Shichiri M, Sano T, et al. (2012) Differential expression of genes related to drug responsiveness between sparsely and densely granulated somatotroph adenomas. Endocr J. 59(3):221-8.
18. Katznelson L, Laws ER, Jr., Melmed S, Molitch ME, Murad MH, Utz A, et al. (2014) Acromegaly: an endocrine society clinical practice guideline. J Clin Endocrinol Metab. 99(11):3933-51.
19. Kiseljak-Vassiliades K, Carlson NE, Borges MT, Kleinschmidt-DeMasters BK, Lillehei KO, Kerr JM, et al. (2015) Growth hormone tumor histological subtypes predict response to surgical and medical therapy. Endocrine. 49(1):231-41.
20. Knosp E , Steiner E, Kitz K, Matula C. (1993) Pituitary adenomas with invasion of the cavernous sinus space: a magnetic resonance imaging classification compared with surgical findings. Neurosurgery. Oct;33(4):610-7; discussion 617-8.
21. Larkin S, Reddy R, Karavitaki N, Cudlip S, Wass J, Ansorge O. (2013) Granulation pattern, but not GSP or GHR mutation, is associated with clinical characteristics in somatostatin-naive patients with somatotroph adenomas. Eur J Endocrinol. Mar 15;168(4):491-9.
22. Mazal PR, Czech T, Sedivy R, Aichholzer M, Wanschitz J, Klupp N, et al. (2001) Prognostic relevance of intracytoplasmic cytokeratin pattern, hormone expression profile, and cell proliferation in pituitary adenomas of akromegalic patients. Clin Neuropathol. Jul-Aug;20(4):163-71.
23. Melmed S. (2009) Acromegaly pathogenesis and treatment. J Clin Invest. Nov;119(11):3189-202.
24. Melmed S. (2016) New therapeutic agents for acromegaly. Nat Rev Endocrinol. Feb;12(2):90-8.
25. Micko SGA, Wöhrer A, Wolfsberger S, Knosp E. (2015) Invasion of the cavernous sinus space in pituitary adenomas: endoscopic verification and its correlation with an MRI-based classification. J Neurosurg. Apr;122(4):803-11.
26. Potorac I, Beckers A, Bonneville JF. (2017) T2-weighted MRI signal intensity as a predictor of hormonal and tumoral responses to somatostatin receptor ligands in acromegaly: a perspective. Pituitary. Feb;20(1):116-120.
27. Potorac I, Petrossians P, Daly AF, Alexopoulou O, Borot S, Sahnoun-Fathallah M, et al. (2016) T2-weighted MRI signal predicts hormone and tumor responses to somatostatin analogs in acromegaly. Endocr Relat Cancer. 23(11):871-81.
28. Potorac I, Petrossians P, Daly AF, Schillo F, Ben Slama C, Nagi S, et al. (2015) Pituitary MRI characteristics in 297 acromegaly patients based on T2-weighted sequences. Endocr Relat Cancer. 22(2):169-77.
29. Puig-Domingo M, Resmini E, Gomez-Anson B, Nicolau J, Mora M, Palomera E, et al. (2010) Magnetic resonance imaging as a predictor of response to somatostatin analogs in acromegaly after surgical

failure. J Clin Endocrinol Metab. 95(11):4973-8.

30. Sarkar S, Rajaratnam S, Chacko G, Chacko AG. (2014) Endocrinological outcomes following endoscopic and microscopic transsphenoidal surgery in 113 patients with acromegaly. Clin Neurol Neurosurg. 126:190-5.
31. Shen M, Zhang Q, Liu W, Wang M, Zhu J, Ma Z, et al. (2016) Predictive value of T2 relative signal intensity for response to somatostatin analogs in newly diagnosed acromegaly. Neuroradiology. 58(11):1057–1065.
32. Starke RM, Raper DM, Payne SC, Vance ML, Oldfield EH, Jane JA, Jr. (2013) Endoscopic vs microsurgical transsphenoidal surgery for acromegaly: outcomes in a concurrent series of patients using modern criteria for remission. J Clin Endocrinol Metab. 98(8):3190-8.
33. Tortora F, Negro A, Grasso LFS, Colao A, Pivonello R, Splendiani A,et al. (2019) Pituitary magnetic resonance imaging predictive role in the therapeutic response of growth hormone-secreting pituitary adenomas. Gland Surg. Sep;8(Suppl 3):S150-S158.

Figures

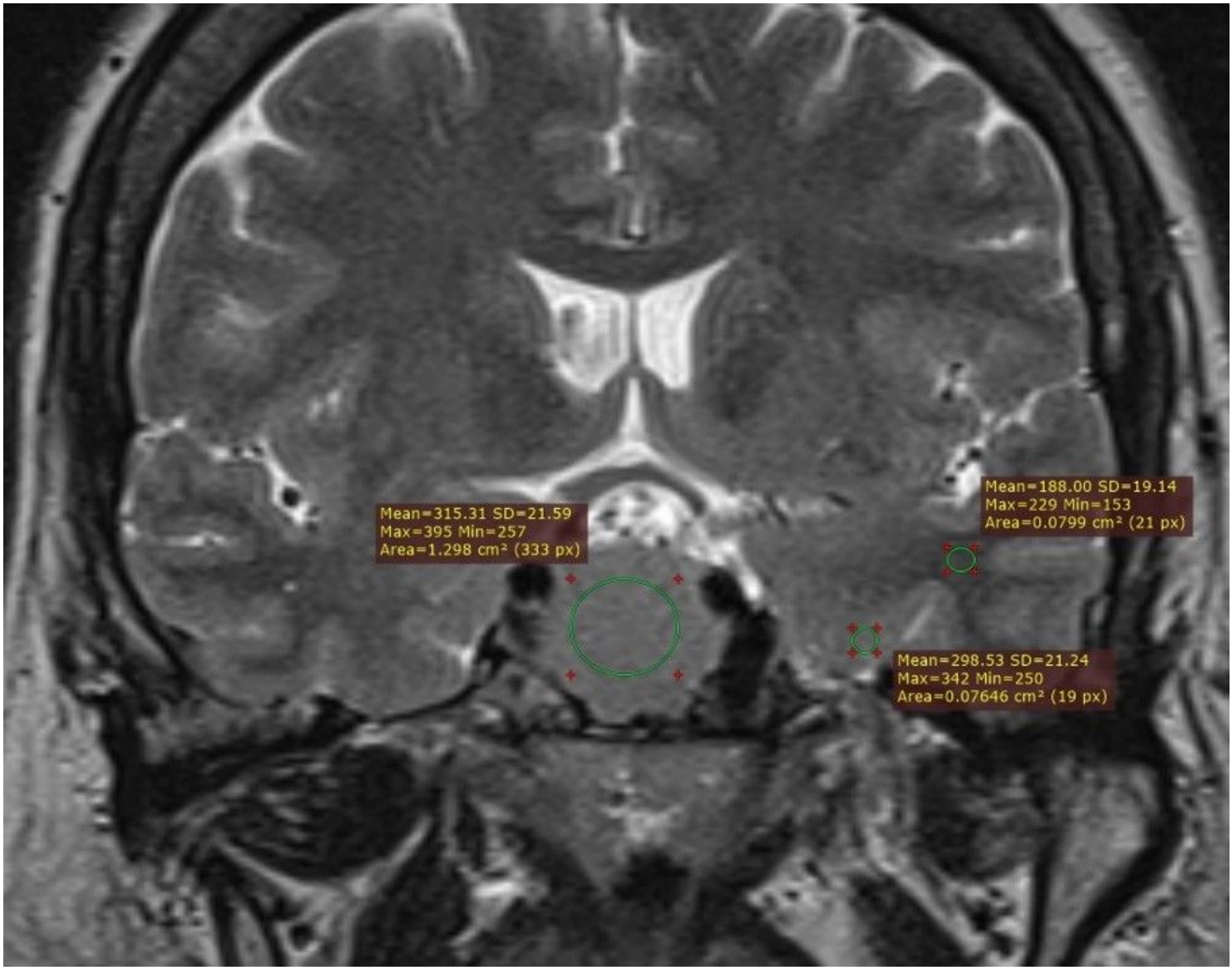

Figure 1

Coronal T2 weighted MRI image (T2W; repetition time [TR]: 2090 ms, echo time [TE]: 104 ms, slice thickness [ST]: 2.5 mm, the field of view [FOV]: 180×180 mm2, number of excitation [NEX]: 4, and matrix: 224×320) depicting the measurement of T2-Weighted MRI intensity in this study. The T2-intensity of the solid portion of the adenoma has been compared with that of the grey and white matter of temporal lobe. The regions of interest (ROIs) has been demonstrated in the solid part of adenomas, the grey and white matter of temporal lobe.

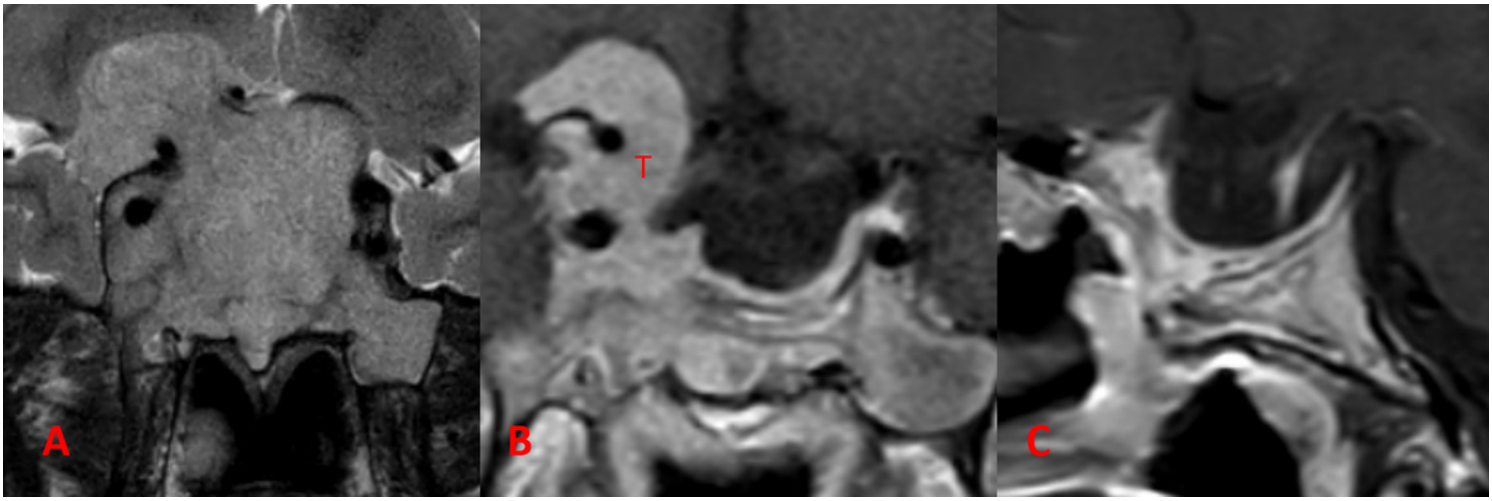

Figure 2

Preoperative (A) T2- weighted coronal and postoperative (B and C) contrast enhanced T1-weighted coronal-sagittal plane MR images obtained in a 51 years old male acromegalic patient who underwent resection of a T2W hyperintense giant pituitary adenoma. Surgical remission could not be achieved and the residual tumor within the right cavernous sinus has been documented in the postoperative MR images (T). The patient received somatostatin analogues during the postoperative period. Preoperative GH/IGF-1 (ng/ mL) values: 10.5 / 593 Postoperative GH/IGF-1 (ng/ mL) values 3 months after surgery: 7.8 / 494. T: Tumor

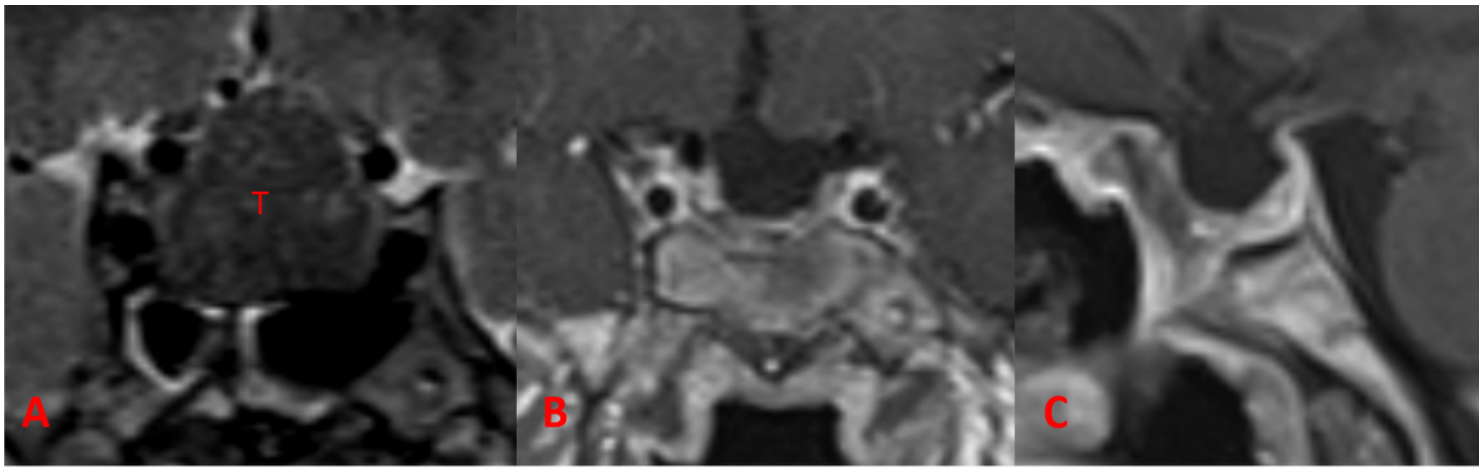

Figure 3

Preoperative (A) T2- weighted coronal and early postoperative (B and C) contrast enhanced T1-weighted coronal-sagittal plane MR images obtained in a 48 years old female acromegalic patient who underwent resection of a T2W hypointense macroadenoma. Total resection was performed and surgical remission has been achieved. Preoperative GH/IGF-1 (ng/ mL) values: 50 / 981, Postoperative GH/IGF-1 (ng/ mL) values 3 months after surgery: 0.7 / 200. T: Tumor

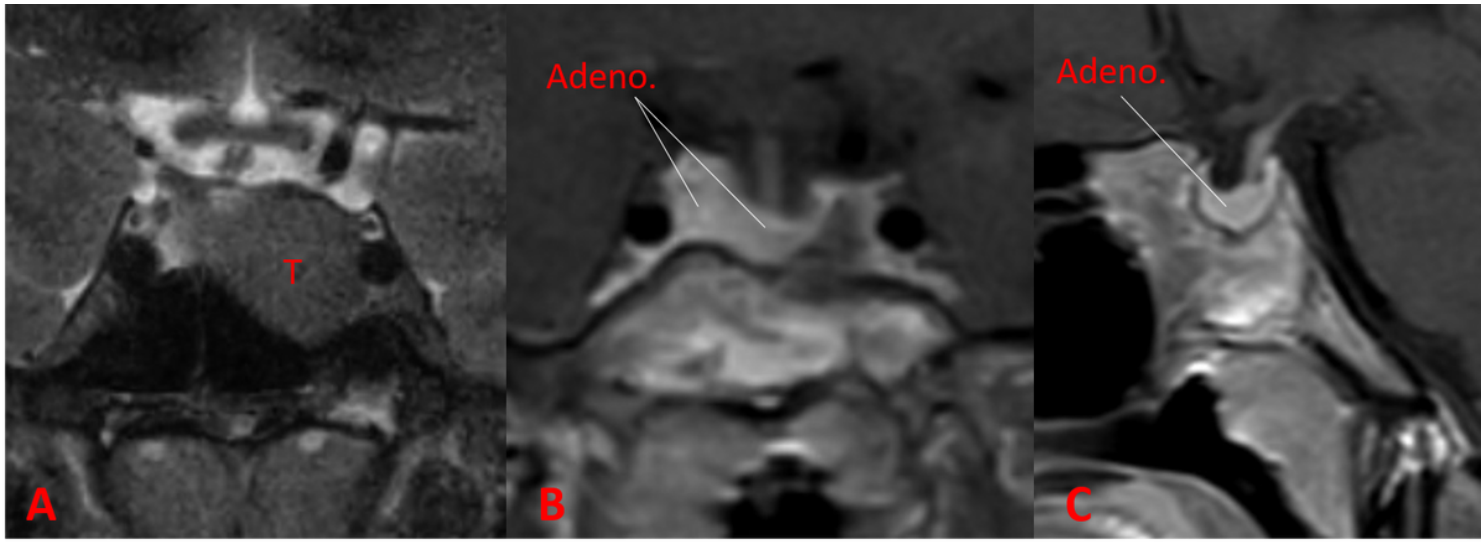

Figure 4

Preoperative (A) T2- weighted coronal and postoperative (B and C) contrast enhanced T1-weighted coronal plane MR images obtained in a 37 years old female acromegalic patient who underwent resection of a T2W isointense macroadenoma. Total resection and surgical remission has been achieved. Preoperative GH/IGF-1 (ng/ mL) values: 4.3 / 401 Postoperative GH/IGF-1 (ng/ mL) values: 0.4 / 191. Adeno.: Adenohypophysis (normal pituitary gland), T: Tumor