Modification of the Classical Percutaneous Extraperitoneal Procedure for Pediatric Inguinal Hernia to Reduce Complications: A Multiple-Centered Comparison Study

Zhi-bin Luo
Department of Pediatric Surgery, Union Hospital, Tongji Medical College, Huazhong University of Science and Technology, Wuhan 430022, China

Jing-rong Tu
Department of Pediatric Surgery, Union Hospital, Tongji Medical College, Huazhong University of Science and Technology, Wuhan 430022, China

Hong-guang Shi
Department of Pediatric Surgery, the Third Affiliated Hospital of Zhengzhou University, Zhengzhou450052, China

Zhi-yong Du
Department of Pediatric Surgery, the No. 1 People's Hospital of Yichang, Yichang443000, China

Xian-cai Xiang
Department of Pediatric Surgery, Minda Hospital of Hubei Minzu University, Enshi445000, China

Shui-qing Chi
Department of Pediatric Surgery, Union Hospital, Tongji Medical College, Huazhong University of Science and Technology, Wuhan 430022, China

De-hua Yang
Department of Pediatric Surgery, Union Hospital, Tongji Medical College, Huazhong University of Science and Technology, Wuhan 430022, China

Kang Li
Department of Pediatric Surgery, Union Hospital, Tongji Medical College, Huazhong University of Science and Technology, Wuhan 430022, China

Shuai Li (179857830@qq.com)
Department of Pediatric Surgery, Union Hospital, Tongji Medical College, Huazhong University of Science and Technology, Wuhan 430022, China

Shao-tao Tang
Department of Pediatric Surgery, Union Hospital, Tongji Medical College, Huazhong University of Science and Technology, Wuhan 430022, China

Research Article

Keywords: percutaneous, extraperitoneal, pediatric

Posted Date: March 2nd, 2021

DOI: https://doi.org/10.21203/rs.3.rs-252361/v1

Abstract

Single-site laparoscopic percutaneous extraperitoneal ligation (SLPEL) for pediatric inguinal hernia gained popularity all over the world. However, complications associated with extraperitoneal knotting were not rare in the classical SLPEL(C-SLPEL) procedure. In order to overcome disadvantages, we herein developed the modified SLPEL (M-SLPEL) procedure, intact circuit ligation of the peritoneum around the internal ring using a homemade hernia needle with a single abdominal wall centesis. To evaluated the effectiveness of the M-SLPEL procedure to decrease adverse events associated with ligation knotting, a comparative study was carried out. A total of 3219 patients from multiple centers were divided into two groups according to the operative procedures: M-SLPEL group and C-SLPEL group. All patients were followed up. Data describing the clinical characteristics, operative time, postoperative hospital stay, and complications was collected and retrospectively analyzed. With equivalent operative time, postoperative hospital stay, there was statistically significant difference between two groups in terms of the overall complications incidence (2.6% in C-SLPEL Vs 0.11% in M-SLPEL, P=0.03), including pain in inguinal area, knot foreign body reaction, palpable knot, recurrence. Together, these findings suggest that the M-SLPEL procedure is an effective and safe approach, with unique advantage in reducing adverse events in the inguinal region.

Introduction

Indirect inguinal hernia is one of the most common anomalies in pediatric surgery, and ligation of the internal ring by either open or laparoscopic operation is the most effective treatment [1–3]. With the continuous innovation of instruments and the development of laparoscopic manipulation, numerous minimally invasive surgical modifications have been developed since the 1990s. To our knowledge, popular laparoscopic inguinal hernia repair procedures used worldwide for children can be roughly divided into two broad categories: direct purse string suture of the internal ring and extraperitoneal ligation of the internal ring using a hernia needle[4,5]. Purse string suture of the internal ring is a relative technique-demanding procedure for surgeons, while laparoscopic extraperitoneal ligation (known as SLPEL) can greatly simplify the surgical procedure[2,6].

Recently, SLPEL has gained popularity with patients and their parents due to cosmetic concerns[1,6,7]. However, according to the literature, infection, pain, palpable thread knot and other adverse events associated with extraperitoneal knotting could occur in classical SLPEL procedure[2,6,8]. Twice punctures of the abdominal wall might be the main cause.

To overcome these disadvantages, either direct purse string suture with intraperitoneal knotting which is more technique-demanding or extraperitoneal ligation of the internal ring which requires a well designed hernia needle should be applied[9]. We herein developed a one-puncture SLPEL procedure using only a common hernia needle. A comparative study between this procedure and the classical SLPEL procedure was carried out and the results was reported here.

Results

A total of 3219 patients underwent this procedure and had a smooth recovery. The male-to-female ratio was around 9:1. Among these patients, 582 had a unilateral hernia (1802 right-sided and 621 left-sided), and 796 had bilateral hernias. A total of 582 patients diagnosed with unilateral hernia before operation (259 left-sided and 323 right-sided) were confirmed to have a contralateral patent processus vaginalis (PPV) by intraoperative laparoscopic exploration. The overall incidence of contralateral PPV was 19.4% (12.6% from the previous right-sided cases and 34.2% from the left-sided cases). The overall mean operative time was 12.2 ± 1.5 minutes for unilateral hernias (12.5 ± 1.8 min in C-group Vs 11.7 ± 1.3 min in M-group) and 14.9 ± 1.3 minutes (15.1 ± 2.1 min in C-group Vs 14.6 ± 1.7 min in M-group) for bilateral.

No hematoma occurred around spermatic vessels. No umbilical hernia, iatrogenic cryptorchidism, testicular atrophy, hydrocele, or scrotal edema developed postoperatively. The average hospital stay was 1.3 ± 1.0 days (1.4 ± 1.1 in C-group Vs 1.0 ± 0.8 in M-group). 30% patients were discharged in 12 hours after the operation and 50% in 24 hours. Incarcerated hernia cases were observed for an additional 3 days. All patients were followed up for 9–77 months (mean, 55 months). No obvious scars were visible on the abdomen by one month after the operation. In modified group, recurrence was noted in one patient with an incarcerated hernia (age, 15 months) at 7 days after the operation. No adverse events, such as pain, foreign body reaction, and palpable knot occurred in the inguinal region. While in the classical group, 8 cases recurred during the follow-up, and were repaired again using the same method (Table 1). 16 cases complained inguinal pain, 12 cases got foreign body reaction and 25 had palpable knot in the inguinal region. The overall complications rate of the two groups was 2.6% and 0.11%, respectively ($P<0.01$).

Table 1
Patients' characteristics (n = 3219)

Parameters	Total	Classical	Modified	P (C Vs M)
Mean age	2.63 ± 1.54 years(1 months to 14 years)	2.56 ± 1.46 years (1 months to 14 years)	2.78 ± 2.03 years(2 months to 12 years)	0.79
No. of cases	3219	2367	852	NA
Sex				0.83
Male	2901(90.1%)	2126(89.8%)	775(91.0%)	
Female	318	241	77	
Side of hernia				NA
Right	1802(56.0%)	1291(54.5%)	511(60.0%)	
Left	621(20.3%)	490(20.7%)	131(16.4%)	
Bilateral	796(24.7%)	586(24.8%)	210(24.6%)	
contralateral PPV(confirmed during operation)	582 (259 on the right group and 323 on the left)(19.4%)	420 (171 on the right group and 249 on the left)(19.1%)	162 (62 on the right group and 100 on the left) (20.1%)	0.27
Mean operative time				
Unilateral	12.2 ± 1.5 min	12.5 ± 1.8 min	11.7 ± 1.3 min	0.58
Bilateral	14.9 ± 1.3 min	15.1 ± 2.1 min	14.6 ± 1.7 min	0.65
Hospital stay	1.3 ± 1.0 d	1.4 ± 1.1 d	1.0 ± 0.8 d	0.16
Complications		61	1	<0.01
Pain in inguinal area	16	16	0	
Knot foreign body reaction	12	12	0	
Palpable knot	25	25	0	
Scrotal hematoma	0	0	0	
Spermatic cord injury	0	0	0	
Recurrence	9	8	1	

Discussion

Inguinal hernia is a common surgical condition in pediatric surgery with an incidence between 0.8% and 4.4% [10]. SLPEL was first described by Takehara in 2006 for the treatment of inguinal hernias[11]. In the minimally invasive era, there has been an increasing trend among pediatric surgical centers to correct anomalies using fewer and smaller incisions[12,13]. Therefore, a considerable number of surgeons have started to perform SLPEL for pediatric inguinal hernia[11].

However, complications associated with the ligation knot require advanced modification of the surgical instruments or the procedure itself. Preventive measures should be applied to avoid unnecessary ligation of subcutaneous tissues[14]. The C-SLPEL uses a simple hernia needle and involves twice hernia needle insertions; the first insertion is used to pass the medial semicircle of the internal ring and introduce the thread tail, while the second insertion is used to pass the other semicircle of the internal ring and retract the tail from the peritoneal cavity with a wire loop[11]. Because most postoperative complications are caused by the ligation of extra tissues into the knot as a consequence of repeated puncture of the abdominal wall, we developed a one-puncture approach(Fig. 3). In the M-SLPEL procedure, the needle is pulled back to the space just outside of the peritoneum layer after the only puncture and continually passed through the outside half ring instead of being removed and performing a second puncture（Fig. 3C-D）. Then, the wire loop, which has some elasticity (we prefer the Prolene line), is introduced to retract the thread tail through the same peritoneal puncture. The grasper is essential during this procedure for flattening the peritoneum fold around the internal ring and retracting the thread tail into the wire loop（Fig. 3E）. In addition, to prevent the ligation of abdominal wall tissue around the puncture route, the abdominal wall is pulled once after the placement of each knot starting with the second knot. However, these maneuvers cannot be as easily accomplished without a well designed hernia needle before[9].

The recently reported recurrence rate of laparoscopic inguinal hernia repair in children is 0.3–1.2%[15]. Many factors can cause hernia recurrence. Some are due to technical problems, including leaving a peritoneal gap when the thread is passed through the internal ring, ligation loosening due to inappropriate or inadequate knotting, and using absorbable sutures[2,16–18]. According to the data, this series had a very low recurrence rate. The possible reasons were as follows: first, we performed a complete extraperitoneal ligation without a peritoneal gap, and the puncture hole caused tissue adhesion; second, we applied a single puncture procedure without ligating any tissue of the abdominal wall.

A significant advantage of laparoscopic ligation is the ability to inspect contralateral defects, which potentially avoids a second operation and additional incision[19–22]. In pediatric patients, the incidence of recessive hernia is 20.0–43%[23]. In this series, the overall incidence of contralateral PPV was 19.4%, which is consistent with the reported data.

The cosmetic result is an important aspect for assessing the improvement of a modified operation[7]. Parent’s satisfaction regarding wound appearance is significantly better after laparoscopic surgery than

open surgery[1,2]. In either procedure, the 5-mm trocar incision scar and the other 3-mm incision for the forceps along the umbilical ring were hidden within the umbilicus fossa. The stab incision in the inguinal area was on the abdominal transvers striae. By reducing the number of incisions and making them in hidden areas, a better cosmetic result was achieved. No obvious scar was visible at one month after the operation.

In conclusion, the M-SLPEL procedure is a safe and effective approach with a low recurrence rate, fewer postoperative complications and a better cosmetic appearance. The hernia needle is simple and easy to obtain, making the procedure suitable for promotion in wider regions.

Materials And Methods

The study protocol was reviewed and approved by the Ethics Committee of the Union Hospital of Tongji Medical College, Huazhong University of Science and Technology, Wuhan, China.Informed consent was obtained from all participants and/or their legal guardians before the operation. Research have been performed in accordance with the Declaration of Helsinki.

Patients

A total of 3219 patients (2901 boys and 318 girls) who underwent laparoscopic hernia high ligation from January 1, 2014, to September 30, 2019 in these four tertiary medical centers were included in this study. These cases were divided into two groups as the classical group (C-SLPEL, n = 2367) and the modified group (M-SLPEL, n = 852) according to the procedure. There were 2061 right-sided, 944 left-sided, and 214 bilateral hernia openings presented, including 5 incarcerated cases (Table 1). Data describing the general information, operative time (from the initial incision to incision closure), postoperative hospital stay, and complications were collected.

Surgical procedure

M-SLPEL

Under general anesthesia, the patient was placed in the Trendelenburg position. The surgical area was routinely prepared and draped. A monitor was placed at the patient’s feet. A 5-mm trocar was placed using the open technique through a 5-mm trans-umbilical incision into the peritoneal cavity to establish pneumoperitoneum (Fig. 1A). The insufflation pressure was maintained between 6 mmHg and 12 mmHg according to patient age.

A hooked needle was constructed from an epidural needle with the tip slightly bent (Fig. 1B). A 5-mm, 30° laparoscope was introduced, and the whole abdominal cavity was inspected. A 3-mm grasper was inserted into the peritoneal cavity without using a trocar through a 3-mm incision on the umbilical ring to the left of the laparoscope (Fig. 1A). A 2 – 0 nonabsorbable silk thread was introduced through the needle with a tail of 5 cm protruding outside the tip of the needle (Fig. 1B). The needle was used to puncture the

anterior abdominal wall in layers using one 1.5-mm stab incision immediately above the internal inguinal ring (Fig. 2A), and the needle was stopped by the peritoneum. The 3-mm grasper was used to grasp and smooth the peritoneal folds between the vas deferens, vessels, and adjacent structures. The needle was manipulated to first pass through the medial half of the margin of the inguinal ring (Fig. 2B) and puncture the peritoneum, and then, the tail of the silk thread was left in the peritoneal cavity. Next, the needle was slowly retracted into the extraperitoneal space (Fig. 2C), continually advanced around the outside half of the ring and then inserted into the peritoneal cavity again through the same hole (Fig. 2D-F). A loop made of 2 – 0 Prolene line was introduced into the abdominal cavity through the hernia needle (Fig. 2G). The tail of the silk thread was grasped through the Prolene loop (Fig. 2H-I). Then, the hernia needle was pulled back, together with the Prolene loop and the silk tail, out of the abdominal wall (Fig. 2J). The inguinal ring was ligated using the silk thread (Fig. 2K) after withdrawing the air and/or fluid from the hernia cavity with the assistant helping to slightly pull the scrotum down to keep the vas deferens away from the peritoneum. The silk thread was knotted three times. The thread was cut adjacent to the skin. Finally, the abdominal wall was lifted to allow the knot to return to the extraperitoneal space (Fig. 2L). The incisions were closed after releasing the pneumoperitoneum (Fig. 1C).

C-SLPEL

The classical procedure was done according to the reported[11,23].

Statistical analysis

Data were analyzed using SPSS version 25.0 statistical software (IBM Corp., Armonk, NY, USA). Continuous data are expressed as the mean ± standard deviation or median (IQR) and students-t test was applied. Categorical variables are expressed as the frequency, number and percentage, and chi-square test was used.

Declarations

Data Availability:

All data generated or analysed during this study are included in this published article

Author contributions

S.L. and S.T.T contributed to the study conception and design. Material preparation, data collection and analysis were performed by Z.B.L. and J.R.T.. The first draft of the manuscript was written by Z.B.L. and J.R.T.. All authors commented on previous versions of the manuscript. All authors read and approved the final manuscript.

Competing financial interests:

The authors declare no competing financial interests.

References

1. Yonggang, H. *et al.* Single-port laparoscopic percutaneous extraperitoneal closure of inguinal hernia using "two-hooked" core needle apparatus in children. *Hernia.* **23**, 1267–1273 https://doi.org/10.1007/s10029-019-01933-9 (2019).
2. Wang, Y. J. *et al.* Laparoscopic Percutaneous Extraperitoneal Internal Ring Closure for Pediatric Inguinal Hernia: 1,142 Cases. *J Laparoendosc Adv Surg Tech A.* **29**, 845–851 https://doi.org/10.1089/lap.2018.0721 (2019).
3. Chu, C. B. *et al.* Individualized treatment of pediatric inguinal hernia reduces adolescent recurrence rate: an analysis of 3006 cases. *Surg Today.* **50**, 499–508 https://doi.org/10.1007/s00595-019-01940-4 (2020).
4. Li, S. *et al.* A Modified Approach for Inguinal Hernias in Children: Hybrid Single-Incision Laparoscopic Intraperitoneal Ligation. *J Laparoendosc Adv Surg Tech A.* **25**, 689–693 https://doi.org/10.1089/lap.2014.0474 (2015).
5. McClain, L., Streck, C., Lesher, A., Cina, R. & Hebra, A. Laparoscopic needle-assisted inguinal hernia repair in 495 children. *Surg Endosc.* **29**, 781–786 https://doi.org/10.1007/s00464-014-3739-8 (2015).
6. Uchida, H. *et al.* Inguinal hernia repair in children using single-incision laparoscopic-assisted percutaneous extraperitoneal closure. *J Pediatr Surg.* **45**, 2386–2389 (2010).
7. Shalaby, R. *et al.* One trocar needlescopic assisted inguinal hernia repair in children: a novel technique. *J Pediatr Surg.* https://doi.org/10.1016/j.jpedsurg.2017.08.020 (2017).
8. Shalaby, R. *et al.* Needlescopic assisted internal ring suturing; a novel application of low-cost home-made instruments for pediatric inguinal hernia repair. *Hernia.* **23**, 1279–1289 https://doi.org/10.1007/s10029-019-01982-0 (2019).
9. Li, S., Li, M., Wong, K. K., Liu, L. & Tam, P. K. Laparoscopically assisted simple suturing obliteration (LASSO) of the internal ring using an epidural needle: a handy single-port laparoscopic herniorrhaphy in children. *J Pediatr Surg.* **49**, 1818–1820 https://doi.org/10.1016/j.jpedsurg.2014.09.027 (2014).
10. Chen, R. *et al.* A 9-year experience study of single-port micro-laparoscopic repair of pediatric inguinal hernia using a simple needle. *Hernia.* **24**, 639–644 https://doi.org/10.1007/s10029-019-02079-4 (2020).
11. Takehara, H., Yakabe, S. & Kameoka, K. Laparoscopic percutaneous extraperitoneal closure for inguinal hernia in children: clinical outcome of 972 repairs done in 3 pediatric surgical institutions. *J Pediatr Surg.* **41**, 1999–2003 https://doi.org/10.1016/j.jpedsurg.2006.08.032 (2006).
12. Li, B., Nie, X., Xie, H. & Gong, D. Modified single-port laparoscopic herniorrhaphy for pediatric inguinal hernias: based on 1,107 cases in China. *Surg Endosc.* **26**, 3663–3668 https://doi.org/10.1007/s00464-012-2396-z (2012).
13. Chang, Y. T., Lee, J. Y., Tsai, C. J., Chiu, W. C. & Chiou, C. S. Preliminary experience of one-trocar laparoscopic herniorrhaphy in infants and children. *J Laparoendosc Adv Surg Tech A.* **21**, 277–282

https://doi.org/10.1089/lap.2010.0132 (2011).

14. Ozgediz, D. *et al.* Subcutaneous endoscopically assisted ligation (SEAL) of the internal ring for repair of inguinal hernias in children: report of a new technique and early results. *Surg Endosc.* **21**, 1327–1331 https://doi.org/10.1007/s00464-007-9202-3 (2007).
15. Koivusalo, A. I. A Review of the Incidence, Manifestation, Predisposing Factors, and Management of Recurrent Pediatric Inguinal Hernia. *Eur J Pediatr Surg.* **27**, 478–483 https://doi.org/10.1055/s-0037-1608675 (2017).
16. Xiang, B. *et al.* Reasons for Recurrence After the Laparoscopic Repair of Indirect Inguinal Hernia in Children. *J Laparoendosc Adv Surg Tech A.* **25**, 681–683 https://doi.org/10.1089/lap.2014.0401 (2015).
17. Hayashi, K., Ishimaru, T. & Kawashima, H. Reoperation After Laparoscopic Inguinal Hernia Repair in Children: A Retrospective Review. *J Laparoendosc Adv Surg Tech A.* **29**, 1264–1270 https://doi.org/10.1089/lap.2019.0191 (2019).
18. Yoshizawa, J. *et al.* Laparoscopic percutaneous extraperitoneal closure for inguinal hernia: learning curve for attending surgeons and residents. *Pediatr Surg Int.* **29**, 1281–1285 https://doi.org/10.1007/s00383-013-3337-1 (2013).
19. Zhang, Y. *et al.* Does the laparoscopic treatment of paediatric hydroceles represent a better alternative to the traditional open repair technique? A retrospective study of 1332 surgeries performed at two centres in China. *Hernia.* **22**, 661–669 https://doi.org/10.1007/s10029-017-1715-7 (2018).
20. Esposito, C. *et al.* Current concepts in the management of inguinal hernia and hydrocele in pediatric patients in laparoscopic era. *Semin Pediatr Surg.* **25**, 232–240 https://doi.org/10.1053/j.sempedsurg.2016.05.006 (2016).
21. Gollu, G. *et al.* Transinguinal laparoscopic evaluation of contralateral side during unilateral inguinal hernia repair for children. *J Pediatr Urol* **15**, 561 e561-561 e566, doi:10.1016/j.jpurol.2019.07.006 (2019).
22. Yeap, E., Pacilli, M. & Nataraja, R. M. Inguinal hernias in children. *Aust J Gen Pract.* **49**, 38–43 https://doi.org/10.31128/AJGP-08-19-5037 (2020).
23. Xu, C., Xiang, B., Jin, S. G., Luo, Q. C. & Zhong, L. Transumbilical two-port laparoscopic percutaneous extraperitoneal closure: a new technique for inguinal hernia repair in children. *J Laparoendosc Adv Surg Tech A.* **23**, 392–396 https://doi.org/10.1089/lap.2012.0456 (2013).

Figures

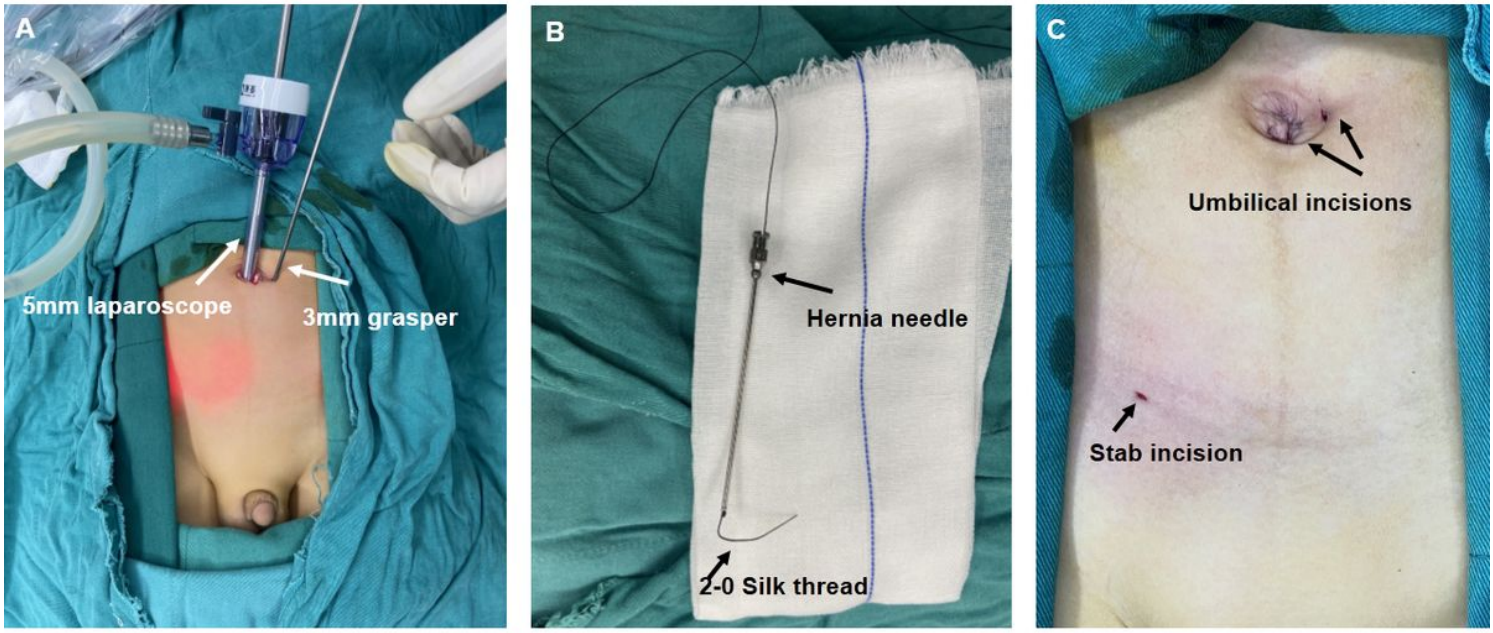

Figure 1

Incisions and instruments (A) position of 5-mm 30 laparoscope and 3-mm grasper; (B) hernia needle with 2-0 silk thread in it; (C) postoperative abdominal appearance; stab incision made on the abdominal transvers striae.

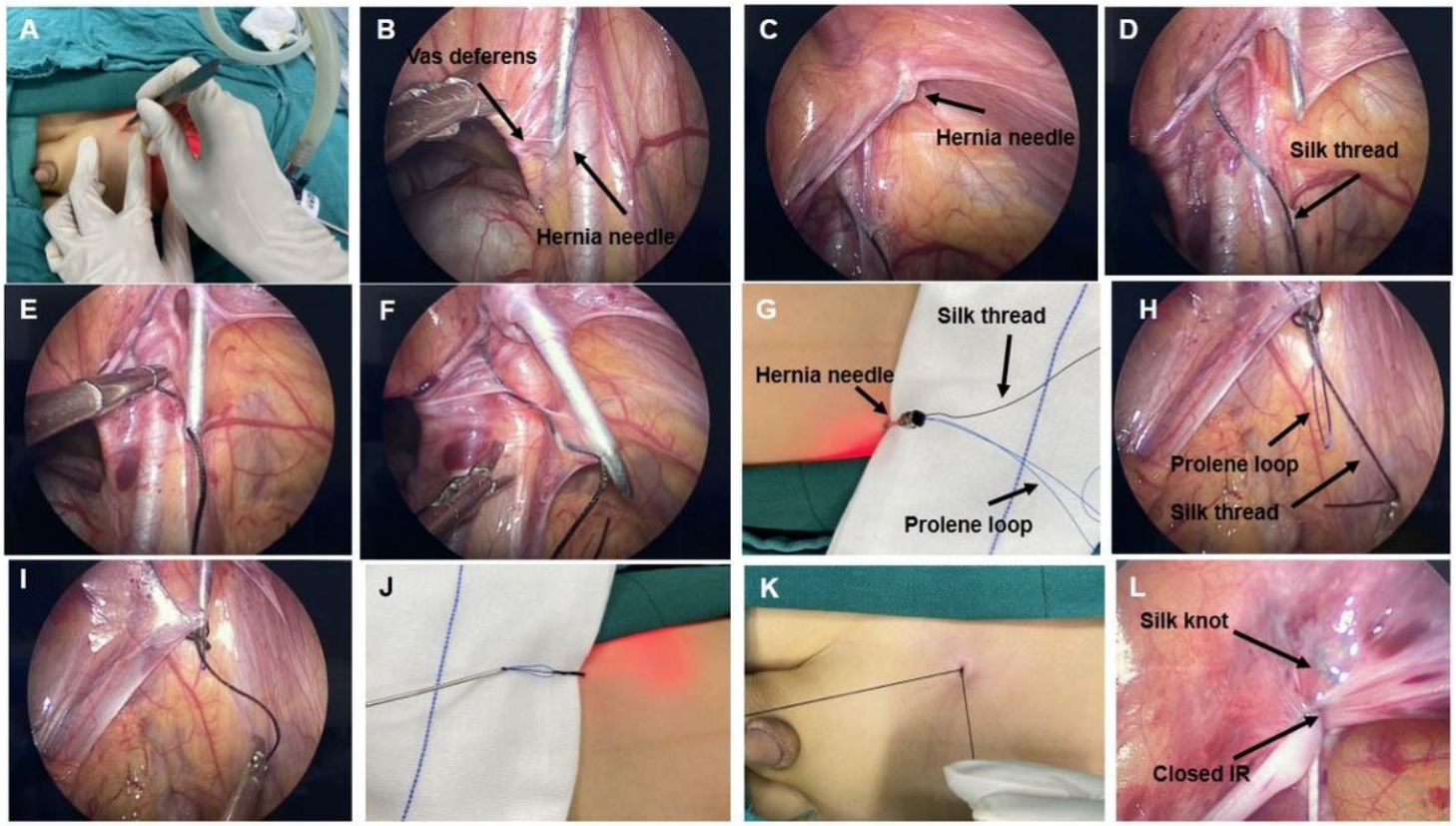

Figure 2

M-SLPEL procedures: (A) stab incision made just above the inguinal ring by the tip of scalpel; (B) hernia needle passing through the medial semicircle of the inguinal ring;(C) hernia needle retracted back to the extraperitoneal cavity with the tail of the silk thread left into the peritoneal cavity;(D) hernia needle continued to pass through the outer half of the inguinal ring close to the peritoneum;(E) hernia needle try to get into the peritoneal cavity through the same breach on the peritoneum; (F) hernia needle get into the peritoneal cavity again through the same breach on the peritoneum (G) the Prolene loop pass through the lumen of the hernia needle into the peritoneal cavity;(H) the silk threads pulled into the Prolene loop using the assisted forceps; (I) the tail of the silk thread hooked out with withdrawing of the hernia needle; (J) the tail of the silk thread brought out from the peritoneal cavity; (K) knotting outside of the abdomen; (L) the ligation knot CLOSE to the peritonium;

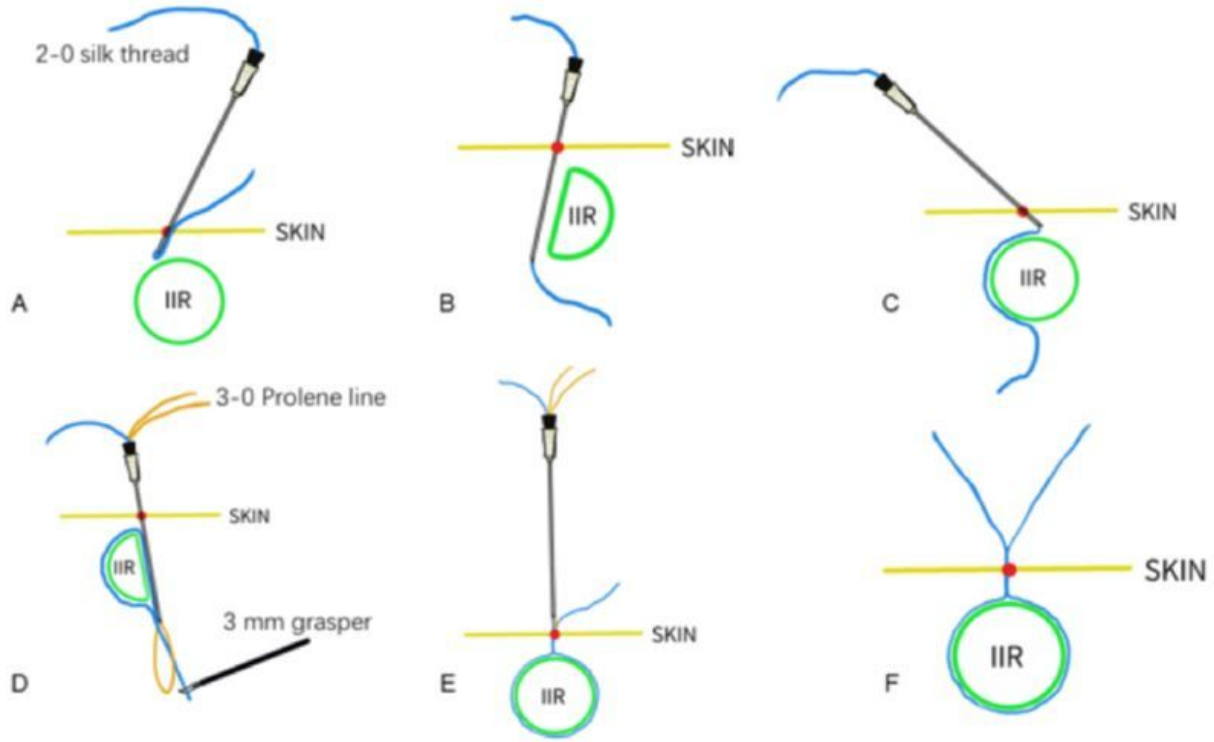

Figure 3

Operative diagram for M-SLPEL