

Perfusion Deficits in Different Mechanisms of Two Subtypes of Acute Stroke with Diffusion MRI confirmation

Cuiting Zhu

Beijing Chao-Yang Hospital

Wei Qin

Beijing Chao-Yang Hospital

Wenli Hu (✉ wenlihu3366@126.com)

Beijing Chao-Yang Hospital

Research Article

Keywords: CT perfusion, MRI, Branch atheromatous disease, Lacunar infarcts, Perfusion deficits, Acute stroke

Posted Date: February 6th, 2023

DOI: <https://doi.org/10.21203/rs.3.rs-2525505/v1>

License:   This work is licensed under a Creative Commons Attribution 4.0 International License.

[Read Full License](#)

Abstract

Background: Branch atheromatous disease (BAD) and lacunar infarcts (LI) are the different mechanisms of subtypes of acute stroke. We aimed to investigate perfusion deficits and clinical characteristics of the different mechanisms of two subtypes of acute stroke.

Methods: Five-hundred and ninety-nine CTP examinations were retrospectively reviewed between January and December 2021 in patients with acute stroke symptoms with CTP within 12 hours and MRI within 7 days of symptom onset. The subtype of ischemic stroke was diagnosed according to DWI imaging. Baseline characteristics between normal and abnormal CTP results in BAD and LI were compared with chi-square or Fisher's exact test for categorical. The t-test or Mann-Whitney U test was performed for continuous variables.

Results: One hundred thirty-three patients met the inclusion criteria (26.3% female). The BAD group was present in 104 of 133 (78.2%), and the LI group 29 of 133 (21.8%). Based on CT perfusion, 42 of 78 (53.8%) the BAD group and 5 of 18 (27.8%) the LI group had perfusion deficits in the supratentorial region. The BAD group had a higher proportion of abnormal perfusion than the LI group, with a significant difference ($P < 0.05$). The sensitivity of CTP ranged from 21.4% (CBV) to 90.5% (TTP); specificity ranged from 97.2% (TTP) to 100% (CBV, CBF, and MTT) in the BAD patients.

Conclusions: Compromised perfusion deficits are more presented in BAD patients compared with LI. CT perfusion imaging may be useful for determining the clinical significance of perfusion abnormalities in BAD occurrence.

Background

The small-vessel disease accounts for up to 25% of all ischemic strokes[1, 2]. The pathologies of small vessel disease were the thickening of the arterial media and obstruction of the origins of penetrating arteries by parent artery intimal plaques[3]. Deep small infarcts are caused by decreased perfusion in the territory of penetrating arteries. The limited collateral circulatory capacity and occlusive changes in the adjoining penetrators can lead to infarcts. In 1989, Louis Caplan[4] first reported that branch atheromatous disease (BAD) is one of the stroke subtypes caused by occlusion at the origin of a deep penetrating artery of the brain and is associated with a micro-atheroma or a junctional plaque. Lacunar infarcts (LI) are small (< 20 mm diameter) subcortical infarcts-normally located in the basal ganglia, thalamus, internal capsule, corona radiata, and the brainstem. Hypo-perfused parenchyma can progress to lacunar stroke and white matter hyperintensity[5]. Anterograde and retrograde collaterals may play a critical role in maintaining cerebral perfusion, while perfusion compromise was closely associated with final infarct size[6]. Nowadays, studies have reported that the pathology of small vessel disease, but blood flow perfusion in BAD and LI was investigated minimally, especially in early diagnosis of acute stroke onset.

CTA and CTP can detect intracranial vascular stenosis or occlusion and perfusion deficits in patients with different types of ischemic stroke. MRI simultaneously visualized the infraction regions allowing us to detect BAD and LI patients. A previous study reported that the emergence of occlusion in the collateral circulation caused by hypoperfusion in the distal branches affects the expansion of the ischemic lesion and the progression of neurological sequelae[7]. BAD and LI patients often presented similar clinical characteristics of lacunar syndromes; therefore, it is difficult to predict BAD only by neurological examination.

In our study, we aimed to assess whether abnormal cerebral perfusion is related to impairments in patients with different mechanisms of two subtypes of acute stroke. The purpose of this study was to investigate CT perfusion abnormalities and clinical characteristics of BAD and LI patients and evaluate the diagnostic capabilities of CTP in the detection of lacunar strokes within different areas of the brain.

Methods

Study design and participants

The design of this study was approved by the Ethics Committee of Beijing Chao Yang Hospital and performed according to the Declaration of Helsinki guidelines. All participants consented to participate in our study and signed an informed consent to the use of data for research. A retrospective review of all patients who presented with acute stroke symptoms between January and December 2021 was performed; all patients completed multimodal CT (non-contrast CT brain (NCCT), CT perfusion (CTP), CT angiogram (CTA)) examinations. Patients were included if they underwent multimodal CT examination within 12 hours of symptom onset, as well as DWI within 7 days of presentation. CTA was performed to exclude large artery atherosclerosis. After DWI confirmed infarctions were small vessel occlusions. The subtype of ischemic stroke was diagnosed by an experienced neurologist according to the report of Caplan[4] and established criteria of TOAST[8]. According to brain infarction diameter on DWI, lacunar infarcts (LI) were defined as intracerebral lesions <20 mm in diameter and fewer than 3 slices or a lesion within the pontine parenchyma. Branch atheromatous disease (BAD) was defined as an intracerebral lesion of ≥ 20 mm in diameter and more than 3 slices or a lesion extending to the surface of the pontine base. Exclusion criteria were: (1) The severity of large intracranial artery stenosis was $\geq 50\%$; (2) non-atherosclerotic vasculopathies, such as dissection, vasculitis, or moyamoya disease; (3) lack of MRI results or incomplete data; (4) the diagnosis was cerebral hemorrhage and subarachnoid hemorrhage; (5) patients were allergic to iodinated contrast or incomplete imaging data could not be reprocessed; (6) known renal dysfunction.

Demographic and clinical characteristics

Demographic features included age, gender, and systolic blood pressure at the time of admission. The previous history of disease included hypertension (defined as receiving medication for hypertension or blood pressure >140/90 mmHg on repeated measurements), hyperlipidemia (defined as receiving cholesterol-reducing agents or low-density lipoprotein cholesterol 2.6 mmol/L at the time of admission),

diabetes mellitus (defined as receiving medication for diabetes mellitus or diagnosed at discharge), current cigarette smoking (last at least 6 months), drinking (last at least 6 months), history of ischemic stroke, and history of coronary heart disease. All patients underwent a blood test after admission (including cholesterol, triglycerides, HDL-C, LDL-C, Lipoprotein (a), creatinine, HbA1c, Hcy, and uric acid).

DWI and CTP Acquisition and Postprocessing

Magnetic resonance imaging (MRI) examinations, including conventional T1-weighted, T2-weighted, fluid-attenuated inversion recovery imaging, and DWI were performed on a 3.0-T MRI scanner (Prisma; Siemens AG, Erlangen, Germany) and a 32-channel array head coil. Multimodal CT examinations, including NCCT, CTP, and CTA were performed on a 64-section multidetector scanner (Revolution Frontier, GE Healthcare, Siemens). Standard NCCT was acquired (5 mm slices) followed by CTP using a SOMATOM Emotion 16 (Siemens GE Healthcare). Forty milliliters of nonionic iodinated contrast were administered intravenously at 5 mL/s by using a power injector. Fifty milliliters of normal saline were injected immediately after the contrast agent injection. CTP imaging parameters were 80 kV(peak), 250 mAs, 0.4r/s, 1.5-second rotation, and 5-mm thickness, and color maps were reformatted at 4-mm thickness. The total imaging time was 50.73 seconds. CTP images were obtained 5 minutes later. Perfusion maps (time to peak (TTP), cerebral blood flow (CBF), cerebral blood volume (CBV), and mean transit time (MTT) were produced using the d fast-processing of ischemic stroke (F-STROKE) software[9]. CTA was performed after 3 min once CTP was completed. The software automatically subtracts and reconstructs 4D-CTA reconstruction.

Image Review and Interpretation

Two experienced neuroradiologists reviewed the DWI, NCCT, CTA, and CTP (CBV, CBF and TTP) images blindly and independently to identify abnormalities diagnostic of acute ischemic stroke. The presence or absence of stroke were then assessed on all imaging sequences; NCCT, CTA, and CTP images were reviewed first, and DWI was reviewed afterward to blind the review of CTA and perfusion data to the DWI results. F-STROKE provided a fully automatic CTP processing and defined relative CBF < 30% as ischemic core volume and relative T-max > 6s of that in normal tissue as penumbra volume[9]. Perfusion deficits was defined as regions with visually perceptible presence abnormality of CTP map, decrease of CBF or CBV, or increased T-max or MTT compared with the contralateral side. FLAIR images were reviewed to ensure that the perfusion deficits did not correspond to a region of old infarction. If the result was controversial, we will find another neuroradiologist to confirm. Interpretations were considered correct if 2 or more reviewers agreed on the results. Inter-observer agreement on quantitative perfusion parameters were assessed in terms of the intraclass correlation coefficient (95% confidence interval), which was 0.84. Stroke locations were divided into the supratentorial region and the infratentorial area. The infratentorial areas were ultimately excluded because the CTP margins did not extend inferiorly enough to encompass strokes in those locations. Using DWI as the criterion standard, findings were defined as true-positive results if two slabs of sufficient quality on CTP abnormality corresponded with the same areas as the infarcts on DWI.

Statistical Analysis

Categorical variables were presented as percentages and continuous variables as mean with standard deviation or median with interquartile range. Baseline characteristics between normal and abnormal CTP results in BAD and LI were compared with chi-square or Fisher's exact test for categorical. The t-test or Mann-Whitney U test was performed for continuous variables. Statistical analyses were performed using SPSS 26.0. Values with $P < 0.05$ were considered statistically significant.

Results

Demographic profile

In the present study, 599 patients with acute stroke symptom within 12 hours of symptoms onset completed multimodal CT and MRI within 7 days of symptom onset from Jan to Dec 2021. We excluded 65 patients diagnosed with cerebral hemorrhage, and 31 patients with subarachnoid hemorrhage. There were 503 patients diagnosed with acute ischemic stroke and including 247 patients with large artery atherosclerosis, 25 patients with cardio-embolism and 98 patients with other types of infarcts (Figure 1). Therefore, a total of 133 patients with small vessel occlusion were included in the present analysis.

Their average age was 63.0 ± 10.6 years (73.7% male). Among them, 104 (78.2%) patients were BAD, and 29 (21.8%) patients were LI. The demographics and baseline clinical characteristics in the BAD group and LI group were shown in Table 1. There was a significant difference in age between BAD and LI patients. The average age of the BAD group was 61.9 ± 10.7 (76.9% male), and the LI group was 66.9 ± 9.4 (62.1% male). Compared to patients with BAD, LI patients were older ($P = 0.024$) and had more proportion of ischemic stroke history ($P = 0.022$). No significant difference was found in gender, other medical history, SBP, and laboratory data in patients with BAD and LI.

Table 1 Demographic and baseline characteristics in patients with BAD and LI

Characteristics	BAD (n=104)	LI (n=29)	P-value
Age, years, mean \pm SD	61.9 \pm 10.7	66.9 \pm 9.4	0.024
Gender, males, n (%)	80.0(76.9)	18.0(62.1)	0.108
HT, n (%)	62.0(59.6)	23.0(79.3)	0.051
DM, n (%)	38.0(36.5)	8.0(27.6)	0.370
CHD, n (%)	12.0(11.5)	5.0(17.2)	0.528
Hyperlipidemia, n (%)	19.0(18.3)	9.0(31.0)	0.136
CI, n (%)	16.0(15.4)	10.0(34.5)	0.022
Smoking, n (%)	58.0(55.8)	16(55.2)	0.954
Drinking, n (%)	41.0(39.4)	11.0(37.9)	0.884
SBP, mmHg	155.5 \pm 21.2	156.7 \pm 20.6	0.790
TC, mmol/L	4.8 \pm 1.0	4.8 \pm 1.3	0.709
TG, mmol/L	1.5(1.1-2.2)	1.7(1.0-3.0)	0.479
HDL-C, mmol/L	1.0(0.9-1.2)	1.0(0.9-1.3)	0.552
LDL-C, mmol/L	3.2(2.7-3.7)	2.8(1.9-4.0)	0.292
Lipoprotein (a), mg/dL	16.1(7.8-41.9)	16.9(7.9-32.3)	0.517
Cr, umol/L	65.0(56.8-78.5)	62.0(53.3-74.4)	0.425
HbA1c, %	6.4(5.8-7.5)	6.0(5.6-7.2)	0.226
Hcy, umol/L	15.0(12.0-18.0)	13.0(10.5-16.0)	0.074
Uric acid, umol/L	333.9 \pm 91.1	328.7 \pm 75.8	0.782

Abbreviations: BAD, branch atheromatous disease; LI, lacunar infarcts; SD, standard deviation; HT, hypertension; DM, diabetes; CHD, coronary heart disease; CI, cerebral infarction; SBP, systolic blood pressure; TC, total cholesterol; TG, triglyceride; Cr, creatinine; Hcy, homocysteine.

Infarction Locations

The average time between admission to the emergency room to CTP imaging was 25 ± 10 minutes for all patients; the average time between CTP and MR imaging was 2.0 ± 1.0 days. According to infarcts locations within the brain identified on DWI, 78 of 104 (75.0%) the BAD group infarctions were located at the supratentorial region, including the lenticulostriate arteries (LSA) area, basal ganglia, and thalamus; 26 of 104 (25.0%) in the paramedian pontine arteries (PPA) area. 18 of 29 (62.1%) the LI group

infarctions were located at the supratentorial region; 11 of 19 (37.9%) were in the brainstem. 27 patients (23(22.1% BAD), 4(13.8%) LI) received intravenous thrombolysis before MR imaging.

Imaging results

Forty two of 78 (53.8%) the BAD group patients had perfusion deficits on CTP concordant with infarctions on DWI. NCCT revealed 29 (37.2%) acute infarcts concordant with infarctions on DWI ($P = 0.003$), including 22 of 42 (52.4%) abnormalities on CTP. Five of 18 (27.8%) the LI group patients had perfusion deficits on CTP concordant with infarction on DWI. NCCT revealed 3 (16.7%) acute infarcts concordant with infarctions on DWI ($P = 0.172$), including 2 of 5 (40.0%) abnormalities on CTP. The BAD group patients (Figure 2) had a higher proportion of perfusion deficits than the LI group patients (Figure 3), with a significant difference ($P < 0.05$) (Table 2). The sensitivity and specificity of NCCT in CTP abnormality namely 51.1% and 83.7% ($P < 0.001$). The sensitivity and specificity of CBF were 61.7% and 100% ($P < 0.001$), CBV 21.3% and 100% ($P = 0.001$), TTP 89.4% and 100% ($P < 0.001$), MTT 87.2% and 98.0% ($P < 0.001$).

Table 2 CTP results of supratentorial regional infarcts in BAD and LI patients

Characteristics	BAD (n=78)		LI (n=18)	
	Normal CTP	Abnormal CTP	Normal CTP	Abnormal CTP
Number (%)	36(46.2)	42(53.8)	13(72.2)	5(27.8) *
Positive CT, n (%)	7(19.4)	22(52.4) ^a	1(7.7)	2(40.0)
Age, years, mean ± SD	58.8±8.8	62.6±11.7	64.0(60.0-70.5)	68.0(64.5-78.5)
Gender, males, n (%)	29(80.6)	31(73.8)	9(69.2)	3(60.0)
HT, n (%)	21(58.3)	22(52.4)	11(84.6)	2(40.0)
DM, n (%)	12(33.3)	17(40.5)	2(15.4)	1(20.0)
CHD, n (%)	2(5.6)	4(9.5)	3(23.1)	0(0)
Hyperlipidemia, n (%)	7(19.4)	6(14.3)	2(15.4)	3(60.0)
CI, n (%)	5(13.9)	6(14.3)	2(15.4)	3(60.0)
Smoking, n (%)	27(75.0)	19(45.2) ^a	9(69.2)	2(40.0)
Drinking, n (%)	17(47.2)	16(38.1)	6(46.2)	2(40.0)
SBP, mmHg	156.5±15.2	155.9±22.4	152.0(142.5-159)	151.0(138.5-174.0)
TC, mmol/L	4.6±1.0	4.8±1.0	4.3(3.4-5.0)	5.3(4.0-6.8)
TG, mmol/L	1.4(1.0-2.2)	1.5(1.2-2.0)	1.4(1.0-3.0)	1.9(0.7-5.1)
HDL-C, mmol/L	1.0(0.8-1.2)	1.0(0.9-1.2)	1.0(0.9-1.3)	1.1(0.8-1.2)
LDL-C, mmol/L	3.0(2.4-3.7)	3.1(2.7-3.7)	2.4(1.9-3.4)	1.9(0.7-5.1)
Lipoprotein (a), mg/dL	22.6(8.1-55.3)	13.5(7.8-47.6)	10.9(6.5-27.1)	33.8(9.0-50.0)
Cr, umol/L	64.3(58.5-77.0)	64.7(54.5-84.8)	66.3(58.9-74.4)	54.8(51.7-67.5)
HbA1c, %	6.5(6.0-7.3)	6.0(5.7-8.3)	6.0(5.8-7.0)	5.9(5.5-6.1)
Hcy, umol/L	15.5(11.3-19.8)	15.0(11.0-18.3)	11.0(9.5-17.5)	13.0(10.5-25.0)
Uric acid, umol/L	339.9±101.0	326.1±95.5	326.0(253.0-371.0)	291.0(264.5-347.5)

* $P < 0.05$ compared with abnormal CTP BAD.

^a $P < 0.05$ compared with normal CTP BAD.

Abbreviations: BAD, branch atheromatous disease; LI, lacunar infarcts; CTP, CT perfusion; SD, standard deviation; HT, hypertension; DM, diabetes; CHD, coronary heart disease; CI, cerebral infarction; SBP, systolic blood pressure; TC, total cholesterol; TG, triglyceride; Cr, creatinine; Hcy, homocysteine.

Discussion

In our study, we retrospectively investigated a group of 133 patients with acute stroke who were brought to the emergency department within 12 hours after the onset of stroke symptoms and found that compromised cerebral perfusion was associated with impairments in the small vessel occlusion and could be detected by CTP after the onset of symptoms. In addition, our results also showed that the underlying etiology of small vessel occlusion may influence the perfusion alterations. Perfusion deficits were more prevalent in BAD patients than LI patients.

Firstly, our study found that LI patients were older than BAD, and LI had more ischemic stroke history compared with BAD patients. The risk of atherosclerosis and cerebral vascular disease increased with age. Previous studies showed that LI patients had a higher prevalence of history of hypertension, more severe leukoariosis, and smaller size in FLAIR image compared to patients with BAD[10]. We further analyzed the cerebral blood flow characteristics. It was reported that perfusion deficits in patients with strokes of large vessels atherosclerosis, but few studies used CTP and MRI to detect changes of cerebral perfusion in patients with small vessel occlusion. Previous studies showed that 52.2% to 76% of patients with single subcortical infarct had cerebral perfusion deficits within 24h of symptom onset[6, 11, 12]. Poppe AY used magnetic resonance perfusion-weighted imaging and found perfusion abnormalities in two-thirds of lacunar infarcts[12]. Using 4D dynamic perfusion MRI, they found patients with hypoperfusion patterns had the highest rate of early neurological deterioration[6]. In our study, we found 49% of patients with small vessel occlusion had cerebral perfusion deficits in supratentorial regions.

Further, our study revealed that the sensitivity and specificity of CTP were significantly more sensitive and accurate than NCCT alone. BAD patients had a higher proportion of abnormal perfusion than LI patients. Our results reported that 53.8% BAD and 27.8% LI patients had perfusion abnormality in supratentorial regions. Small hyperacute infarcts were poorly discernible on both NCCT and CTP, especially infarctions in the brainstem. Different etiology of infarctions had diverse causes. BAD radiological diagnosis was based on vascular territory, dimensions and/or shape of the acute ischemic lesion, and CTP imaging techniques can show abnormal perfusion evidence of parent artery disease in an acute time window[13]. The sensitivity of CTP varied considerably due to the heterogeneity in patient characteristics, CTP spatial and temporal resolution and postprocessing methods[14]. It was reported that atherothrombotic had more sensitivity[15] and TTP or T-max is highly sensitive to large vessel occlusion and collateral blood flow[16]. Previous studies about detecting acute lacunar infarcts with CTP found that sensitivity was 48.7-56% and specificity of 98.7-100%[17-19]. CTP improves detection but requires careful evaluation of the perforator locations for small perfusion deficits in the absence of a larger perfusion abnormality.

It was reported that CBF and CBV abnormalities were more frequent among patients with BAD than LI patients[20]. Our study found more perfusion deficits in BAD patients than in LI. A previous study showed perfusion abnormality in LI was associated with atherothrombotic occlusion of several perforator branches[21]. Local branch occlusion is caused by the obliteration of the orifices of perforating arteries, and a longer atheroma may increase the chance of obliterating the perforating arteries[22]. BAD involving persistent perfusion deficits has been attributed to atherothrombotic blockage of penetrating arteries with less autoregulation, or to insufficient collateral blood flow from adjacent vascular territories, which is often concomitant with larger lesion size[3]. It is reported that endothelial dysfunction or blood-brain barrier leakage may play part in the pathogenesis of LI patients[23-25]. Mikito Yamada[26] reported that a higher MTT ratio (>1.26) and a lower CBF ratio (<0.76) on perfusion CT scans can predict progressive lacunar infarction in the LSA territory. Our study found that TTP and MTT had highly sensitivity in perfusion deficits with BAD patients. MR imaging could provide superior infarct core delineation in acute ischemic stroke. However, acute MR imaging access is not the optimal first choice of green channel for acute ischemic stroke patients. Although, MR imaging had the advantage of not conferring any radiation dose, it's time consuming and difficult to move. In emergency, most acute ischemic stroke patients received NCCT scan to exclude hemorrhagic cerebrovascular diseases. The use of CTA and CTP could improve initial detection over NCCT and demonstrate perfusion deficits in small vessel diseases in very early diagnosis. CTA and CTP had great potential and advantages in identifying ischemic penumbra in acute ischemic stroke.

This study has several limitations. First, the sample size was small, and the study was based on retrospective analysis using medical charts. A larger number of population samples, including cohorts of different ethnic, geographic, and age groups, need to be conducted in the future. Second, in our study, perfusion deficits were found in supratentorial regions. We separately analyzed the cerebellum and brain stem CTP images, but the results were ultimately excluded because the CTP margins did not extend inferiorly enough to encompass strokes in those locations. Lastly, the study may potentially miss patients due to the known negative DWI infarcts leading to both false-positive and -negative studies. And it lacked research data about NIHSS scores and outcome measures. These data may provide more important insights for clinical work in the future.

Conclusion

In conclusion, CTP has high sensitivity and specificity in identifying BAD. Compromised perfusion deficits are more presented in BAD patients compared with LI. CT perfusion abnormality might provide a more accurate diagnosis of BAD very early in the disease course. However, further studies are required to evaluate the sensitivity and specialty of CT perfusion in BAD and other types of ischemic stroke.

Abbreviations

BAD: Branch atheromatous disease; LI: lacunar infarcts; SD, standard deviation; HT, hypertension; DM, diabetes; CHD, coronary heart disease; CI, cerebral infarction; SBP, systolic blood pressure; TC, total

cholesterol; TG, triglyceride; Cr, creatinine; Hcy, homocysteine; CTP, CT perfusion; NCCT: non-contrast CT brain; CTA: CT angiogram; TTP: time to peak; CBF: cerebral blood flow; CBV: cerebral blood volume; MTT: mean transit time.

Declarations

Acknowledgements

Declared none

Authors' contributions

C.Z. conceived the study and design, conducted the experiment, and wrote the manuscript. W.Q. provided the data analysis and revised this manuscript. W.H. conceived the study and design and edited the manuscript. The authors read and approved the final manuscript.

Funding

None.

Availability of data and materials

The datasets generated for this study are available on request to the corresponding author.

Ethics approval and consent to participate

The design of this study was approved by the Ethics Committee of Beijing Chao Yang Hospital and performed according to the Declaration of Helsinki guidelines. All participants consented to participate in our study and signed an informed consent to the use of data for research.

Consent for publication

Not applicable.

Competing interests

The authors declare no conflict of interest.

Author details

¹Department of Neurology, Beijing Chao-Yang Hospital, Capital Medical University, Beijing, China

Institution address: Department of Neurology, Beijing Chao-Yang Hospital, Capital Medical University, No. 8, South Gongti Road, Chaoyang District, Beijing, P.R. China, 100020.

References

1. Kolominsky-Rabas PL, Weber M, Gefeller O, Neundoerfer B, Heuschmann PU. Epidemiology of ischemic stroke subtypes according to TOAST criteria: incidence, recurrence, and long-term survival in ischemic stroke subtypes: a population-based study. *Stroke*. 2001;32 12:2735-40; doi: 10.1161/hs1201.100209.
2. Norrving B. Long-term prognosis after lacunar infarction. *Lancet Neurol*. 2003;2 4:238-45; doi: 10.1016/s1474-4422(03)00352-1.
3. Caplan LR. Lacunar infarction and small vessel disease: pathology and pathophysiology. *J Stroke*. 2015;17 1:2-6; doi: 10.5853/jos.2015.17.1.2.
4. Caplan LR. Intracranial branch atheromatous disease: a neglected, understudied, and underused concept. *Neurology*. 1989;39 9:1246-50; doi: 10.1212/wnl.39.9.1246.
5. Regenhardt RW, Das AS, Lo EH, Caplan LR. Advances in Understanding the Pathophysiology of Lacunar Stroke: A Review. *JAMA Neurol*. 2018;75 10:1273-81; doi: 10.1001/jamaneurol.2018.1073.
6. Huang YC, Lee JD, Pan YT, Weng HH, Yang JT, Lin LC, et al. Perfusion Defects and Collateral Flow Patterns in Acute Small Subcortical Infarction: a 4D Dynamic MRI Study. *Transl Stroke Res*. 2022;13 3:399-409; doi: 10.1007/s12975-021-00953-x.
7. Chen Y, Liu Y, Luo C, Lu W, Su B. Analysis of multiple factors involved in acute progressive cerebral infarction and extra- and intracranial arterial lesions. *Exp Ther Med*. 2014;7 6:1495-505; doi: 10.3892/etm.2014.1624.
8. Adams HP, Jr., Bendixen BH, Kappelle LJ, Biller J, Love BB, Gordon DL, et al. Classification of subtype of acute ischemic stroke. Definitions for use in a multicenter clinical trial. TOAST. Trial of Org 10172 in Acute Stroke Treatment. *Stroke*. 1993;24 1:35-41; doi: 10.1161/01.str.24.1.35.
9. Shi Z, Li J, Zhao M, Zhang M, Wang T, Chen L, et al. Baseline Cerebral Ischemic Core Quantified by Different Automatic Software and Its Predictive Value for Clinical Outcome. *Front Neurosci*. 2021;15:608799; doi: 10.3389/fnins.2021.608799.
10. Yang L, Qin W, Zhang X, Li Y, Gu H, Hu W. Infarct Size May Distinguish the Pathogenesis of Lacunar Infarction of the Middle Cerebral Artery Territory. *Med Sci Monit*. 2016;22:211-8; doi: 10.12659/msm.896898.
11. Förster A, Mürle B, Böhme J, Al-Zghloul M, Kerl HU, Wenz H, et al. Perfusion-weighted imaging and dynamic 4D angiograms for the estimation of collateral blood flow in lacunar infarction. *J Cereb Blood Flow Metab*. 2016;36 10:1744-54; doi: 10.1177/0271678x15606458.
12. Poppe AY, Coutts SB, Kosior J, Hill MD, O'Reilly CM, Demchuk AM. Normal magnetic resonance perfusion-weighted imaging in lacunar infarcts predicts a low risk of early deterioration. *Cerebrovasc Dis*. 2009;28 2:151-6; doi: 10.1159/000225908.
13. Petrone L, Nannoni S, Del Bene A, Palumbo V, Inzitari D. Branch Atheromatous Disease: A Clinically Meaningful, Yet Unproven Concept. *Cerebrovasc Dis*. 2016;41 1-2:87-95; doi: 10.1159/000442577.

14. Biesbroek JM, Niesten JM, Dankbaar JW, Biessels GJ, Velthuis BK, Reitsma JB, et al. Diagnostic accuracy of CT perfusion imaging for detecting acute ischemic stroke: a systematic review and meta-analysis. *Cerebrovasc Dis.* 2013;35 6:493-501; doi: 10.1159/000350200.
15. Hana T, Iwama J, Yokosako S, Yoshimura C, Arai N, Kuroi Y, et al. Sensitivity of CT perfusion for the diagnosis of cerebral infarction. *J Med Invest.* 2014;61 1-2:41-5; doi: 10.2152/jmi.61.41.
16. McVerry F, Dani KA, MacDougall NJJ, MacLeod MJ, Wardlaw J, Muir KW. Derivation and evaluation of thresholds for core and tissue at risk of infarction using CT perfusion. *J Neuroimaging.* 2014;24 6:562-8; doi: 10.1111/jon.12134.
17. Cao W, Yassi N, Sharma G, Yan B, Desmond PM, Davis SM, et al. Diagnosing acute lacunar infarction using CT perfusion. *J Clin Neurosci.* 2016;29:70-2; doi: 10.1016/j.jocn.2016.01.001.
18. Benson JC, Payabvash S, Mortazavi S, Zhang L, Salazar P, Hoffman B, et al. CT Perfusion in Acute Lacunar Stroke: Detection Capabilities Based on Infarct Location. *AJNR Am J Neuroradiol.* 2016;37 12:2239-44; doi: 10.3174/ajnr.A4904.
19. Lin K, Do KG, Ong P, Shapiro M, Babb JS, Siller KA, et al. Perfusion CT improves diagnostic accuracy for hyperacute ischemic stroke in the 3-hour window: study of 100 patients with diffusion MRI confirmation. *Cerebrovasc Dis.* 2009;28 1:72-9; doi: 10.1159/000219300.
20. Jiang S, Cui JY, Yan YY, Yang T, Tao WD, Wu B. Association of compromised cerebral perfusion with lenticulostriate artery impairments in the subacute phase of branch atheromatous disease. *Ther Adv Neurol Disord.* 2022;15:17562864221109746; doi: 10.1177/17562864221109746.
21. Das T, Settecase F, Boulos M, Huynh T, d'Esterre CD, Symons SP, et al. Multimodal CT provides improved performance for lacunar infarct detection. *AJNR Am J Neuroradiol.* 2015;36 6:1069-75; doi: 10.3174/ajnr.A4255.
22. Ha SH, Chang JY, Lee SH, Lee KM, Heo SH, Chang DI, et al. Mechanism of Stroke According to the Severity and Location of Atherosclerotic Middle Cerebral Artery Disease. *J Stroke Cerebrovasc Dis.* 2021;30 2:105503; doi: 10.1016/j.jstrokecerebrovasdis.2020.105503.
23. Wardlaw JM, Dennis MS, Warlow CP, Sandercock PA. Imaging appearance of the symptomatic perforating artery in patients with lacunar infarction: occlusion or other vascular pathology? *Ann Neurol.* 2001;50 2:208-15; doi: 10.1002/ana.1082.
24. Jiang S, Wu S, Zhang S, Wu B. Advances in Understanding the Pathogenesis of Lacunar Stroke: From Pathology and Pathophysiology to Neuroimaging. *Cerebrovasc Dis.* 2021;50 5:588-96; doi: 10.1159/000516052.
25. Wardlaw JM, Smith C, Dichgans M. Small vessel disease: mechanisms and clinical implications. *Lancet Neurol.* 2019;18 7:684-96; doi: 10.1016/s1474-4422(19)30079-1.
26. Yamada M, Yoshimura S, Kaku Y, Iwama T, Watarai H, Andoh T, et al. Prediction of neurologic deterioration in patients with lacunar infarction in the territory of the lenticulostriate artery using perfusion CT. *AJNR Am J Neuroradiol.* 2004;25 3:402-8.

Figures

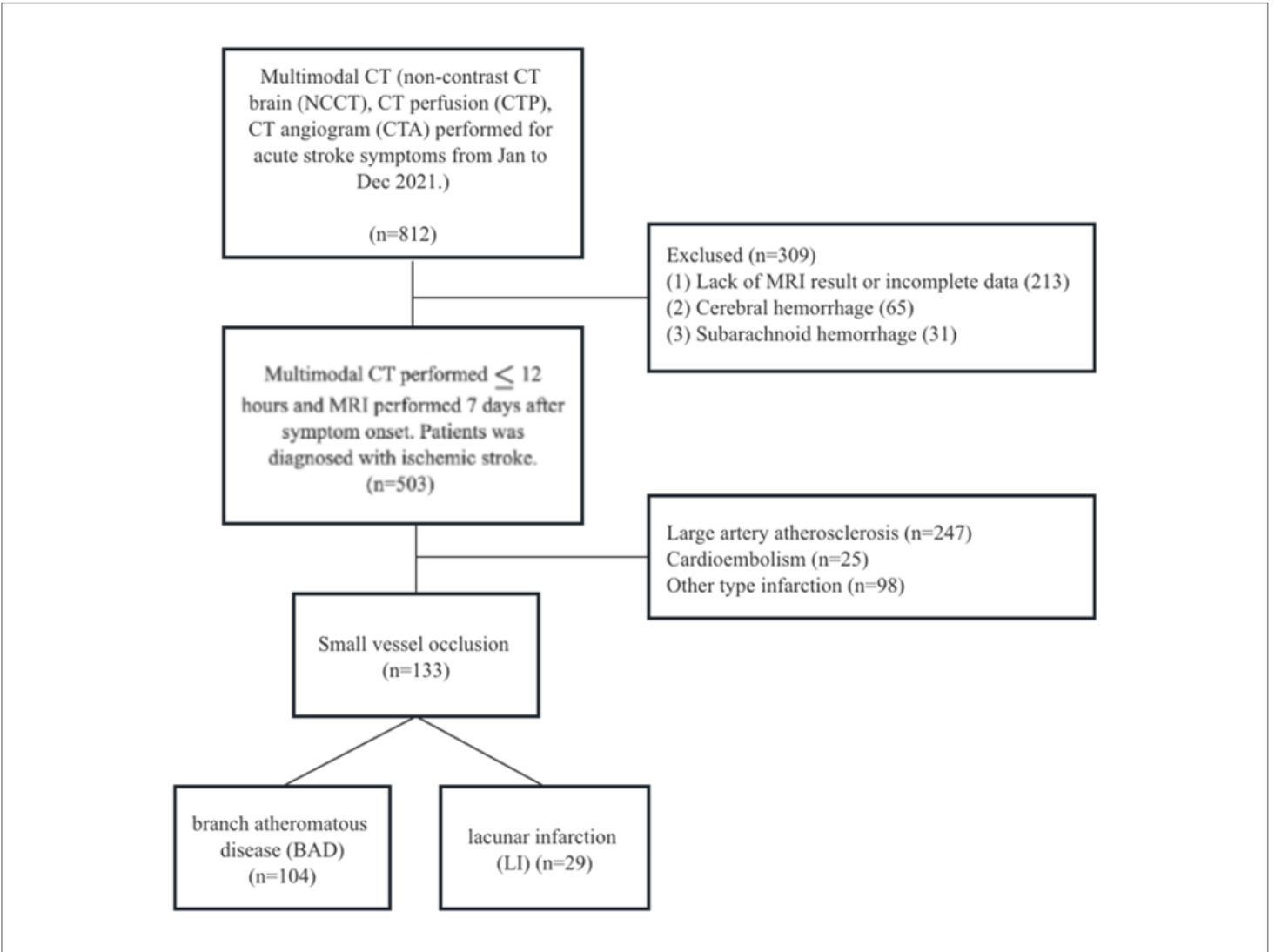


Figure 1

The selection criteria and the number of patients in each category.

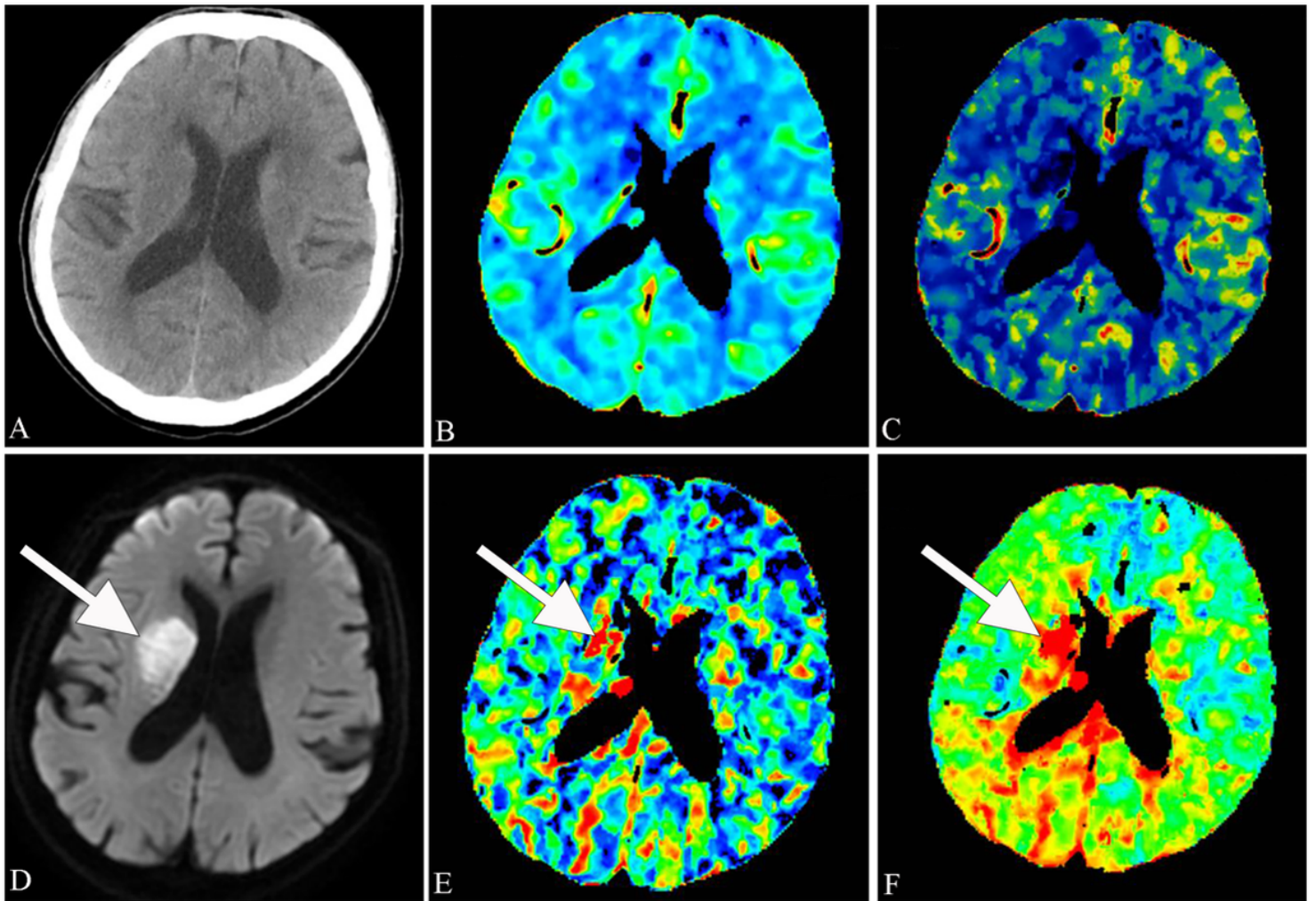


Figure 2

A 61-year-old man who presented with left hemiparesis. Infarct within the right basal ganglia on DWI (D, white arrow) corresponded with focal abnormalities on CBV (B), CBF (C), MTT (E, white arrow) and TTP (F, white arrow) images. No abnormalities were identified on NCCT (A).

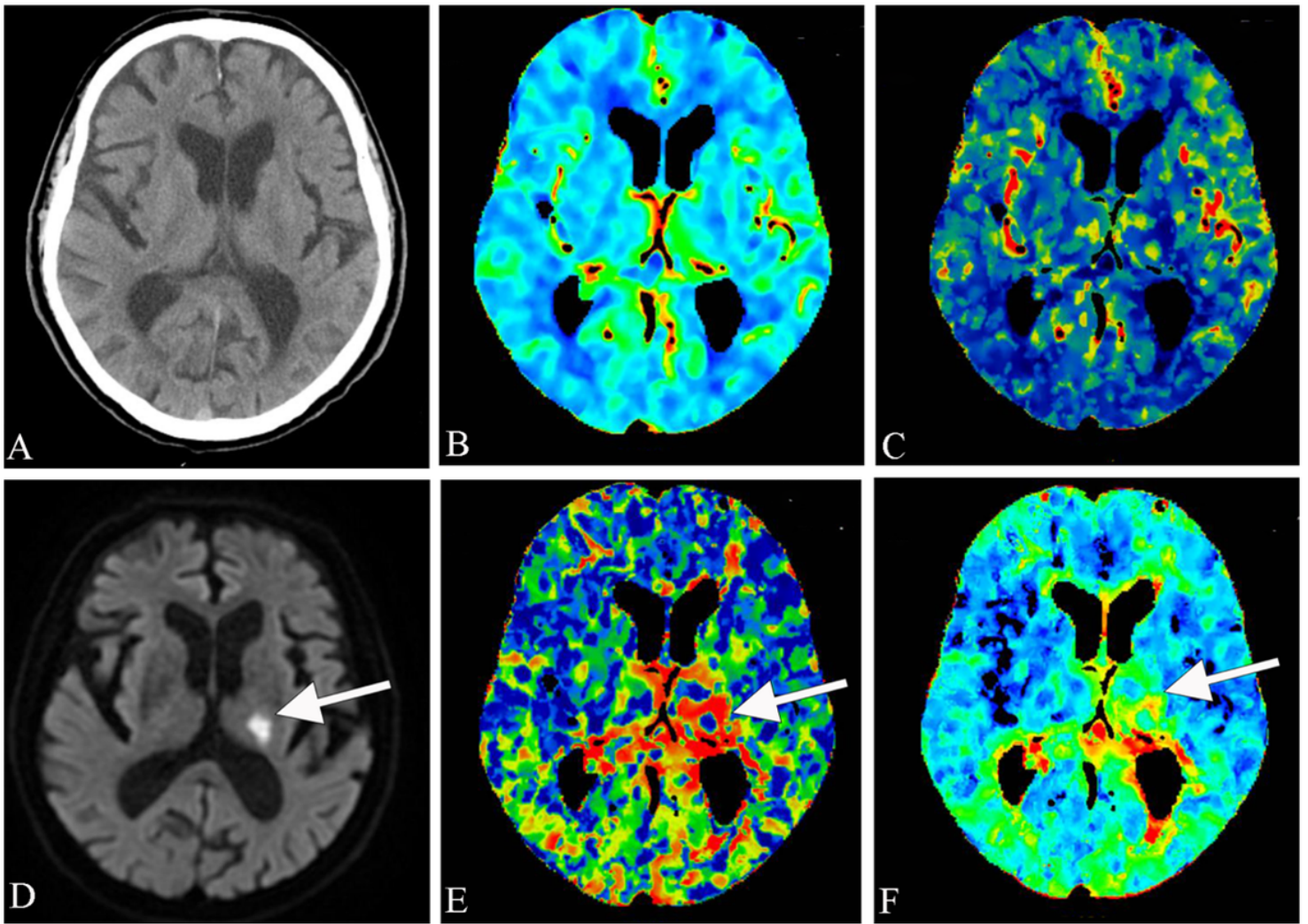


Figure 3

Example of a lacunar infarct visualized on CTP images. A 74-year-old man who presented with numbness in his right limb. DWI confirmed a lacunar infarct in the left thalamus (D, white arrow) corresponded with focal abnormalities on CBF (C), MTT (E, white arrow) and TTP (F, white arrow) images. No abnormalities were noted on NCCT (A) or CBV (B).