Endoscopic repair of ventral hernia and rectus diastasis

Doru Florian Moga (mogadoru@yahoo.com)
Military Hospital Sibiu Romania https://orcid.org/0000-0002-6258-633X

Florin Buia
Military Hospital Cluj-Napoca

Valentin Oprea
Military Hospital Cluj-Napoca

Technical advance

Keywords: umbilical hernia, diastasis recti, extended-view totally extraperitoneal, eTEP

Posted Date: July 21st, 2019

DOI: https://doi.org/10.21203/rs.2.11743/v1

Abstract

Abstract Background Umbilical and epigastric hernias are sometimes associated with rectus muscle divarication. Isolated repair of the hernia defect can have a high recurrence rate and bad cosmetic results .With this condition the repair of both pathologies is mandatory. The goal of the study is to detail some technical aspects of the endoscopic retro-rectus mesh repair. Methods We present a small series of 15 patients operated for primary or incisional ventral hernias associated with rectus diastasis. The width of the defect was under 6 cm. The performed procedure was eRives repair. Results There were no perioperative complications or short term recurrences. Conclusions In our opinion eTEP access Rives Stoppa repair is the best choice for ventral hernias associating rectus diastasis. The technique has to be promoted for its cosmetic results, reproducibility and for acquiring the principles of modern hernia surgery. Key words: umbilical hernia, diastasis recti, extended-view totally extraperitoneal, eTEP

Background

The adult umbilical and epigastric hernia are common primary or acquired mostly as a result of surgery. There is no standard method for hernia repair and different approaches, suture techniques, and mesh-augmented repairs compete for best-evidence surgery [1]. Diastasis recti means a reduction in the consistency of the inter-crossed fibers that compose the linea alba of the abdominal wall, with the consequent increase in the length of these fibers, which brings as a separation of both aponeurosis of the rectus abdominis muscles [2]. There is a group of patients in which umbilical or epigastric hernias co-exist with rectus divarication hernia repair [3].

These patients have weak abdominal musculature and are likely to pose a higher risk of recurrence. For these patients mesh-based repair of the midline is considered [1]. The technical variants described in the literature are diverse: open, minimally invasive and hybrid [4].

We would like to present endoscopic technique for midline hernias with umbilical and epigastric location (primary and incisional) in patients with co-existing rectus divarication. We consider this entity to be a good indication for the enhanced-view totally extraperitoneal (eTEP) approach repair, a technique recently published by Igor Belyansky et al for the repair of ventral and incisional hernias [5]. For these patients, in our experience, it was not necessary to practice the posterior component separation (eTAR), since the transverse parietal defect usually does not exceed 5-6 cm. Under these conditions we prefer instead of the eTEP approach, which is a generic term, to use the term eRives to name the used procedure.

We would like to present endoscopic technique for midline hernias with umbilical and epigastric location (primary and incisional) in patients with co-existing rectus divarication. We consider this entity to be a good indication for the enhanced-view totally extraperitoneal (eTEP) approach repair, a technique recently published by Igor Belyansky et al for the repair of ventral and incisional hernias [5]. For these patients, in our experience, it was not necessary to practice the posterior component separation (eTAR), since the

transverse parietal defect usually does not exceed 5-6 cm. Under these conditions we prefer instead of the eTEP approach, which is a generic term, to use the term eRives to name the used procedure.

Methods

Between 02.03.2017 – 10.28.2018 in both Departments of surgery, 15 procedures were performed.

The patient's position on the operating table is in dorsal decubitus with the legs distant and lowered below the body, with the left hand near the body.

The surgeon and cameraman are initially positioned on the left side of the patient.

The retromuscular space is approached by an open technique or using an optic port inside the lateral edge of the left rectus abdominis muscle at a point located on the umbilical line. A 10 or 5 mm camera port is retromuscular inserted and the CO_2 is insufflated with a pressure of 12 – 14 mmHg.

The retromuscular space is bluntly dissected using the scope. Two 5 mm ports are introduced under direct vision on the same line with the optic port superior and inferior to it. The left retro rectus space is dissected. When the dissection is complete the midline is crossed in the plane of the falciform ligament and outside the defect. This step is facilitated by the wide linea alba, and are must be taken not to penetrate it and enter the subcutaneous space (Fig. 1).

Figure 1

The right side rectus muscle with its investing sheath is identified and the posterior leaf of the sheath is incised longitudinally on its endoabdominal surface at 0.5 cm from the medial aspect.

The right side retro rectus space is dissected in the same manner as on the left side and after that we proceed to dissect the hernia defect (Fig. 2).

Figure 2

Usually during the hernia sac dissection, the peritoneal cavity is opened without any notable consequences on the procedure conduct. For the small defects when the protrusion is only preperitoneal fat, the peritoneum could be maintained closed. The dissection is completed superiorly under the xyphoid process and inferiorly for minimum 5 cm below the defect.

Two more additional trocars are inserted now: a 10 mm port on the midline in the inferior point of dissection and a 5 mm one in the right iliac fossa. All peritoneal leaks are closed using a barbed absorbable suture (V-Loc 2/0) (Fig. 3).

Figure 3

Next operative step is to close the anterior sheath with narrowing of the linea alba using a running suture with non-absorbable barbed suture (V-Loc 0). The surgeon is positioned between patient legs. The insufflation pressure is dropped to 9 mmHg. With the needle holder in the subombilical port, the linea alba and the defect are closed from both extremities. (Fig. 4, 5).

Figures 4 and 5

The left hand of the operative surgeon giving gentle pressure on the abdominal wall also helps in applying the sutures.

A large peritoneal hernia sac can be excised using a small skin incision on top of it (hybrid technique).

The newly created retro-muscular space is measured and the mesh is cut to fit the size. Mesh is inserted through the median 10 mm port and arranged in order to maintain flat. Usually the mesh is fixed with a non-absorbable 2/0 suture to the posterior sheath in its upper extremity (Fig. 6).

Figure 6

No systematic drainage. Exsuflation under direct vision. The final aspect is presented in Fig.7.

Figure 7

Results

The operating time was between 2 hours 45 minutes and 5 hours, with the mention that the suture of the anterior sheath was between 1 and 2 hours.

Our preference is medium weight macroporous polypropylene mesh, with dimensions varying between 20x12 cm and 35x20 cm.

Patients were discharged after 2.53 days (between 1 and 5 days).

There were no postoperative complications or recurrences in the short term follow up.

Discussion

The suture of the anterior rectus sheath on the roof of the rectus space it is the difficult and the least ergonomic step of the procedure such that the position or the number of the using ports the same as the positioning of the operative team can be subjected to modifications.

We also consider that the procedure should be the choice for the eTEP approach of ventral hernias. After the learning curve more complex cases can be approached.

When the abdominal wall defect is larger than 5 or 6 cm in width the cosmetic result is not so good because after suturing the midline an unpleasant elevation results under the skin.

The procedure combines the advantages of the minimally invasive approach with the retrorectus mesh placement avoiding the contact of the mesh with the abdominal viscera or subcutaneous space and offering a wide space with a larger mesh surface.

The costs of the procedure is not too high because we use the standard reusable laparoscopic instruments and a common monofilament macroporous sheet of polypropylene.

Conclusion

In our opinion eTEP access Rives Stoppa repair is the best choice for ventral hernias associating rectus diastasis. The technique has to be promoted for its cosmetic results, reproducibility and for acquiring the principles of modern hernia surgery.

Abbreviations

eTEP: enhanced-view totally extraperitoneal; eRives: endoscopic Rives procedure;

eTAR – endoscopic transversus abdominis release.

Declarations

Ethics approval and consent to participate

Written informed consent was obtained from all patients. The study was approved by the institutional ethics commitee of Military Hospital Sibiu and Military Hospital Cluj-Napoca.

Consent for publication

Not applicable.

Availability of data and materials

The datasets analysed during the current study are available from the corresponding author on reasonable request.

Competing interests

DM, FB, VO have nothing to disclose.

Funding

No funding was obtained for this study.

Authors' contributions

All the authors participated in surgical treatment for the patients in this study. DM analyzed and interpreted the patient data and was a major contributor in writing the manuscript. FB and VO reviewed and edited the manuscript. All authors read and approved the final manuscript.

Acknowledgements

Not applicable.

References

1. Kohler G, Luketina RR, Emmanuel K. Sutured Repair of Primary Small Umbilical and Epigastric Hernias: Concomitant Rectus Diastasis Is a Significant Risk Factor for Recurrence. World J Surg. 2015;39:121–126. doi: 10.1007/ s00268-014-2765-y
2. Bellido Luque J, Bellido Luque A, Valdivia J et all. Totally endoscopic surgery on diastasis recti associated with midline hernias. The advantages of a minimally invasive approach. Prospective cohort study. Hernia. 2015;19:493–501. doi: 10.1007/s10029-014-1300-2
3. Privett BJ, Ghusn M. Proposed technique for open repair of a small umbilical hernia and rectus divarication with self-gripping mesh. Hernia. 2016;20:527–530. doi:10.1007/s10029-016-1470-1
4. Mommers EHH, Ponten JEH, Al Omar AK et all. The general surgeon's perspective of rectus diastasis. A systematic review of treatment options. Surg Endosc. 2017;31:4934–4949. doi: 10.1007/s00464-017-5607-9
5. Belyansky I, Daes J, Radu VG et all. A novel approach using the enhanced-view totally extraperitoneal (eTEP) technique for laparoscopic retromuscular hernia repair. Surg Endosc. 2018;32:1525–1532. doi: 10.1007/s00464-017-5840-2

Figures

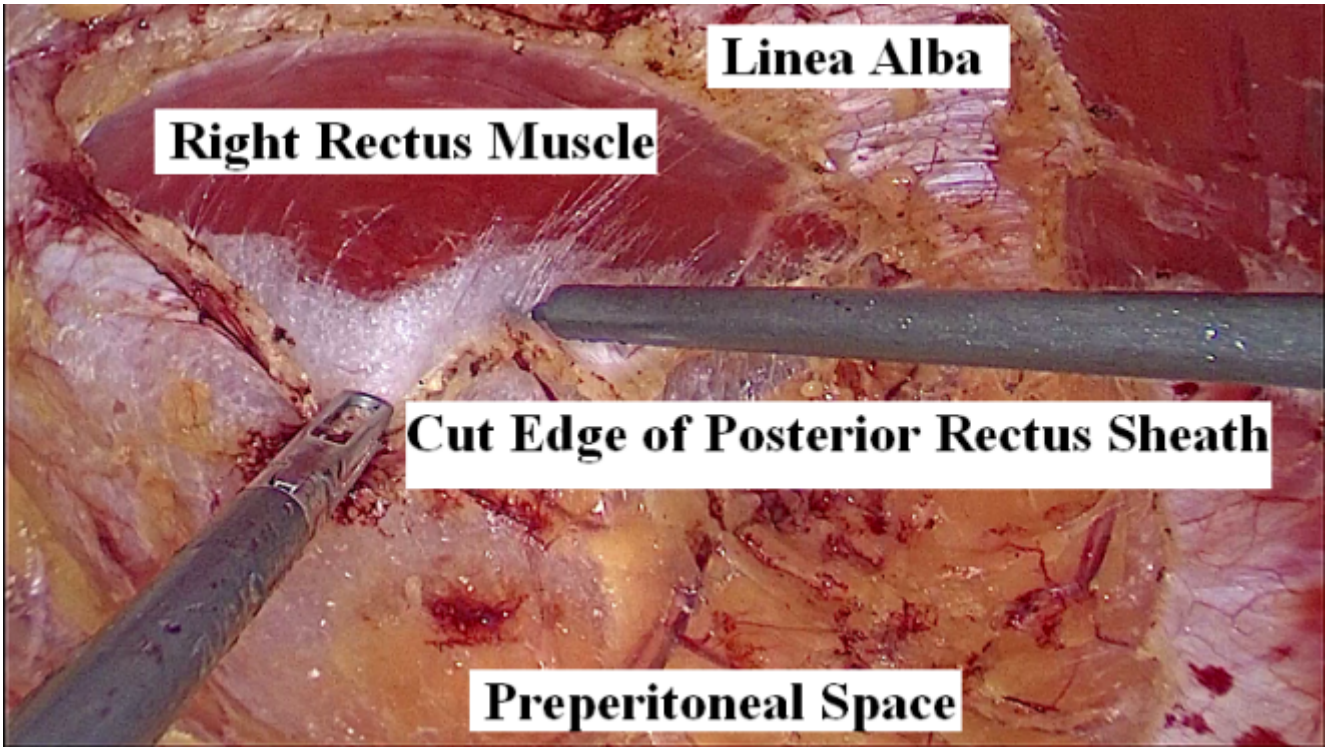

Figure 1

Dissection of the retro-rectus space

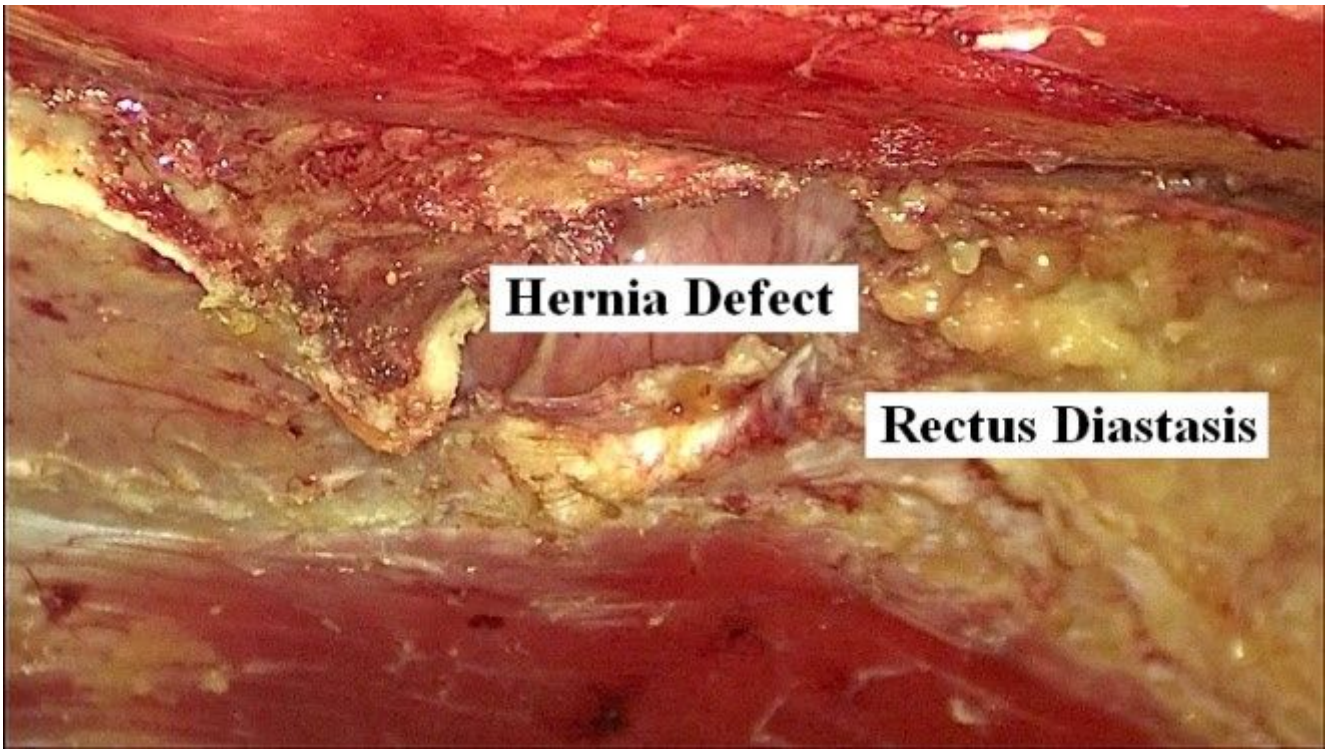

Figure 2

Aspect of hernia defect and diastasis

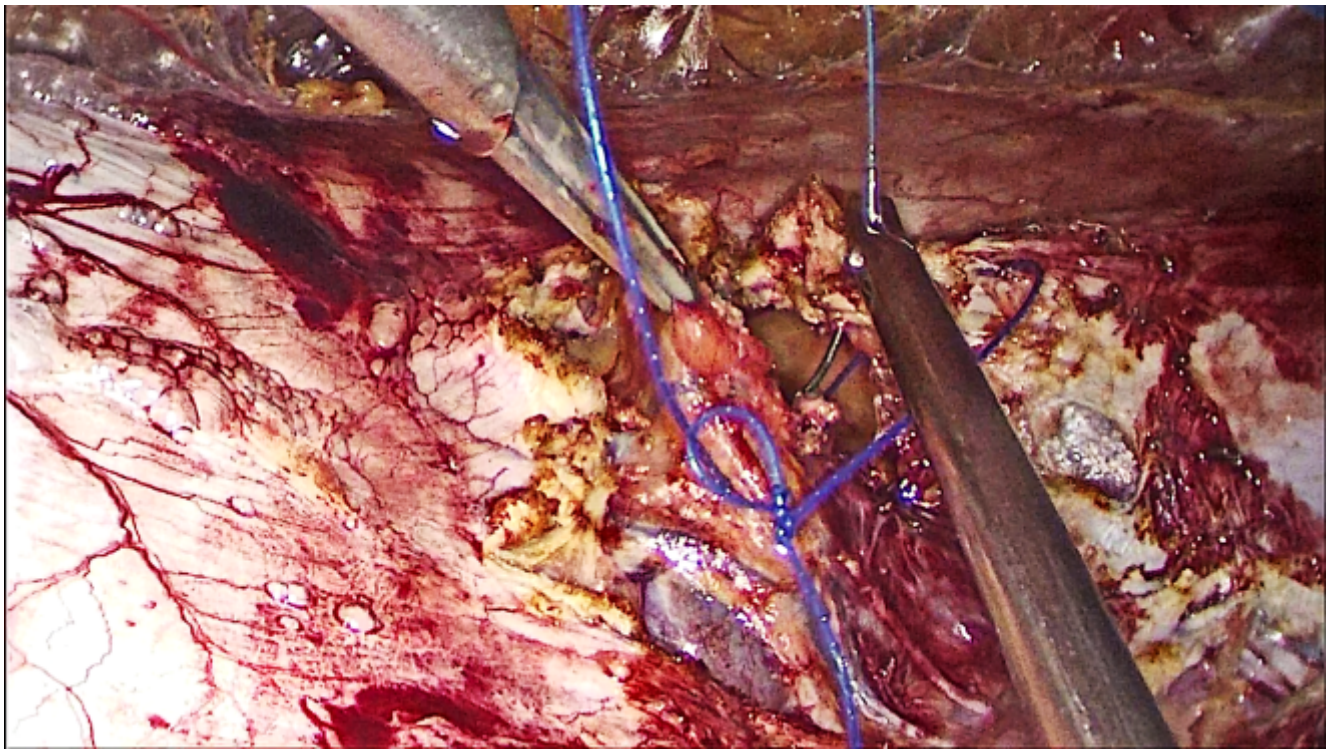

Figure 3

Closure of the posterior layer tears

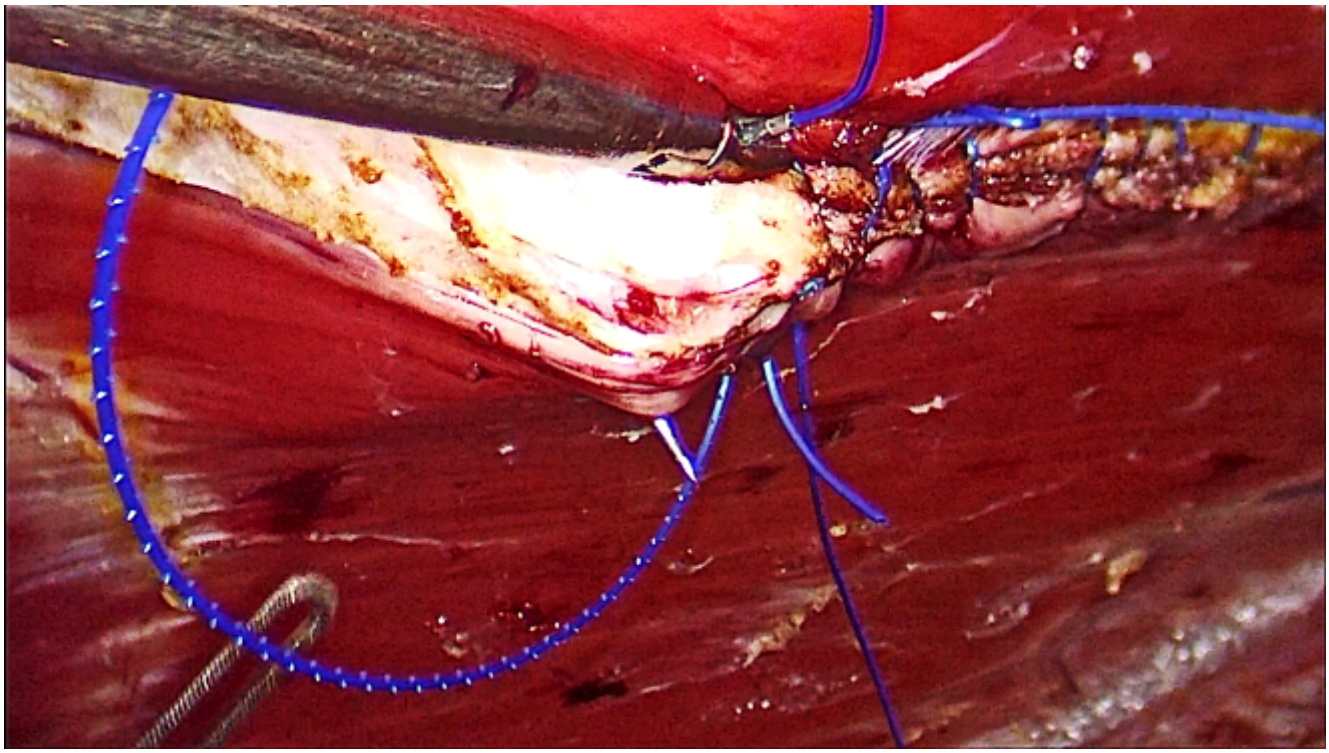

Figure 4

Closure of the anterior rectus sheath (from cephalad to caudal)

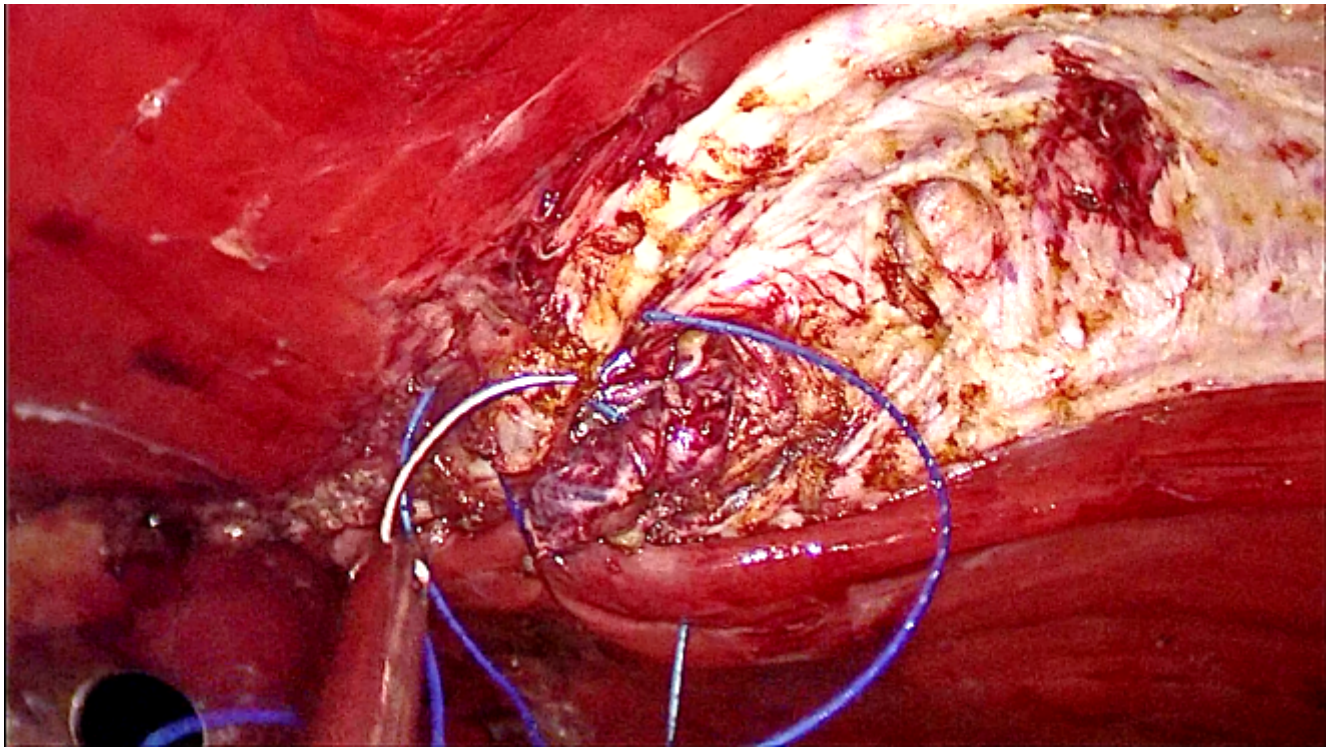

Figure 5

Closure of the anterior rectus sheath (from caudal to cephalad)

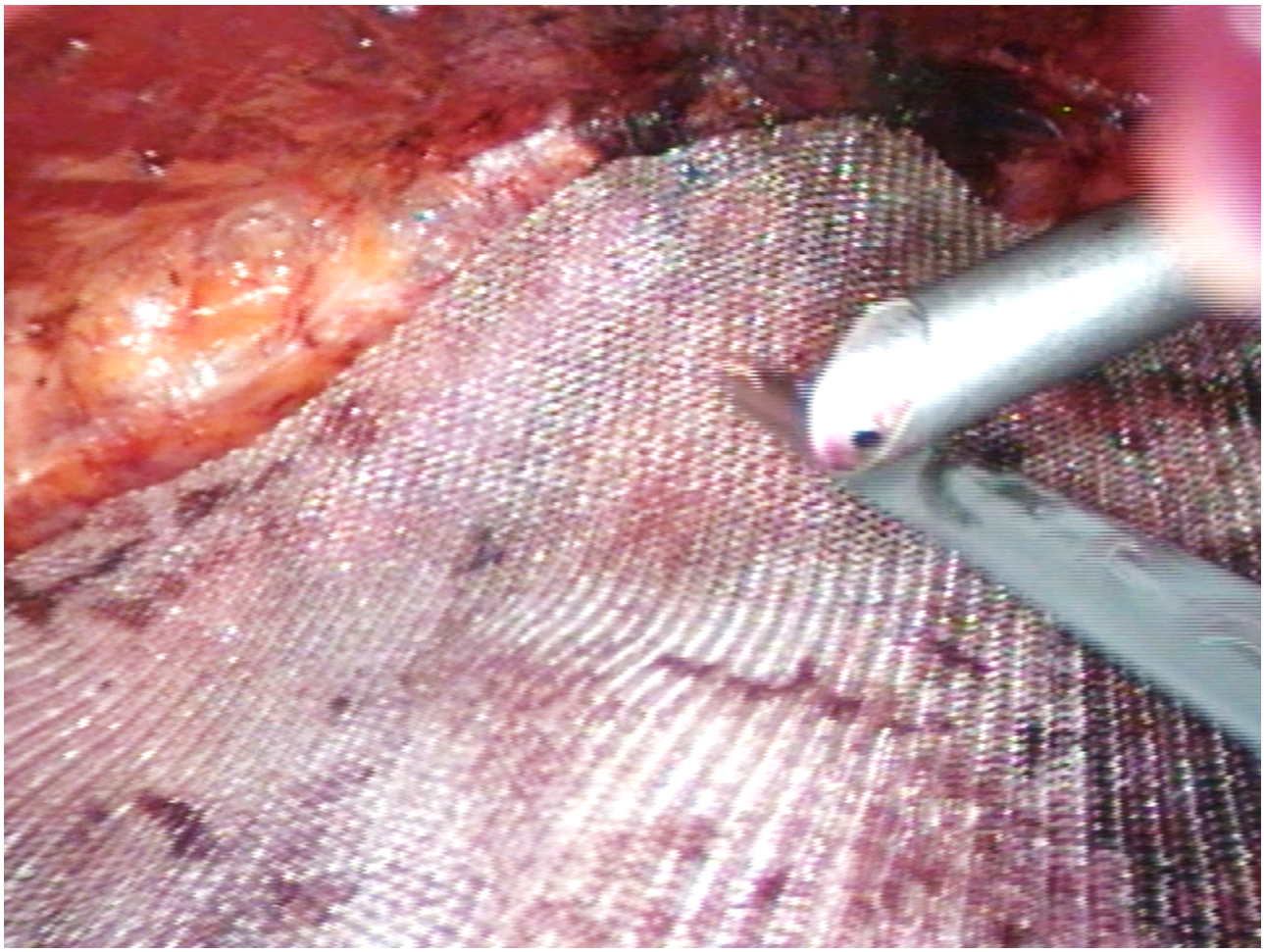

Figure 6

Position of the prothesis

Figure 7

Final aspect