Changes of Deltoid Tissue Properties after Reserve Shoulder Arthroplasty – A Shear Wave Elastography Study

Anabell Fenwick
Universitatsklinikum Augsburg
Thomas Reichel
Orthopadische Klinik Konig-Ludwig-Haus
Lars Eden
Universitatsklinikum Wurzburg
Jonas Schmalzl
St. Vincentius Klinik Karlsruhe
Rainer H Meffert
Universitatsklinikum Wurzburg
Dirk Boehm
Ortho Mainfranken
Piet Plumhoff
Orthopadische Klinik Konig-Ludwig-Haus
Fabian Gilbert (gilbert_f@ukw.de)
Julius-Maximilians-Universitat Wurzburg https://orcid.org/0000-0002-0056-9593

Research article

Keywords: shear wave elastography, strain elastography, shoulder, deltoid muscle, reverse arthroplasty

Posted Date: May 8th, 2020

DOI: https://doi.org/10.21203/rs.3.rs-25951/v1

Abstract

Introduction

The deltoid muscle plays an essential role for the postoperative functional outcome after reverse shoulder arthroplasty. Ultrasound elastography is areliable method for detecting soft tissueproperties and their changes due to different conditions or pathologies. Tissue stiffness is calculated after application of an acoustic impulse (acoustic radiation force impulse, ARFI), which deforms the underlying tissue. The purpose of this study was to evaluate changes in the deltoid muscle tissue after RSA and reveal a correlation to the functional outcome.

Material and methods

18 patients treated with reserve shoulder arthroplasty after proximal humeral fracture or cuff arthropathy were included. Shear wave elastography was performed on both sides of three regions of the deltoid muscle. Functional outcome was recorded by VAS, CMS, range of motion and strength (flexibar). Statistical analysis was performed by SPSS.

Results

The functional outcome was satisfactory (VAS pain: 18 points, VAS function: 64 points, Constant Murley: 66 points). Force was reduced to 48.8N after RTSA in comparison to 58.3 N on the healthy side ($p > 0.07$). SWE was able to show a higher overall muscle tension of the deltoid in patients after RSA compared to the contralateral non-operated side. The differences were particularly visible in the anterior and middle deltoid region. Under isometric load all deltoid regions showed significantly increased tension, which was particularly eminent in the anterior region of the pars clavicularis.

Conclusion

Shear wave elastography is a reliable method for detecting changes of tension in the deltoid muscle after RTSA and shows a higher tension of all areas of the deltoid, especially prominent in the anterior and middle portion of the deltoid. Future application possibilities are monitoring of deltoid vitality, preoperative assessment and intraoperative management.

Level of evidence: diagnostic study, Level III

Introduction

The number of patients undergoing reserve shoulder arthroplasty is steadily increasing also encouraged by the rise of indications. Because of the reverse anatomy in RSA the deltoid muscle plays an essential role for the postoperative functional outcome independent of the condition leading to the operation (a.e. proximal humeral fracture, osteoarthritis or rotator cuff arthropathy). Various factors can have a negative impact on the postoperative outcome, such as fatty muscle atrophy, acromion stress fractures, glenoid

fractures, malpositioning of the prosthesis, scapular notching, too high or not enough tension on the deltoid muscle and axillary nerv damage resulting in a malfunctioning prosthesis and patient dissatisfaction.[12,28, 29]

Ultrasound elastography is a well-known method for tissue evaluation of liver, thyroid or breast diseases.[8,16,24] Recently the focus has been set on musculoskeletal application possibilities.[1,2,5,21] It has therefore been discussed as a reliable method for detecting soft tissue properties and their changes due to different conditions or pathologies in recent literature.[6,15,17,19,31] There are two main varieties – strain und shear wave elastography. SWE has been shown to be less examiner dependent, easily accessible and applicable at a low cost and without contradictions as in contrast to MRI scans or the use of contras.[23] Tissue stiffness is calculated after application of an acoustic impulse (acoustic radiation force impulse, ARFI), which deforms the underlying tissue. Shear waves are then caused by the depending on the amount of deformation of the tissue. The created wave speed is proportional to the tissue properties ae. Stiffness and is measured in m/s. The estimation of shear wave velocity makes a conversion to the elastic modulus using a mathematical equation possible. To create a reliable result the probe has to be positioned parallel to the muscle fibers. There is no need for tissue compression during the exam. SWE is therefore able to provide quantitative information on the elastic modulus of the examined tissues.[18]

Especially the shoulder girdle including the rotator cuff (esp. supraspinatus muscle)[14] and the deltoid muscle as well as the neck muscles and their properties have been subject to investigations. [14,20,25–27] But few studies have included clinical results or tried to correlate the results to the functional outcome.

The purpose of this study was to evaluate the feasibility of shear wave elastography in the deltoid muscle after reverse arthroplasty of the shoulder as well as determine a change in deltoid stiffness in comparison to the contralateral side and the meaning as an influencing factor for the functional outcome.

Material And Methods

18 patients treated with reserve shoulder arthroplasty could be included in our study. In 12 cases arthroplasty was due to omarthritis or cuff arthropathy. Further six cases were performed because of dislocated, irreducible proximal humeral fracture. Surgery was performed by 3 senior consultants specialized in shoulder surgery. The surgical procedure was performed via the deltopectoral approach in all cases.

The local ethic committee approved of the study.

All patients were contacted by telephone and informed about the study. Written informed consent was obtained of every patient included in the study.

Patients’ demographic data as gender, age, smoker status, BMI and medical history were collected from our clinical database.

The ultrasound and shear wave elastography was performed with Aixplorer (SuperSonic Imagine) using a 9 Mhz linear array transducer. Conditions were identical for all examinations.

The ultrasound examination was performed by only one physician. They were performed on every patient on both shoulders in a sitting position with the arm resting palm downwards on the legs (Fig. 1).

The three anatomic regions of the deltoid muscle (Pars clavicularis, pars acromialis, pars spinalis) were separately examined and measured with parallel fibre positioning of the ultrasound probe.[13] As reference for the probe position the humeral neck was visualized (Fig. 2). Each region of interest of the deltoid on both sides was examined in a resting position and under maximum force under abduction. Instead of using various measurement points the specific deltoid area of interest was surrounded manually without interference by fascias or bony substance and the integral for the shear wave velocity as well as the elasticity modulus as reference for tissue stiffness was calculated for. The depth was set between 2 centimetres.

To evaluate the clinical outcome we used the Constant Murley Score[4] as well as the shoulder and elbow visual analog scale[3] and measured the range of motion. Furthermore a force measurement was performed by Flexibar on the operated and the contralateral shoulder.

For radiological assessment the most recent x-rays were examined. A.p., axial and Y views were obtained and measurements for offset, retroversion, tilt as well as acromio-humeral distance calculated.

Statistical analysis was performed using SPSS version 18 (IBM, Armonk NY, USA). Parameters were tested for normal distribution and the level of significance calculated for dependent samples by Mann Whitney U test and Kruskal Wallis test. Pearson's correlation was used to evaluate a connection between strength, clinical outcome and tissue properties. Differences were considered statistically significant if $p < 0.05$.

Results

13 patients were female and the average patient age was 76 (range, 64–84) years. In 66% the right side was operated on. RTSA was performed with prosthesis by Lima (proximal humerus fractures) and Tornier/Wright, Aequalis/Ascend II (cuff arthropathy). The follow up including the ultrasound examination was carried out on average 15 months postoperatively (range, 4–48).

With an average BMI of 25.9 (range, 22.1–30.1) the cohort was slightly obese. Two patients were still active smokers. In average every patient had at least two comorbidities, more than a third of the patients had multi medication (> 5 daily). In this small group is was not able to correlate the comorbidities with the functional outcome.

In total the recorded functional outcome was satisfactory. All patients after RSA due to osteoarthritis claimed they would undergo surgery again. In average 18 points were achieved in the VAS for pain (range,

5–47) and 64 points in the VAS for function (range, 64–97). The Constant Murley Score showed an average of 66 points (range, 35–89). In general patients with RTSA after cuff arthropathy showed better functional results than patients suffering from proximal humeral fractures and also showed a higher satisfaction rate. The average range of motion consisted of 150° of abduction, 25° of internal rotation, 140° of elevation and 25° of external rotation.

In our collective there were no cases of infection and no necessary revisions or periprosthetic fractures.

The force measurement was performed on all patients. As expected patients were not able to create the same amount of force on the RTSA side in comparison to the healthy side. In average 48.8N were achieved after RTSA in comparison to 58.3 N on the healthy side as the maximum capable strength. This difference was only merely significant ($p > 0.07$). We were not able to find any connection between muscle elasticity and the postoperative functional outcome shown in the scores.

Radiological assessment was performed on the most recent available shoulder x rays. In average the prosthesis was positioned at an offset of 39.07 mm with a tilt of 3.2°. The glenosphere was size 36 in all but two cases in which the size was 42 and was implanted in a slight retroversion of 3°. The average acromio-humeral distance was 28.5 mm (range 18.2–33.9 mm).

In all of the examined areas of the deltoid muscle under relaxed circumstances the shear wave elastography SWE was able to show a higher muscle tension of the deltoid in patients after RSA compared to the contralateral non-operated side. The differences were particularly visible in the pars clavicularis PC and pars acromialis PA. There was a statistical significant difference, $p < 0.05$ which did not show in the posterior part, pars spinalis PS (Fig. 3).

Measurements were repeated on both sides under isometric load. Under the force all regions of the deltoid muscle adapted to new condition independent of RSA with a significant increase of elasticity, $p < 0.001$ (Fig. 4). This change of elasticity underlines SWE as a capable method of detecting tissue properties in the deltoid.

Taking a closer look at the elasticity increase under isometric loading there is a difference in increase of RSA and the healthy side. As seen, all deltoid areas showed a higher tension during the load but the amount of increase of elasticity is again to be significantly higher after implantation of RSA (Fig. 5). This increase can only be see in the pars clavicularis and the pars acromialis and is only significantly higher in the pars clavicularis (RSA: 238.96 ± 160; Healthy side: 154.57 ± 114; $p > 0.04$) (Fig. 6,7).

Again we could not correlate the clinical and functional outcome with the elastography findings.

Limitations of this study are to be taken into account a.e. the small amount of patients as well as the heterogenic cohort (fractures, osteoarthritis etc). Further consideration has to go to the isometric loading which was not performed under fully controlled conditions.

Discussion

The question whether shear wave elastography is a reliable method for detecting changes in muscle tissue properties and therefore a method for measuring muscle activity as well as related pathologies has come into recent literature.[2,5,6,14] In a former study we have already proved the value of SWE by showing a correlation of MRI spectroscopic measurement of fatty degeneration and now intend on further developing the possible uses of SWE.[11]

Kim et al.[17] assessed twelve healthy participants during isometric movement of the shoulder girdle and came to the conclusion that SWE is an excellent method for evaluating muscle stiffness in both static and dynamic modes and shows a high inter- and intraobserver reliability.

For this reason we carried out our assessment of the deltoid after RSA in both resting position as well as under isometric loading and were able to confirm the feasibility and use of SWE.

Numerous studies have investigated muscle tissue properties and their pathologies around the shoulder joint and the neck, including evaluation of normal stiffness values for the pericranial muscles as well as changes and values of the rotator cuff and in patients with adhesive capsulitis.[7,17,19,20,25,30]

In our study we concentrated on the properties of the deltoid muscle especially its changes after RSA. Hatta et al.[13] were able to show experimentally on 8 fresh-frozen cadaver shoulders that EUS could be a reliable and feasible method to quantitatively assess the mechanical properties of the deltoid muscle by comparing elongated and native deltoid muscles. The results were especially promising in the anterior and middle portions ($p < 0.05$). These results confirmed our findings that performing RSA results in the anterior and middle portion of the deltoid muscle showing a significant increase of shear modulus in contrast to the contralateral side.

Fischer et al.[9,10] examined the deltoid muscle of 64 patients treated with RSA with contrast enhanced ultrasound (CEUS) as well as EUS and assessed muscle function using various shoulder scores such as Constant score and American Shoulder and Elbow Surgeons Standardized Shoulder Assessment Form score. EUS measurement of the deltoid muscle elasticity revealed that operated-on deltoid muscles showed higher stiffness than contralateral healthy deltoid muscles ($p = 0.545$) which also matches our results. They concluded from the CEUS results that perfusion was the main impact on the postoperative results and named it a surrogate parameter. Further conclusion towards the findings by EUS were not specified.

Roche et al.[23] examined deltoid wrapping and tensioning of the various prosthesis designs and positioning in a computer model of the shoulder. In average RSA resulted in an elongation of the Deltoid of about 10 to 20% siding with a functional shortening of external and internal rotators. Enough tension is necessary for joint stability but too much tension can also result in malfunction and lack of motion. We looked at the various radiological parameters mentioned as crucial in the study (tilt, retroversion) but in this small cohort could not find any significant correlations to our findings in the ultrasound examination.

To our mind the value of SWE lies in possible future fields of use. On the one hand it could be a possible future tool for assessing the function of deltoid muscle. This can include preoperative scanning and recruiting of patients with a good deltoid function who will benefit from RSA as well as postoperative monitoring of deltoid function during follow ups and on the other hand a tool for analysis of complications in cases of malfunctioning prosthesis. It could be able to reveal reasons for acromion stress fractures or deltoid dysfunction.

Further options could consist of intraoperative application and assessing of deltoid elongation and tension which could enable an optimum positioning of components of reverse arthroplasty during the surgical procedure.

Whether our findings actually have a relevant impact on postoperative functional outcome and therefore imply changes to biomechanical designs of implants or the positioning of the prosthesis will have to undergo further investigations and large randomized controlled studies.

Conclusion

Shear wave elastography is a reliable, easily available and reproducible method for detecting changes of tension in the deltoid muscle after RTSA. RTSA leads to a higher tension of all areas of the deltoid muscle which is especially prominent in the anterior and middle portion of the deltoid. We were not able to show a correlation to the clinical and functional results, which could be due to the small sample size and the heterogenic distribution. The interest lies in future application possibilities, which seem to be multiple, a.e. as a monitoring tool of deltoid vitality and function during follow ups in outpatient clinics, preoperative deltoid assessment and therefore improved patient recrutation as well as complication analysis and intraoperative management of deltoid tension while positioning and sizing the implant components.

Declarations

Ethics approval and consent to participate

We declare that the study has been performed in accordance with the Declaration of Helsinki and has been approved by the ethical Committee of the University of Würzburg (Ethical Committee Approval 156/14)

Written informed consent to participate in the study was obtained from each participant.

Written informed consent to participate in the study was obtained from each participant.

Consent for publication

Not applicable

Availability of data and material

The datasets used and/or analyzed during the current study are available from the corresponding author on reasonable request.

Competing interests

The authors declare that they have no competing interests

Funding

This publication was funded by the German Research Foundation (DFG) and the University of Würzburg in the funding program Open Access Publishing.

Authors' contributions

A Fenwick: made substantial contribution in design and conception of the study, performed acquisition of data, performed statistical analysis of the data and interpretation of data, wrote the manuscript

T Reichel: performed acquisition of data and interpretation of data, performed statistical analysis and interpretation of data

L Eden: made substantial contribution in design and conception of the study

J Schmalzl: made substantial contribution in design and conception of the study

P Plumhoff: made substantial contribution in design and conception of the study, revisited the manuscript critically

RH Meffert: made substantial contribution in design and conception of the study, revisited the manuscript critically

F Gilbert: made substantial contribution in design and conception of the study, revisited the manuscript critiallyAll authors approved the final version of the manuscript

Acknowledgments:

none

Literature

1. Bhatia KSS, Rasalkar DD, Lee YP, Wong KT, King AD, Yuen YH, et al. Real-Time Qualitative Ultrasound Elastography of Miscellaneous Non-Nodal Neck Masses: Applications and Limitations. Ultrasound Med Biol. 2010;36(10):1644–52. doi:10.1016/j.ultrasmedbio.2010.07.010.
2. 10.1016/j.apmr.2014.07.007doi:10.1016/j.apmr.2014.07.007
Brandenburg JE, Eby SF, Song P, Zhao H, Brault JS, Chen S, et al. Ultrasound elastography: The new frontier in direct measurement of muscle stiffness. Arch. Phys. Med. Rehabil. [Internet]. 2014;95(11):2207–2219. Available from: http://dx.doi.org/10.1016/j.apmr.2014.07.007doi:10.1016/j.apmr.2014.07.007.
3. Carlsson AM. Assessment of chronic pain. 1. Aspects of the reliabilty and validity of the visual analogue scale. Pain. 1983 May;16(1):87–101.
4. Constant CR, Murley AH. A clinical method of functional assessment of the shoulder. Clin Orthop Relt Res. 1987;214:160–4.
5. Drakonaki EE, Allen GM, Wilson DJ. Ultrasound elastography for musculoskeletal applications. Br J Radiol. 2012;85(November):1435–45. doi:10.1259/bjr/93042867.
6. 10.1016/j.jbiomech.2013.07.033doi:10.1016/j.jbiomech.2013.07.033
Eby SF, Song P, Chen S, Chen Q, Greenleaf JF, An KN. Validation of shear wave elastography in skeletal muscle. J. Biomech. [Internet]. 2013;46(14):2381–2387. Available from: http://dx.doi.org/10.1016/j.jbiomech.2013.07.033doi:10.1016/j.jbiomech.2013.07.033.
7. Ewertsen C, Carlsen J, et al. Reference Values for Shear Wave Elastography of Neck and Shoulder Muscles in Healthy Individuals. Ultrasound Int Open. 2018;39:E23–9.
8. 10.1016/j.ejrad.2012.05.030doi:10.1016/j.ejrad.2012.05.030
Ferraioli G, Tinelli C, Zicchetti M, Above E, Poma G, Di Gregorio M, et al. Reproducibility of real-time shear wave elastography in the evaluation of liver elasticity. Eur. J. Radiol. [Internet]. 2012;81(11):3102–3106. Available from: http://dx.doi.org/10.1016/j.ejrad.2012.05.030doi:10.1016/j.ejrad.2012.05.030.
9. Fischer C, Flammer S, Kauczor HU, Zeifang F, Schmidmaier G, Kunz P. Preoperative deltoid assessment by contrast-enhanced ultrasound (CEUS) as predictor for shoulder function after reverse shoulder arthroplasty: a prospective pilot study. Arch Orthop Trauma Surg. 2019 Oct 17. doi:10.1007/s00402-019-03281-w.
10. 10.1016/j.jse.2016.04.012doi:10.1016/j.jse.2016.04.01
Fischer C, Krammer D, Hug A, et al., Dynamic contrast-enhanced ultrasound and elatography assess deltoid muscle integrity after reverse soulder arthroplasty; JSES, 2016.Available from: http://dx.doi.org/10.1016/j.jse.2016.04.012doi:10.1016/j.jse.2016.04.01.
11. 10.1186/s12891-017-1911-8
Gilbert F, Klein D, Weng AM, Köstler H, Schmitz B, Schmalzl J, Böhm D. Supraspinatus muscle elasticity measured with real time shear wave ultrasound elastography correlates with MRI spectroscopic measured amount of fatty degeneration. BMC Musculoskelet Disord. 2017 Dec 28;18(1):549. doi: 10.1186/s12891-017-1911-8.

12. Greiner SH, Back D, Herrmann S, et al. Degenerative changes of the deltoid muscle have impact on clinical outcome after reversed total shoulder arthroplasty. Arch Orthop Trauma Surgery. 2010;130:177–83.
13. Doi10.1007/s00402-009-1001-y.
14. Hatta T, Giambini H, Sukegawa K, et al. Quantified mechanical properties of the deltoid muscle using the shear wave elastography: potential implications for reverse shoulder arthroplasty. Plos one. 2016;11(5):e0155102.
15. Hatta T, Giambini H, Uehara K, et al. Quantative assessment of rotator cuff muscle elasticity: Reliability and feasibility of shear wave elastography; JBiomech. Nov. 2015;5(14):3853–8. 48).
16. 10.1016/j.jelekin.2015.07.010doi:10.1016/j.jelekin.2015.07.010
Ishikawa H, Muraki T, Sekiguchi Y, Ishijima T, Morise S, Yamamoto N, et al. Noninvasive assessment of the activity of the shoulder girdle muscles using ultrasound real-time tissue elastography. J. Electromyogr. Kinesiol. [Internet]. 2015;25(5):723–730. Available from: http://dx.doi.org/10.1016/j.jelekin.2015.07.010doi:10.1016/j.jelekin.2015.07.010.
17. Itoh A, Ueno E, Tohno E, Kamma H, Takahashi H, Shiina T, et al. Breast Disease: Clinical Application Purpose : Methods : Results : Conclusion. 2006;239(2):341–50.
18. Kim K, Hwang HJ, Kim SG, et al. Can Shoulder muscle activity be evaluated with ultrasound shear wave elastography? Clin Ortho Relat Res. 2018;476:1276–83.
19. Kot BC, Zhang ZJ, Lee AW, Leung VY, Fu SN. Elastic modulus of muscle and tendon with shear wave elastography: Variations with different technical settings. PloS One. 2012;7:e44348.
20. Lalitha P, Balaji Reddy M, Jagannath Reddy K. Musculoskeletal applications of elastography: A pictorial essay of our initial experience. Korean J Radiol. 2011;12(3):365–75. doi:10.3348/kjr.2011.12.3.365.
21. 10.1016/j.jse.2014.04.012doi:10.1016/j.jse.2014.04.012
Muraki T, Ishikawa H, Morise S, Yamamoto N, Sano H, Itoi E, et al. Ultrasound elastography-based assessment of the elasticity of the supraspinatus muscle and tendon during muscle contraction. J. Shoulder Elb. Surg. [Internet]. 2014;24(1):120–126. Available from: http://dx.doi.org/10.1016/j.jse.2014.04.012doi:10.1016/j.jse.2014.04.012.
22. Ophir J, Cespedes I, Ponnekanti H, Yazdi Y, Li X. Elastography: a quantitative method for imaging the elasticity of biological tissues. Ultrasound Imaging. 1991;13(2):111–34. doi:10.1016/0161-7346(91)90079-W.
23. Roche CP, Diep P, Hamilton M, Crosby LA, Flurin PH, Wright TW, Zuckerman JD, Routman HD. Impact of inferior glenoid tilt, humeral retroversion, bone grafting, and design parameters on muscle length and deltoid wrapping in reverse shoulder arthroplasty. Bull Hosp Jt Dis. 2013;71(4):284–93.
24. Schmalzl J, Fenwick A, Böhm D, Gilbert F. The application of ultrasound elastography in the shoulder. J Shoulder Elbow Surg. 2017 Dec;26(12):2236–46. doi:10.1016/j.jse.2017.08.001.
25. 10.1210/jc.2010-0766

Sebag F, Vaillant-Lombard J, Berbis J, Griset V, Henry JF, Petit P, et al. Shear wave elastography: a new ultrasound imaging mode for the differential diagnosis of benign and malignant thyroid nodules. J. Clin. Endocrinol. Metab. [Internet]. 2010;95(12):5281–8. Available from: http://www.ncbi.nlm.nih.gov/pubmed/20881263doi:10.1210/jc.2010-0766.

26. 43/12/2935.longdoi:10.1177/0363546515608476
Takenaga T, Sugimoto K, Goto H, Nozaki M, Fukuyoshi M, Tsuchiya A. Posterior Shoulder Capsules Are Thicker and Stiffer in the Throwing Shoulders of Healthy College Baseball Players: A Quantitative Assessment Using Shear-Wave Ultrasound Elastography. Am J Sport. Med [Internet]. 2015;43(12):2935–2942. Available from: http://ajs.sagepub.com/content/43/12/2935.longdoi:10.1177/0363546515608476.
27. Takuma Y, Mura N, Yuki I. Contractile property measurement of the torn supraspinatus muscle using real-time tissue elastography. JSES. 2018;27:1700–4.
28. Vasishta A, Kelkar A, Joshi P, et al. The value of sonoelastography in the diagnosis of supraspinatus tendinopathy – a comparison study. Br J Radiol. 2019;92:20180951.
29. 10.1016/j.jse.2015.09.015doi:10.1016/j.jse.2015.09.015
Walker DR, Struk AM, Matsuki K, Wright TW, Banks SA. How do deltoid muscle moment arms change after reverse total shoulder arthroplasty? J. Shoulder Elb. Surg. [Internet]. 2016;25(4):581–588. Available from: http://dx.doi.org/10.1016/j.jse.2015.09.015doi:10.1016/j.jse.2015.09.015.
30. Wall B, Nove-Josserand L, O'Connor P, Bradley Edwards T, Walch G. Reverse total shoulder arthroplasty: A review of results according to etiology. JBJS Am. 2007;89:1476–85. Doi:10.2106/JBJS.F.00666.
31. Xie Y, Thomas L, et al. Quantifying cervical and axioscapular muscle stiffness using shear wave elastography. J Electromyogr Kinesiol. 2019 Oct;48:94–102.
32. doi: 10.1016/j.jelekin.2019.06.009. Epub 2019 Jun 22.
33. De Zordo T, Fink C, Feuchtner GM, Smekal V, Reindl M, Klauser AS. Real-time sonoelastography findings in healthy Achilles tendons. Am J Roentgenol. 2009;193(2). doi:10.2214/AJR.08.1843.

Figures

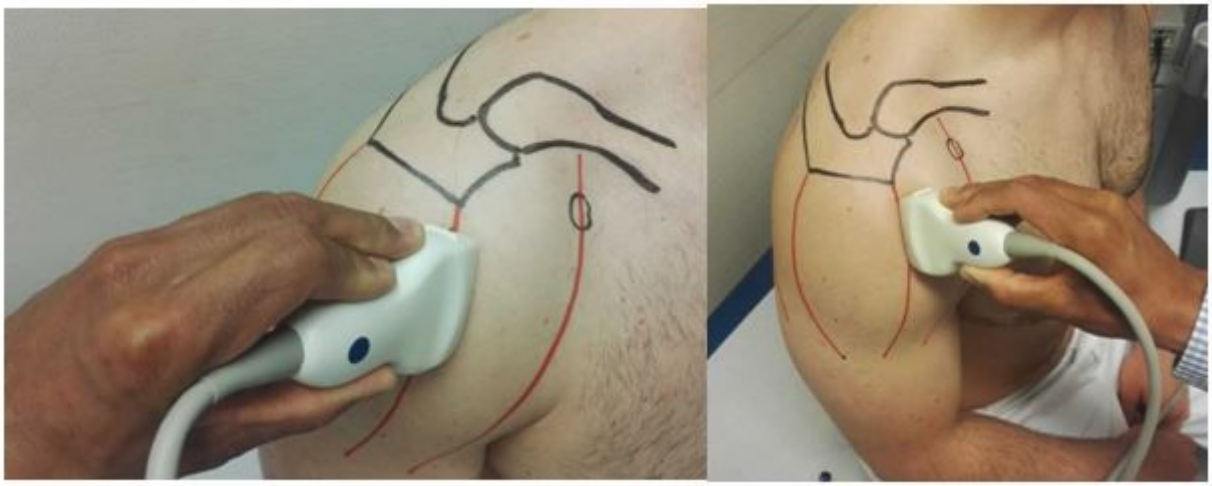

Figure 1

Standard examination set up.

Figure 2

Example for ultrasound slide including humeral neck und deltoid muscle, middle portion as standard examination setup

Figure 3

Shear wave elastography shows a change of deltoid elasticity in each region of the deltoid with an increased tension after RSA than on the healthy contralateral side especially in the anterior and middle portion of the deltoid in resting position without loading ($p<0.05$).

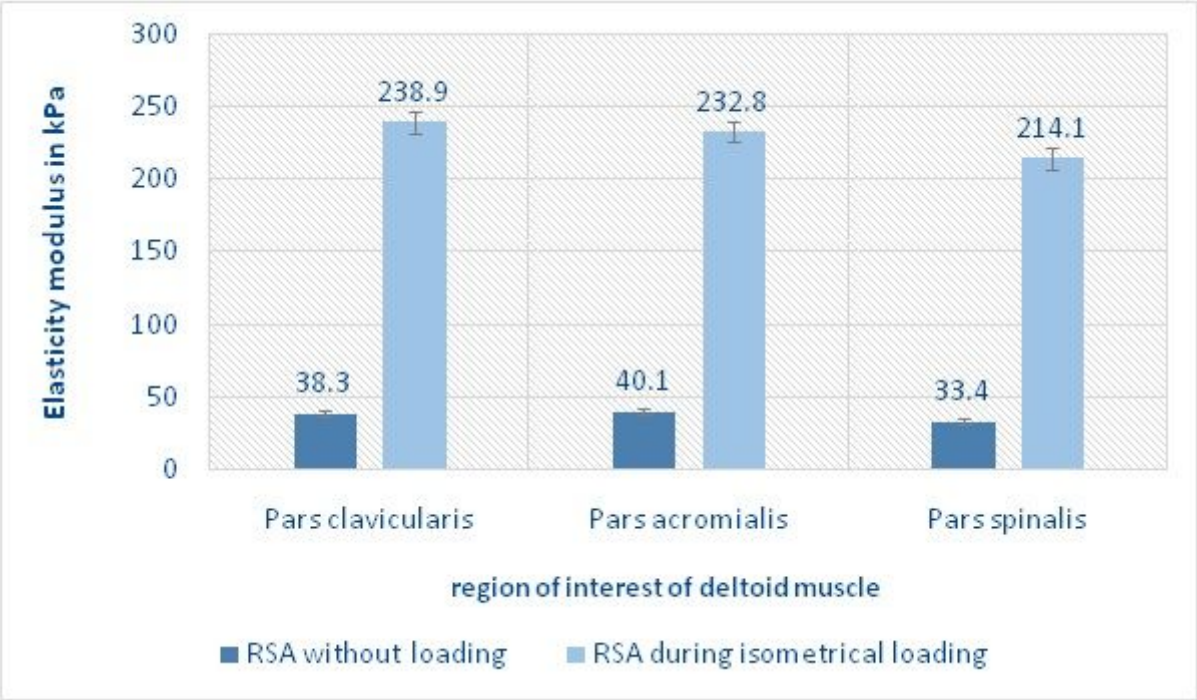

Figure 4

Isometric loading of the shoulder after RSA leads to a significant increase of tension of the whole deltoid muscle in comparison to elasticity measurements in a resting position in the same shoulder $p<0.005$.

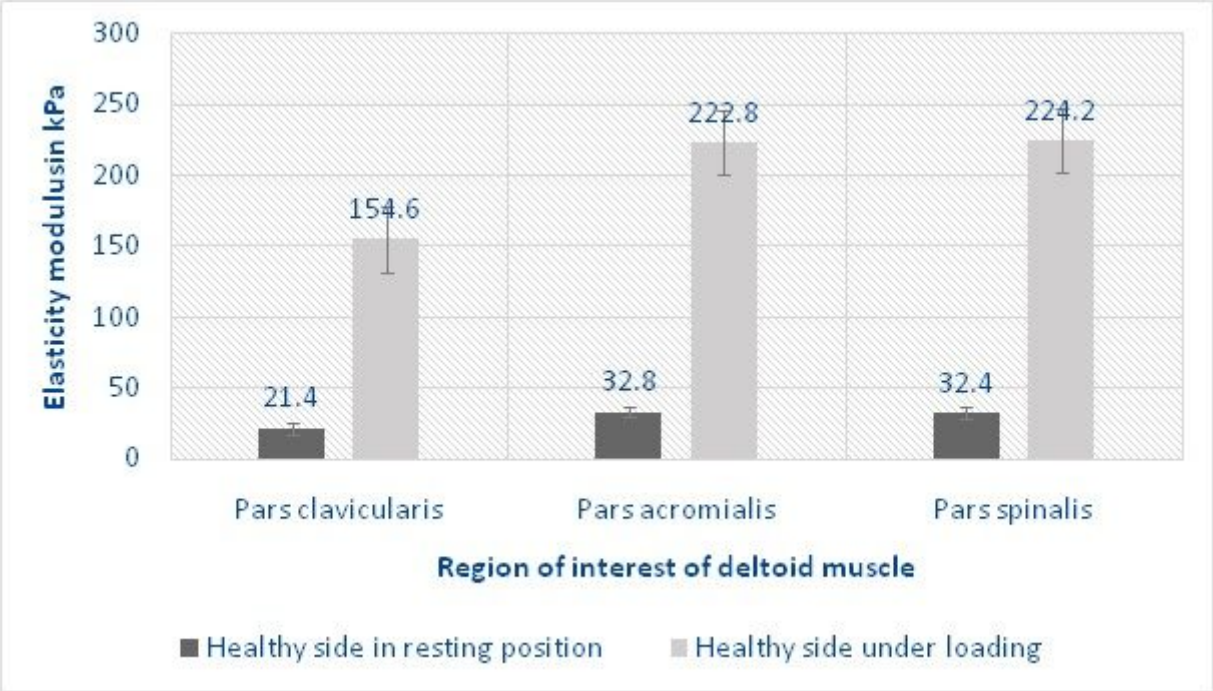

Figure 5

Isometricloading of the contralateral healthy side also leads to an increased tension of all areas of the deltoid muscle. But in comparison to RSA the increase of tension is significantly lower.

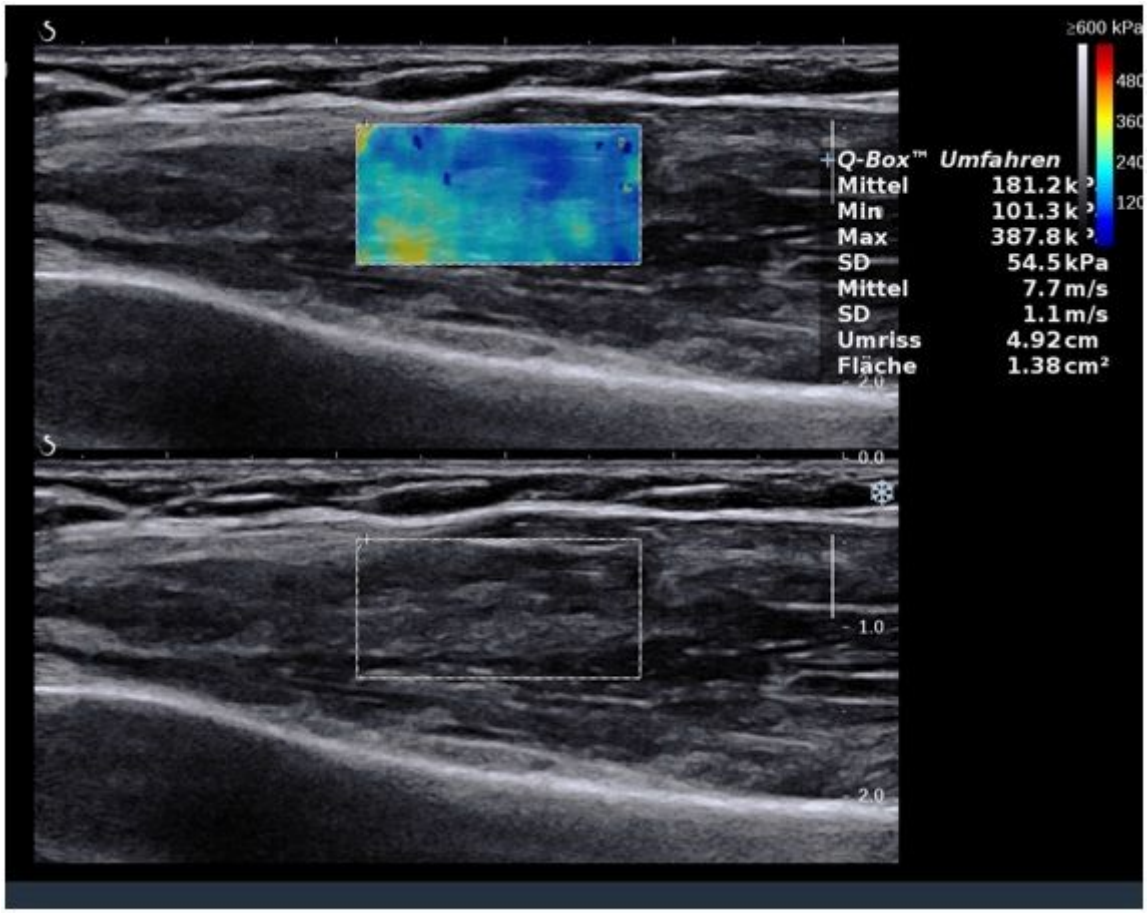

Figure 6

Female, RSA left side, 74 years. Shear wave elastography shows an increased tension in the anterior deltoid part without RSA under isometric load which is visualized by the light blue colour describing an elasticity modulus of around 181.2kPa.

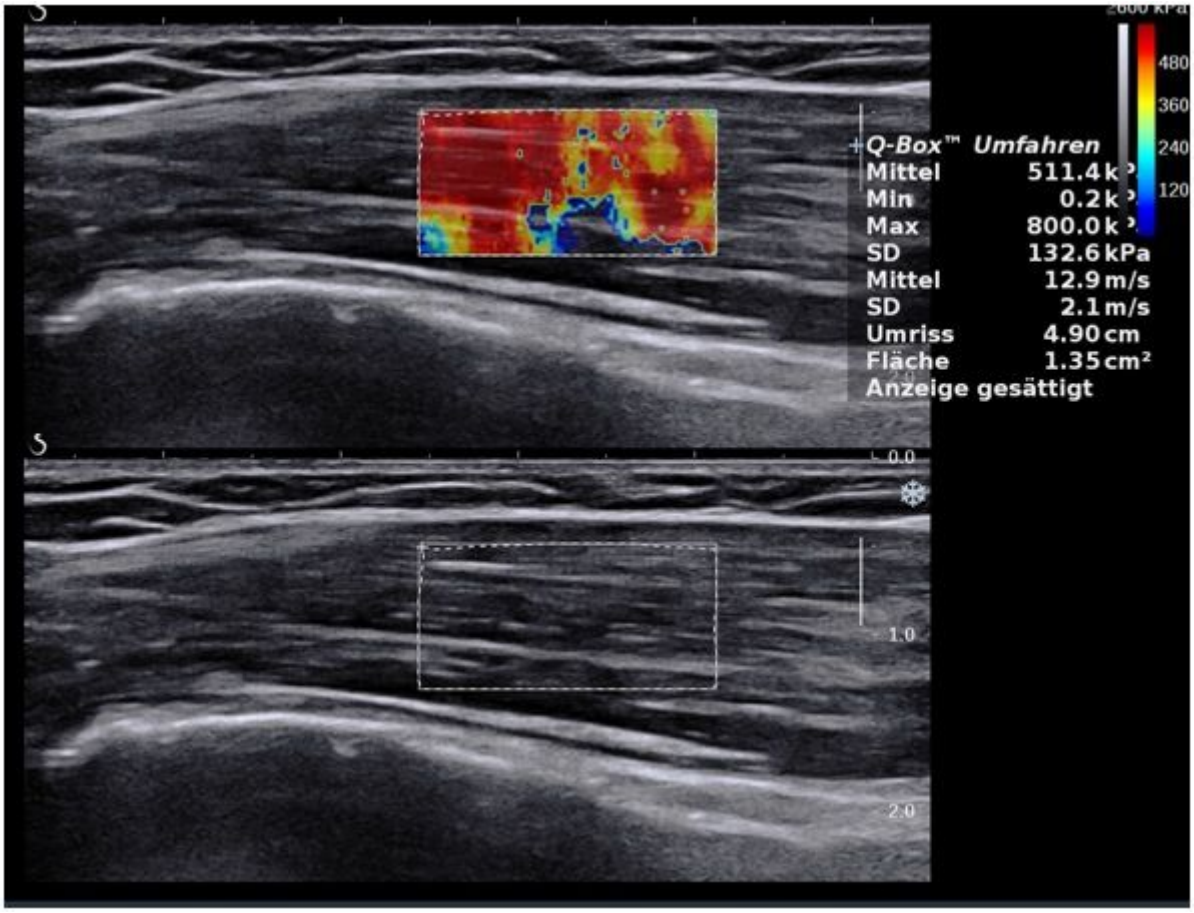

Figure 7

Female, RSA left side, 74 years. Shear wave elastography shows an increased tension in the anterior deltoid part without RSA under isometric load which is visualized by the light blue colour describing an elasticity modulus of around 181.2kPa.