Comparison of three treatment methods for simple bone cyst in children

Ke Xue Zhang
the First Medical center,Chinese PLA General Hospital
Wei Chai
the First Medical Center, Chinese PLA General Hospital
Jia Jia Zhao
Shun Yi District Hospital
Jun Hao Deng
the First Medical Center, Chinese PLA General Hospital
Zhan Peng
the First Medical Center, Chinese PLA General Hospital
Ji Ying Chen (15110245907@163.com)
the first Medical Center, Chinese PLA General Hospital

Research article

Keywords: Child, Bone cyst, Elastic stable intramedullary nail, Autologous bone marrow

Posted Date: November 23rd, 2020

DOI: https://doi.org/10.21203/rs.3.rs-25954/v2

Version of Record: A version of this preprint was published on January 12th, 2021. See the published version at https://doi.org/10.1186/s12891-020-03933-8.

Abstract

Background Unicameral bone cyst (UBC) is a benign tumor whose clinical treatments and efficacy are controversial. The purpose of this study was to evaluate the efficacy of the elastic stable intramedullary nail (ESIN), the injection of autologous bone marrow (ABM) and the combination of ESIN and ABM in the treatment of simple bone cyst of children.

Methods 83 children with simple bone cyst were analyzed retrospectively. 28 cases were treated with ABM. 28 cases were treated with ESIN. 27 cases were treated with ABM and ESIN. All cases were diagnosed through X-ray, CT or MRI scans. For the suspicious ones, pathological biopsy was performed for an accurate diagnosis. X-ray examinations were carried out for the postoperative follow-up. Capanna criteria for bone cyst was used for the postoperative evaluation of the three methods.

Results All the cases accomplished the follow-up. The effective rate of ABM+ESIN group was significantly higher than that of the ABM group ($P<0.05$), and the cure rates of ESIN group and ABM+ESIN group were higher than that of ABM group ($P<0.05$, respectively). The cure time in ESIN group was lower than that of the other two groups ($P<0.05$, respectively). The times for admission were 2.0±0.0 in ESIN group, 5.7±1.9 in ABM group and 4.7±2.4 in ABM+ESIN group ($P<0.05$ when compared with each other).

Conclusions The method of ABM combined with ESIN for children bone cyst has the highest effective and curative rates. For individual method, ESIN has a higher effective rate and curative rate than that of ABM with the lowest time of admission.

Background

Unicameral bone cyst (UBC) is a benign tumor which usually occurs in the epiphysis of the long diaphysis [1-3]. The etiology and pathogenesis of UBC in children have not been identified[3]. There are many treatment methods in clinical practice for bone cysts, such as autograft or allograft bone grafting after lesion curettage[3-5], local injection of autogenous bone marrow (ABM)[6-7] or methylprednisolone[8] , and implantation of elastic stable intramedullary nail (ESIN) [9-11] et al. Among them, local injection of ABM and implantation of ESIN are used widely. However, the comparison of clinical efficacy among ABM, ESIN and ABM combined with ESIN is rarely reported. In this study, we tried to analyze the three methods in a total of 83 children retrospectively to disclose and compare of their efficacy. Twenty-eight cases were treated with ABM, 28 cases were treated with ESIN and 27 cases were treated by ABM combined with ESIN. All patients were evaluated by preoperative and postoperative X-ray examination. The of Capanna evaluation criteria [12] was used to compare the clinical efficacy of bone cyst.

Methods

1.1 Ethical approval

The study was approved by the ethical committee of Chinese PLA General Hospital. Written informed consents for study were obtained from all children's parents.

1.2 Inclusion and Exclusion criteria

Inclusion criteria: (1) Age was under 14 years old. (2) Diagnosis was ascertained by X-ray, CT or MRI images. For the suspicious ones, pathological biopsy was performed. (3) No treatments were performed before admission.

Exclusion criteria: (1) Lesions complicated with other neoplasms. (2) Pathological fractures occurred in the processes of internal and external fixations.

1.3 Criteria for diagnosis

In X-ray plains, simple cyst presents with a round or oval lowdensity area with mild plumping. Its long axis is mostly parallel to the shaft. Bone ridge separation is visible inside of the bone cyst. The boundary of the cyst is clear and sharp, mostly with thin-wall sclerotic edge. Bone debris collapse sign can be found when pathological fracture happens[1 13].

1.4 Patients data

83 children with simple bone cysts were retrospectively studied. They admitted to the department of pediatric orthopedic of Chinese PLA general hospital from January 2010 to December 2016. Twenty-eight cases were treated with ABM. Twenty-eight cases were treated with ESIN. Twenty-seven cases were treated with ABM combined with ESIN. The general data of the patients were shown in Table 1. There were no statistical significances of age, gender constitution, weight and height among the three groups.

1.5 Surgical procedures

ABM Injection[14]: General anesthesia with endotracheal intubation was applied, the child was routinely sterilized and toweled. Before injection, 0.4% lidocaine wainjected on the bone surface for local anesthesia. Under X-ray fluoroscopy guidance , a core-inside needle was punctured to the bone surface. The needle tip slowly pierced into the cortex, with the core withdrawing, light-colored liquid slowly drilled out. Then the needle sheath advanced further with X-ray guidance to the central of the cyst cavity and fastened well. Next, after local anesthesia of the anterior superior iliac spine region, ABM was extracted then slowly injected into the bone cyst cavity. After injection completion, the puncture needle was removed. The puncture points were covered with sterile dressings.

ESIN Implantation[14]: Anesthesia and X-ray fluoroscopy guidance were the same with ABM. A 0.5 cm incision was made at the epiphysis of the long diaphysis away from the bone cyst. Hemostatic forceps bluntly dissected subcutaneous tissue to the bone cortex. The nail drilled a hole in the cortex. The ESIN, pre-bent into a "C" shape, was slowly inserted into the medullary cavity along the drill hole with the guidance of fluoroscopy X-ray. After the ESIN is properly implanted, bending and cutting the outer portion

of the nail for a completely subcutaneous embedding. The incision was sutured and wrapped with sterile gauze.

ESIN+ABM method: After one to three ABM injections with three-month intervals, ESIN implantation was followed.

All cases were given postoperative antibiotics of cefuroxime sodium for two days. The affected limbs were fixed with plaster for six to eight weeks. All cases were encouraged to early exercises after surgery. For cases of lower extremities lesions, in order to avoid pathological fracture, they were encouraged weight-free exercises in bed in the early period of recovery.

1.6 Follow-up and outcome appraisal indicators

The therapeutic effect of treatment was evaluated by the criteria of Capanna[12] for bone cyst. All children received preoperative X-ray, CT or MRI examinations. Pathological biopsy was carried out if necessary. All patients were followed up with X-ray examinations. Preoperative and Postoperative images evaluation were performed for all the patients. In the process of Capanna evaluation, two experienced clinicians conducted double-blind evaluation. When there was difference in the scores of the same patient, the third specialist participated. The evaluation criteria of Capanna[12] for bone cyst: (1) Complete cure: The cyst cavity is completely filled with new bone. No residual lesion is observed. (2) Residual Cure : Lesion area is mostly replaced by newly growing bone tissue. The mixture of newly growing bone with the surrounding cyst wall bone can be seen. The cyst wall of cortex scleroses and thickens. Small transparent areas present in the original cyst site. (3) Recurrence: In the early stage of the treatment, good effect can be observed. Subsequently, transparent areas in the original cyst cavity emerged again. Bone cortex around the cyst becomes thinner. (4) No response: X-ray shows no favorable changes and healing tendency.

Effective cases included complete cure and residual cureones. Effective rate was calculated by the proportion of effective cases to the total number of the cases being treated.

1.7 Statistical analysis

SPSS 20.0 statistical analysis software was used for statistical analysis. One-way ANOVA test was used in the analysis data of admission times, age, and height. Kruskal-wallis rank-sum test was used in the analysis of weight, follow-up duration and therapeutic times for cure ones. Chi-square test was used in the analysis of gender composition, effective rate, cure rate and the site of cyst. $P<0.05$ was considered statistical significance.

Results

2.1 The comparison of three methods in the treatment of bone cyst in children

Following-up completed for all 83 patients. The follow-up time were 32.1±3.2 months in ESIN group, 32.4±9.2 months in ABM group and 31.7±6.3 months in ABM+ESIN group [Table 1]. In ESIN group, 25

cases healed (23 cases cure, two cases residual cure), two cases recurred, one case did not respond to the treatment. In ABM group, 18 cases healed (13 cure, five residual cure), eight cases recurred, and two did not respond to the treatment. In ABM+ESIN group, 26 cases cured and one case residual cured [Table 2]. The effective rate of ABM+ESIN group was significantly higher than that of the ABM group ($P<0.05$), and the cure rates of ESIN group and ABM+ESIN group were significantly higher than that of ABM group ($P<0.05$, respectively). Among three groups who were completely cured (23 in ESIN group, 13 in ABM group and 26 in ABM+ESIN group), the cured period was 22.2±3.3 months in ESIN, 27.7±7.8 months in ABM and 31.3±8.5 months in ABM+ESIN group. The cure period of ESIN group was significantly lower than that of the other two groups ($P<0.05$). The frequency of hospitalization was 5.7±1.9 times in ABM group, 2.0±0.0 times in ESIN group, and 4.7±2.4 times in ABM+ESIN group. Pairwise comparisons between the three groups were statistically significant ($P<0.05$) [Figure 1].

X^2 test was used to compare the therapeutic effect among the three methods. Compared with ABM group, $^*P<0.05$ indicates the statistical significance.

Figure 1 The comparison of hospitalization times and cure period in three groups. 1a. The number of admissions. 1b. Cure time in cured cases. One-way ANOVA test was used. *$P<0.05$, ** $P<0.01$ indicates the statistical significance.

2.2 Case One

Figure 2: Male, nine years old, unicameral bone cyst localized in his left proximal femur. 2a: X-ray before the implantation of ESINs. 2b: X-ray imaging after the implantation of ESINs. The ESINs runs through the proximal end of the cyst. 2c: X-ray imaging at four months after the operation and there is new osteotylus in the cyst. 2d: X-ray imaging at sixteen months after the operation showed more osteotylus formed in the cyst. 2e: X-ray imaging after the removal of ESINs. The bone cyst healed.

2.3 Case Two

Figure 3: Male, nine years old, bone cyst localized in his right humeral bone. 3a: X-ray imagimg before the first ABM therapy. 2b: X-ray imaging before the second ABM treatment (3 months after the first ABM injection). 3c: X-ray imaging before the third ABM treatment (6 months after the first ABM injection), the formation of newly growing bone callus in the cyst can be seen. 3d: X-ray imaging before the fourth ABM treatment (1 year after the first ABM injection), more callus bone could be seen. 3e: X-ray imaging before the seventh ABM treatment (30 months after the 1st bone marrow blood injection)bone cyst is divided into multiple cystic spaces by the newly growing bone. 3f: 42 months after the first ABM injection, the bone cyst healed. 3g: 56 months after the first ABM, the bone cyst was cured.

2.4 Case Three

Figure 4: Male, eight years old, unicameral bone cyst localized in his right distal femur. 4a-4b: The X-ray plains of preoperative and postoperative of ABM injection for the first time. 4c-4d: The second ABM

injection was performed 5 months later. 4e-4f: 5 months later, the ESIN was inserted. 4g-4h: 14 months later, the ESIN was removed and the bone lesion cured.

Discussion

Bone cyst has been studied for more than 100 years, but its pathogenesis and etiology are still unknown. Chigira et al.[15] believed that the increase of intracapsular pressure caused by the stasis of intraosseous vein resulted in the accumulation of a large amount of exudate in the epiphysis of the diaphysis and led to the localized osteonecrosis of the epiphysis, which eventually led to the formation of bone cyst. Injection of ABM can provide growth factors and mesenchymal cells to the cystic cavity. Mesenchymal cells have a variety of differentiation potentials and can differentiate into osteogenic cells then the newly growing bone tissue may be anticipated. This study showed that ESIN had the therapeutic advantage of shorter curative period and fewer hospitalization times compared with that of ABM. ABM provides mesenchymal cells and related growth factors locally, but the pathological condition of cyst formation remains which leaves a high risk of recurrence and refracture[16]. The treatment principles of ESIN are as follows (1) Decompression and drainage of the cyst fluid. Drainage can reduce the pressure within the cyst and even remove the adverse factors that hinder the healing, such as PGE2, lysosomes, toxic free radicals, interleukin-2. (2) ESIN provides support inside the bone marrow cavity. (3) ESIN promotes the growth of new bone around the intramedullary nail. Many scholars also believe that ESIN is the best treatment for patients with simple bone cyst. Roposch et al. [11] treated 32 patients with bone cyst with ESIN, with an average follow-up time of 105 months, and found that the cure rate was as high as 94%De Sanctiset al.[10] treated 47 patients with bone cyst treated by ESIN, with an average follow-up time of 11 years, and found that the cure rate was as high as 100%.

Our study suggested that compared with the previously reported methods of local curettage and bone grafting[12], ESIN had a higher cure rate and a shorter cure period. For the local curettage and bone grafting method, although the lesion is removed ephemerally, pathological conditions causing to the bone cyst formation persist. ABM has the advantages of simplicity and safety, less pain in a single surgery and wide source of bone marrow. Its disadvantages include poor long-term treatment effect, high recurrence rate, high cumulative treatment cost, the need for multiple surgeries and cumulative overall treatment pain. ESIN is more worthy of recommendation in the treatment of simple bone cyst in children.

It should be emphasized that there are some complications and risks associated with ESIN [17]. Most bone cysts occur at both ends of the long bone and close to the epiphyseal plate. In the case whose cyst is adjacent to or invades the epiphyseal periphery, improper implantations of the ESINs easily cause damage of epiphysis plate, which will result in negative effect in the growth and development of the bone. Furthermore, when the cyst occurred in a thin bone. ESIN could easily penetrate outside of the bone cortex (such as case one), which will lead to the damage of surrounding blood vessels and nerves. ESIN tail can often lead to the irritant reaction of the subcutaneous tissue, which may cause local inflammatory hyperplasia and ulceration. For avoidance of the epiphysis plate injury, if the implantation

of ESIN becomes superficial, it will compromise the function of supporting and draining which will lead to unsatisfactory therapeutic effect. Hence, we propose ABM method for this kind of patients in the early stage of therapy. When new callus in the cyst presents, ESIN combined with ABM was recommended to reduce the following surgical manipulations. Our study showed that the combination of ABM and ESIN has advantages of the two methods, especially for the treatment of the bone cyst adjacent to the epiphyseal plate. It has the characteristics of higher efficiency and cure rate.

The limitations of this study was that it was a retrospective study with short follow-up period. The average age of patients was around 7 years old in all 3 groups and the overall follow-up was 32 months (average) in all groups. The follow-up period needs to be extended in the future. Meanwhile, further mechanism study of the combination therapy of ABM and ESIN should be continued.

To summarize, ABM combined with ESIN has a definite efficacy for the treatment of children bone cyst with a high cure rate and controllable treatment process, especially for the cases of cyst adjacent to the epiphysis periphery, even evade the epiphysis plate. This method is worthy of clinical application. ESIN is better than that of ABM with a less hospitalization times and shorter cure period.

Abbreviations

Unicameral bone cyst (UBC); Autogenous bone marrow (ABM); Elastic stable intramedullary nail (ESIN); Computerized tomography (CT); Magnetic Resonance Imaging (MRI); Analysis of variance (ANOVA); Chinese People's Liberation Army (PLA)

Declarations

All authors of this research paper have directly participated in the research. No part of this paper has published or submitted elsewhere.

Ethics approval and consent to participate

The study was approved by the ethical committee of Chinese PLA General Hospital. Written informed consents for study were obtained from all children‘s parents.

Consent for publication

Not applicable

Availability of data and materials

All data generated or analysed during this study are included in this published article and its supplementary information files.

Competing interests

None

Funding

This work was supported by grants of Military Medical and Health Achievement Fund (19WKS09), Military Medicine Youth Fund of PLA General Hospital (QNF19056) and grants of Foundation and Strengthening Program in Technical Area (2019-JCJQ-JJ-149).

Author contribution

KXZ and WC wrote the manuscript and did the study work. JJZ, JHD and ZP did the study work. JYC designed and conducted the study. All authors read and approved the final manuscript

Acknowledgements

Not applicable

Authors' Information

Department of Pediatric Surgery, Chinese PLA General Hospital, Beijing, 100853, China (KXZ).

Department of Orthopaedics, Chinese PLA General Hospital, Beijing, 100853, China (JYC, WC, JHD and ZP).

Department of Anesthesiology, Shun Yi District Hospital, Beijing, 101300, China (JJZ).

References

1. Zhang P, Zhu N, Du L, et al. Treatment of simple bone cysts of the humerus by intramedullary nailing and steroid injection. *BMC Musculoskelet Disord* 2020;21(1):70. doi: 10.1186/s12891-020-3054-6
2. Hou T, Wu Z, Xing J, et al. Tissue-engineered bone treating simple bone cyst–a new strategy. *J Surg Res* 2016;200(2):544-51. doi: 10.1016/j.jss.2015.09.032
3. Noordin S, Allana S, Umer M, et al. Unicameral bone cysts: Current concepts. *Ann Med Surg (Lond)* 2018;34:43-49. doi: 10.1016/j.amsu.2018.06.005
4. Zhang K, Wang Z, Zhang Z. Comparison of curettage and bone grafting combined with elastic intramedullary nailing vs curettage and bone grafting in the treatment of long bone cysts in children. *Medicine (Baltimore)* 2019;98(25):e16152. doi: 10.1097/MD.0000000000016152
5. Mavcic B, Saraph V, Gilg MM, et al. Comparison of three surgical treatment options for unicameral bone cysts in humerus. *J Pediatr Orthop B* 2019;28(1):51-56. doi: 10.1097/BPB.0000000000000518
6. Kadhim M, Thacker M, Kadhim A, et al. Treatment of unicameral bone cyst: systematic review and meta analysis. *J Child Orthop* 2014;8(2):171-91. doi: 10.1007/s11832-014-0566-3

7. Kadhim. M, Sethi. S, Thacker MM. Unicameral Bone Cysts in the Humerus:Treatment Outcomes. *J Pediatr Orthop* 2016;36(4):7.
8. Zhao JG, Wang J, Huang WJ, et al. Interventions for treating simple bone cysts in the long bones of children. *Cochrane Database Syst Rev* 2017;2:CD010847. doi: 10.1002/14651858.CD010847.pub3
9. Pogorelic Z, Kadic S, Milunovic KP, et al. Flexible intramedullary nailing for treatment of proximal humeral and humeral shaft fractures in children: A retrospective series of 118 cases. *Orthop Traumatol Surg Res* 2017;103(5):765-70. doi: 10.1016/j.otsr.2017.02.007
10. de Sanctis N, Andreacchio A. Elastic stable intramedullary nailing is the best treatment of unicameral bone cysts of the long bones in children?: Prospective long-term follow-up study. *Journal of pediatric orthopedics* 2006;26(4):520-25. doi: 10.1097/01.bpo.0000217729.39288.df
11. Roposch A, Saraph V, Linhart WE. Flexible intramedullary nailing for the treatment of unicameral bone cysts in long bones. *J Bone Joint Surg Am* 2000;82(10):1447-53. doi: 10.2106/00004623-200010000-00011
12. Capanna R, Dal Monte A, Gitelis S, et al. The natural history of unicameral bone cyst after steroid injection. *Clinical orthopaedics and related research* 1982(166):204-11.
13. Noordin S, Allana S, Umer M, et al. Unicameral bone cysts: Current concepts. *Annals of medicine and surgery (2012)* 2018;34:43-49. doi: 10.1016/j.amsu.2018.06.005
14. Zhang K-X, Chou X-B, Li H-Y. Treatment of long bone cyst in children by autologous bone marrow blood injection and elastic intramedullary needle. *Zhongguo Gu Shang* 2019;32(5):475-78. doi: 10.3969/j.issn.1003-0034.2019.05.017
15. Chigira M, Maehara S, Arita S, et al. The aetiology and treatment of simple bone cysts. *J Bone Joint Surg Br* 1983;65(5):633-37.
16. Lokiec F, Ezra E, Khermosh O, et al. Simple bone cysts treated by percutaneous autologous marrow grafting. A preliminary report. *J Bone Joint Surg Br* 1996;78(6):934-37. doi: 10.1302/0301-620x78b6.6840
17. Neer CS, 2nd, Francis KC, Marcove RC, et al. Treatment of unicameral bone cyst. A follow-up study of one hundred seventy-five cases. *J Bone Joint Surg Am* 1966;48(4):731-45.

Tables

Table 1 General clinical data in 83 cases among three groups

Group	Cases	Gender		Age	Weight	Height	Follow-up time	Location of cyst				
		Male	Female	($\bar{x}$±s,year)	($\bar{x}$±s,kg)	($\bar{x}$±s,cm)	($\bar{x}$±s,month)	proximal humerus	proximal femur	proximal tibia	femoral shaft	distal femur
ABM	28	16	12	7.7±2.0	17.6±4.0	121.9±7.3	32.4±9.2	10	8	6	4	0
ESIN	28	18	10	7.5±3.1	18.1±3.0	120.8±6.1	32.1±3.2	11	7	5	4	1
ABM+ESIN	27	17	10	7.7±2.3	18.3±4.0	122.7±7.0	31.7±6.4	10	6	5	4	2
F	-	0.3		0.1	2.2	0.5	0.7	2.5				
P	-	0.8		0.9	0.3	0.6	0.7	1.0				

Table 2 The comparison of three methods in the treatment of bone cyst in children

Group	Case	Number of effective cases (effective rate)	Cured cases (cure rate)
ABM	28	18（64.3%）	13（46.4%）
ESIN	28	25（89.3%）	23（82.1%）*
ABM+ESIN	27	27（100%）*	26（96.3%）*

Figures

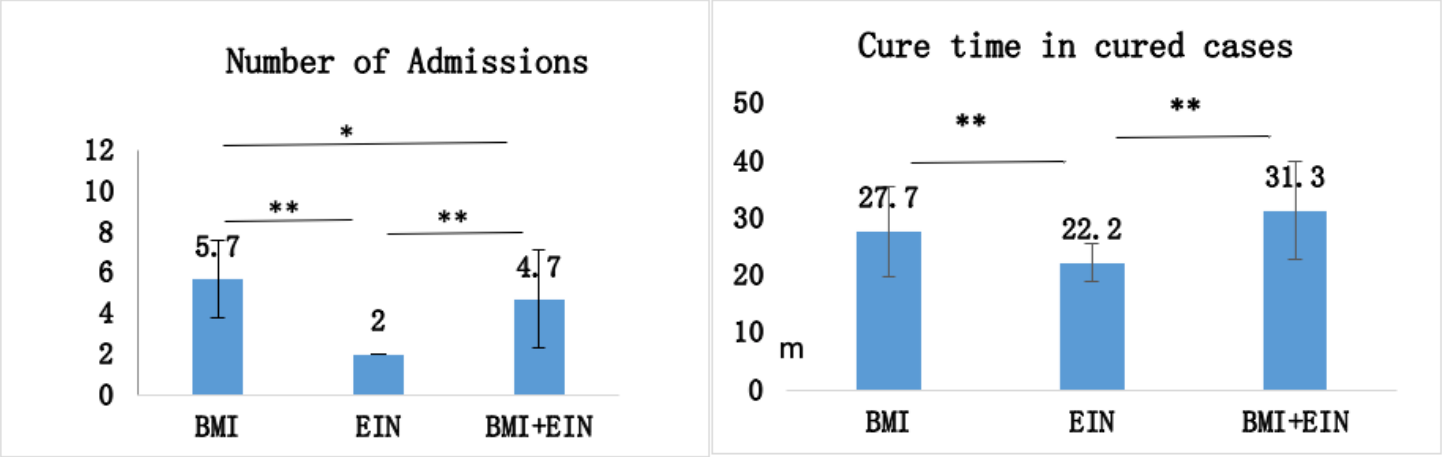

1a 1b

Figure 1

The comparison of hospitalization times and cure period in three groups. 1a. The number of admissions. 1b. Cure time in cured cases. One-way ANOVA test was used. *P<0.05, ** P<0.01 indicates the statistical significance.

Figure 2

Male, nine years old, unicameral bone cyst localized in his left proximal femur. 2a: X-ray before the implantation of ESINs. 2b: X-ray imaging after the implantation of ESINs. The ESINs runs through the proximal end of the cyst. 2c: X-ray imaging at four months after the operation and there is new osteotylus in the cyst. 2d: X-ray imaging at sixteen months after the operation showed more osteotylus formed in the cyst. 2e: X-ray imaging after the removal of ESINs. The bone cyst healed.

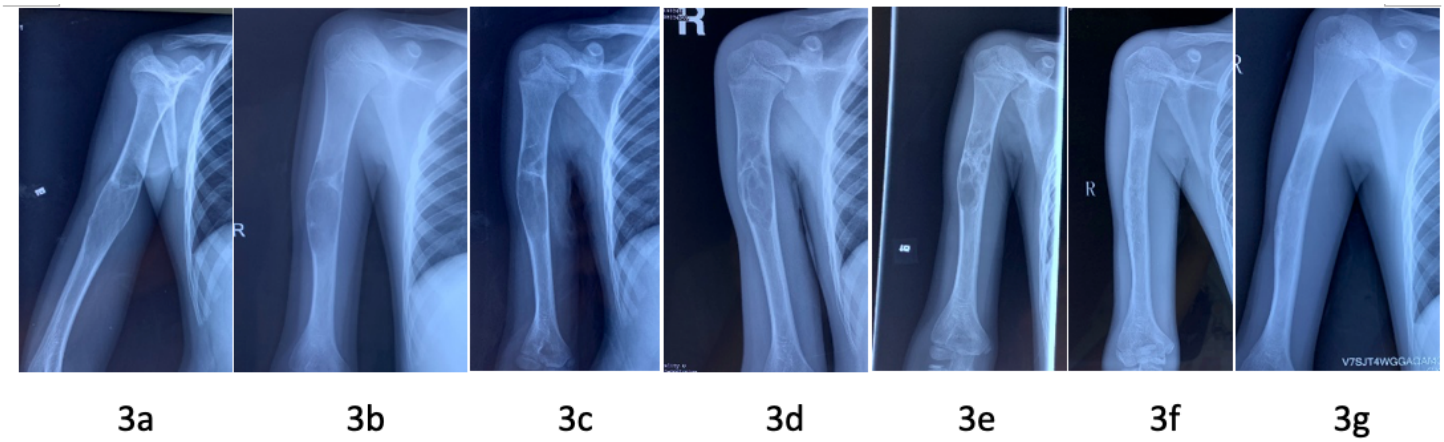

Figure 3

Male, nine years old, bone cyst localized in his right humeral bone. 3a: X-ray imagimg before the first ABM therapy. 2b: X-ray imaging before the second ABM treatment (3 months after the first ABM injection). 3c: X-ray imaging before the third ABM treatment (6 months after the first ABM injection), the formation of newly growing bone callus in the cyst can be seen. 3d: X-ray imaging before the fourth ABM treatment (1 year after the first ABM injection), more callus bone could be seen. 3e: X-ray imaging before the seventh ABM treatment (30 months after the 1st bone marrow blood injection)bone cyst is divided into multiple cystic spaces by the newly growing bone. 3f: 42 months after the first ABM injection, the bone cyst healed. 3g: 56 months after the first ABM, the bone cyst was cured.

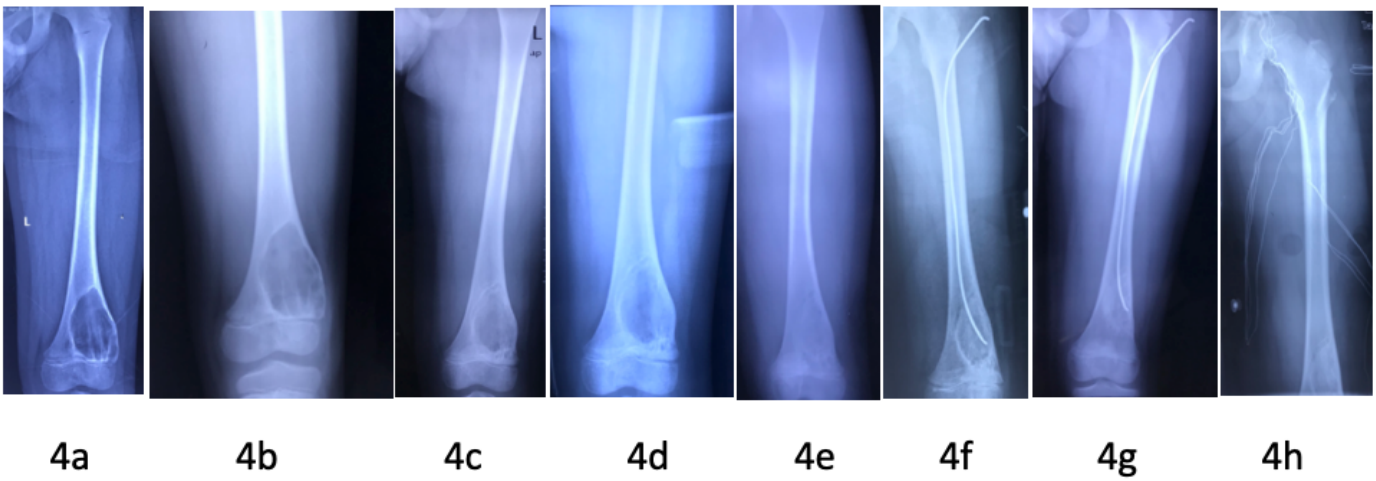

Figure 4

Male, eight years old, unicameral bone cyst localized in his right distal femur. 4a-4b: The X-ray plains of preoperative and postoperative of ABM injection for the first time. 4c-4d: The second ABM injection was performed 5 months later. 4e-4f: 5 months later, the ESIN was inserted. 4g-4h: 14 months later, the ESIN was removed and the bone lesion cured.