The surgical treatment of retroperitoneal echinococcosis: the experience of a single center

Jingyu He
Sichuan University West China Hospital

Chuang Yang
The Third Hospital of Mianyang,Sichuan Mental Health Center

Yiwen Qiu
Sichuan University west China Hospital

Wentao Wang (wwtdoctor02@163.com)
Sichuan University West China Hospital https://orcid.org/0000-0002-6966-2665

Research article

Keywords: Retroperitoneal, Echinococcosis, Surgical treatment

Posted Date: May 8th, 2020

DOI: https://doi.org/10.21203/rs.3.rs-26026/v1

Abstract

Background

Echinococcosis refers to a worldwide epidemic of zoonotic parasites that commonly affect the human liver, lungs, and omentum and can be classified as cystic echinococcosis (CE) and alveolar echinococcosis (AE).Retroperitoneal echinococcosis (RE) is a rare condition that is associated with a high mortality and disability rate. Because RE manifests in a concealed and deep location, and can often involve several important organs, it is associated with a high rate of misdiagnosis, a high risk of surgery, and is extremely difficult to manage.

Methods

This was a retrospective analysis of the characteristics and surgical management of patients diagnosed with RE in our hospital between 2012 and 2019.

Results

Between 2012 and 2019, 1257 cases of echinococcosis and 121 cases of RE were diagnosed in our hospital. Of these, 68 cases involved surgical treatment, 53 involved non-surgical treatment, and 12 cases were lost to follow-up (four cases in the surgical group and eight cases in the non-surgical group). Thus, 109 cases were followed-up. RE cases were divided according to different treatment methods into a radical resection group (Group A, 31 cases), a non-radical resection group (Group B, 37 cases), and a non-surgical group (Group C, 53 cases). We carried out a detailed analysis of the 109 cases experiencing surgical intervention with effective follow-up; there were 31 cases of radical resection (Group A), 33 cases of non-radical resection (Group B).

Conclusions

Our analysis found that RE is rare and can occur at any age; the cystic form is common and often involves multiple organs. The liver is the most commonly affected organ and is associated with serious complications. The rate of radical resection for RE is low, and multiple organ resection is often required; there is a high incidence of postoperative complications. Radical resection is the first line of treatment of RE, although non-radical surgery can benefit most patients. It is important to emphasize the importance of the first round of surgery, particularly in cases involving hepatic echinococcosis. If the lesion can be removed radically during the first round of surgery, then radical surgery should be performed.

Background

Echinococcosis is a global epidemic of zoonotic diseases caused by Echinococcus larvae. There are several species of Echinococcus, although *E. granulosus* and *E. multilocularis* are the main pathogenic microorganisms in humans. These species cause cystic echinococcosis (CE) and alveolar echinococcosis (AE), respectively, and have serious impacts on global public health. These diseases are considered as neglected tropical diseases (NTDs) and neglected zoonotic diseases (NZDs) and have been prioritized by the World Health Organization (WHO). In endemic areas, the incidence of CE is 1 to 200 per 100000, while that of AE ranges from 0.03 to 1.2 per 100000 [1]. Without effective treatment, more than 90% of patients with AE will die within 10–15 years. CE is associated with higher rates of disability; the fatality rate, at 2% – 4%, is significantly lower than that of AE [2]. The existing literature reports that the principles of echinococcosis treatment are mainly focused on hepatic echinococcosis (HE). There are different forms of treatment available, including follow-up, albendazole, intervention, and surgery; the appropriate form of treatment is usually selected according to the stage of echinococcosis, the overall condition of the patient, along with the location and number of lesions [3]. Radical surgical resection is the gold standard for the treatment of echinococcosis [4]. However, for various reasons, most patients cannot choose radical resection at the time of consultation and are forced to choose medication or non-radial surgery [5]. There is no uniform standard for determining the exact form of surgical method and the timing of surgery. Some scholars rate non-radial surgery very highly and point out the fact that radical resection and non-radial resection can achieve similar survival rates. Surgical resection, combined with long-term chemotherapy, can also provide a better prognosis for patients with AE [6].

The most commonly affected organ in cases involving echinococcosis is the liver (50–70% of cases), followed by the lungs (20–30% of cases), and to a far lesser extent, the central nervous system, heart, bones, kidneys, spleen, and other organs[7]. Retroperitoneal echinococcosis (RE) is rare[8] and can be divided into primary retroperitoneal echinococcosis (PRE) and secondary retroperitoneal echinococcosis (SRE); the incidence of SRE is relatively high. The existing literature only features reports of retroperitoneal cyst hydatids but only in case reports [9, 18, 19]. Because RE has a hidden onset, deep location, and often invades multiple important organs, there is a very high risk of misdiagnosis and a serious risk of surgery; this condition is extremely difficult to manage. Due to the low incidence of RE, there is a serious lack of discussion in the literature as to how to treat this condition. In this study, we analyzed the medical records, diagnostic criteria, and treatment methods used in our center for RE. Our goal was to facilitate a better understanding of how to treat RE.

Methods

Patients

This study was a retrospective analysis of 121 cases of RE that were diagnosed clinically and pathologically in West China Hospital of Sichuan University between June 2012 and June 2019. As 12 cases were lost to follow-up, our final analysis involved 109 cases. We analyzed the clinical characteristics of all cases, the selection of surgical method, whether or not multiple organ resection was

involved, postoperative complication rate, postoperative symptom remission rate, perioperative mortality, lesion recurrence rate/lesion progression rate, survival rate, mean length of hospitalization, and other indicators.

Preoperative assessment

We used enhanced abdominal computed tomography (CT) or magnetic resonance imaging (MRI) examinations to evaluate each lesion and its relationship with surrounding organs and CT of the head and chest to assess the presence of intracranial and pulmonary lesions. The detection of hydatid antibodies can also help to diagnose hydatid disease[10]. We also determined whether the lesion could be removed and determined the surgical method to be used. We also performed an electrocardiogram and hematology tests to assess whether each patient could tolerate surgery.

Surgical and postoperative management

Patients selected radical resection if it was deemed possible to completely remove the lesion (Fig. 1). Radical resection was considered the preferential option if it was possible to completely resect the lesion and surrounding invaded tissue[20] and/or the lesion involved additional organs or involved important organs. If the lesion could not be radically removed but seriously affected the quality of life, then non-radical resection or drainage was considered (Fig. 2, 3), as long as the patient was able to tolerate surgery. Patients who underwent radical resection were given oral albendazole (15–20 mg/kg/d) for 2 years. Patients undergoing non-radical surgery or conservative treatment were given long-term albendazole (20 mg/kg/d) [15] to prevent re-infection post-surgery. Patients were followed-up for a mean of 40.2 (range: 6–84) months.

Statistical analysis

Statistical analysis was performed with SPSS software version 21.0 (IBM Corp., Armonk, NY, USA). Normally distributed continuous variables are given as means ± standard deviation (SD), while non-normally distributed variables are given as medians. Comparison between groups were performed with Fisher's exact test. Differences were considered to be statistically significant if $p < 0.05$.

Results

Between 2012 and 2019, 1257 cases of echinococcosis and 121 cases of RE were diagnosed in our hospital. Of these, 68 cases involved surgical treatment, 53 involved non-surgical treatment, and 12 cases were lost to follow-up (four cases in the surgical group and eight cases in the non-surgical group). Thus, 109 cases were followed-up. RE cases were divided according to different treatment methods into a radical resection group (Group A, 31 cases), a non-radical resection group (Group B, 37 cases), and a non-surgical group (Group C, 53 cases). A detailed analysis of the clinical characteristics of these three groups is given in Table 1. The numbers of AE and CE cases in Groups A, B, and C were 13/18, 12/25, 18/35, respectively. There were 13, 23, and 35 cases, who had received one or more rounds of surgery in Groups A, B, and C, respectively; 9, 18, and 29 cases had liver surgery; and 28, 37, and 45 cases had symptoms. All patients showed symptoms have different degrees of pain. There was one case of paraplegia in Group C; six, 16, and 36 cases with co-infection in Groups A, B, and C, respectively; 20, 26, and 35 cases with liver involvement, and 22, 34,

and 35 cases with multiple lesions. The overall 1-, 3-, and 5-year survival rates for patients in the non-surgical group with effective follow-up were 64.45%, 35.56%, and 13.33%. Next, we carried out a detailed analysis of the 109 cases experiencing surgical intervention with effective follow-up(Table 2); there were 31 cases of radical resection (Group A), 33 cases of non-radical resection (Group B); there was a significant difference between Group A and Group B with regards to combined organ resection [Group A (28/31, 90.3%) *vs* Group B (0), P < 0.05]. There were also significant differences between Groups A and B with respect to postoperative complication rate [Group A (4/31, 12.9%) *vs* Group B (14/33, 42.4%), P < 0.05]; postoperative symptom relief rate [Group A (31/31, 100%) *vs* Group B (21/33, 63.6%), P < 0.05]; recurrence rate/lesion progression rate [Group A (6/33, 19.4%) *vs* [Group B (26/33, 78.8%), P < 0.05]; the 1-, 3-, and 5-year survival rates [Group A (100%, 100%, 96.8%) *vs* Group B (93.9%, 75.8%, 51.5%), P < 0.05] and mean number of hospitalization days [Group A (12 days) *vs* Group B (16 days), P < 0.05]. The perioperative mortality rate was 0.

Table 1. The clinical characteristics of the patients enrolled in this study.

	Surgery group（n）		Nonoperative group（n）
	Group A	Group B	Group C
Male/female	15/16	16/21	53
Age(years)	42.9	43.8	42.3
AE/CE	13/18	12/25	18/35
Surgical history	13	23	35
Liver surgery	9	18	29
Symptom	28	37	45
Pain	28	37	53
Co-infection	6	16	36
Paralpegia	0	0	1
Liver lesions	20	26	35
Multiple lesions	22	34	35

Table 2. The surgical treatment of retroperitoneal echinococcosis. *P<0.05, compared to each group, respectively.

	Group A	Group B
n	31	33
Male	15	15
Female	16	18
PRE	4（12.9%）	0
Multiple organ resection※	28（90.3%）	0
Postoperative complications※	4（12.9%）	24（72.7%）
Postoperative symptom relief※	31（100%）	24（72.7%）
Perioperative mortality	0	0
Relapse / progress※	6（19.4%）	26（78.8%）
1-year Survival Rate※	100%	93.9%（
3-year Survival Rate※	100%	75.8%
5-year Survival Rate※	96.8%	51.5%
Average hospitalization day※	12	16

Discussion

RE is normally diagnosed by considering life history, clinical characteristics, laboratory findings, and imaging examinations[2, 17]. In this study, 109 patients had contact or a life history of echinococcosis in the epidemic area; the disease affected all ages. Our analyses showed that the liver was the most susceptible organ (affecting 81/109 cases, 74.3% of the study population); all patients had varying degrees of abdominal pain or bloating and one case in the non-surgical group had serious complications of paraplegia. Because the liver is the main organ involved in echinococcosis, only the treatment principles for hepatic echinococcosis have been established in the existing literature. Thus, the treatment selected is determined according to whether the lesion can be resected, including multidisciplinary imaging assessments, consideration of the general condition of the patient, and the technical capabilities of the surgical team[15, 16]. In this study, the short- and long-term survival rates of the surgical group were significantly higher than those of the non-surgical treatment group; this clearly demonstrated the importance of surgical treatment. Radical resection is the gold standard for treating echinococcosis[4], although non-radical surgery can reduce symptoms, reduce the risk of body damage, improve organ function and the quality of life, and prolong the survival period. For patients with severe symptoms, or complications in the later stages, non-radical surgery may also be considered[12]. In our center, according to the treatment principles of HE, the patient is hospitalized for a detailed assessment of the lesion and

his or her systemic condition. If the lesion is limited and can be completely removed, and the patient can withstand surgery, radical resection is preferred. If the lesion causes serious complications, reduces the quality of life, and is life-threatening, but the lesion involves important organs, then non-radical surgery is selected. After strict preoperative evaluation, we found that the perioperative mortality rate of both groups of patients was 0. There was a significantly better symptom remission rate in Group A (31 / 31,100%) than Group B (24 / 33,72.7%) ($P < 0.05$). During long-term follow-up, the recurrence rate of postoperative lesions in Group A was 19.4%, while that of Group B was 78.8%. These data showed that regardless of whether radical resection or non-radical resection was carried out, as long as we carried out rigorous preoperative evaluation and the operation was performed safely and effectively, then non-radical has a significant effect on relieving symptoms and improving the quality of life. Although it is important to consider the importance and necessity of radical resection, non-radical resection is the preferred choice for patients who cannot tolerate surgery and have multiple lesions that cannot undergo radical resection. These patients have no choice but to take medical treatment (Albendazole 15–20 mg/kg/d) [1]. If patients with infections in the lesions form a pus cavity, then it is possible to relieve symptoms by puncture and drainage[11], but because of the multiple lesions and the specific location of the RE lesions, the surgical difficulty can increase and the clinical effect is poor.

Due to anatomical reasons, the onset of RE is hidden; the disease also occurs in a deep location and often involves multiple important organs. Furthermore, the lesions are easy to spread and often occur as multiple lesions (surgical group: 55/64 cases; non-surgical group: 53/53 cases). Therefore, RE can be easily misdiagnosed, carries a high surgical risk, and is extremely difficult to manage. With regards to radical lesion resection, we observed 28 cases that involved combined organ resection (e.g., the liver, adrenal glands, kidneys, blood vessels) in Group A. We also found that the postoperative complication rate, postoperative lesion recurrence or progression rate, and the and mean length of hospitalization were significantly lower in Group A than in Group B. The short- and long-term survival rates were significantly higher in the radical resection group than the non-radical surgery group. Symptoms, including pain, were significantly relieved after the radical resection of lesions, although 63.6% of patients in Group B also experienced symptom relief, thus indicating that surgery can be of benefit to most patients irrespective of whether the form of surgery adopted was radical or non-radical.

The lesions associated with echinococcosis can metastasize to distant tissues and organs through direct invasion, the lymphatic vessels, and via blood vessels[4]; Secondary retroperitoneal echinococcosis is more common, although primary retroperitoneal echinococcosis is rare[13]. In this study, only four cases were diagnosed with PRE; cystic echinococcosis was more common. These findings were therefore consistent with the existing literature. Thirty-six cases in the surgical group and 35 cases in the non-surgical group had a history of one or more surgical interventions. Of these in the 27 cases and 29 cases had undergone excision of HE lesions. The liver is the most likely organ to be invaded by hydatid lesions. In a previous study, Lim[14] reported the lack of fascia tissue between the bare area of the right lobe of the liver and the right kidney when examined at autopsy, thus, indicating that the liver and the retroperitoneal space were connected. Our retrospective analysis showed that 16 cases in Group A and 28 cases in

Group B had liver surgery; some cases had experienced an initial round of surgical resection for their liver lesions only for this to be followed by the appearance of RE several years after surgery (Fig. 3). This suggests that opening the naked area on the right liver lobe during the first round of surgery caused the lesion to spread along the retroperitoneal loose space, thus leading to the occurrence of RE; this might be the main factor responsible for the higher incidence of SRE than PRE. Therefore, we believe that it is very important that in the first round of surgery, especially in cases involving the right liver lobe, surgeons protect the operation area to avoid the spread of cystic fluid and to avoid radical resection of the lesion. We believe that his practice could prevent the recurrence of RE lesions.

Conclusions

This study has some limitations that need to be considered. First, the incidence of RE is low. Consequently, because our study was carried out in a single-center, the number of RE cases was low. However, we were able to summarize the treatment process for RE (Fig. 4). We hope that our findings and recommendations can help facilitate the future treatment of RE. We aim to verify and expand our findings in the future by conducting multi-center and large-scale studies.

Abbreviations

CE:Cystic echinococcosis; AE:Alveolar echinococcosis; NTDs:Neglected tropical diseases; NZDs:Neglected zoonotic diseases; WHO:World Health Organization; RE:Retroperitoneal echinococcosis; HE:Hepatic echinococcosis; PRE:primary retroperitoneal echinococcosis; SRE:secondary retroperitoneal echinococcosis; CT:Computed tomography; MRI:magnetic resonance imaging.

Declarations

Ethics approval and consent to participate

This study was approved by the Ethics Committee of West China Hospital of Sichuan University (No. 2017–38) and was performed in accordance with the Declaration of Helsinki.All patients and their families signed informed consent and surgical consent before surgery. Patient signed publicly issued consent form (name, ID number and address cannot be provided; gender, age and clinical data are available).

Consent for publication

Written informed consent was obtained from the patients and/or their legal guardians for publication, and any accompanying images, sex, age of these patients.

Availability of data and materials

The datasets used and/or analysed during the current study are available from the corresponding author on reasonable request.

Competing interests

The authors declare that they have no competing interests.

Funding

This research was supported by the Science and Technology Program of Sichuan Science and Technology Department (No. 2019YFS0029, 2019YFS0529), the National Natural Science Foundation of China (No. 81770566) and the New Medical Technology Foundation of West China Hospital of Sichuan University (No. XJS2016004). Corresponding author WWT is the guarantor. The funding body financed the costs of the study and contributed to the design of the study, interpretation of data, and revising the manuscript.

Authors' contributions

HJY, YC and QYW collected and performed the data analysis and contributed to the writing of the manuscript. HJY and YC performed the literature search and statistical analyses.HJY and WWT, interpretation of data, contributed to the discussion and final approval of the manuscript. All authors have read and approved the final version of the manuscript.

Acknowledgments

We thank International Science Editing (http://www.internationalscienceediting.com) for editing this manuscript.

References

1. Wen H, Vuitton L, Tuxun T, et al. Echinococcosis: Advances in the 21st Century.Clin Microbiol Rev.2019; 32(2):e00075-18. https://doi.org/1128/CMR.00075-18.
2. Brunetti E, Kern P, Vuitton DA, et al. Expert consensus for the diagnosis and treatment of cystic and alveolar echinococcosis in humans. Acta Trop.2010;114(1):1-16. https://doi.org/10.1016/j.actatropica.2009.11.001.
3. Stancu B, Andercou O, Pintea D,et al.Laparoscopic simultaneous partial pericystectomy and total cystectomy for hydatid liver cysts - case report. Clujul Med. 2015;88(3):415-419. https://doi.org/15386/cjmed-416.
4. Kern P, Menezes da Silva A, Akhan O, et al. The Echinococcoses:Diagnosis, Clinical Management and Burden of Disease. Adv Parasitol. 2017; 96:259-369. https://doi.org/10.1016/bs.apar.2016.09.006.
5. BudkeCM, Casulli A, Kern P, et al. Cystic and alveolar echinococcosis: Successes and continuing challenges. PLOS Neglected TropicalDiseases. 2017;11(4).

https://doi.org/1371/journal.pntd.0005477.

6. Kawamura N,Kamiyama T,Sato N,et al.Long-term results of hepatectomy for patients with alveolar echinococcosis: a single-center experience.J Am Coll Surg. 20ll,212(5):804-812. https://doi.org/1016/j.jamcollsurg.2011.02.007.
7. KammererWS, Schantz Echinococcal disease, Infect Dis Clin. 1993;7(3):605–618.
8. OzturkS, Unver M, Kibar Ozturk B, et al. Isolated retroperitoneal hydatid cyst invading splenic hilum. Case Rep Surg.2014: https://doi.org/10.1155/2014/303401.
9. Zhao Q, Luo J, Zhang Q,et al. Laparoscopic surgery for primary ovarian and retroperitoneal hydatid disease: A case report. Medicine (Baltimore) .2018;97(3):e9667. https://doi.org/10.1097/MD.0000000000009667.
10. CraigPS, McManus DP, LightowlersMW, et al. Prevention and control of cystic echinococcosis. Lancet Infectious Diseases. 2007; 7(6):385-394. https://doi.org/10.1016/S1473-3099(07)70134-2.
11. Bresson-Hadni S, Delabrousse E, Blagosklonov O,et a1Imaging aspects and non-surgical interventional treatment in human alveolar echinococcosis. Parasitol Int.2006;55(Suppl:S267-272). https://doi.org/10.1016/j.parint.2005.11.053.
12. Ran B, Shao Y, Yimiti Y,et a1.Surgical Procedure Choice for Removing Hepatic Cysts of Echinococcus granulosus in Children.Eur J Pediatr Surg. 2016;26(4):363-367. https://doi.org/10.1055/s-0035-1554806.
13. Guler I, Kivrak HY, Tolu IPrimary Retroperitoneal Hydatid Cyst. Am J Med Sci. 2015;350(6). https://doi.org/10.1097/MAJ.0000000000000494.
14. Lim JH,Yoon Y,Lee SWet a1Superior aspect of the perirenal spaceanatomy and pathological correlationClin Radiol.1988;39(4):368. https://doi.org/10.1016/s0009-9260(88)80269-1.
15. Vuitton DA, Azizi A, Richou C, et a1. Current interventional strategy for the treatment of hepatic alveolar echinococcosis. Expert Rev anti Infect Ther. 2016;14(12):1179-1194. https://doi.org/10.1080/14787210.2016.1240030.
16. Kadry Z, Renner EC, Bachmann LM,et al. Evaluation of treatment and long-term follow-up in patients with hepatic alveolar echinococcosis. Br J Surg.2005;92(9). https://doi.org/10.1002/bjs.4998.
17. Rajiah P, Sinha R, Cuevas C,et al. Imaging of uncommon retroperitoneal masses. Radiographics.2011; 31(4):949-76. https://doi.org/10.1148/rg.314095132.
18. Jerraya H, Nouira R, Dziri C.Giant primary hydatid cyst of retroperitoneum.ANZ J Surg.2018;88(6). https://doi.org/10.1111/ans.13449.
19. Guler I, Kivrak HY, Tolu I. Primary Retroperitoneal Hydatid Cyst. The American Journal of the Medical Sciences.2015;350(6),e6. https://doi.org/10.1097/MAJ.0000000000000494.
20. Joliat GRMelloul EPetermann Det a1Outcomes After Liver Resection for Hepatic Alveolar EchinococcosisA Single-Center Cohort Study. World J Surg.2015;39(10):2529-2534. https://doi.org/10.1007s00268-015-3109-2

Figures

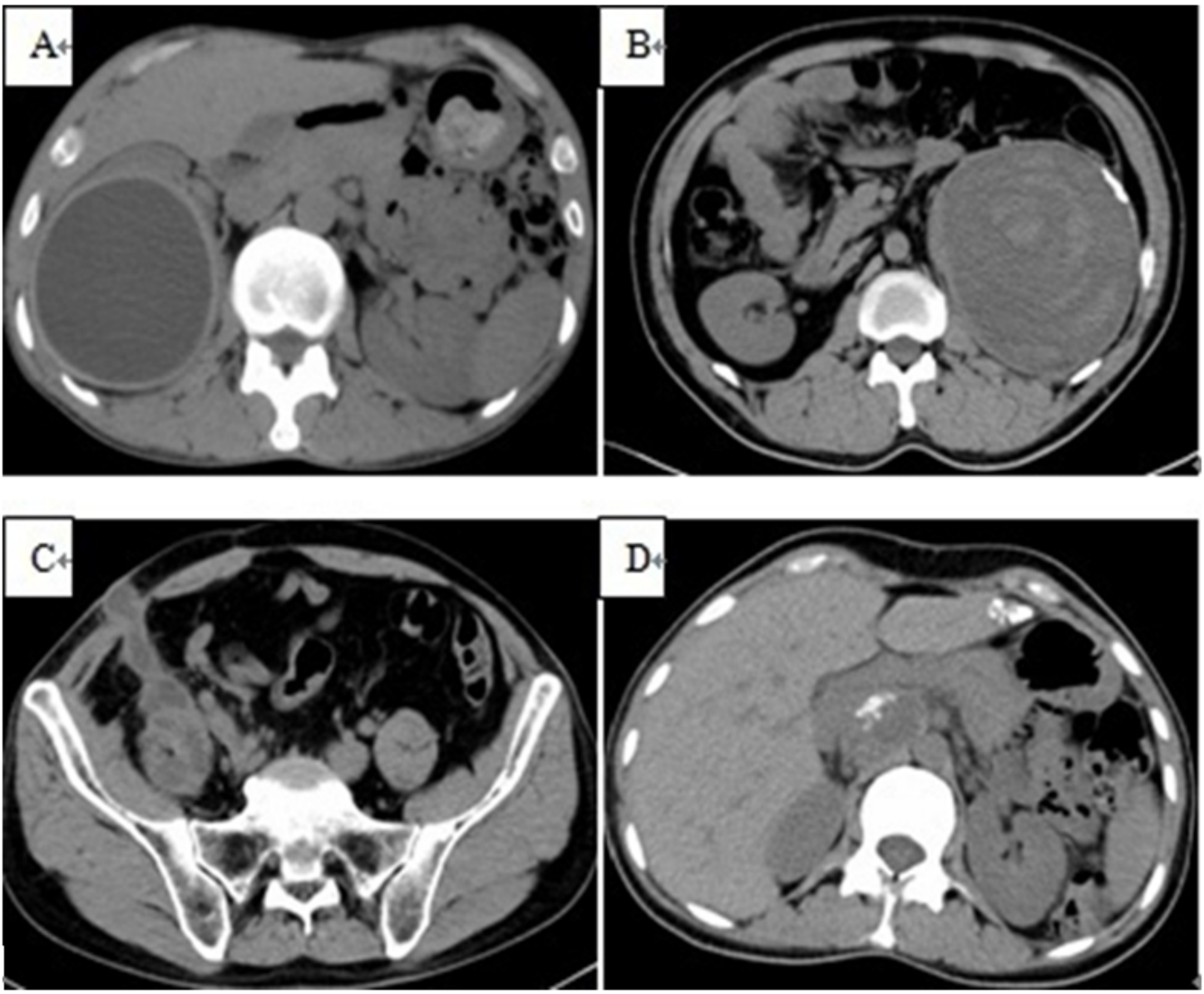

Figure 1

Radical or combined organ resection.

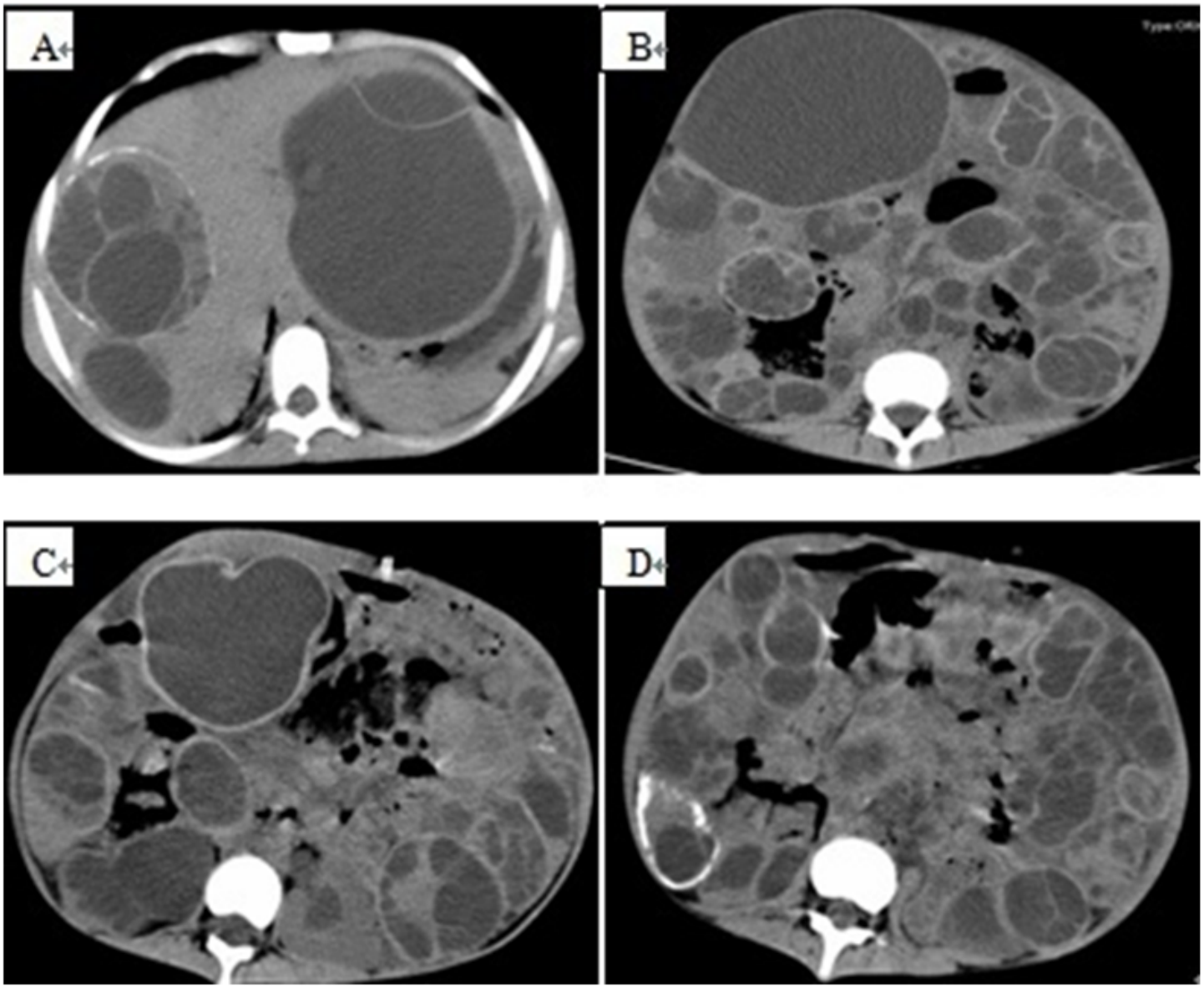

Figure 2

Computed tomography (CT) findings of multiple hydatid lesions in the abdominal cavity and retroperitoneum for palliative surgery.

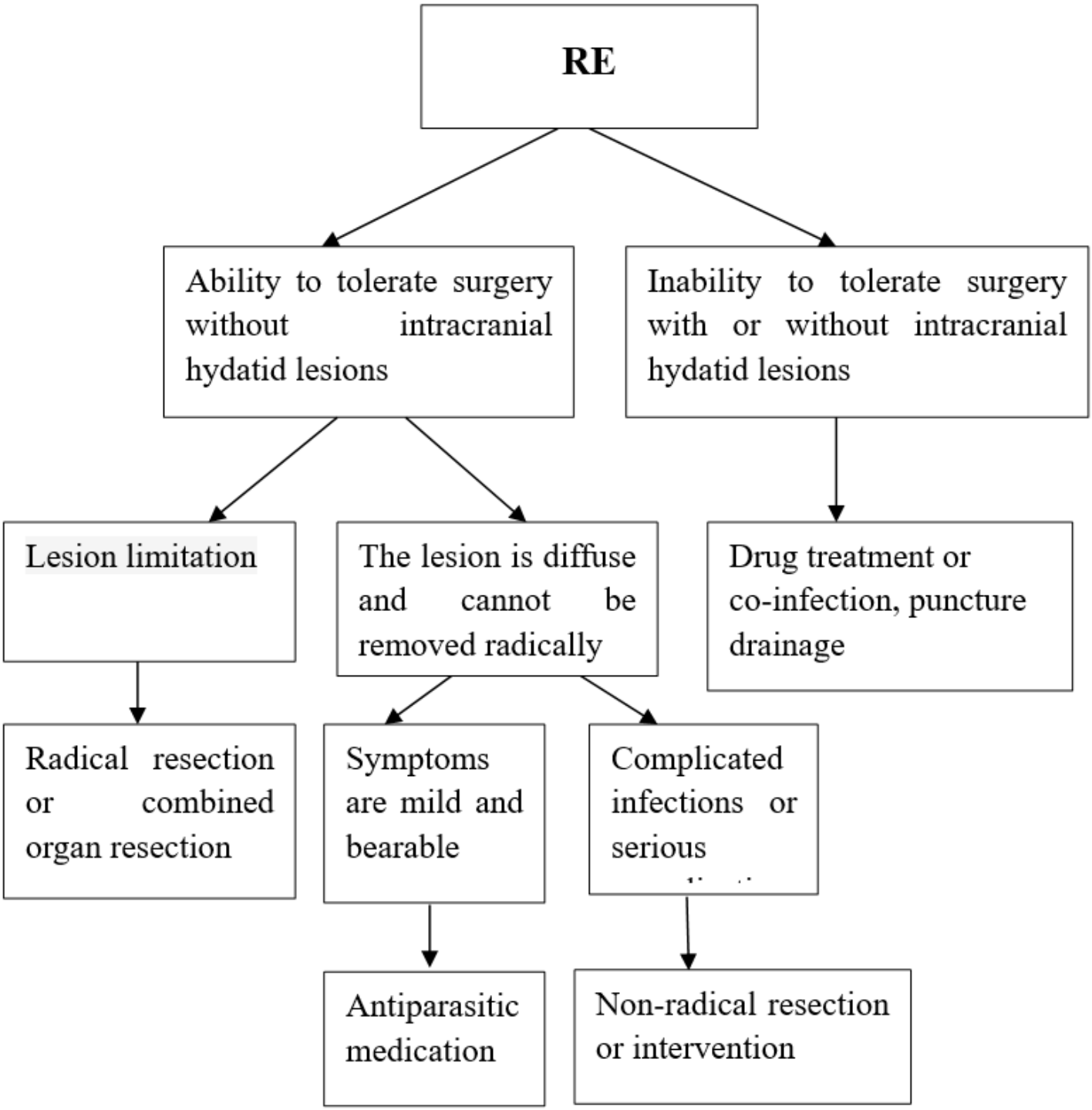

Figure 3

(A, B) Computed tomography (CT) scanning on 6th August 2013. (C, D) CT scanning on 24th March 2019. (E). Intraoperative image taken on 25th March 2019.

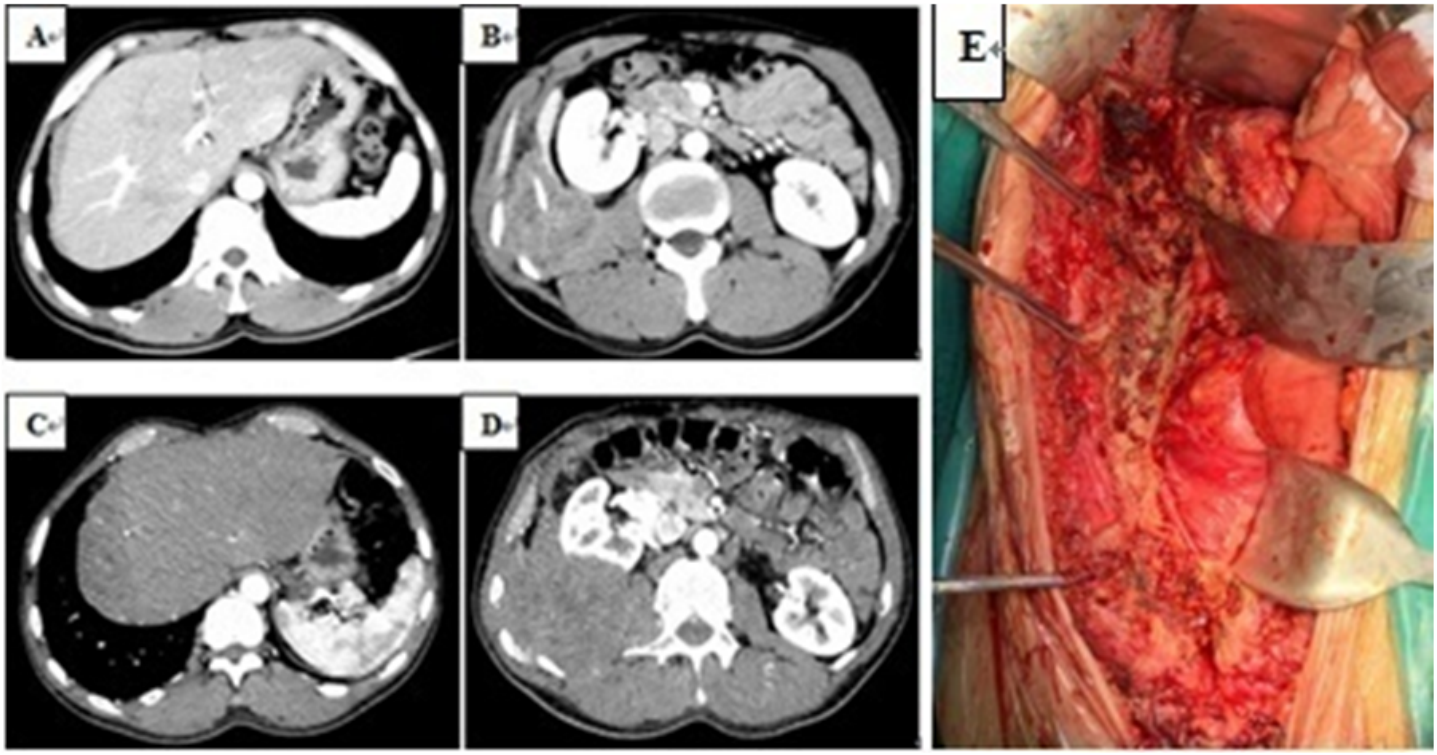

Figure 4

Treatment process for retroperitoneal echinococcosis(RE)