Efficacy and safety of ultrasound-guided percutaneous laser ablation in the treatment of unifocal papillary thyroid microcarcinoma

Feng Zhou
the Affiliated Suzhou Science & Technology Town Hospital of Nanjing Medical University

Zepeng Yu (yuzepengdoctor@163.com)
the Affiliated Suzhou Hospital of Nanjing Medical University https://orcid.org/0000-0003-4949-0699

Xingwei Sun
the Second Affiliated Hospital of Soochow University

Qin Wu
the Affiliated Suzhou Science & Technology Town Hospital of Nanjing Medical University

Kun Zheng
the Affiliated Suzhou Science & Technology Town Hospital of Nanjing Medical University

Shigang Qiao
the Affiliated Suzhou Science & Technology Town Hospital of Nanjing Medical University

Xing Fan
the Affiliated Suzhou Science & Technology Town Hospital of Nanjing Medical University

Jun Gu
the Affiliated Suzhou Hospital of Nanjing Medical University

Research Article

Keywords: papillary thyroid microcarcinoma, Percutaneous laser ablation, Ultrasound, Efficacy, Safety

Posted Date: August 30th, 2022

DOI: https://doi.org/10.21203/rs.3.rs-260933/v2

Abstract

Abstract

Objective Ultrasound-guided percutaneous laser ablation (US-PLA), as a minimally invasive ablation method, has been widely used in the treatment of benign and malignant tumors. The objective of the current study is to determine the efficacy and safety of US-PLA for unifocal papillary thyroid microcarcinoma (PTMC).

Methods 18 patients with pathologically confirmed PTMC underwent US-PLA at our institution. Tumor location, tumor volume and thyroid function were evaluated before PLA. Contrast-enhanced ultrasound (CEUS) was performed immediately after PLA treatment. Complications, thyroid function, ablation area size and volume, tumor recurrence rate and metastasis rate were recorded. The ablation zone size was also compared with the original tumor size before ablation at each follow-up time point.

Results 18 nodules were completely ablated in 18 patients, and postoperative CEUS showed no contrast fill in the ablated areas. 15 patients underwent single needle and single PLA ablation, and 3 cases underwent a second ablation due to incomplete ablation as confirmed by CEUS. All patients tolerated and completed ablation. No serious complications occurred. The maximum diameter and volume of the ablation zone at 6, 12, 18, and 24 months after PLA were significantly smaller than the preoperative nodules. The number of tumors that completely disappeared at 6, 12, 18, and 24 months was 1 (5.56%), 6 (38.89%), 4 (61.11%), and 2 (72.22%), respectively. No local tumor recurrence, lymph node metastasis and distant metastasis occurred.

Conclusion US-PLA is a safe and effective treatment that may provide a new treatment option for patients with PTMC.

Background

In recent years, with the strengthening of the concept of medical examination and the wider clinical application of high-resolution ultrasound, thyroid nodules have become a common disease, and their incidence and detection rate are on the rise year by year[1]. Currently, the detection rate of thyroid nodules has reached 20%-76%, and 5%-13% are malignant tumors[2]. Among them, papillary thyroid carcinoma (PTC) is the most common subtype of thyroid cancer, and papillary thyroid microcarcinoma (PTMC) refers to PTC with a diameter of ≦10 mm. With the promotion of ultrasound-guided fine needle aspiration biopsy (US-FNAB), its detection rate has increased significantly[3].

To date, surgical resection has been the classic and dominant treatment for PTMC. However, with the clinical practice and continuous exploration in recent years, many scholars believe that total lobectomy for PTMC is unnecessary and will lead to lifelong medication replacement[4, 5]. Surgical procedures for

PTMC require general anesthesia and leave a postoperative scar of about 4-6 cm in the neck, which discourages some patients who cannot tolerate surgery and have aesthetic requirements. In fact, PTMC has a "mild" biological behavior, slow growth, and is usually associated with a good prognosis and low mortality, and its diagnosis and treatment strategy and method selection have become a hot topic of debate among domestic and international experts[4, 6].

Ito et al[7] followed up 340 patients with confirmed PTMC and found that 84.1% of them did not have an increase in tumor size during 5 to 10 years of follow-up, and the effect on survival was not statistically significant. Also, none of the 1235 patients with low-risk PTMC they chose to observe without immediate surgery developed distant metastases or died from PTMC during the observation period of 1.5 to 19 years, so they concluded that using follow-up observation rather than immediate surgery for these low-risk PTMCs is also a good choice. However, patients with suspicious nodules often feel anxious after biopsy confirmation of PTMC, which seriously affects patients' quality of life. Therefore, some patients with PTMC prefer to undergo minimally invasive ablation first to actively manage the tumor lesions and then receive regular follow-up observation. In a meta-analysis of 12 studies (1284 nodules in a total of 1187 PTMC patients treated with thermal ablation) by Tong et al[8], all three ablation modalities (radiofrequency, microwave, and laser ablation) resulted in a significant reduction in tumor volume in PTMC. In this study, no distant metastases occurred during the follow-up period (mean 7.8 months), and few major complications were encountered in terms of safety. A systematic evaluation of 503 low-risk PTMC nodes in 470 patients treated by thermal ablation was performed by Cho et al[9]: no patient developed local tumor recurrence or distant metastases, even though two patients (0.4%) developed lymph node metastases, one patient (0.2%) who developed a new PTMC, but all could be successfully treated by another ablation; five patients (1.1%) underwent delayed surgery after ablation, including two patients with lymph node metastasis and three patients with unknown etiology, and even if surgery was performed after ablation, it did not cause any impact on the procedure itself or survival. Therefore, more and more scholars believe that thermal ablation for PTMC has the advantages of precise operation, small trauma, high safety, rapid recovery and precise efficacy, and it has developed into one of the most promising minimally invasive treatment methods.

Ultrasound-guided percutaneous laser ablation (US-PLA) is a minimally invasive interventional method that has been successfully applied in the treatment of benign thyroid nodules in recent years, and it exhibits considerable clinical efficacy[10, 11]. PLA is similar to radiofrequency ablation (RFA) in that it causes irreversible coagulative necrosis of the tissue by generating high temperature to the local tissue. Compared with RFA and microwave ablation (MWA), PLA has unique advantages in the treatment of cervical diseases adjacent to vital organs due to its small laser fiber needle and precise and controllable output energy[12, 13].Some scholars have applied PLA as an alternative surgical treatment to some PTMCs, finding that PLA could effectively kill PTMC without recurrence[14]. Other studies also supported the application of PLA in the treatment of TMC cervical lymphatic metastases[15, 16]. However, overall, studies of US-PLA for PTMC are still in the initial stage.

The purpose of this study is to investigate the safety and efficacy of US-PLA in the treatment of PTMC, and to provide a clinical basis for early intervention in patients with PTMCs.

Methods

Patients

From January 2017 to June 2020, 18 patients with solitary PTMC were included. The demographic and clinical characteristics information of patient is summarized in Table 1. There were 6 men and 12 women, aged between 23 and 58 years old (mean age 40.0 ± 9.5). The present study has been approved by our hospital ethics committee. A written informed consent document was obtained from all patients before the procedure. Inclusion criteria for patients included patients with: (1) PTMC confirmed by fine-needle aspiration biopsy (FNAB); (2) A single tumor with a maximum diameter of less than or equal to 10 mm; (3) A tumor without contact or invasion of the thyroid capsule; (4) Normal cardiopulmonary function; (5) Normal blood tests, such as routine blood and coagulation function; (6) No cervical or distant lymph node metastasis; and (7) Patients who cannot tolerate or refuse surgical treatment. Exclusion criteria were as follows: (1) Patients with multiple nodules, or nodules larger than 10 mm in diameter; (2) Patients with lymph node metastasis or distant metastasis; (3) Patients with tumors that invaded the thyroid capsule or important organs; (4) Patients with severe cardiopulmonary dysfunction; (5) Patients treated with thyroid surgery or radioiodine treatment;6abnormal contralateral vocal cord function; and (7) Patients without complete follow-up information.

Pre-PLA observation

The tumor locations, diameters, volumes and ultrasonographic characteristics were evaluated by ultrasonography (TOSHIBA Apli0500 Ultrasound Instrument, High Frequency Linear Array Probe, frequency of 10 MHz). Blood tests included serum thyroid stimulating hormone (TSH), free triiodothyronine (FT3), free tetraiodothyronine (FT4), thyroglobulin (TG), anti-TG antibody, and routine blood and coagulation function. The tumor volume was calculated as follows: $V = \pi \cdot a \cdot b \cdot c/6$ (where V is the volume, a is the maximum diameter, and b and c are the other maximum vertical diameters).

PLA method

The patient was in a supine position, and the neck was fully exposed. Ultrasound-guided local anesthesia with 2% lidocaine was used after routine disinfection and towel laying. A 21G guided needle was then fixed in the center of the nodule. Then, a needle core was inserted with optical fibers, and the guided needle was retreated 5 mm to the tip of the optical fibers to contact the nodule directly. The laser ablation system was switched on for continuous ablation. Radiofrequency power was ablated from 4 to 6 W, and a single-point and constant ablation was performed until the high echo in the ablation area completely covered the proposed range. The ablation focus was at least 0.1 cm above the edge of the nodule (Figure 1B/ 2B). If the patient did not feel any obvious discomfort, the power could be increased slowly. A volume of 20 ml of hydro dissection solution could be used to avoid thermal damage if tumors were found to be

close to the recurrent laryngeal nerve (RLN), common carotid artery or jugular vein. If patients felt obvious pain or discomfort during ablation, power was reduced or the ablation was suspended. The ablation should be ceased when nodules were completely covered by strong echoes. Contrast-enhanced ultrasonography (CEUS) was performed 5 minutes after ablation (Figure 1C/ 2C). Additional ablation was feasible if nodular enhancement signals were still present in the ablation area. Throughout the procedure, we intermittently asked patients how they felt so as to assess pain levels and vocal status. After the procedure, the puncture area was covered with ice and compressed for 30 minutes and patients were observed in the hospital for 24 hours.

Post-PLA observation and follow-up

Complications and tumor volumes were recorded. Patients were followed at 1, 3, 6, 12, 18, and 24 months and every six months thereafter following PLA. Laboratory tests and ultrasonography were performed at each follow-up visit. The lesion size, blood supply and necrosis were observed via ultrasound or CEUS. US-FNAB was performed if suspected metastatic lymph nodes and suspected lesions in thyroid parenchyma were found. Laboratory tests including serum TSH, FT3, FT4, TG and anti-TG antibody. The volume reduction ratio (VRR) was calculated using the following equation: VRR = ([initial volume - final volume]/initial volume) × 100%[17].

Statistical analysis

Statistical analysis was carried out using SPSS 19.0 (Chicago, IL, USA) and quantitative variables were reported as the mean±standard deviation (SD). A matched t-test was performed on the volume and maximum diameter at different follow-up time points. P values <0.05 were considered to indicate statistical significance.

Results

General characteristics of PTMC Patients

From January 2017 to June 2020, 18 patients with single PTMC lesions treated by US-PLA in our department were enrolled in this study. These patients included 13 women and 5 men with a mean age of 40.0 ± 9.5 years (range, 23-58 years). Of the 18 lesions, 10 were located on the left side and 8 on the right side. The mean maximum lesion diameter was 7.4 ± 1.8 mm (range, 4.5-9.4 mm), and the mean lesion volume was 101.8 ± 64.1 mm3 (range, 20.5-210.2 mm3). No thyroid hormone abnormalities were detected in all patients preoperatively, and the active time during PLA was 283.3±115.4 s (range, 159-522 s). In addition, 15 of the 18 patients underwent single needle and single PLA ablation, and 3 cases underwent a second ablation due to incomplete ablation as confirmed by CEUS (Table 1).

Complications and prognosis

During the PLA procedure, all patients (100%) felt self-limited neck swelling to some extent. 15 patients (83.3%) experienced varying degrees of neck pain and burning during the procedure, and 14 patients were able to tolerate the entire procedure. Once the ablation procedure was completed, the pain decreased or disappeared, with only 1 patient receiving a 5.0 mg intramuscular dezocine injection. 1 patient (5.56%) developed cough and fever on day 7 after PLA, which resolved with symptomatic treatment. There were no cases of neck hematoma, surgical area infection and injury to vital organs such as the trachea or esophagus during surgery. However, a 33-year-old woman was found to have hypothyroidism 1 month after PLA surgery, and her thyroid hormone levels recovered the next month without the administration of medication. A 55-year-old woman who developed hoarseness after the procedure returned to normal 2 months after the ablation procedure without any specific treatment. None of these complications were life-threatening and did not lead to some sequelae. No cervical lymph node metastasis or distant metastasis of these patients was found during the ensuing follow-up (Table 2).

Measurement of Pre, intra and post-PLA

Preoperative ultrasound revealed a hypoechoic nodule (Figure 1A/ 2A). The entire PLA procedure was performed under real-time ultrasound monitoring, intraoperative ultrasound showed that irregular and hyperechoic gasification areas began to appear around the mass with the release of ablation energy (Figure 1B/ 2B). Comparison with the pre-ablation image was used to assess whether the ablated area covered and surpassed the original lesion. CEUS examination immediately after PLA showed no contrast perfusion in the ablated area, suggesting complete ablation (Figure 1C/ 2C). Six months later, ultrasound showed a hyperechoic nodule in the ablation area (Figure 1D/ 2D). The follow-up time ranged from 24.2 months to 31.1 months, with an average follow-up time of 27.2±2.0 months. During the follow-up period, ultrasound dynamic examination confirmed the disappearance of blood perfusion in the ablation area.

Efficacy of PLA for Reducing PTMC Nodule Volume

The maximum diameter, volume, and VRR of the tumors before and after PLA are shown in Table 3 and Figure 3. The mean volume of the 18 nodules before PLA was 101.8 ± 64.1 mm3, and the maximum diameter and volume of the ablated areas at 1 hour, 1 month, and 3 months after PLA were significantly larger than those of the preoperative nodules because we performed enlarged ablation of all tumor lesions ($P < 0.05$). However, the maximum diameter and volume of the ablated area decreased gradually at 6, 12, 18, and 24 months after PLA, all of which were significantly smaller than the preoperative nodules ($P < 0.05$). At the 6th month after PLA, the VRR started to change from negative to positive values, which may be caused by the charred necrotic tissue being gradually absorbed by the body.

At the final follow-up, 13 cases (72.22%) showed complete disappearance of the ablated lesions on ultrasound and 5 cases (27.8%) retained scar-like changes. The number of tumors that completely disappeared at 6, 12, 18, and 24 months was 1 (5.56%), 6 (38.89%), 4 (61.11%), and 2 (72.22%),

respectively. No local tumor recurrence, lymph node metastasis or distant metastasis occurred. None of the patients experienced death due to PTMC during the follow-up period.

Discussion

Surgical resection has remained the main clinical treatment worldwide in recent decades, despite the increasing incidence of PTMC[18]. However, traditional surgical resection may cause detachment of the thyroid gland, which may inevitably lead to varying degrees of hypothyroidism[19]. Surgical resection for PTMC often leads to excessive resection and a sense of insecurity in patients, which has been controversial for many years[20, 21]. Some scholars believe that total thyroidectomy for PTMC is unnecessary and expanding thyroidectomy does not improve surgical outcomes[22]. Some academics argue that lymph node metastasis did not affect the survival rates of PTMC patients, and preventive lymph node dissection is unnecessary for those PTMC patients without suspected lymph node metastasis[23-25]. Therefore, in the current clinical environment, an effective minimally invasive treatment of PTMC is urgently needed.

PLA was first used in the treatment of hepatic, uterine and adrenal diseases[26-28]. Pacella et al[29] preliminarily verified the efficacy of PLA to treat benign thyroid nodules. US-PLA treatment, which has become a promising minimally invasive treatment for thyroid nodules, offers a series of advantages, including simple operation, minimal invasiveness, stable coagulation range, safety and quick recovery[30]. Døssing et al[31-33] performed PLA 3 times for 16, 30, and 78 patients with benign cold thyroid nodules and he found that the nodular volume reduction ratios 6 months after PLA were 46%, 44%, and 51%, respectively, suggesting that PLA offers excellent tumor reduction effects. In 2010, PLA was recommended as an effective and safe method for thyroid nodules according to the American Society of Clinical Endocrinologists, the Italian Society of Clinical Endocrinology, and the European Thyroid Association[34]. Therefore, the proper application of PLA in the treatment of thyroid diseases meets the needs of development of modern medicine.

In our study, the VRR was -738%, -256%, -92%, 26%, 80%, 94%, and 96% at 1 hour, 1 month, 3 months, 6 months, 12 months, 18 months, and 24 months after PLA, respectively. We performed enlarged ablation to ensure complete ablation of the lesion, so that the volume of the ablated area was significantly larger than the primary lesion at 1 hour, 1 month, and 3 months after PLA. At each follow-up time point after PLA, color doppler ultrasound confirmed the absence of blood flow signal in the ablated area and CEUS confirmed the absence of nodular enhancement signal in the ablated area, indicating that PLA treatment was effective for PTMC. With the absorption of charred necrotic tissue, the area of the ablation zone gradually decreased, and the VRR reached 96% in the second year after PLA. In the study by JI et al[35],37 patients with solitary PTMC treated by PLA had a VSR of 96% in the second year after PLA, which was consistent with our findings. At the final follow-up, 13 cases (72.2%) showed complete disappearance of the ablated lesion on ultrasound and 5 cases (27.8) retained scar-like changes, further confirming the effective ablation of the lesion by PLA. In a meta-analysis of 1187 patients with PTMC[8], complete

disappearance of tumors after ablation was found to be 34% - 91%, which may be related to the size and characteristics of the tumors in different studies and the follow-up period.

In the study by Peng et al[36], a recurrence rate of 2.86% (3/105) was observed in 105 patients with PLA-treated unifocal PTMC lesions at a minimum 5-year follow-up. two patients had metastatic central cervical lymph nodes identified 24 months after PLA and both subsequently underwent open surgical resection. A new PTMC lesion was found 12 months after PLA in 1 patient, and the patient underwent a second laser ablation. No recurrence or lymph node metastasis occurred during the subsequent 3-year follow-up. No significant recurrent lesions or lymph node metastases were observed in any of the other 102 patients. In many other studies, the local recurrence rate after ablation was also no higher than 0.5% [8, 37, 38]. JI et al[35] found that only 2.7% of patients developed cervical lymph node metastases during the follow-up time after PLA treatment. In our study, no patients with local recurrence, lymph node metastasis or distant metastasis were identified during the two-year postoperative follow-up period, similar to the results of zhou et al[39]. Complete and enlarged ablation of the tumor may be beneficial in reducing the local recurrence and metastasis rates of the tumor.

The thyroid gland is adjacent to important structures such as RLN, carotid artery, parathyroid glands, esophagus and trachea, making surgical treatment of thyroid disease risky. PLA seems to have its unique advantages in the treatment of small thyroid lesions close to important structures in the neck. In the study by Valcavi et al[40], 122 patients with benign thyroid nodules were treated with PLA. 1.6% of patients developed delayed laryngeal dysfunction after 6-10 weeks and 3.2% developed abnormal thyroid function. In our study, none of the 18 patients developed serious complications such as RLN, tracheal or esophageal injury after PLA. 1 patient developed cough and fever on day 7 after PLA, unrelated to PLA treatment, which resolved with symptomatic treatment. 1 patient developed hoarseness, which returned to normal on its own 2 months after PLA, probably due to laryngeal nerve compression caused by perinodular edema. 1 patient had hypothyroidism, probably due to excessive ablation, which did not require any clinical treatment and resolved spontaneously after 3 months. In addition, all patients (100%) felt self-limited neck swelling to some extent, which may be related to post-ablation parenchymal edema of the thyroid gland.

Hypothyroidism is a common complication after surgical resection treatment. In the study by Ding et al[41], the incidence of hypothyroidism after surgical resection for PTMC was as high as 75%, because the surgery also removed a large amount of normal thyroid tissue. However, PLA is a minimally invasive treatment that destroys the tumor while preserving the integrity of the thyroid gland to the greatest extent possible, thus significantly reducing the incidence of hypothyroidism after PLA.

During the process of PLA treatment, attention should be paid to the following aspects: (1) Hydrodissection solution should be used when the distance between nodules and vital organs is less than 5 mm. (2) The temperatures of the thyroid and vital organs must be monitored: once the temperature is too high, energy output must be reduced. (3) If the nodule adheres to the trachea or blood vessels, the nodule can be ablated partially. (4) If one side of RLN is injured, the other side of RLN should

be avoided during ablation to avoid asphyxia. Although PLA exhibits considerable clinical efficacy in treating PTMC in the present study, it still must be further improved. (1) More patients and long-term follow-up need to be investigated in the ensuing studies. (2) New imaging techniques, such as computerized three-dimensional stereotaxic technology, could be used to reduce the damage surrounding vital tissues during the PLA process. (3) There are few comparative studies between thermal ablation and surgical resection, which need to be further investigated.

In conclusion, US-PLA for unifocal PTMC is a precise and safe method with good treatment results, minimal trauma and no surgical scars, and can be used as one of the alternatives for clinical treatment of PTMC.

References

[1] HOLT E H. Current Evaluation of Thyroid Nodules [J]. Med Clin North Am, 2021, 105(6): 1017-31.

[2] CHO B Y, CHOI H S, PARK Y J, et al. Changes in the clinicopathological characteristics and outcomes of thyroid cancer in Korea over the past four decades [J]. Thyroid, 2013, 23(7): 797-804.

[3] MIN Y, WANG X, CHEN H, et al. Thermal Ablation for Papillary Thyroid Microcarcinoma: How Far We Have Come? [J]. Cancer Manag Res, 2020, 12(13369-79.

[4] MAURI G, ORSI F, CARRIERO S, et al. Image-Guided Thermal Ablation as an Alternative to Surgery for Papillary Thyroid Microcarcinoma: Preliminary Results of an Italian Experience [J]. Front Endocrinol (Lausanne), 2020, 11(575152.

[5] XU B, ZHOU N M, CAO W T, et al. Comparative study on operative trauma between microwave ablation and surgical treatment for papillary thyroid microcarcinoma [J]. World J Clin Cases, 2018, 6(15): 936-43.

[6] CAO X J, YU M A, ZHU Y L, et al. Ultrasound-guided thermal ablation for papillary thyroid microcarcinoma: a multicenter retrospective study [J]. Int J Hyperthermia, 2021, 38(1): 916-22.

[7] ITO Y, MIYAUCHI A, INOUE H, et al. An observational trial for papillary thyroid microcarcinoma in Japanese patients [J]. World J Surg, 2010, 34(1): 28-35.

[8] TONG M, LI S, LI Y, et al. Efficacy and safety of radiofrequency, microwave and laser ablation for treating papillary thyroid microcarcinoma: a systematic review and meta-analysis [J]. Int J Hyperthermia, 2019, 36(1): 1278-86.

[9] CHO S J, BAEK J H, CHUNG S R, et al. Thermal Ablation for Small Papillary Thyroid Cancer: A Systematic Review [J]. Thyroid, 2019, 29(12): 1774-83.

[10] MAURI G, NICOSIA L, DELLA VIGNA P, et al. Percutaneous laser ablation for benign and malignant thyroid diseases [J]. Ultrasonography (Seoul, Korea), 2019, 38(1): 25-36.

[11] RAHAL JUNIOR A, FALSARELLA P M, MENDES G F, et al. Percutaneous laser ablation of benign thyroid nodules: a one year follow-up study [J]. Einstein (Sao Paulo, Brazil), 2018, 16(4): eAO4279.

[12] CHENG Z, CHE Y, YU S, et al. US-Guided Percutaneous Radiofrequency versus Microwave Ablation for Benign Thyroid Nodules: A Prospective Multicenter Study [J]. Scientific reports, 2017, 7(1): 9554.

[13] MORELLI F, SACRINI A, POMPILI G, et al. Microwave ablation for thyroid nodules: a new string to the bow for percutaneous treatments? [J]. Gland surgery, 2016, 5(6): 553-8.

[14] ZHOU W, ZHANG L, ZHAN W, et al. Percutaneous laser ablation for treatment of locally recurrent papillary thyroid carcinoma <15 mm [J]. Clinical radiology, 2016, 71(12): 1233-9.

[15] MAURI G, COVA L, IERACE T, et al. Treatment of Metastatic Lymph Nodes in the Neck from Papillary Thyroid Carcinoma with Percutaneous Laser Ablation [J]. Cardiovascular and interventional radiology, 2016, 39(7): 1023-30.

[16] MAURI G, COVA L, TONDOLO T, et al. Percutaneous laser ablation of metastatic lymph nodes in the neck from papillary thyroid carcinoma: preliminary results [J]. The Journal of clinical endocrinology and metabolism, 2013, 98(7): E1203-7.

[17] CAO X J, LIU J, ZHU Y L, et al. Efficacy and Safety of Thermal Ablation for Solitary T1bN0M0 Papillary Thyroid Carcinoma: A Multicenter Study [J]. J Clin Endocrinol Metab, 2021, 106(2): e573-e81.

[18] ZHI J, ZHAO J, GAO M, et al. Impact of major different variants of papillary thyroid microcarcinoma on the clinicopathological characteristics: the study of 1041 cases [J]. International journal of clinical oncology, 2018, 23(1): 59-65.

[19] KALISZEWSKI K, DIAKOWSKA D, WOJTCZAK B, et al. The occurrence of and predictive factors for multifocality and bilaterality in patients with papillary thyroid microcarcinoma [J]. Medicine, 2019, 98(19): e15609.

[20] JEON M J, KIM W G, KWON H, et al. Clinical outcomes after delayed thyroid surgery in patients with papillary thyroid microcarcinoma [J]. European journal of endocrinology, 2017, 177(1): 25-31.

[21] XUE S, WANG P, HURST Z A, et al. Active Surveillance for Papillary Thyroid Microcarcinoma: Challenges and Prospects [J]. Frontiers in endocrinology, 2018, 9(736.

[22] XU S, LIU W, ZHANG Z, et al. Routine Prophylactic Central Neck Dissection May Not Obviously Reduce Lateral Neck Recurrence for Papillary Thyroid Microcarcinoma [J]. ORL; journal for oto-rhino-laryngology and its related specialties, 2019, 81(2-3): 73-81.

[23] XU Y, XU L, WANG J. Clinical predictors of lymph node metastasis and survival rate in papillary thyroid microcarcinoma: analysis of 3607 patients at a single institution [J]. The Journal of surgical research, 2018, 221(128-34.

[24] TANG J, LIU H B, YU L, et al. Clinical-pathological Characteristics and Prognostic Factors for Papillary Thyroid Microcarcinoma in the Elderly [J]. Journal of Cancer, 2018, 9(2): 256-62.

[25] WANG X, LEI J, WEI T, et al. Clinicopathological characteristics and recurrence risk of papillary thyroid microcarcinoma in the elderly [J]. Cancer management and research, 2019, 11(2371-7.

[26] CHAI W, ZHAO Q, KONG D, et al. Percutaneous Laser Ablation of Hepatic Tumors Located in the Portacaval Space: Preliminary Results [J]. Lasers in surgery and medicine, 2019,

[27] HINDLEY J T, LAW P A, HICKEY M, et al. Clinical outcomes following percutaneous magnetic resonance image guided laser ablation of symptomatic uterine fibroids [J]. Human reproduction (Oxford, England), 2002, 17(10): 2737-41.

[28] JIANG T, CHAI W. Endoscopic ultrasonography (EUS)-guided laser ablation (LA) of adrenal metastasis from pancreatic adenocarcinoma [J]. Lasers in medical science, 2018, 33(7): 1613-6.

[29] PACELLA C M, BIZZARRI G, SPIEZIA S, et al. Thyroid tissue: US-guided percutaneous laser thermal ablation [J]. Radiology, 2004, 232(1): 272-80.

[30] PACELLA C M, MAURI G, CESAREO R, et al. A comparison of laser with radiofrequency ablation for the treatment of benign thyroid nodules: a propensity score matching analysis [J]. International journal of hyperthermia : the official journal of European Society for Hyperthermic Oncology, North American Hyperthermia Group, 2017, 33(8): 911-9.

[31] DOSSING H, BENNEDBAEK F N, KARSTRUP S, et al. Benign solitary solid cold thyroid nodules: US-guided interstitial laser photocoagulation–initial experience [J]. Radiology, 2002, 225(1): 53-7.

[32] DOSSING H, BENNEDBAEK F N, HEGEDUS L. Long-term outcome following interstitial laser photocoagulation of benign cold thyroid nodules [J]. European journal of endocrinology, 2011, 165(1): 123-8.

[33] DOSSING H, BENNEDBAEK F N, HEGEDUS L. Effect of ultrasound-guided interstitial laser photocoagulation on benign solitary solid cold thyroid nodules - a randomised study [J]. European journal of endocrinology, 2005, 152(3): 341-5.

[34] BAEK J H, LEE J H, VALCAVI R, et al. Thermal ablation for benign thyroid nodules: radiofrequency and laser [J]. Korean journal of radiology, 2011, 12(5): 525-40.

[35] JI L, WU Q, GU J, et al. Ultrasound-guided percutaneous laser ablation for papillary thyroid microcarcinoma: a retrospective analysis of 37 patients [J]. Cancer Imaging, 2019, 19(1): 16.

[36] PENG K, ZHOU P, LIU W. Long-Term Efficacy of Ultrasound-Guided Percutaneous Laser Ablation for Low-Risk Papillary Thyroid Microcarcinoma: A 5-Year Follow-Up Study [J]. Biomed Res Int, 2021, 2021(6616826.

[37] DING M, TANG X, CUI D, et al. Clinical outcomes of ultrasound-guided radiofrequency ablation for the treatment of primary papillary thyroid microcarcinoma [J]. Clin Radiol, 2019, 74(9): 712-7.

[38] WANG L, XU D, YANG Y, et al. Safety and efficacy of ultrasound-guided percutaneous thermal ablation in treating low-risk papillary thyroid microcarcinoma: A pilot and feasibility study [J]. J Cancer Res Ther, 2019, 15(7): 1522-9.

[39] ZHOU W, JIANG S, ZHAN W, et al. Ultrasound-guided percutaneous laser ablation of unifocal T1N0M0 papillary thyroid microcarcinoma: Preliminary results [J]. Eur Radiol, 2017, 27(7): 2934-40.

[40] VALCAVI R, RIGANTI F, BERTANI A, et al. Percutaneous laser ablation of cold benign thyroid nodules: a 3-year follow-up study in 122 patients [J]. Thyroid, 2010, 20(11): 1253-61.

[41] DING B, YU J F, SUN W, et al. Surgical safety analysis of retaining the glands in papillary thyroid microcarcinoma [J]. Eur Rev Med Pharmacol Sci, 2017, 21(2): 234-8.

Tables

Table1.

Patient No.	Sex/Age (years)	Lobar location	Size before PLA (mm)	Serum thyroglobulin before PLA (ng/ml)	PLA ablation time (s)	No. of ablation procedures	Follow-up (months)
1	F/44	L	6.4×2.9×3.5	0.13	159	1	25.5
2	M/39	L	7.8×6.5×4.9	0.17	327	1	25.1
3	M/37	R	9.1×3.3×6.4	0.09	199	1	28.6
4	F/30	L	4.8×3.7×3.8	0.25	245	2	25.4
5	F/53	L	8.7×5.0×4.8	0.16	488	1	28.3
6	F/31	L	5.2×2.8×3.3	0.11	211	1	27.9
7	F/23	R	4.5×3.1×2.8	0.21	349	1	26.5
8	F/40	L	8.4×6.8×6.5	0.13	187	1	24.2
9	F/49	R	6.4×5.6×5.4	0.09	236	1	29.4
10	M/57	R	8.9×5.8×4.9	0.13	190	2	24.5
11	F/37	R	9.4×7.3×5.6	0.14	393	1	31.1
12	M/40	L	9.3×7.1×4.6	0.08	385	1	26.2
13	F/45	R	7.6×3.5×6.8	0.10	416	1	27.1
14	M/32	L	8.5×4.1×2.8	0.19	522	2	29.6
15	F/33	R	9.1×4.4×7.2	0.22	183	1	29.8
16	F/37	L	6.0×4.5×4.0	0.17	166	1	25.4
17	F/35	R	9.4×7.0×6.1	0.12	235	1	26.7
18	M/58	L	4.5×3.9×2.7	0.14	208	1	27.9

Table2.

Complications	No. (%)	Actions Taken
neck swelling	100%（18/18）	None, self-limiting
Pain	83.33%（15/18）	14 patients were well tolerated and 1 patient received 5 mg of dezocine injection
Cough and fever	5.56%（1/18）	Effective symptomatic treatment
hoarseness	5.56%（1/18）	None, self-limiting
Neck hematoma	0%（0/18）	-
Local infection	0%（0/18）	-
Vital organ injury	0%（0/18）	-
Serum hormone abnormalities	5.56%（1/18）	None, self-limiting
local recurrence	0%（0/18）	-
Cervical lymph node metastasis	0%（0/18）	-
Distant metastasis	0%（0/18）	-

Table3.

Time	Maximum diameter (mm)	P-value	Volume (mm^3)	P-value	VRR (%)
Pre-PLA (n=18)	7.4 ± 1.8	-	101.8 ± 64.1	-	-
Post-PLA					
1 hour (n=18)	18.1 ± 3.9	<0.001	1039.5 ± 799.8	<0.001	-737.5 ± 608.6
1 month (n=18)	13.9 ± 4.2	<0.001	754.8 ± 499.7	<0.001	-256.4 ± 126.7
3 months (n=18)	9.4 ± 3.1	<0.001	396.5 ± 221.8	<0.001	-92.4 ± 70.9
6 months (n=17)	5.2 ± 2.5	<0.001	64.3 ± 76.4	<0.01	25.8 ± 20.3
12 months (n=11)	2.1 ± 1.2	<0.001	9.7 ± 7.4	<0.001	80.1 ± 16.4
18 months (n=7)	1.4 ± 0.9	<0.001	6.5 ± 3.1	<0.001	93.5 ± 15.7
24 months (n=5)	1.0 ± 0.5	<0.001	3.2 ± 1.5	<0.001	96.1 ± 11.4

Figures

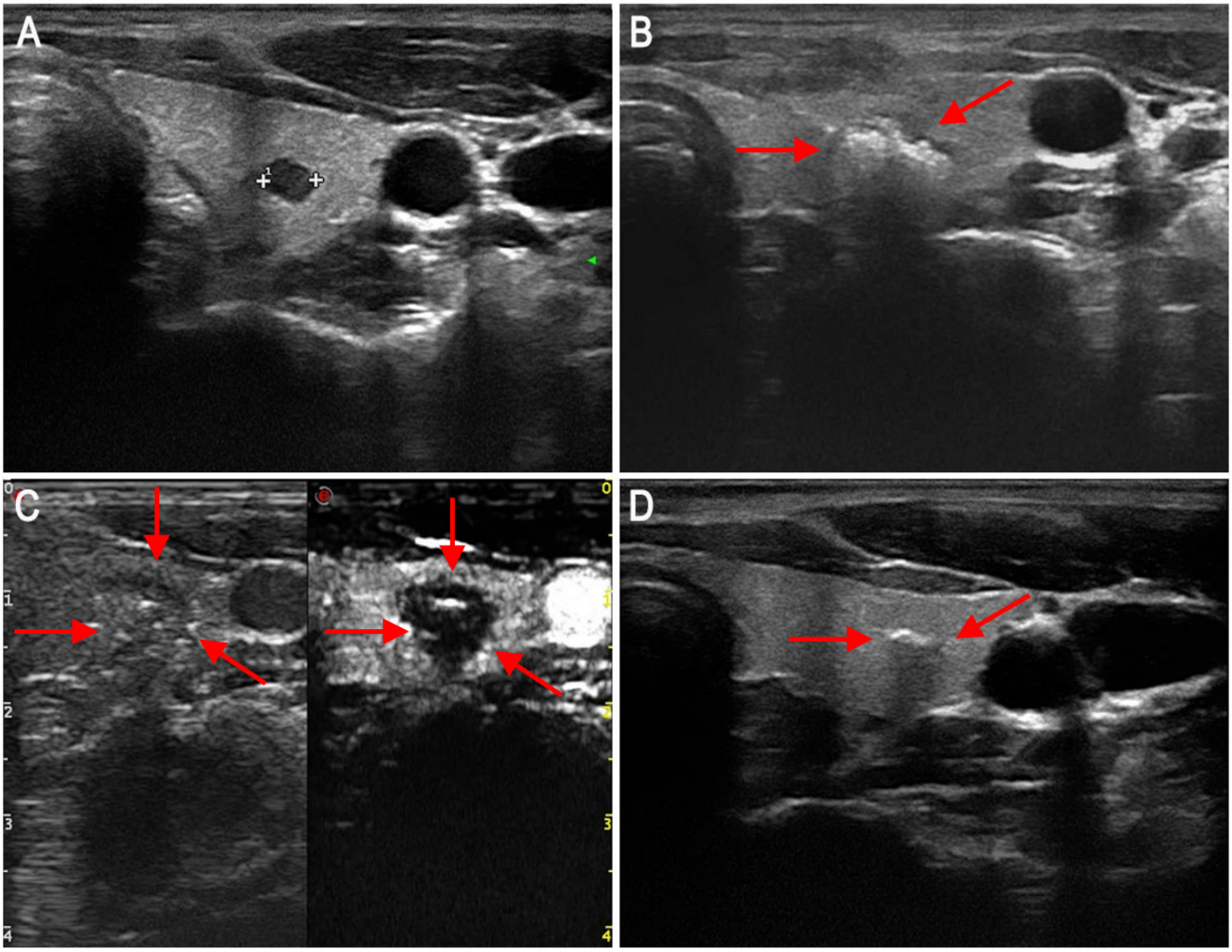

Figure 1

A 31-year-old female (Patient 6) with PTMC on the left side of the neck. A: Preoperative ultrasound showed a hypoechoic nodule with a size of 5.2×2.8×3.3 mm, ultrasound-guided biopsy confirmed the tumor as PTMC. B: Intraoperative ultrasound showed the typical hyperechoic region (red arrow) during ablation. C: Postoperative CEUS shows that the ablation area is larger than the preoperative nodule and there is no contrast filling in the ablation area, suggesting complete ablation. D: Six months later, ultrasound showed a scar like tissue with a size of 4.2×1.2×1.7 mm.

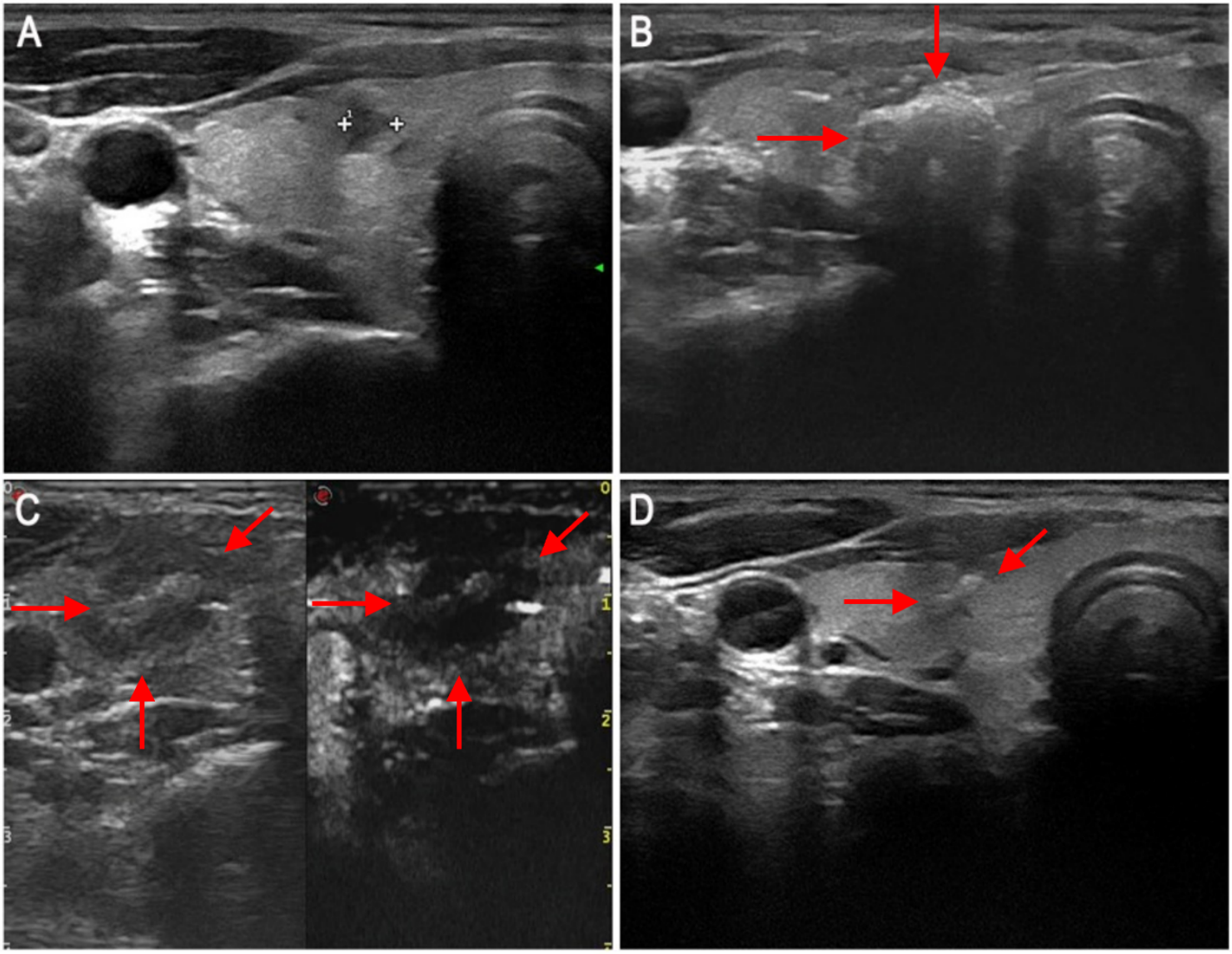

Figure 2

A 23-year-old female (Patient 7) with PTMC on the right side of the neck. A: Preoperative ultrasound showed a hypoechoic nodule with a size of 4.5×3.1×2.8 mm, ultrasound-guided biopsy confirmed the tumor as PTMC. B: Intraoperative ultrasound showed a vaporized area (red arrow) during ablation. C: CEUS showed a vaporized cavity in the ablation area after operation. D: Six months later, ultrasound showed a scar like tissue with a size of 2.1×0.8×1.1 mm.

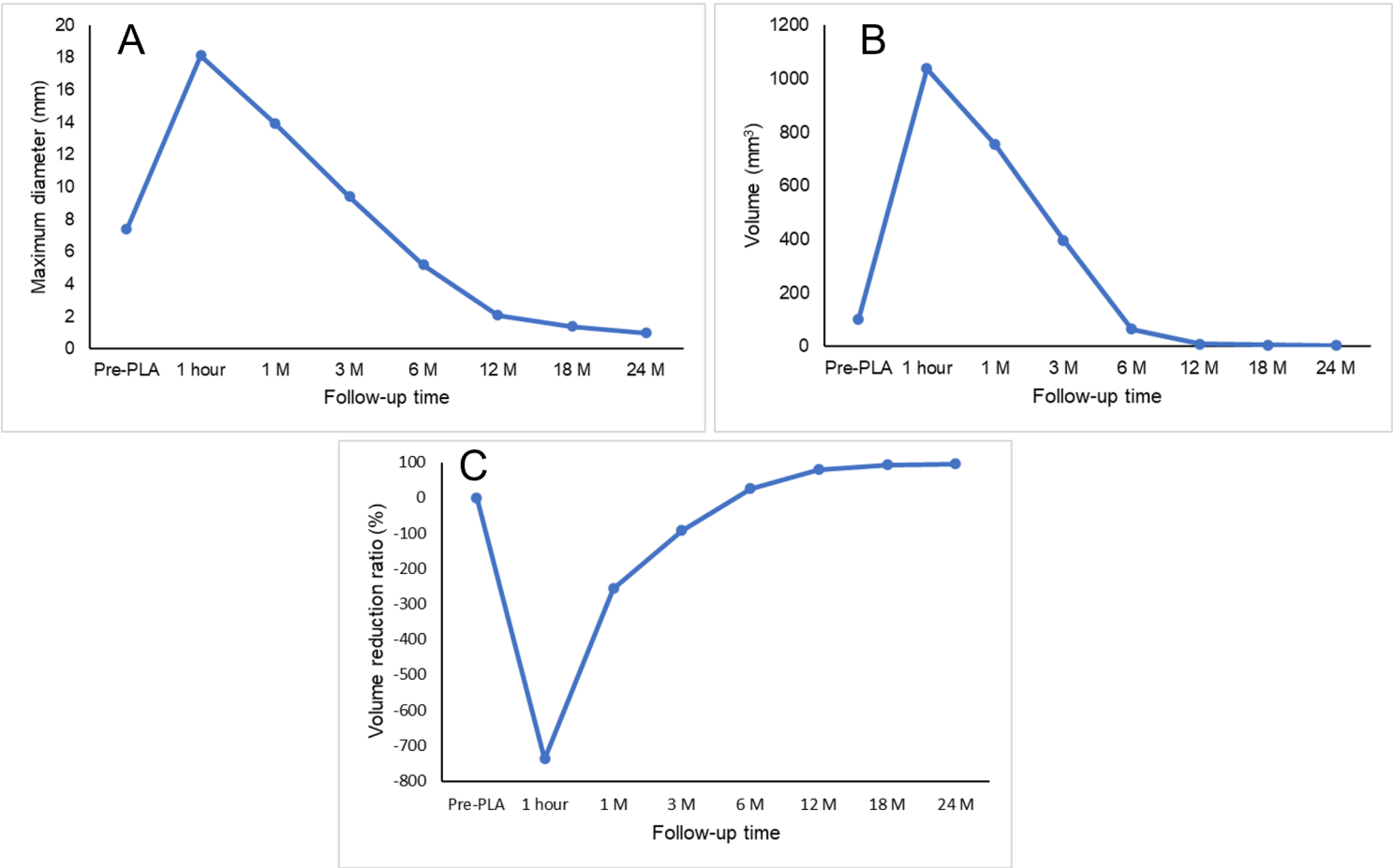

Figure 3

Changes in the maximum diameter (A), volume (B), and volume reduction ratio (C) of the tumors at each follow-up.