Anatomical Basis of the Support of Fibula to Tibial Plateau and Its Clinical Significance

Wen-Bin Jiang
Dalian Medical University
Shi-Zhu Sun
Dalian Medical University
Chan Li
Dalian Medical University
Philip Adds
St George's University of London
Tang Wei
Dalian Medical University
Wei Chen
Hebei Medical University
Sheng-Bo Yu
Dalian Medical University
Hong-Jin Sui (suihj@hotmail.com)
Dalian Medical University

Research Article

Keywords: Tibia plateau, Fibula, Trabeculae bone, Partial fibulectomy, Knee osteoarthritis

Posted Date: March 3rd, 2021

DOI: https://doi.org/10.21203/rs.3.rs-261516/v1

Abstract

Background

Partial fibulectomy always was used to treat knee osteoarthritis. The settlement of the nonuniform proximal tibia plateau is clinically defined as the height of the medial tibial platform was lower than that of the lateral side in the medial compartment knee osteoarthritis (KOA). The reason for the unapparent is caused by fibular support on the lateral side. Orthopedic surgeons practiced partial fibulectomy based on the theory of nonuniform settlement, and the effect of reduce pain and improve function in patients with osteoarthritis was significant. However, this hypothesis of nonuniform settlement is still lacking an anatomical basis.

Methods

The P45 section technique was used to focus the distribution of the bone trabeculae on the tibial-fibular region.

Results

The distribution of the bone trabeculae was uneven in the lateral condyle of the tibia and the head and neck of the fibula. The bone trabeculae with uneven distribution of tibia and fibula in space might form a triangle. The fibula and the posterolateral bone cortex of the shaft of the tibia united to form an arch beam via the tibiofibular joint. In the meantime, a lot of thick and dense trabeculae were present in a longitudinal direction on the tibiofibular arch.

Conclusions

The fibula supports the lateral tibial plateau, but the trabeculae were concentrated on the tibiofibular arch.

Introduction

Knee Osteoarthritis (KOA), a degenerative joint condition, is one of the most prevalent chronic health conditions in the world, which was characterized by synovial membrane inflammation, subchondral bone sclerosis, articular cartilage degradation, and osteophyte formation[1]. The medial compartment of the knee was most commonly affected in those with osteoarthritis and often leads to knee varus deformity. Which the risk factors and their pathogenesis have been a research hotspot in the field of joint surgery in recent years[2, 3]. Wang et al[4] have argued that the changes of the proximal tibial plateau were particularly obvious in the dynamic changes of bones. They found that the height of the medial tibial plateau was lower than that of the lateral plateau in the medial compartment KOA. The difference in height between these two positions was defined as the nonuniform settlement of the proximal tibia plateau. The reason for the nonuniform was presumed fibular support on the posterior lateral wall of the tibia plateau. The construction of tibial plateau would be inclined to accelerate this uneven

phenomenon[3, 5], because the tibial plateau was mainly composed of cancellous bone. The slope of the tibial plateau caused by nonuniform settlement results in a transverse shearing force, with the femoral condyle producing ramping during walking and sports[6]. Besides, many researchers found a phenomenon that the femoral condyle slides medially in the X-ray plain films of patients with medial KOA, which was named a coronal tibial subluxation[7–10]. However, the pathogenesis of the nonuniform settlement is not yet clear[11, 12]. It was universally acknowledged that total knee arthroplasty (TKA) was standard surgery for end-stage degenerative. Before the progression of total arthritis, high tibial osteotomy or unicompartmental arthroplasty was used to solve the problem of medial compartment involvement in knee osteoarthritis to avoid or postpone TKA [5]. Given the risks and high cost inherent with those surgeries, orthopedic surgeons in China practiced partial fibulectomy based on the manifestation of nonuniform settlement, and this simple surgical technique to reduce pain and improve function in patients with osteoarthritis[4]. But, the anatomical study of this theory has not been reported. In the present study, the P45 plastinated section technique was used to reveal the distribution of trabeculae bone of the tibial-fibular region, and then to provide anatomical clues for exploring the mechanism of nonuniform settlement of tibial plateau and the strategy of treating KOA.

Materials And Methods

Materials

In this study, a total of 27 formalin-fixed adult knee joint specimens were studied. All the specimens were from the cadavers used in the teaching of human body dissection at Dalian Medical University. The Dalian Hoffen Biotechnology Co., Ltd., prepared the seriate sagittal, coronal, and horizontal sections of knee joints by the P45 plastination technique. The signs of tumor, congenital malformation, fracture, severe osteoarthritis, and other related diseases couldn't be found in the specimens. Finally, 15 cases of plastinated sagittal sections, 8 cases of plastinated coronal sections, and 4 cases of plastinated horizontal sections were selected.

Methods

P45 plastination technique

[13]

The plastination study of the knee joint has been reported[14]. According to the previous method[14], this paper focuses on observing the relationship between the trabecular distribution of cancellous bone of lateral tibial condyle and fibula.

Result

Oblique sagittal section through the tibiofibular joint (Fig. 1)

The lateral condyle of the femur and tibia and the lateral compartment of the knee joint were found in the section. The tibiofibular joint composed of the fibular head and the lateral condyle of the tibia was showed on the posterolateral side of the tibial plateau. Uneven distribution of bone trabeculae was present in the lateral condyle of the tibia. In the lateral condyle of the tibia, there were mainly longitudinal thick trabeculae clusters beneath the articular surface, while in the anterior part of the lateral condyle of the tibia near the tibial tuberosity, the sparse trabeculae were found to be tiny and reticulate. And in the posterolateral part of the lateral condyle of the tibia, the trabeculae above the tibiofibular joint were still small and sparse. At the level of the metaphysis of the tibia, it was found that an arched construction was formed by the union of the shaft of the fibula and the posterior lateral bone cortex of the shaft of the tibia via the tibiofibular joint. The fibula was acted as the fulcrum of the arch. The longitudinal dense trabeculae passing through the epiphyseal line of the tibia were distributed between the vault of the arch and the articular surface of the lateral tibial plateau. Furthermore, the trabeculae in the fibular head were unevenly arranged in a tiny and sparse.

Coronal section through the tibiofibular joint (Fig. 2)

The sections showed the medial and lateral condyles of the femur, the posterior part of the tibial plateau, and the tibiofibular joint. The distribution of bone trabeculae in the tibial plateau was uneven. In the inferior projection area of the articular surface of the tibial plateau, it was found that the thick and dense bone trabeculae were originated at the articular surface to penetrate the epiphyseal line and then terminated at the bone cortex slope of the posterior wall of the metaphysis of the tibia, and the bone trabeculae in the lateral condyle were slightly denser than those in the medial condyle. The bone cortex was thickened accordingly at the lateral side of the posterior oblique wall of the metaphysis of the tibia. However, in the lateral edge of the lateral condyle, on top of the tibiofibular joint, the trabeculae were tiny and loose, and equally, tiny and sparse bone trabeculae were present in the head of the fibula.

Horizontal section through the neck of the fibula (Fig. 3)

The section showed the structure in the cross-section of the metaphysis of the tibia and the neck of the fibula. The cross-section of the metaphysis of the tibia was triangular, and a large number of dense and reticulated bone trabeculae were found in its three regions, namely areas near the posterior lateral and medial bone cortex of the tibia, and the tibial tuberosity. Similarly, the dense trabeculae were constructed in a reticulate pattern in the posteromedial half area of the neck of the fibula. These areas of dense and reticulated trabeculae in the metaphysis of the tibia and the neck of the fibula were combined by the tibiofibular joint might form a trabecular solid foundation of the knee, namely a situation of tripartite confrontation of trabecular dense areas. However, which tripartite could not be determined.

Discussion

According to the current view, the fibula is indirectly involved in the composition of the knee joint. Therefore, the fibula has been neglected in the research on knee osteoarthritis[4]. In this study, it was found that the uneven distribution of bone trabeculae in the lateral condyle of the tibia and the head and

neck of the fibula. In the lateral condyle of the tibia, a large number of thick bone trabeculae were distributed longitudinally in clusters beneath the articular surface, which penetrated the epiphyseal line and terminated on the slope of the posterior bone cortex of the metaphysis of the tibia. The cortical slope was a stable arch beam constructed by the union of the fibula and the cortex of the posterolateral side of the metaphysis of the tibia via the tibiofibular joint. This gave us a hint that the tibiofibular arch would play an important role in bearing the stress of the lateral compartment of the knee joint. It was also supported that concentrated reticular bone trabeculae were present in the posteromedial half area of the neck of the fibula, which could provide the internal strength for the brace of the fibular head. As a result, the tibiofibular joint was an indispensable fulcrum for the mechanical arch between the tibia and fibula. Furthermore, the thin and sparse bone trabeculae were located above the tibiofibular joint in the posterolateral marginal region of the tibial plateau. Accordingly, the fibula might not directly bear the stress originated from the knee articular surface.

Previous studies have shown that the proximal tibia was mainly comprised of cancellous bone, the bone density of different parts of proximal fibula and tibia decreased in the following order: fibula, medial platypus, lateral platypus, and middle proximal tibia[5]. There was little chance of cortical thickness loss in the proximal fibula with age but was much more significant in the proximal tibia were pointed out by McNeil et al[15]. This means that the fibula was not subject to bone loss. Accordingly, the strength maintaining of fibula could be superior to the tibial plateau. In the present study, it was observed that the mechanical arch beam was formed by the union of the fibula and the tibial plateau and the tibiofibular joint was the constant fulcrum of the arch beam on the posterior lateral side of the tibial plateau. When upright walking or moving, gravity transmitted by the articular surface of the lateral condyle of the tibia could fall on the top of the arch beam. The dense and reticulated trabeculae in the tibia and the fibula might be combined with each other by the tibiofibular joint to form a situation of tripartite confrontation. Consequently, the fibula probably could play a key role in transmitting the weight of the posterolateral knee joint and kinetic energy in motion.

The process of human aging was accompanied by the decrease of bone mass[16]. Especially, in the load-bearing joints exists varying degrees of the settlement of bone mass, such as the knees, hips, ankles, and spine. A supporting and plugging effect on the lateral tibial plateau through the proximal tibiofibular joint was provided with the strong fibula. It might be the anatomical and pathological mechanism of nonuniform settlement. It was indirectly indicated that the forces of the tibia were uneven in medial and lateral[17–20]. There was evidence that the progression of KOA was related to the tibiofemoral articular stress distribution[21]. Studies found that the slope of the tibial plateau arising from nonuniform settlement results in a transverse shearing force, with the femoral condyle producing ramping during walking and sports[6]. These assumptions should bring the clinician's attention to the role of the factors of the fibula, in the coronal subluxation of the proximal tibia in patients with knee osteoarthritis.

Moreover, the geometry of the tibial plateau has attracted more and more attention from scholars in recent years. Some data have shown the inclination of the tibial plateau could be used as a risk factor for anterior cruciate ligament injury to a certain extent[22]. According to the results of the present study, the

fibula more probably affects the inclination of the tibial plateau to some extent, especially for osteoarthritis patients with knee varus. Therefore, for medial KOA, the role of the fibula in supporting the tibial plateau should strongly attract the attention of clinicians.

Collectively, the finding in the present study had revealed a novel correlation between the fibula and tibial, and this might provide an anatomical basis for the further treatment of KOA and understanding the risk factors of cruciate ligament injury.

Limitations

In future research, quantifying the information of trabecular bone at the arched beam will be of important implications for further treatment of KOA.

Conclusion

The arch beam was formed by the union of the fibula and the posterolateral bone cortex of the tibial shaft via the tibiofibular joint, which played an important role in the stress transfer of the articular surface of the lateral condyle of the tibia. The tibiofibular joint was an indispensable fulcrum for the arch beam. The fibula more probably was an important factor in the diagnosis and treatment of knee diseases.

Abbreviations

KOA: Knee Osteoarthritis; TKA: Total knee arthroplasty

Declarations

Acknowledgments

This study was supported by the National Natural Science Foundation of China (Grant No. 82072447). We would like to thank Director Yun Zheng of Dalian Hoffen Biotechnology Co., Ltd., for assistance with photography.

Author Contributions

S-B. Y, H-J. S, conceived and designed the experiments. W-B. J, S-Z S, W T, data acquisition. W-B. J, C L, P A, drafted the manuscript. W C, S-B. Y, H-J. S, critical revision of the manuscript. All authors were involved in data interpretation.

Funding

This study was supported by the National Natural Science Foundation of China (Grant No. 82072447).

Availability of data and materials

The datasets used and/or analyzed during the current study are available from the corresponding author on reasonable request.

Ethics approval and consent to participate

The ethics committee of the Body and Organs Donation Center of Dalian Medical University approved this study. 27 knee specimens of Chinese adults in middle age from the Body and Organs Donation Center were involved. Before death following the regulation of the ethics committee, the written informed consent was obtained from the donors involved in this study.

Consent for publication

Not applicable.

Competing of interest

All the authors declare that they have no competing of interest.

References

1. Brandt KD, Dieppe P, Radin EL. Etiopathogenesis of osteoarthritis. In: Rheumatic Disease Clinics of North America. vol. 34; 2008: 531-+.
2. Chang AH, Lee SJ, Zhao H, Ren Y, Zhang L-Q. Impaired varus-valgus proprioception and neuromuscular stabilization in medial knee osteoarthritis. Journal of Biomechanics 2014, 47(2):360-366.
3. Wang J, Chen W, Hou Z-Y, Lyu H-Z, Zhu Y-B, Zhang Y-Z. Law of dynamic deformation of bone. Chinese Medical Journal 2019, 132(21):2636-2637.
4. Wang J, Lv H-z, Chen W, Fan M-k, Li M, Zhang Y-Z. Anatomical Adaptation of Fibula and its Mechanism of Proximal Partial Fibulectomy Associated with Medial Compartment Knee Osteoarthritis. Orthopaedic Surgery 2019, 11(2):204-211.
5. Dong T, Chen W, Zhang F, Yin B, Tian Y, Zhang Y. Radiographic measures of settlement phenomenon in patients with medial compartment knee osteoarthritis. Clinical Rheumatology 2016, 35(6):1573-1578.
6. Zhang Y, Li C-X, Li J-D, Wang F, Zhu Y-B, Yang G, Tian Y. The pathogenesis research of non-uniform settlement of the tibial plateau in knee degeneration and varus. Journal of Hebei Medical University 2014, 35(2):218-219.
7. Sugita T, Kawamata T, Ohnuma M, Yoshizumi Y, Sato K. Radial displacement of the medial meniscus in varus osteoarthritis of the knee. Clinical orthopaedics and related research 2001(387):171-177.
8. Adams JG, McAlindon T, Dimasi M, Carey J, Eustace S. Contribution of meniscal extrusion and cartilage loss to joint space narrowing in osteoarthritis. Clinical radiology 1999, 54(8):502-506.

9. Gale DR, Chaisson CE, Totterman SM, Schwartz RK, Gale ME, Felson D. Meniscal subluxation: association with osteoarthritis and joint space narrowing. Osteoarthritis and cartilage 1999, 7(6):526-532.
10. Khamaisy S, Zuiderbaan HA, Thein R, Gladnick BP, Pearle AD. Coronal tibiofemoral subluxation in knee osteoarthritis. Skeletal Radiology 2016, 45(1):57-61.
11. Englund M, Guermazi A, Lohmander SL. The Role of the Meniscus in Knee Osteoarthritis: a Cause or Consequence? Radiologic Clinics of North America 2009, 47(4):703-+.
12. Yasushi A, Satoshi O, Hideo K, Yoshihiro K, Ken K, Tomoyuki S. Coronal subluxation of the proximal tibia relative to the distal femur after opening wedge high tibial osteotomy. Knee 2017, 24:70-75.
13. Sui H-J, Henry R: Polyester plastination of Biological tissue. Hoeffen P45 technique. J INT SOC PLASTINATION 2007, 22:78-81.
14. Jiang W-B, Sun S-Z, Song T-W, Li C, Tang W, Fei X, Yu S-B, Sui H-J. Internal Structural Connections in the Popliteal Muscle Tendon Complex and Their Clinical Significance. 2021, doi:10.21203/rs.3.rs-200424/v1. PPR:PPR280935.
15. McNeil CJ, Raymer GH, Doherty TJ, Marsh GD, Rice CL. Geometry of a Weight-Bearing and Non-Weight-Bearing Bone in the Legs of Young, Old, and Very Old Men. Calcified Tissue International 2009, 85(1):22-30.
16. H.F.Newton-John, D.B.Morgan. Osteoporosis: disease or senescence? . Lancet 1968, 291(7536):232-233.
17. Guo J, Zhang L, Qin D, Chen W, Dong W, Hou Z, Zhang Y. Changes in ankle joint alignment after proximal fibular osteotomy. Plos One 2019, 14(3).
18. Qin D, Chen W, Wang J, Lv H, Ma W, Dong T, Zhang Y. Mechanism and influencing factors of proximal fibular osteotomy for treatment of medial compartment knee osteoarthritis: A prospective study. Journal of International Medical Research 2018, 46(8):3114-3123.
19. Liu B, Chen W, Zhang Q, Yan X, Zhang F, Dong T, Yang G, Zhang Y. Proximal fibular osteotomy to treat medial compartment knee osteoarthritis: Preoperational factors for short-term prognosis. Plos One 2018, 13(5).
20. Yang Z-Y, Chen W, Li C-X, Wang J, Shao D-C, Hou Z-Y, Gao S-J, Wang F, Li J-D, Hao J-D. Medial Compartment Decompression by Fibular Osteotomy to Treat Medial Compartment Knee Osteoarthritis: A Pilot Study. Orthopedics 2015, 38(12):E1110-E1114.
21. Segal NA, Donald D A, Krishna S I, Jennifer B, James C T, John A L, David T F, Cora E L, Thomas D B. Baseline articular contact stress levels predict incident symptomatic knee osteoarthritis development in the MOST cohort. J Orthop Res 2009, 27(12):1562-1568.
22. Todd MS, Lalliss S, Garcia ES, DeBerardino TM, Cameron KL. The Relationship Between Posterior Tibial Slope and Anterior Cruciate Ligament Injuries. American Journal of Sports Medicine 2010, 38(1):63-67.

Figures

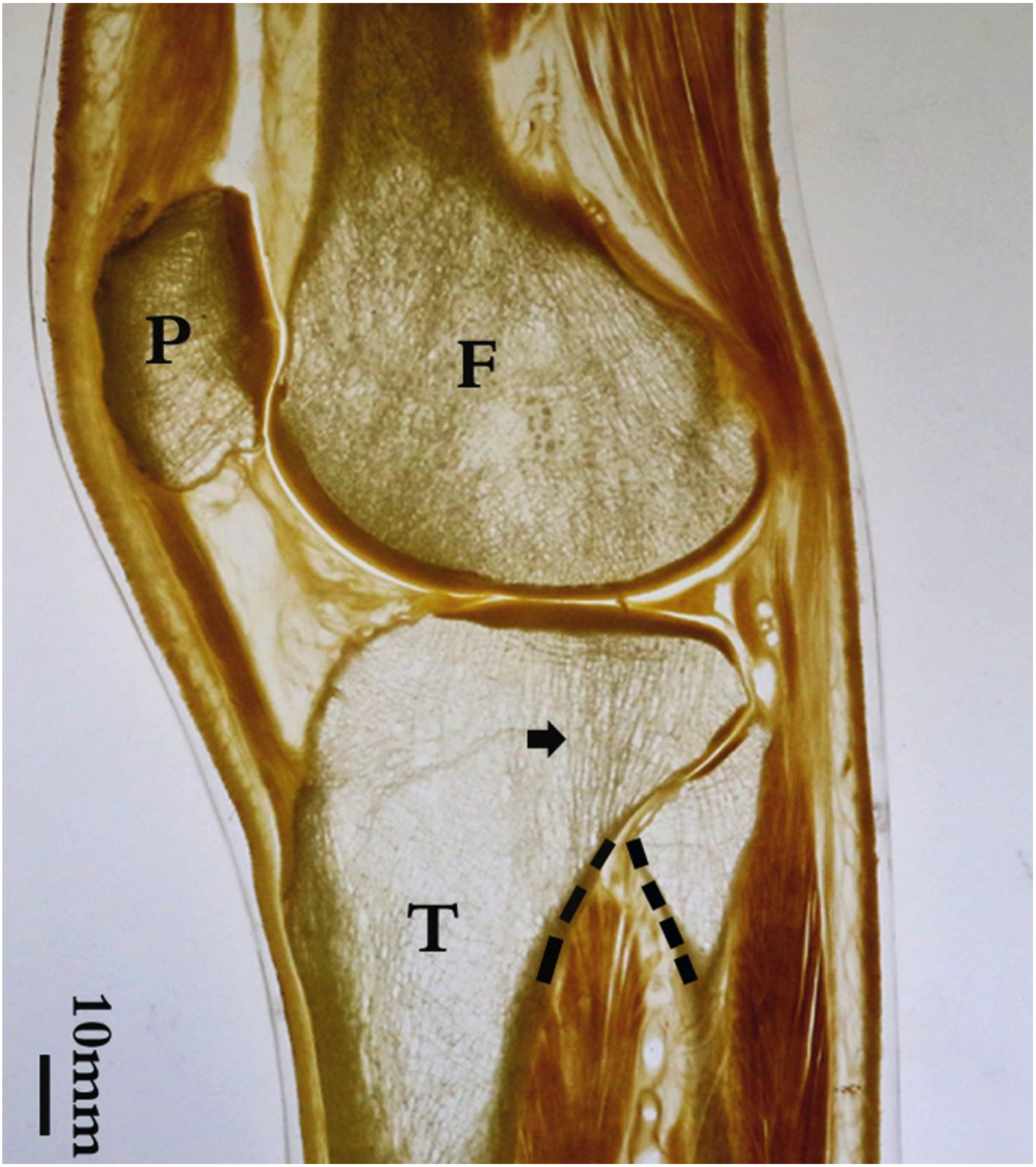

Figure 1

Sagittal P45 section of the knee joint (through Oblique sagittal section of the tibiofibular joint) It was found that the tiny and sparse bone trabeculae be assigned perpendicular to the tibiofibular joint surface, above the tibiofibular joint. The fibula formed an arch through the tibiofibular joint and the posterior lateral bone cortex of the tibial shaft. The distribution of trabeculae bone in the lateral condyle of the tibia was nonuniform, the longitudinal trabeculae bone was densely distributed in the posterior lateral part of

the lateral tibial condyle. The longitudinal trabeculae passing through the epiphyseal line were distributed between the arch and the articular surface of the lateral tibial plateau. The posterior part of the fibular head shows parallel trabeculae perpendicular to the tibiofibular articular surface. However, in the anterior part of the fibular head, the internal trabeculae were sparse and no obvious longitudinal trabeculae were found. F: Femur; T: Tibia; P: Patella; Dotted line: arch beam between the fibula and tibial plateau; black arrow: bone trabeculae arranged vertically

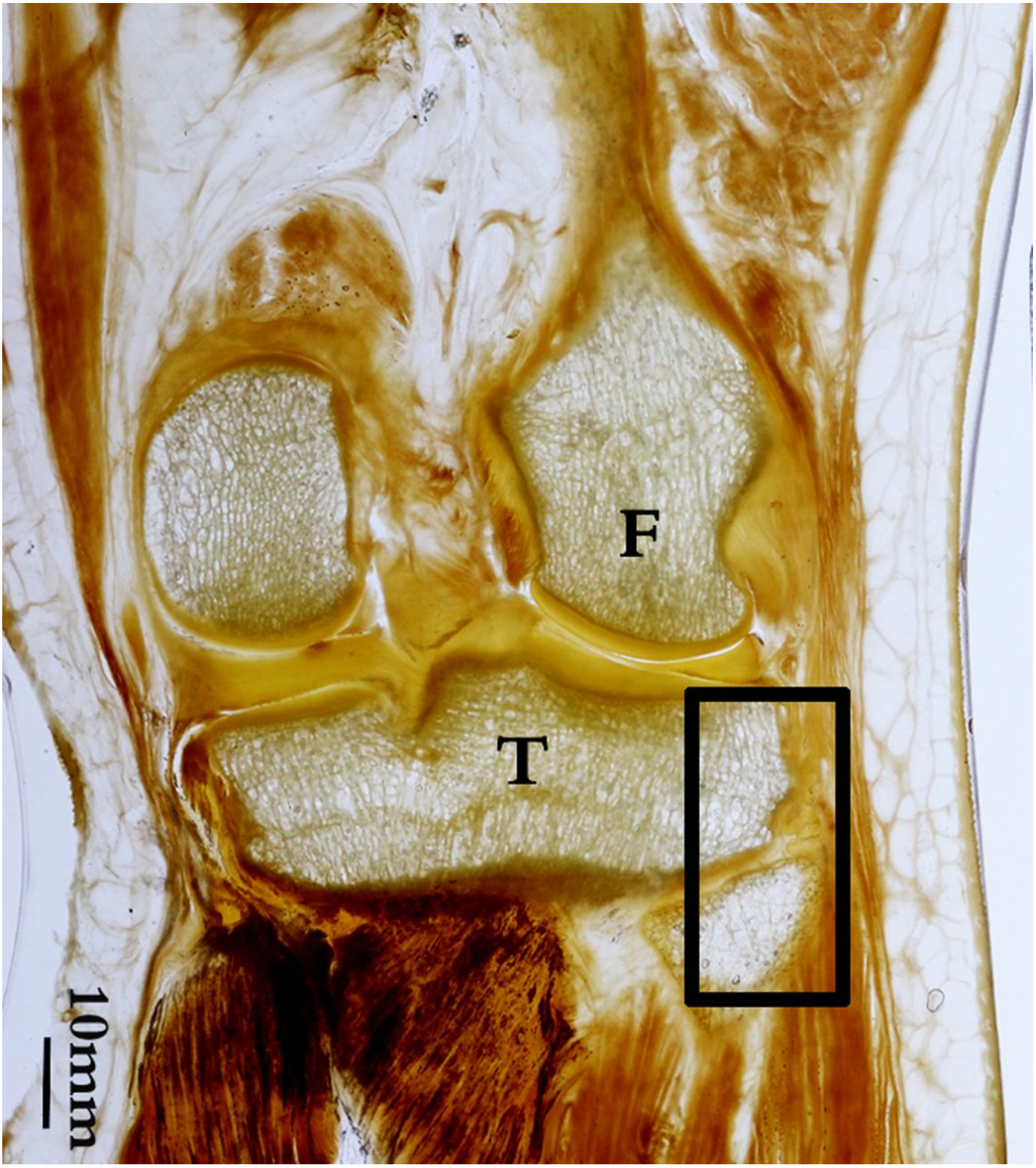

Figure 2

Coronal P45 section of the knee joint (through the tibiofibular joint) In the lateral condyle of the tibia, the bone trabecula in the area above the fibular head was tiny and sparsely reticulated, accounting for about a quarter of the coronal section of the lateral condyle. The thicker and longitudinally arranged bone trabeculae could be seen between the articular surface and the epiphyseal bone cortex in the medial three-fourths area. In the fibular head, the trabeculae were sparse. F: Femur; T: Tibia; Black box: the bone trabecula was in the loose area of the lateral tibial plateau and fibula.

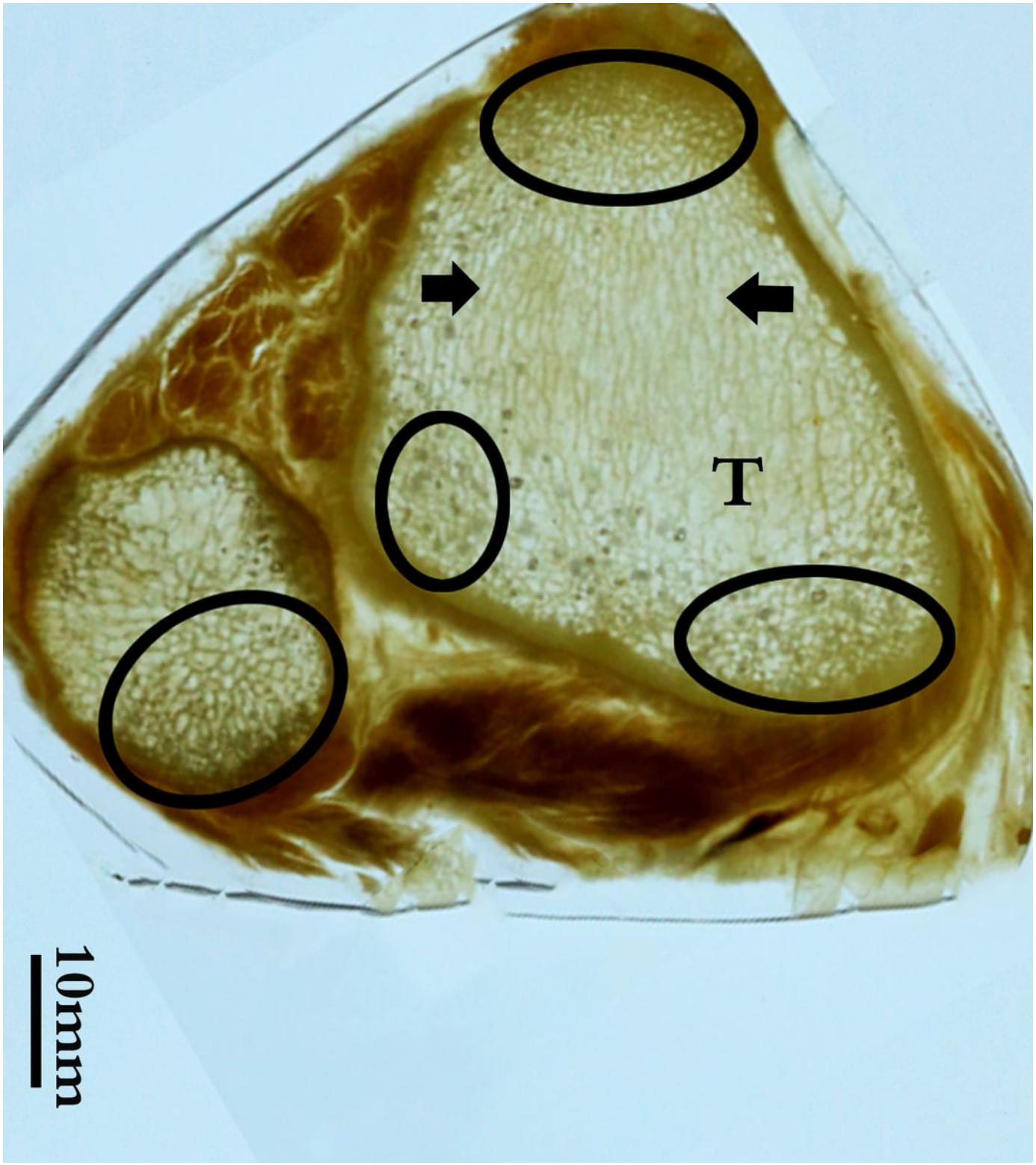

Figure 3

Horizontal P45 section of the knee joint (through the tibiofibular joint) A large number of bone trabeculae were reticulated near the peroneal side and posterior medial bone cortex. But, in the central area of the metaphyseal of the tibia, the bone trabeculae arranged in parallel in the sagittal position could be found. It was observed that the thickened and densely distributed trabeculae on the deep surface of the tuberosity of the tibia. On the other hand, the fibula was mainly composed of grid-like trabeculae, and the dense grid-like trabeculae were mainly distributed in the posterior part of the fibula. The dense and reticulated trabeculae in the metaphysis of the tibia and the posterior half area of the neck of the fibula could be combined by the tibiofibular joint to form a situation of tripartite confrontation. But, which tripartite could not be identified. T: the metaphysics of the tibia; the black ellipse: the reticulated trabecular area densely distributed in the posterior medial side of the fibula. Black arrow: the central parallel bone trabecular area.