Pedicled Buccal Flaps as a Back-Up Procedure for Intraoral Reconstruction

Gesche Frohwitter (gesche.frohwitter@uk-erlangen.de)
University Hospital Erlangen Department of Oral and Maxillofacial Surgery https://orcid.org/0000-0001-6732-215X

Marco Rainer Kesting
Department of Oral and Maxillofacial Surgery University Hospital Erlangen

Andrea Rau
Department of Oral and Maxillofacial Surgery University Hospital Greifswald

Manuel Weber
Department of Oral and Maxillofacial Surgery University Hospital Erlangen

Christoph Baran
Department of Oral and Maxillofacial Surgery University Hospital Erlangen

Christopher-Philipp Nobis
Department of Oral and Maxillofacial Surgery University Hospital Erlangen

Tjark-Ole Buentemeyer
Department of Oral and Maxillofacial Surgery University Hospital Erlangen

Raimund Preidl
Department of Oral and Maxillofacial Surgery University Hospital Erlangen

Rainer Lutz
Department of Oral and Maxillofacial Surgery University Hospital Erlangen

---

Research

Keywords: Pedicle flaps, reconstructive surgery, back-up procedures, cleft surgery, oral surgery

Posted Date: March 3rd, 2021

DOI: https://doi.org/10.21203/rs.3.rs-262525/v1

Abstract

Background

Intraoral soft tissue deficiency and impaired wound beds are common problems after cleft and tumour surgery or after dental trauma. Frequently, limited defects are overtreated with extensive microvascular reconstruction procedures and pedicled flaps remain useful, as they are simple to harvest and provide a reliable outcome. The buccal flap, first described in the 1970s, has been used for palatine lengthening in cleft patients over decades. In the following we present an expanded indication in cases of palatal fistula, complex vestibulum, exposed bone in orthognathic surgery and osteoradionecrosis.

Methods

We conducted a retrospective chart review and report on all buccal flaps harvested within the last three years. 16 buccal flaps were performed in 10 patients. The median age at the time of surgery was 42 years, reaching from 12 years up to 66 years.

Results

14 buccal flaps were used for upper jaw or palatal coverage, two buccal flaps were used in the mandible.

In terms of complications (four flaps; 25 %) there were two partial flap failures, one wound dehiscence and one wound dehiscence. There were no failures of the remaining mucosal flap islands after the cut of the pedicles.

Conclusion

The buccal flap is a reliable and straight forward approach to challenging intraoral wound beds with soft tissue deficiency. We thoroughly discuss the additional indications for buccal flap surgery, describe the harvest technique and provide strategies to prevent intra- and postoperative complications.

Introduction

Deficiency of intraoral soft tissue is often the result of ablative tumour surgery, trauma or cleft formation. Considering the reconstructive ladder there are two relevant strategies for circumscribed and medium-sized defects of the oral cavity: microvascular flaps or local (pedicled) flaps. The popularity of microvascular flaps due to their high success rates and flexible extend of defect coverage led to the development of so-called pedicled (mini) perforator flaps during the last decade (1). The advantage of a minimal morbidity at the donor site during the harvest of the perforator flap harvest is offset by the non-mucosal lining for intraoral substitution as well as the short and small-diameter vascular pedicle, resulting in higher complication rates compared to conventional microvascular flaps (2, 3). Furthermore, limited intraoral defects such as palatal fistulas in cleft surgery, mucosal shortage in complex dental implant procedures or coverage of alveolar crest wounds in osteo (radio-) necrosis are not suitable for

extensive microvascular reconstruction. Hence, in oral defects with compromised mucosa a number of local pedicled flaps remain useful as their simplicity in harvesting as well as their reliable outcome mark key aspects in challenging wound beds. Standard procedures include (myo-) mucosal flaps like Axhausen ´s cheek transposition flap or Rehrmann's trapezoid mucoperiostal buccal flap (4, 5). However, they are restricted to defined anatomic locations such as oroantral fistula closure and may not be extended to palatal defects. Furthermore, in cases of secondary or tertiary surgery the local tissue may be extensively impaired by scarring, malperfusion and contraction, remaining impossible for standard local flap procedures. This led to the development of innovative (myo-) mucosal flaps in the late 1980s and early 1990s which allow a wider range of movement to cover intraoral defects and may even be successful in pre-operated tissue (6–8). Mann et al. described a technique of bilateral buccal flaps for primary closure of wide palatal clefts and as a back-up procedure for palatal lengthening in cases of cleft associated velopharyngeal dysfunction (9, 10). The flap may be harvested as an either anteriorly or posteriorly pedicled random pattern myomucosal flap of the buccal soft tissue under sparing of the parotid duct. Depending on the local conditions it may have a length of up to 6 cm with a width of 2 cm, which allows a rotation just over the median sagittal plane and if harvested bilaterally safely covers the same. We present a series of indication extension for the buccal flap in cases of palatal fistula, complex vestibulum and recurrent exposed bone in orthognathic surgery and osteoradionecrosis.

Methods

Patients

Between October 2017 and September 2020 over 250 patients with small to medium-sized intraoral defects were treated by the use of microvascular and pedicled flaps in our institution.

A retrospective chart review of the first authors' experience (MK, GF) using the buccal flap as back-up procedure after (failed) surgical pre-treatment was carried out.
The review was performed in accordance with the Declaration of Helsinki and approval by the local ethics committee (Medical Faculty of University Hospital of Erlangen, registration number 341_20Bc).
A total of 16 buccal flaps, 6 bilaterally and 4 unilaterally, in 10 patients were harvested. Statistical analysis was performed by the use of IBM SPSS Statistics Version 24 (Released 2016. IBM SPSS Statistics for Windows. Armonk, NY: IBM Corp.).

Surgical technique

All patients underwent surgery in general anaesthesia with nasal intubation. If possible, the nasotracheal tube was placed in the nostril of the unaffected defect side. The wound margins of the defects were prepared by de-epithelialisation, sharp bone edges were removed, and the wound bed was rinsed with polyhexanide 0.04% (Serasept, Serag Wiessner, Naila, Germany).

For flap preparation the parotid duct was marked and the buccal flap size inferior to the parotid duct was outlined (Fig. 1). In cases of a posterior pedicle the flap may not exceed the retromolar trigone. In anterior

pedicled flaps the base of pedicle should respect a distance to the oral commissure of 1 cm to avoid a visible torsion of the lip and the corner of the mouth. The flap harvest was performed from distal to proximal by incision of the mucosa and a split dissection of the buccinator muscle with leave of a thin muscle layer on the buccal fat (Fig. 1). Depending on the defect size and the individual anatomical circumstances the pedicle may have a length of up to 6 cm with a diameter of 2 cm and a thickness of 0,5 cm (Fig. 1). After raising the flap was rotated to the defect site and bipolar cautery for haemostasis was performed. The donor site was closed primarily with resorbable sutures (Serafit 3 – 0, Serag Wiessner, Naila, Germany) from distal to proximal saving a distance of 5 mm to the pedicle to prevent squeezing and malnutrition. The flaps were sutured to the defect site with resorbable sutures of either 3 – 0 or 4 – 0 USP-size (Serafit, Serag Wiessner, Naila, Germany). All patients received nasogastric feeding tubes for five days and afterwards were instructed to keep a soft food diet until the cut of the pedicle. Furthermore, all patients were advised in careful oral hygiene by mouth rinse and brushing. Patients received a single-shot antibiosis during surgery or if considered as necessary, for up to ten days (ampicillin and clavulan acid, for patients with penicillin allergy: clindamycin). Analgesics were prescribed according to the WHO-scheme and included non-steroidal anti-inflammatory drugs and metamizole.

All patients were integrated in clinical recalls. The pedicle was left in place until complete local wound closure and flap autonomy was achieved. Flap autonomy was assessed based on clinical impression and a colour change when the pedicle was gently squeezed with forceps. In a second procedure, the pedicle was transected under general or local anaesthesia in dependence on the further treatments necessary. At the reconstructive site the tissue was sutured to the local mucosa (resorbable sutures 3 – 0 or 4 – 0 USP-size, Serafit, Serag Wiessner, Naila, Germany), the tissue excess at the donor site was usually not resutured but resected and cauterized, as it frequently results as a trigger for cheek bites.

Results

A total of 16 buccal flaps, 6 bilaterally and 4 unilaterally, in 10 patients (5 females, 5 males) were harvested. The median age at the time of surgery was 42 years (minimum 12 years, maximum 66 years, mean 48 years). One patient died 83 days after flap surgery due to distant metastatic tumour progress. All patients (n = 10) who received buccal flaps were extensively surgically pre-treated within the oral cavity (minimum 5 times, maximum 35 times). Five patients initially suffered from malign oral tumour disease or precancerous lesion, three patients received multiple cleft surgeries, one patient experienced a complex dental trauma and one patient suffered from exposed bone after orthognathic surgery.

The indication for buccal flap surgery (n = 16) were four palatal fistula closures after cleft surgery (25 %; no flap failure wound dehiscence; Fig. 2), three palatal fistula closures after tumour resection and wound dehiscence of a microvascular transplant (18,75 %; no flap failures, one persisting palatal fistula; Fig. 3), three vestibuloplasties after tumour surgery (18,75 %; no flap failures), three mucosal coverages after bone autogengous bone augmentation (18,75 %; one partial flap failure due to malperfusion), one mucosal coverage after osteoradionecrosis resection (6.25 %; no flap failure) and two surgical wound revisions after previous partial buccal flap failure (12.5 %; one flap failure due to wound dehiscence). 14

buccal flaps (87.5 %) were used for upper jaw or palatal coverage, two buccal flaps (12.5 %) were used in the mandible. 10 flaps (62.5 %) were anterior pedicled and 6 flaps (37.5 %) were posterior pedicled. The flap sizes had a mean width of 1.706 cm and a mean length of 4,687 cm (width: minimum 1.0 cm, maximum 2 cm, median 1,650 cm; length: minimum 3.5 cm, maximum 6 cm, median 5.0 cm). In terms of complications (four flaps; 25 %) there were two partial flap failures (12.5 %) that required the raising of a second buccal flap from the contralateral side, one wound dehiscence (6.25 %) that required a surgical intervention to refixate the mucosal island, one wound dehiscence (6.25 %) with a clinical irrelevant palatal fistula that was left untreated and no total flap losses. In cases of pedicle interference with the occlusion a removable occlusal splint was inserted to prevent squeezing.

The pedicle was cut in 12 cases (n = 16, 75 %), in 4 cases (25 %) the pedicle remained as it completely adapted to the former wound bed. The mean time form flap raises to cutting the pedicle was 63.17 days (median 41.5 days, minimum 23 days, maximum 133 days). In the case where the pedicle was cut 133 days after initial flap raise the patient received further orthodontic and medical treatment due to physical disabilities (CHARGE syndrome) which postponed the maxillofacial surgery. There were no failures of the remaining mucosal flap islands after the cut of the pedicles. Three pedicles (23.07 %) were cut in local anaesthesia and ten pedicles (76.92 %) were cut under general anaesthesia as further surgical interventions were required. A secondary flap debulking after the cut of the pedicle did not become necessary in any patient. In two case (12.5 %) the palatal fistula of a tumour patient and a cleft patient could not be closed sufficiently by two buccal flaps; all other flaps showed the desired results and a long-term stability. None of the patients experienced any donor site morbidity such as intraoral deformities causing cheek bites, speech difficulties, chronic pain or reduced mouth opening.

Discussion

In cases of extensively impaired intraoral wound beds, commonly seen after secondary or tertiary closure in palatal clefts, oroantral fistulae, osteo(-radio) necrosis and as a lack of attached gingiva or vestibulum depth after ablative tumour surgery, standard local flaps such as Axhausen’s cheek transposition flap, Rehrmanns’s trapezoid flap or simple palatal flaps are no longer possible due to extensive scarring, malperfusion and a lack of mobilizable tissue. Frequently, microvascular flaps serve as reliable options in situations of large defect sizes, however in selected clinical cases free flap surgery would be considered as a vast overtreatment neglecting the reconstructive needs of the local conditions. Hence, innovative but reliable local flap procedures need to be considered as back-up strategies in the armamentarium of today’s oral and maxillofacial surgery.

In the following we discuss a safe, reliable and highly useful indication extension of the buccal flap in hostile wound beds affected by a multitude of surgeries and adjuvant therapy. Introduced in the mid 1970s the buccal flap has experienced many modifications (11, 12). It may be harvested as an axial pattern flap including the facial artery as a main vessel as well as a random pattern flap, furthermore its thickness may reach from thin myomucosal flaps up to pedicled buccal fat pad integration (8, 13). Traditionally the myomucosal random patterned buccal flap, as described by Mann et al. in the late

1990s, serves as an option for primary closure of wide palatal clefts or as a back-up procedure for palatal lengthening in cases of cleft associated velopharyngeal dysfunction (9, 10). Beside the indications for cleft treatment there are a multitude of intraoral surgical procedures that demand soft tissue coverage in regions where dehiscence and infection play a key role in heavily pre-treated, malperfused and scarred wound beds. Even though the usage of allogenic and xenogenic grafts in pre-implantologic surgery, due to their easy handling, has become vastly popular these methods are not applicable in most cases of complex maxillofacial defects even if their anatomic diameter may not exceed the size of standard case in dental surgery surgery (14–16). Especially in preirradiated, malperfused tissue the application of xenogenic membranes may result in wound infection with consecutive tissue contraction and scarring that hampers the challenges of intraoral rehabilitation. Hence, the application of safely perfused local tissue is inevitable for treatment success.

We applied the buccal flap in ten patients who overall received 16 flaps and had undergone a multitude of surgeries in advance (minimum 5 times, maximum 35 times). The surgical indications were closure of palatal fistulas after tumour resection and cleft surgery, pre-implantological soft tissue improvement by vestibuloplasties, mucosal covering of autogenous bone transplants and defect closure after the resection of osteoradionecroses. The surgeries were uneventful, all flaps were harvested without complications such as malperfusion or injury of the pedicle and suited the initial treatment indication. In two cases (12.5 %) the palatal fistulae could not be closed completely but were transposed from clinically apparent (nasal food and fluid regurgitation) to clinically silent (no food and fluid regurgitation). Both patients were heavily pre-treated with up to 35 surgical attempts in different hospitals and private practices to close the fistulae. However, when considering the buccal flap as an option for intraoral soft tissue reconstruction certain aspects need to be borne in mind.

Firstly, the defect location determines the origin of the pedicle. Anterior pedicled flaps may be indicated in tissue shortage of the anterior half of the oral cavity up to the first premolar and cover the entire vestibulum and hard palate of the harvested flap site, whereas posterior pedicled flaps mostly serve as a coverage for the dorsal half of the oral cavity including the soft palate. In both cases distal flap perfusion seems to be limited when the myomucosal flap extends a length-to-base relation of over 3:1. To preserve the aesthetic unit of the lips and prevent extraoral deformities due to tension or distortion a gap of 1 cm to the angle of the mouth should be kept in anteriorly pedicled flap. Posterior pedicled flaps the retromolar trigone should not be incised to prevent bleeding and secure sufficient flap perfusion. Independently of the pedicle location a flap mobilisation over the median sagittal plane is not recommended as pulling and stressing the pedicle results in immediate malperfusion followed by dehiscence or flap loss. Due to masticatory movements and speech which, often result in tension of the pedicle, buccal flaps for tissue coverage in the lower jaw are more sensitive for wound healing disorders then defect closures in the upper jaw. However, in both cases as soon as the flap crosses the alveolar crest or the teeth the need of a spacer in form of an occlusal splint needs to be considered to avoid biting and injuring the pedicle. During the mixed dentition period tooth gaps may provide a natural corridor which prevents pedicle squeezing.

A clear advantage or the buccal flap compared to other pedicled flaps used for intraoral reconstruction is its blood supply. The random pattern nutrition allows a secure and vessel independent harvest even in patients with heavily pre-treated and perfusion compromised tissue. Especially in hostile necks where the lack of facial arteries or the damage of both lingual arteries may lead to a necrosis of tongue flaps or a reduced security in nasolabial flaps the buccal flap is a reliable alternative (17, 18). Besides it usually offers a larger and more versatile amount of movable tissue compared to classical local flaps such as Rehrmann's trapezoid flap or Axhausen's cheek flap.

However, meticulous wound care is needed to promote uneventful healing. Therefore, we highly recommend nasogastric tube feeding for at least five days, regular mouth rinsing with Chlorhexamed 0,2% and careful tooth brushing. When the nasogastric tube is removed a soft diet should be kept until the cut of the pedicle. Current literature provides inconsistent data concerning the time of transplant autonomisation, reaching from two to six weeks (19, 20). Depending on the local wound situation our patient collective showed a very wide time range of 63.17 days (median 41.5 days, minimum 23 days, maximum 133 days) for pedicle incision. The maximum time of division (133 days) was due to a prolonged orthodontic treatment to prepare the upper jaw for cleft osteoplasty with an autogenous bone transplant and exceeded the clinical appearance from which point on a cut of the pedicle would have been uneventful. Furthermore, the patient suffers from a CHARGE-syndrome that demanded medical intervention during which no maxillofacial treatment was possible. In four cases a pedicle removal was not performed as the lower surface of the flap was completely sutured to the wound bed and aligned with the local mucosa. Nevertheless, the two-stage removal of the pedicle may be seen as a main disadvantage in buccal flap treatment. The intraoral wound situation appears inconvenient and pre-surgical patient education and careful patient selection are needed to ensure best conditions for uneventful healing. As all patients in our collective showed a long history of surgical and adjuvant pre-treatment the buccal flap served as a final back-up for local would management before referring to microvascular tissue replacement. This aspect provides a high patient motivation but justifies the inconvenient time of intraoral pedicle carriage and the temporary restrictions to nutrition, speech and oral hygiene. In our experience, the pedicled buccal flap therefore represents a reliable and practical alternative in selected cases of impaired wound bed and intraoral soft tissue scarcity in demanding local situations for oral and maxillofacial surgeons.

Conclusion

The article introduces a new field of application for the myomucosal random patterned buccal flap in heavily pre-treated intraoral soft tissue defect coverage. Considering the advices in patient selection, flap raise and post-surgical aftercare it provides a secure and technically straight forward alternative in a highly demanding niche in intraoral maxillofacial back-up reconstruction.

Declarations

Ethical approval and Conflict of Interest: All procedures performed in this study were in accordance with the ethical standards of the institutional research committee (Medical Faculty of University Hospital of Erlangen, registration number 341_20Bc) and with the 1964 Helsinki declaration and its later amendments. All authors declare that they have no conflict of interest.
Consent for publication: Written informed consent on the publication of photographs was obtained from all participants.
Availability of data and materials: Additional chart data from all patients may be provided by contacting the corresponding author.

Competing interests None of the authors have any conflict of interest to declare.

Funding: None of the authors received any funding .

Authors' contributions All authors contributed to the study conception and design. Patient surgery, material preparation, data collection by all authors named above. The first draft of the manuscript as well as the data analysis was written and performed by Gesche Frohwitter, Marco Kesting and Rainer Lutz. All authors commented on previous versions of the manuscript. All authors read and approved the final manuscript.

Acknowledgements: The research article is part of a medical doctoral thesis by Christoph Baran.

Author's information: The author's team has a broad experience in the treatment of significant facial deformities caused by congenital syndromes, trauma or cancer. As departments of maximum care hospitals, the maxillofacial teams are specialized on pediatric craniofacial surgery and oro-facial tumor management as well as complex reconstructions of the head and face.

References

1. Janis JE, Kwon RK, Attinger CE. The new reconstructive ladder: modifications to the traditional model. Plastic and reconstructive surgery. 2011;127 Suppl 1:205s-12s.
2. Wolff KD. New aspects in free flap surgery: Mini-perforator flaps and extracorporeal flap perfusion. Journal of stomatology, oral and maxillofacial surgery. 2017;118(4):238-41.
3. Wolff K-D, Rau A, Kolk A. Perforator flaps from the lower leg for intraoral reconstruction: experience of 131 flaps. Journal of Cranio-Maxillofacial Surgery. 2018;46(2):338-45.
4. Axhausen G. Über den plastischen Verschluss von Antrum-Mundhöhlen-Verbindungen. Dtsch Monschr f Zahnheilkunde. 1930;3:193-204.
5. Rehrmann A. Eine Methode zur Schliessung von Kieferhöhlenperforationen. Dtsch Zahnärztl Wschr. 1936;39:1136.
6. Bozola AR, Gasques J, Carriquiry CE, de Oliveira Cardoso M. The buccinator musculomucosal flap: anatomic study and clinical application. Plastic and reconstructive surgery. 1989;84(2):250-7.

7. Carstens MH, Stofman GM, Hurwitz DJ, Futrell J, Patterson GT, Sotereanos GC. The buccinator myomucosal island pedicle flap: anatomic study and case report. Plastic and reconstructive surgery. 1991;88(1):39-50; discussion 1-2.
8. Pribaz J, Stephens W, Crespo L, Gifford G. A new intraoral flap: facial artery musculomucosal (FAMM) flap. Plastic and reconstructive surgery. 1992;90(3):421-9.
9. Mann RJ, Fisher DM. Bilateral buccal flaps with double opposing Z-plasty for wider palatal clefts. Plastic and reconstructive surgery. 1997;100(5):1139-43; discussion 44-5.
10. Mann RJ, Neaman KC, Armstrong SD, Ebner B, Bajnrauh R, Naum S. The double-opposing buccal flap procedure for palatal lengthening. Plastic and reconstructive surgery. 2011;127(6):2413-8.
11. Culf N, Chong J, Cramer L, editors. Different surgical approach to secondary velopharyngeal incompetence. Symposium on management of cleft lip and palate and associated deformities Mosby, St Louis; 1974.
12. Kaplan EN. Soft palate repair by levator muscle reconstruction and a buccal mucosal flap. Plastic and reconstructive surgery. 1975;56(2):129-36.
13. Lee TS, Park S. Use of Pedicled Buccal Fat Pad for Midface Augmentation. The Journal of craniofacial surgery. 2017;28(8):2133-4.
14. Bassetti RG, Stähli A, Bassetti MA, Sculean A. Soft tissue augmentation procedures at second-stage surgery: a systematic review. Clinical oral investigations. 2016;20(7):1369-87.
15. Schmitt CM, Moest T, Lutz R, Wehrhan F, Neukam FW, Schlegel KA. Long-term outcomes after vestibuloplasty with a porcine collagen matrix (Mucograft(®)) versus the free gingival graft: a comparative prospective clinical trial. Clin Oral Implants Res. 2016;27(11):e125-e33.
16. Preidl RHM, Wehrhan F, Weber M, Neukam FW, Kesting M, Schmitt CM. Collagen Matrix Vascularization in a Peri-Implant Vestibuloplasty Situation Proceeds Within the First Postoperative Week. Journal of oral and maxillofacial surgery : official journal of the American Association of Oral and Maxillofacial Surgeons. 2019;77(9):1797-806.
17. Rahpeyma A, Khajehahmadi S. The place of nasolabial flap in orofacial reconstruction: A review. Annals of medicine and surgery (2012). 2016;12:79-87.
18. Gupta N, Shetty S, Degala S. Tongue flap: a "workhorse flap" in repair of recurrent palatal fistulae. Oral and maxillofacial surgery. 2020;24(1):93-101.
19. Menick FJ. Nasal reconstruction with a forehead flap. Clinics in plastic surgery. 2009;36(3):443-59.
20. Surowitz JB, Most SP. Use of laser-assisted indocyanine green angiography for early division of the forehead flap pedicle. JAMA facial plastic surgery. 2015;17(3):209-14.

Tables

Tabel 1 Clinical data of all patients treated with a buccal flap.

Patient-/pedicle number (sex)	Age	Diagnosis	Pedicle location	Flap width (cm)	Flap length (cm)	Defect location	Pedicle cut (days)	Wound healing disorder	Surgical revision	Pedicle cut	Successful wound closure
1/1 (f)	58,12	Palatal fistula after cleft repair	anterior	2,0	5,5	Palate	36	no	no	GA	no
2/1 (m)	36,85	Autologous bone graft coverage after TPD	anterior	1,5	5,0	Maxilla, anterior alveolar ridge	30	Partial flap failure, smoker	yes	GA	yes
2/2 (m)	36,86	Back-up flap after partial buccal flap failure	anterior	1,5	5,0	Maxilla, anterior alveolar ridge	26	no	no	GA	yes
3/1 (m)	59,26	Exposed bone after osteoradionecrosis	anterior	1,5	3,5	Mandible crest	no	no	no	no	yes
4/1 (m)	66,08	Vestibuloplasty after oral cancer	posterior	2,0	6,0	Mandible vestibulum	35	no	no	GA	yes
5/1 (f)	47,89	Palatal fistula after tumor resection	posterior	1,5	5,5	Palate	no	Partial flap failure, no soft food diet	yes	no	yes
5/2 (f)	48,21	Back-up flap after partial buccal flap failure	posterior	1,8	5,0	Palate	no	Clinical irrelevant palatal fistula	no	no	no
6/1 (f)	19,27	Autologous bone graft coverage after dental trauma	anterior	1,5	4,0	Maxilla, anterior alveolar ridge	36	no	no	LA	yes
6/2 (f)	19,27	Autologous bone graft coverage after dental trauma	anterior	1,5	4,0	Maxilla, anterior alveolar ridge	no	no	no	no	yes
7/1 (f)	20,47	Palatal fistula after cleft repair	anterior	1,0	3,5	Palate	133	no	no	GA	yes
7/2 (f)	20,47	Palatal fistula after cleft repair	anterior	1,5	3,5	Palate	133	no	no	GA	yes
8/1 (f)	52,53	Palatal fistula after tumor resection	posterior	2,0	5,5	Palate	106	Refixation of the pedicle	yes	GA	yes
8/2 (f)	52,53	Palatal fistula after tumor resection	posterior	2,0	5,5	Palate	106	no	no	GA	yes
9/1 (m)	63,97	Vestibuloplasty after oral cancer	anterior	2,0	4,5	Maxilla anterior alveolar ridge	47	no	no	LA	yes
9/2 (m)	63,97	Vestibuloplasty after oral cancer	anterior	2,0	5,0	Maxilla anterior alveolar ridge	47	no	no	LA	yes
10/1 (m)	12,38	Palatal fistula after cleft repair	posterior	2,0	4,0	Palate	23	no	no	GA	yes

Abbreviations: TPD – transpalatinal distraction; GA – general anaesthesia, LA – local anaesthesia

Figures

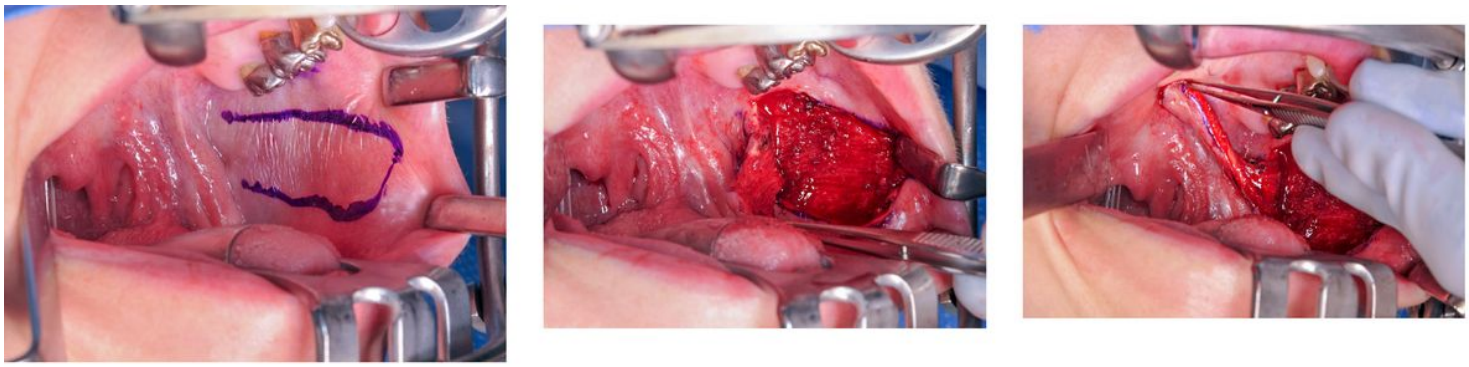

a b b

Figure 1

Workflow of a buccal flap harvest in three steps. a - Marking of the incision lines b - Buccal flap harvest c - Mobilisation of the buccal flap to the recipient site

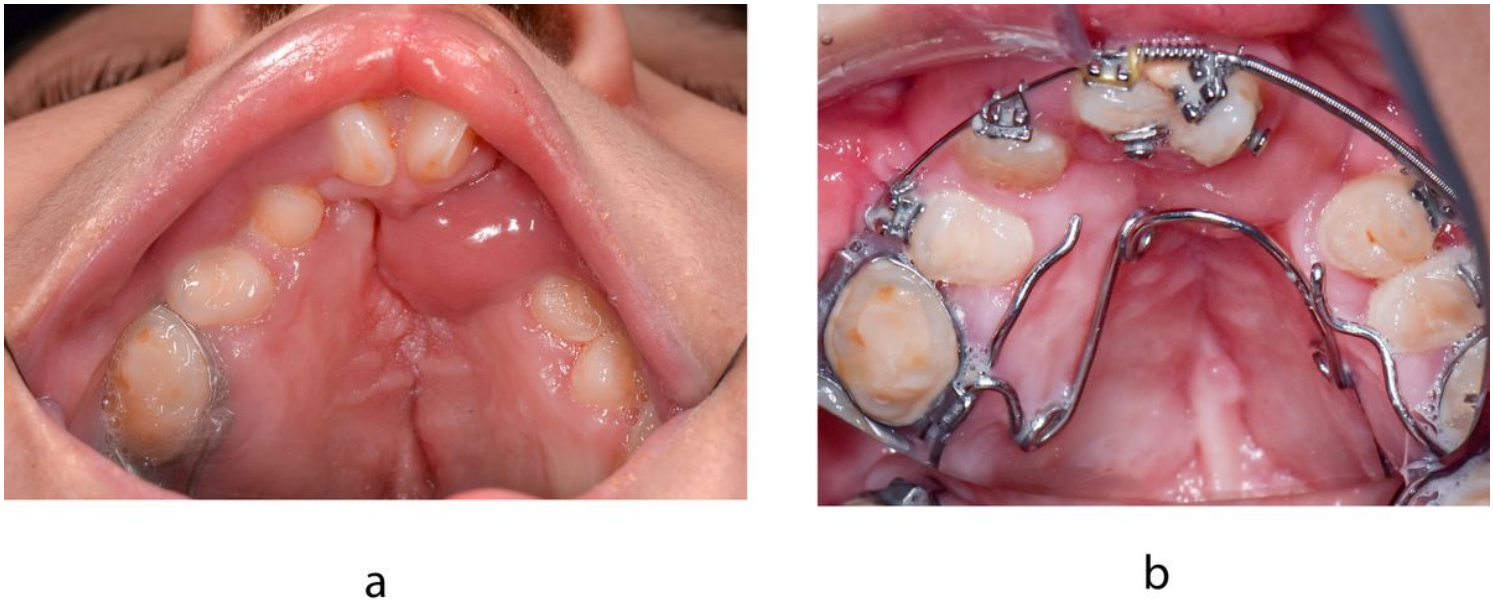

Figure 2

A 14 years old patient with a bilateral palatal fistula after bilateral cleft repair after fistula closure. a - Healed bilateral buccal flap in a case of successful palatal fistula coverage in a bilateral cleft lip and palate b - Healed bilateral buccal flap with an inserted orthodontic multiband appliance

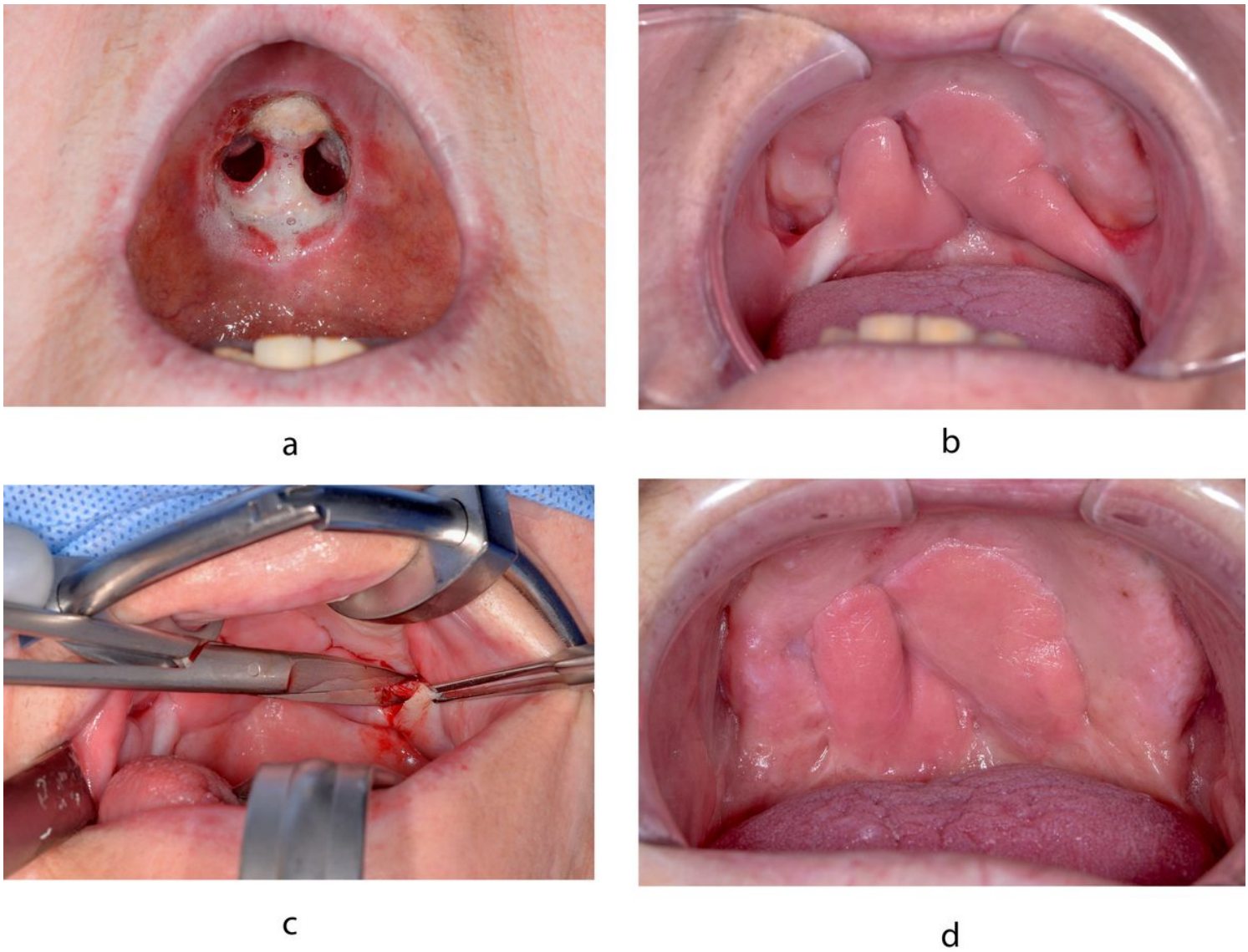

Figure 3

A 53 years old patient with a palatal fistula after tumour resection. a - Hard palate wound ground after tumour resection b - Pedicled buccal flap adapted to the recipient site of the hard palate c - Pedicle dissection d - Hard palate with healed bilateral buccal flap