Research Square

Preprints are preliminary reports that have not undergone peer review. They should not be considered conclusive, used to inform clinical practice, or referenced by the media as validated information.

Incidence of ischemic complications and technical nuances of arteries protection for insular gliomas resection.

Zonggang Hou
Capital Medical University
Zhenxing Huang
Capital Medical University
Zhenye Li
Capital Medical University
Gen Li
Capital Medical University
Yaokai Xu
Capital Medical University
Mingran Wang
Capital Medical University
Shengjun Sun
Capital Medical University
Yazhuo Zhang
China National Clinical Research Centre for Neurological Diseases
Hui Qiao
Capital Medical University
Jian Xie (xiejianw@yeah.net)
Capital Medical University https://orcid.org/0000-0002-2674-6148

Research Article

Keywords: insular glioma, surgery, middle cerebral artery, ischemia, motor evoked potentials, surgical technique

Posted Date: March 3rd, 2021

DOI: https://doi.org/10.21203/rs.3.rs-262945/v1

License: This work is licensed under a Creative Commons Attribution 4.0 International License. Read Full License

Abstract

Insular gliomas remain surgically challenge due to their complex anatomical position and microvascular supply. The incidence of ischemic complications is a risk that should not be ignored. The goal of this study was to analyze the incidence of ischemia and its risk factors, and also describe a single surgeon's arteries protection experience of insular gliomas resection. The authors studied 75 consecutive cases of insular gliomas that underwent transcortical tumor resection in their division. Analysis included pre- and postoperative demographic, clinical, radiological including diffusion weighted imaging (DWI), as well as intraoperative neurophysiology data, and functional outcomes. Strategies such as “Residual Triangle”, “Basal Ganglia Reconstruction” and “Sculpting Technique” were used to protect lateral lenticulostriate arteries and main branches of M2 for maximal tumor resection according to the different classification of Berger-Sinai. Postoperative diffusion-weighted imaging showed acute ischemia in 44 patients, only 9 of whom developed new motor deficits. Flat inner edge (OR 0.144 95% CI 0.024, 0.876), and motor evoked potentials (MEPs) (<50%) (OR 18.182, 95% CI 3.311, 100.00) were determined to have significant associations with postoperative Critical Ischemia, which located in the posterior limb of the internal capsule or corona radiata. For insular gliomas resection, the protection of main branches of MCA is important. Insular gliomas resection might be with high incidence of ischemia uncovered by DWI which not always result in neurological deficits. Their own strategies maybe the feasible technical nuances allow the surgeon to achieve a thorough and safe resection. Motor evoked potentials is essential for its resection.

Introduction

The insular lobe is a common intrinsic brain tumor site[3]. The M2 segment of middle cerebral artery (MCA) and insular arteries form a grid covering over the insular cortex. The lateral lenticulostriate arteries (LLSAs) supply the internal capsule and often course along the medial side of the tumor[6]. In cases of large tumors, LLSAs can be a source of vascular supply to the insula along with the M2–M3 short perforating branches[19]. It has been reported that the interruption of M2 branches and LLSAs may result in motor and language deficits and that these arteries should be preserved to prevent infarction [16].

The increasing improvement in the understanding of insular glioma and application of various technologies had made the insular gliomas as an operable entity with acceptable morbidity. However, postoperative motor deficits remain major concern[4]. Reported rates of glioma surgery-related ischemic strokes range from 21% to 80%[9,26]. Regarding the insular gliomas, the perioperative ischemic incidence and its risk factors remains obscure, and its arteries protection skills also need further exploration.

Awake craniotomy has been advocated for intraoperative functional mapping, although it is not possible to use it in every patient. In patients who are unable to undergo awake craniotomy, another method must be used to evaluate of neurological functional integrity under general anesthesia. Motor evoked potentials (MEPs) has been proved to be a valid method to detect motor deficit during neurosurgery[22], and its application in insular glioma resection under general anesthesia needs further investigation.

In this study, we evaluated the incidence of ischemic complications and its risk factors and describe a single surgeon's arteries protection experience in insular gliomas surgery, especially the LLSAs protection. Additionally, we wanted to verify the effectiveness of intraoperative neuromonitoring (IONM) under general anesthesia in insular patients.

Methods

Patient Selection

We conducted a retrospective study to evaluate the incidence and risk factors for surgical ischemic complications in patients of insular gliomas at our center between October 2018 and June 2020. We studied pre- and postoperative clinical, radiological, and IONM data. Berger-Sanai insular glioma classification was used for tumor classification[20]. All tumors were examined histologically and were classified according to World Health Organization (WHO) primary central nervous system tumors. This study was approved by the institutional review board.

Microsurgical technique and key points.

A transcortical approach was used for all insular tumors under general anesthesia, as published before[13]. Regarding the preservation of LLSAs and main M2 branches of MCA, in our experience, there are three key points: First, if the initial segment of LLSAs were encased by the tumor, a small cone-like tumor tissue at the initial segment of LLSAs would be left not only for the preservation proximal branches of LLSAs but also for the support LLSAs to avoid distortion resulting in ischemia (Fig. 1). The cone-like tumor tissue resembles a triangle on postoperative imaging, so it was called the “Residual Triangle”. Second, as we all know, the basal ganglia is adjacent to or even invaded by insular gliomas. In order to achieve maximal safe resection, the artificial profile of basal ganglia (Fig. 2) was made based on the texture of the basal ganglia (orange-yellow colors and partial crisp texture, similar to the Chinese food tofukasu), which had also been described as nutmeg[19] and distal branches of LLSAs to identification the depth of resection. We might call it “Basal Ganglia Reconstruction.” In this way, not only can we avoid direct injury of the pyramidal tract, but we also preserve the distal branches of LLSAs. Finally, the “Sculpting Technique” was used to protection of main branches of M2. Initiatively hemostasis rather than passive hemostasis was used to prevent the damage to the main branches of M2[19]. After the tumor had been resected, the skeletonized main branches of M2 were preserved and suspended in the operative cavity[13]. All the surgical procedures were done with continuously IONM.

Radiological Data

All patients underwent preoperative, postoperative magnetic resonance imaging (MRI). Postoperative MRI, including diffusion weighted imaging (DWI), was performed within 72 hours of surgery. Evaluation of imaging was conducted independently by a neuroradiologist and a neurosurgeon who were each blinded to the clinical course.

The four radiologic characteristics that may be associated with ischemia were evaluated. The initial segment of LLSAs encased by tumor was determined by the relationship of the initial segment of LLSAs and the tumor on T2-weighted images (Fig. 1A). A clear flat inner boundary between the tumor and the ipsilateral putamen was determined to be high clear signal intensity edge on T2-weighted images of tumor. At the plane of the foramen of Monro on T2-weighted images, a vertical line at the midpoint of the posterior limb of the inner capsule was made and the length of the line to the nearest tumor was described as the distance between the lesion and the posterior limb of the internal capsule. Whether the superior limiting sulcus was invaded by the tumor was identified with sagittal and coronal MRI. Volumes and extent of resection (EOR) were calculated as described previously[13].

Intraoperative Neuromonitoring

IONM was performed by two experienced IONM technicians, and SSEPs and continued transcranial MEPs of extremities were monitored in all patients, as described previously[12,27]. We defined a decline in MEP amplitude of more than 50% (not caused by technical issues) as significant deterioration.

Postoperative MRI Ischemic definition and Neurological Outcomes

Areas that appeared hyperintense on DWI and hypointense on Apparent Diffusion Coefficient (ADC) mapping of early postoperative MRI scans were classified as ischemic lesions[5]. Ischemic lesions were classified into 2 categories: Critical Ischemia and No Critical Ischemia. Critical Ischemia is defined as circumscribed areas located in the posterior limb of the internal capsule or corona radiata. No Critical Ischemia is documented for ischemia in other places except for the posterior limb of internal capsule and corona radiata.

The postoperative neurological outcomes were recorded and confirmed by retrospective review of all records. Newly detected neurological deteriorations were considered to be postoperative neurological deficits and were evaluated during the first 7 days and 6 months after surgery.

Statistical Analyses

All statistical analyses were performed with SPSS for Windows software, Version 21.0 (IBM Corp.). Significance was set at $p < 0.05$ for the entire analysis. Kolmorogov–Smirnov test and equal variances test were performed prior to any other statistical analysis. Continuous data with normal distribution were analyzed with Student t test and reported as mean ± SD. Data with non-normal distribution were analyzed with Wilcoxon 2-sample test and reported as median (interquartile range). Categorical data were analyzed using Fisher exact test or Chi-square tests. Multivariate logistic regression analysis was used to evaluate risk factors for developing intraoperative stroke. To assess the relationship between the four surgical indicators and outcomes, we performed Logistic multivariate regression analyses. Any variable with a p value of less than 0.10 by univariate analysis was considered to be a potential independent variable and was included in the multivariate analysis.

Results

Clinical, Demographic Data and Outcomes

75 patients were included in this study. Their mean age was 42.6±12.1 years, and 51 patients (68.0%) were males. 2 patients had surgery for recurrent tumor.41 patients (54.7%) had right-sided tumors. Preoperative new-onset clinical manifestations included seizures (58.7%), occasionally findings (20.0%), limb numbness (14.7%), headache (4.0%), speech deficits (2.7%).The majority of the patients had preoperative Karnofsky Performance Scale (KPS) scores ≧90 (93.3%) and modified Rankin Scale (mRS) ≦ 2 (94.7%). According to Berger-Sanai classification, there were 18 (24.0%) tumors in zone I, 3 tumors (4.0%) in zone II, 1 tumor (1.3%) in zone III, 1 tumor (1.3%) in zone IV, 8 tumors (10.7%) in zone I + II, 13 tumors (17.3 %) in zone I + IV, 3 tumors (4.0%) in zone II + III, 11 tumors (14.7%) in zone III + IV, 17 tumors (22.7%) in giant.

The mean preoperative tumor volume was 57.7±43.4 cm^3. The EOR ≧ 90% was in 56 patients (70.0%). There was no significant difference in preoperative tumor volume ($p>0.05$) or EOR ($p>0.05$) between LGGs and HGGs. The mean EOR was 91.4% in zone 1, 86.3% in zone 2, 94.0% in zone 3, 100% in zone 4, 90.5% in zone I + II, 89.4% in zone I + IV, 92% in zone II + III, 89.1% in zone III + IV, and 89.7% in giant.

The histological composition of tumors was as follows: 47 WHO grade II (62.7%) glioma patients, followed by 17 grade III (22.7%) and 12 grade IV (16.0%) glioma patients. Molecular diagnostics showed isocitrate dehydrogenase (IDH)1/2 mutations in 60 of 74 cases (71.1%), 1p19q co-deletion in 22 of 69 cases (31.9%) and O6-methylguanine-DNA methyltransferase (MGMT) promoter methylation in 49 of 69 cases (71.1%). Postoperatively, with regard to low grade glioma, radiotherapy or chemotherapy was recommended based on the molecular biomarkers and EOR. Regarding to HGG, concurrent chemoradiation therapy was offered in accordance with the Stupp regimen[21].

Complete short and long-term (within 7 days and 6-month post-surgery) follow-up data were available for all these 75 patients. Postoperatively within 7 days, motor deficits were observed in 9 patients (12.0%). Speech disorders were found in 8 of the 34 dominant-side surgery patients (23.5%) following surgery, 4 of these 8 aphasia patients returned to almost normal within 7 days. At 6 months follow-up, motor deficits were observed in 7 patients (9.3%). The verbal function of the other 4 aphasia patients also improved.

Critical Ischemia and its risk factors

Among the 75 patients, postoperative DWI showed evidence of acute ischemia in 44 patients (58.7%), most of which were beneath the resection cavity and with size varied from case to case. Only 11 patients of the 44 ischemic patients were Critical Ischemia. Of the Critical Ischemia, 9 patients (12.0%) of the 75 patients developed new acute motor deficits (Table 1)

Retrospective analysis of preoperative MR images revealed clear flat inner boundaries for 47 of the 75 tumors (62.7%). Critical Ischemia occurred in 2 patients and motor complications occurred in 1 of 47

patients with clear tumor boundaries, which was significantly fewer than those with obscure tumor boundaries (p□0.05).

The initial segment of LLSAs encased by tumor was determined in 51 of the 75 tumors. “Residual Triangle” was found in 43 patients, accounting for 84.3% of encased 51 patients. The volume of “Residual Triangle” ranged from 0.38 to 8.89 cm^3, with its mean value of 1.06 cm^3, accounting for 1.7% of the preoperative tumor volume. The sign of superior limiting sulcus invaded by tumor was identified in 30 of the 75 patients (40.0%). The distance between the lesion and the posterior limb was 4.50±5.05 mm. None of these three neuroimaging factors was found to be significant with the Critical Ischemia.

IONM data were available in all these 75 patients. 11 cases (14.7%) showed 50% decline in MEPs. MEP decline was found to be significant associated with Critical Ischemia (p□0.05) postoperative paralysis (p□ 0.05) and 6 months paralysis (p□0.05), but not No Critical Ischemia (p>0.05) .

After a multivariate analysis for potential risk factors of Critical Ischemia, flat inner edge (OR 0.144 95% CI 0.024, 0.876), and MEPs (<50%) (OR 18.182, 95% CI 3.311, 100.00) were determined to have significant associations with postoperative Critical Ischemia. (Table 2).

Discussion

The insular area is a predilection site for gliomas[28], with insular gliomas accounting for up to 25% of low grade gliomas and 10% of high-grade gliomas[3]. Due to the complex vascular network and functional areas around the insula, the surgical resection of insular gliomas remains a huge challenge for neurosurgeons. Despite this, the standard management of insular gliomas continues to remain maximum resection followed by chemoradiation therapy.

LLSAs, which originates from segment of M1, courses under the anterior perforated substance and generally supply the internal capsule and basal ganglia. The vascular supply of the insula is mainly provided by the M2 branches, which overlie the insular surface[23]. The course of M2 segment along the surface of insula constitutes a rich arterial network, which represents a substantial obstacle to access the insular region[1,7,25], especially, when the arterial network was encased and distorted and wrapped by the tumors. LLSAs may also be encased by the tumor and be a source of vascular supply to the tumor. All these vascular characteristics of insular gliomas make the maximal resection difficult and increase the incidence of ischemia.

Moreover, in contrast to other glioma locations, the insula is largely and frequently supplied by perforating arteries with no collateral flow[18]. There is new evidence that motor deficits frequently arise from ischemia of the pyramidal tract due to compromise of the blood vessels supplying the corona radiata and the internal capsule[5].

As to the insular glioma resection, most of the procedure was done among the main branches of M2, which may cause ischemia to the surrounding structure. Various mechanisms have been proposed for

the development of intraoperative brain ischemia, including direct vascular damage, vasospasm, and kinking of arteries by the retraction of the brain [2,5]. Therefore, the identification and protection of blood vessels is particularly important for insular gliomas resection.

In our experience, as to the insular gliomas, we use different strategies according to the location tumor based on the Berger-Sinai classification. For the anterior location, the protection the initial segment of LLSAs is especially important. If the initial segment of LLSAs was encased by the tumor, which make it difficult to totally resect the tumor and increase the risk of motor deficits[10]. Given our experience, in such situation, we made the “Residual Triangle” at the initial segment of LLSAs to preserve and avoid LLSAs distortion resulting in ischemia[8]. In this study, the multivariate analysis showed no significant association between the encased initial segment of LLSAs and Critical Ischemia. Meanwhile, the volume of “Residual Triangle” less than 2% of the tumor volume, has little influence on the EOR. This may confirm the effectiveness of this strategy for protection of proximal of LLSAs. As to posterior tumor location, the protection of distal of LLSAs is the key point. Due to the basal ganglia was adjacent to or even invaded by the insular gliomas when there was no clear border between the tumor and the basal ganglia, “Basal Ganglia Reconstruction” was made base on the texture of basal ganglia and distal branches of LLSAs, which not only avoided the direct injury of the posterior limb of internal capsule but also preserved the distal branches of LLSAs. Based on the identification of the texture of basal ganglia and distal branches of LLSAs to control the depth of resection, direct injury to the white matter motor fibers is unusual [5], and also the tumor maybe maximally and safely resected. Finally, the protection of main branches of M2 is also important, the “Sculpting Technique” was used to outline the frame of the main branches of M2. In this way, we could cut off the blood supply arteries of the tumor (insular arteries) and protect the arteries that pass through (mainly branches of M2). All these strategies of arteries protection may verify the importance and validity of the protection of supply arteries of critical structure as to the insular glioma resection.

Deep small infarcts are commonly found after glioma surgery[14], which is also true for insular glioma[2]. To achieve maximal resection, surgeon pay much attention to the protection of LLSAs, mainly branches of M2 and the long insular artery, some small artery may be need to be sacrificed which may result in ischemia but not cause neurological deficits. The surgical manipulation among the main branches of M2 might aggravate such situation. The incidence of such small ischemia of insular glioma resection has not been fully revealed and need further investigation. As to insular glioma surgery in this study, ischemic lesions were found in 44 (58.7%) cases on DWI, while Critical Ischemia were in 11 patients. Though the ischemic incidence was higher than some earlier reports[2,5], the insular tumor location had been shown to be the strongest risk factor for the development of intraoperative ischemia, comprising almost all of their cases with ischemia[2]. In other reports, the incidence was as high as 100%[11]. In this report, multivariate analysis showed that the Critical Ischemia incidence was significantly association with clear flat inner boundary. Our explanation may be that the clear flat inner boundary between the tumor and basal ganglia means the basal ganglia haven’t invaded by the tumor yet, the tumor maybe totally resected and the risk of LLSAs damage is less. Obscure boundary means the risk of LLSAs damage

increased greatly. Through the “Basal Ganglia Reconstruction” strategy to control the depth of resection, the risk of distal of LLSAs maybe decrease, especially to the patients with obscure boundary.

Intraoperative detection of impending stroke is important for operation because a prompt response may improve the declines to transient instead of permanent deficits. Although intraoperative MRI was efficient in estimating EOR, its role in detecting ischemic lesions is not recommended[15]. Thus, IONM is one such technique, and multiple studies have verified that IONM parameters including MEP and SSEP are useful and reliable for predicting and preventing ischemic brain injury in neurosurgery[22]. In general, MEP is thought to offer better diagnostic accuracy than SSEP[24]. The monitoring of intraoperative MEPs reveals early ischemia and even prevents it from becoming permanent through the implementation of a therapeutic response, such as holding surgery, irrigating with warm saline, and releasing retraction on the brain parenchyma[5,17]. In this study, MEP 50% decline was found to be significantly associated with Critical Ischemia, postoperative paralysis and three months paralysis, but not with No Critical Ischemia. Thus, intraoperative continue IONM is necessary for insular gliomas.

Study Limitations

The main limitations of our study are its retrospective nature and the limited number of enrolled patients. Moreover, our strategies for insular gliomas on survival need longer time and more cases to certify. Finally, although No Critical Ischemia has no effect on motor deficits, its influence on neurocognitive functions needs further study.

Conclusion

For insular gliomas resection, the protection of main branches of MCA is important. The surgical manipulations among main branches of M2 and sacrificed small arteries might cause ischemia uncovered by postoperative DWI. Although this type of ischemia may not always result in neurological deficits, its impact needs further study. Through strategies such as “Residual Triangle” at the initial segment of LLSAs, “Basal Ganglia Reconstruction” and “Sculpting Technique” to protect distal branches of LLSAs and main branches of M2, maximal resection of insular gliomas with minimum operative complications may be achieved. Furthermore, intraoperative continue IONM is recommended as clinical routine for insular gliomas resection.

Declarations

Acknowledgments

We thank all of the patients who trusted us, and all of the doctors who helped in this study.

Compliance with ethical standards

Conflict of interest

The authors declare that they have no conflicts of interest.

Ethical standards

This study was approved by the Institutional Review Board of Beijing Tiantan Hospital.

Informed consent

Patient informed consents were waived due to the retrospective nature of the study.

References

1. Benet A, Hervey-Jumper SL, Sanchez JJ, Lawton MT, Berger MS (2016) Surgical assessment of the insula. Part 1: surgical anatomy and morphometric analysis of the transsylvian and transcortical approaches to the insula. Journal of neurosurgery 124:469-481. https://doi.org/10.3171/2014.12.jns142182.
2. Berger A, Tzarfati G, Costa M, Serafimova M, Korn A, Vendrov I, Alfasi T, Krill D, Aviram D, Ben Moshe S, Kashanian A, Ram Z, Grossman R (2019) Incidence and impact of stroke following surgery for low-grade gliomas. Journal of neurosurgery:1-9. https://doi.org/10.3171/2019.10.jns192301.
3. Duffau H, Capelle L (2004) Preferential brain locations of low-grade gliomas. Cancer 100:2622-2626. https://doi.org/10.1002/cncr.20297.
4. Gempt J, Förschler A, Buchmann N, Pape H, Ryang YM, Krieg SM, Zimmer C, Meyer B, Ringel F (2013) Postoperative ischemic changes following resection of newly diagnosed and recurrent gliomas and their clinical relevance. Journal of neurosurgery 118:801-808. https://doi.org/10.3171/2012.12.jns12125.
5. Gempt J, Krieg SM, Hüttinger S, Buchmann N, Ryang YM, Shiban E, Meyer B, Zimmer C, Förschler A, Ringel F (2013) Postoperative ischemic changes after glioma resection identified by diffusion-weighted magnetic resonance imaging and their association with intraoperative motor evoked potentials. Journal of neurosurgery 119:829-836. https://doi.org/10.3171/2013.5.jns121981.
6. Hentschel SJ, Lang FF (2005) Surgical resection of intrinsic insular tumors. Neurosurgery 57:176-183; discussion 176-183. https://doi.org/10.1227/01.neu.0000163603.70972.ab.
7. Hervey-Jumper SL, Li J, Osorio JA, Lau D, Molinaro AM, Benet A, Berger MS (2016) Surgical assessment of the insula. Part 2: validation of the Berger-Sanai zone classification system for predicting extent of glioma resection. Journal of neurosurgery 124:482-488. https://doi.org/10.3171/2015.4.jns1521.
8. Hirono S, Ozaki K, Ito D, Matsutani T, Iwadate Y (2018) Hammock Middle Cerebral Artery and Delayed Infarction in Lenticulostriate Artery After Staged Resection of Giant Insular Glioma. World neurosurgery 117:80-83. https://doi.org/10.1016/j.wneu.2018.05.226.
9. Jakola AS, Berntsen EM, Christensen P, Gulati S, Unsgård G, Kvistad KA, Solheim O (2014) Surgically acquired deficits and diffusion weighted MRI changes after glioma resection–a matched case-control

study with blinded neuroradiological assessment. PloS one 9:e101805. https://doi.org/10.1371/journal.pone.0101805.

10. Kawaguchi T, Kumabe T, Saito R, Kanamori M, Iwasaki M, Yamashita Y, Sonoda Y, Tominaga T (2014) Practical surgical indicators to identify candidates for radical resection of insulo-opercular gliomas. Journal of neurosurgery 121:1124-1132. https://doi.org/10.3171/2014.7.jns13899.
11. Kumabe T, Higano S, Takahashi S, Tominaga T (2007) Ischemic complications associated with resection of opercular glioma. Journal of neurosurgery 106:263-269. https://doi.org/10.3171/jns.2007.106.2.263.
12. Li Z, Fan X, Wang M, Tao X, Qi L, Ling M, Guo D, Qiao H (2019) Prediction of postoperative motor deficits using motor evoked potential deterioration duration in intracranial aneurysm surgery. Clinical Neurophysiology 130:707-713. https://doi.org/10.1016/j.clinph.2019.02.010.
13. Li Z, Li G, Liu Z, Pan Y, Hou Z, Wu L, Huang Z, Zhang Y, Xie J (2020) Transcortical approach for insular gliomas: a series of 253 patients. Journal of neuro-oncology 147:59-66. https://doi.org/10.1007/s11060-020-03390-2.
14. Loit MP, Rheault F, Gayat E, Poisson I, Froelich S, Zhi N, Velut S, Mandonnet E (2019) Hotspots of small strokes in glioma surgery: an overlooked risk? Acta neurochirurgica 161:91-98. https://doi.org/10.1007/s00701-018-3717-3.
15. Masuda Y, Akutsu H, Ishikawa E, Matsuda M, Masumoto T, Hiyama T, Yamamoto T, Kohzuki H, Takano S, Matsumura A (2018) Evaluation of the extent of resection and detection of ischemic lesions with intraoperative MRI in glioma surgery: is intraoperative MRI superior to early postoperative MRI? Journal of neurosurgery 131:209-216. https://doi.org/10.3171/2018.3.jns172516.
16. Moshel YA, Marcus JD, Parker EC, Kelly PJ (2008) Resection of insular gliomas: the importance of lenticulostriate artery position. Journal of neurosurgery 109:825-834. https://doi.org/10.3171/jns/2008/109/11/0825.
17. Neuloh G, Simon M, Schramm J (2007) Stroke prevention during surgery for deep-seated gliomas. Neurophysiologie clinique = Clinical neurophysiology 37:383-389. https://doi.org/10.1016/j.neucli.2007.09.002.
18. Phan TG, Donnan GA, Wright PM, Reutens DC (2005) A digital map of middle cerebral artery infarcts associated with middle cerebral artery trunk and branch occlusion. Stroke 36:986-991. https://doi.org/10.1161/01.STR.0000163087.66828.e9.
19. Rey-Dios R, Cohen-Gadol AA (2013) Technical nuances for surgery of insular gliomas: lessons learned. Neurosurg Focus 34:E6. https://doi.org/10.3171/2012.12.FOCUS12342.
20. Sanai N, Polley MY, Berger MS (2010) Insular glioma resection: assessment of patient morbidity, survival, and tumor progression. Journal of neurosurgery 112:1-9. https://doi.org/10.3171/2009.6.jns0952.
21. Stupp R, Mason WP, van den Bent MJ, Weller M, Fisher B, Taphoorn MJ, Belanger K, Brandes AA, Marosi C, Bogdahn U, Curschmann J, Janzer RC, Ludwin SK, Gorlia T, Allgeier A, Lacombe D,

Cairncross JG, Eisenhauer E, Mirimanoff RO (2005) Radiotherapy plus concomitant and adjuvant temozolomide for glioblastoma. The New England journal of medicine 352:987-996. https://doi.org/10.1056/NEJMoa043330.

22. Szelényi A, Langer D, Kothbauer K, De Camargo AB, Flamm ES, Deletis V (2006) Monitoring of muscle motor evoked potentials during cerebral aneurysm surgery: intraoperative changes and postoperative outcome. Journal of neurosurgery 105:675-681. https://doi.org/10.3171/jns.2006.105.5.675.
23. Tanriover N, Rhoton AL, Jr., Kawashima M, Ulm AJ, Yasuda A (2004) Microsurgical anatomy of the insula and the sylvian fissure. Journal of neurosurgery 100:891-922. https://doi.org/10.3171/jns.2004.100.5.0891.
24. Thomas B, Guo D (2017) The Diagnostic Accuracy of Evoked Potential Monitoring Techniques During Intracranial Aneurysm Surgery for Predicting Postoperative Ischemic Damage: A Systematic Review and Meta-Analysis. World neurosurgery 103:829-840.e823. https://doi.org/10.1016/j.wneu.2017.04.071.
25. Türe U, Yaşargil MG, Al-Mefty O, Yaşargil DC (2000) Arteries of the insula. Journal of neurosurgery 92:676-687. https://doi.org/10.3171/jns.2000.92.4.0676.
26. Voglis S, Müller T, van Niftrik CHB, Tosic L, Neidert MC, Regli L, Bozinov O (2020) Impact of additional resection on new ischemic lesions and their clinical relevance after intraoperative 3 Tesla MRI in neuro-oncological surgery. Neurosurg Rev. https://doi.org/10.1007/s10143-020-01399-9.
27. Wang M, Li Z, Fan X, Tao X, Qi L, Ling M, Guo D, Qiao H (2020) A prediction of postoperative neurological deficits following intracranial aneurysm surgery using somatosensory evoked potential deterioration duration. Neurosurg Rev 43:293-299. https://doi.org/10.1007/s10143-019-01077-5.
28. Yasargil MG, von Ammon K, Cavazos E, Doczi T, Reeves JD, Roth P (1992) Tumours of the limbic and paralimbic systems. Acta neurochirurgica 118:40-52. https://doi.org/10.1007/BF01400725.

Tables

Table 1 Comparison of baseline demographics and clinical characteristics of patients who developed Critical Ischemia and those who did not

Variable	Total	Ischemia		P value
		No Critical Ischemia and no ischemia	Critical Ischemia	
	75	64	11	
Age	42.6±12.1	41.9±12.5	46.5±8.7	0.15
Sex				
Male	51 (68.0)	44 (68.8)	7 (63.2)	0.74
Female	24 (32.0)	20 (31.3)	4 (36.4)	
PA				
2	47(62.7	41(64.1)	6(54.5)	0.55
3 or 4	28(37.3	23(35.9	5(45.5)	
R-L				
L	34 (45.3)	29 (45.3)	5 (45.5)	0.99
R	41 (54.7)	35 (54.7)	6 (54.5)	
Flat Inner Boundary				
Yes	47 (62.7)	45 (70.3)	2 (18.2)	0.001*
No	28 (37.3)	19 (29.7)	9 (81.8)	
Enhancement				
Yes	22 (29.3)	16 (25.0)	6 (54.5	0.047
No	53 (70.7	48 (75.0	5 (45.5)	
Intact Superior Limiting Sulcus				
Yes	45(60.0)	41(64.1)	4 (36.4)	0.083
No	30(40.0)	23(35.9)	7 (63.6)	
Encased of initial of LLSAs				
Yes	51(68.0)	45(70.3)	6 (54.5)	0.3
No	24(32.0)	19 (29.7)	5(45.5)	
Distance to the posterior limb(mm)	4.40±5.05	4.93±4.68	1.96±6.51	0.97
Preop tumor vol (mm^3)	57.7±43.4	58.38±42.83	53.95±42.58	0.43
Hypertension				
Yes	13(17.3)	10 (15.6)	3(27.3)	0.35
No	62 (82.7)	54 (84.4)	8 (72.7)	
Diabetes mellitus				
Yes	6 (8.0)	4 (6.3	2(18.2	0.18
No	69 (92.0)	60 (93.8	9(81.8	
Smoking				
Yes	27 (36.0	23(35.9	4(36.4	0.98
No	48 (64.0	41(64.1	7(63.6	
Preop KPS				
≥90	70(93.3)	61(95.3)	9(81.8)	0.097
90	5(6.7)	3 (4.7)	2(18.2)	
Preop mRS				
2	72(96.0)	61(95.3)	11(100.0)	0.46
≥2	3(4.0)	3(4.7)	0 0.0	
BMI in kg/m^2	23.9±3.0	24.1±3.1	22.7±2.4	0.24
MEP (<50%)				
No	64(85.3)	60(93.8)	4 (36.4)	<0.001*
Yes	11(14.7)	4(6.3)	7(63.6)	
EOR				
≧90%	56 (74.7)	49 (76.6)	7 (63.6)	0.36
<90%	19(25.3)	15(23.4)	4 (36.4)	
IDH				
Yes	60(81.1)	51(81.0)	9 (81.8)	0.95
No	14(18.9)	12(19.0)	2 (18.2)	
1p/19q				
Yes	22 (31.9)	19(31.1)	3 (37.5)	0.72
No	47 (68.1)	42 (68.9)	5 (62.5)	
MGMT				

Yes	49 (71.0)	42 (68.9	7 (87.5)	0.27
No	20 (29.0)	19 (31.1)	1 (12.5)	

PA pathology, LLSAs lateral lenticulostriate arteries, KPS karnofsky performance status, mRS modified Rankin Scale, BMI body mass index, MEP Motor evoked potentials, EOR extent of resection, IDH isocitrate dehydrogenase, MGMT O6-methylguanine-DNA methyltransferase.
*These values are the significant at statistical analysis.

Table 2 Multivariate logistic regression analysis for estimating risk factors for Critical Ischemia

Varibles	Unadjusted OR	P value	Adjusted OR	P value
Flat inner Boundary	0.094 (0.019, 0.476)	0.004*	0.144(0.024,0.876)	0.035*
MEP (<50%)	26.316(5.348, 125)	<0.001*	18.182 (3.311, 100)	<0.001*

MEP Motor evoked potentials,
*These values are the significant at statistical analysis.

Figures

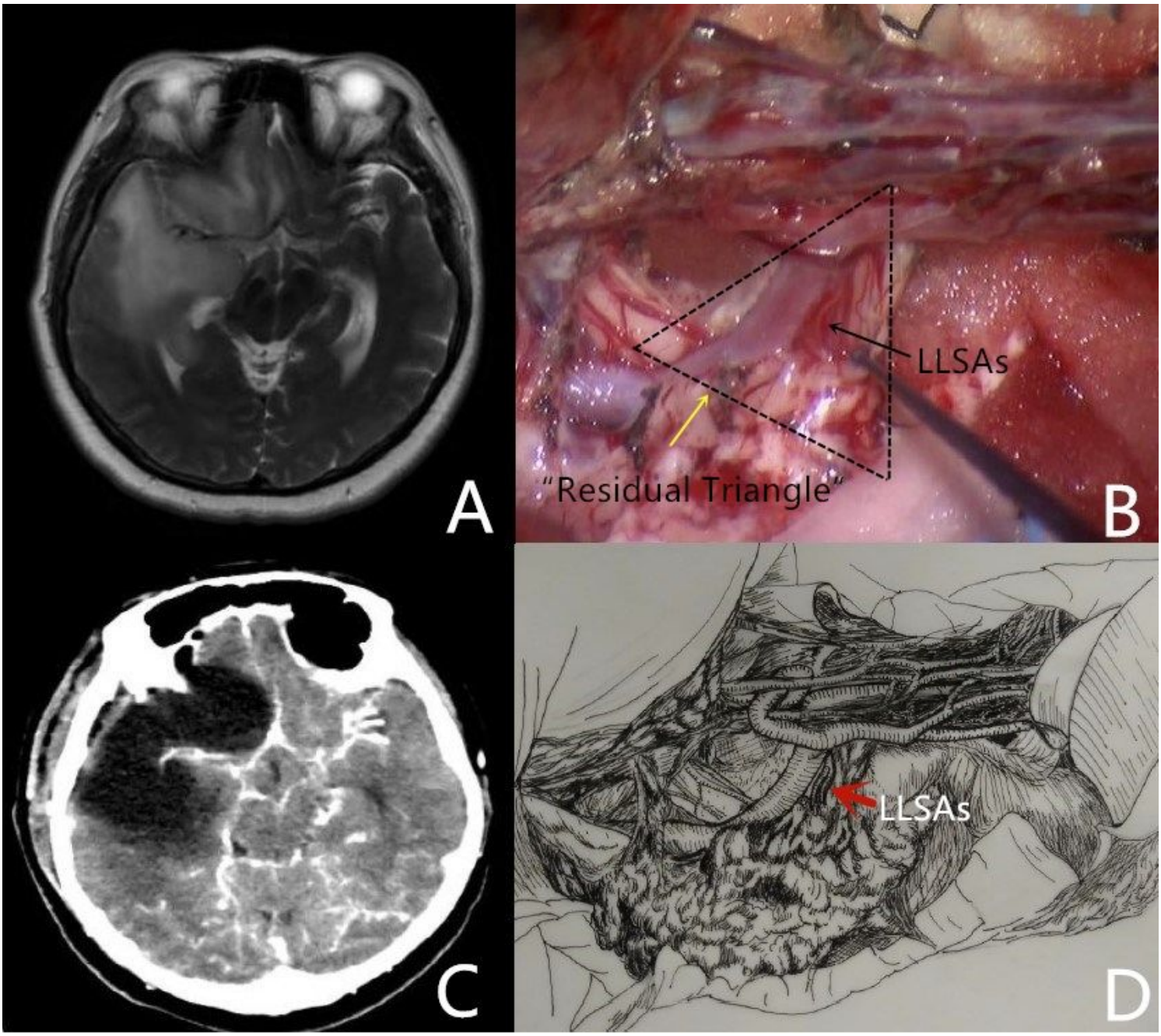

Figure 1

A, T2-weighted images showed that the initial segment of LLSAs encased by the glioma. B, Intraoperative imaging showed that a small cone-like tumor tissue at the initial segment of LLSAs (black arrow) would be left, and outlined the "Residual Triangle" (dotted triangle, yellow arrow). C, Postoperative CT scan demonstrated that the cone-like tumor tissue support MCA. D, Hand drawing displayed the "Residual Triangle" and LLSAs.

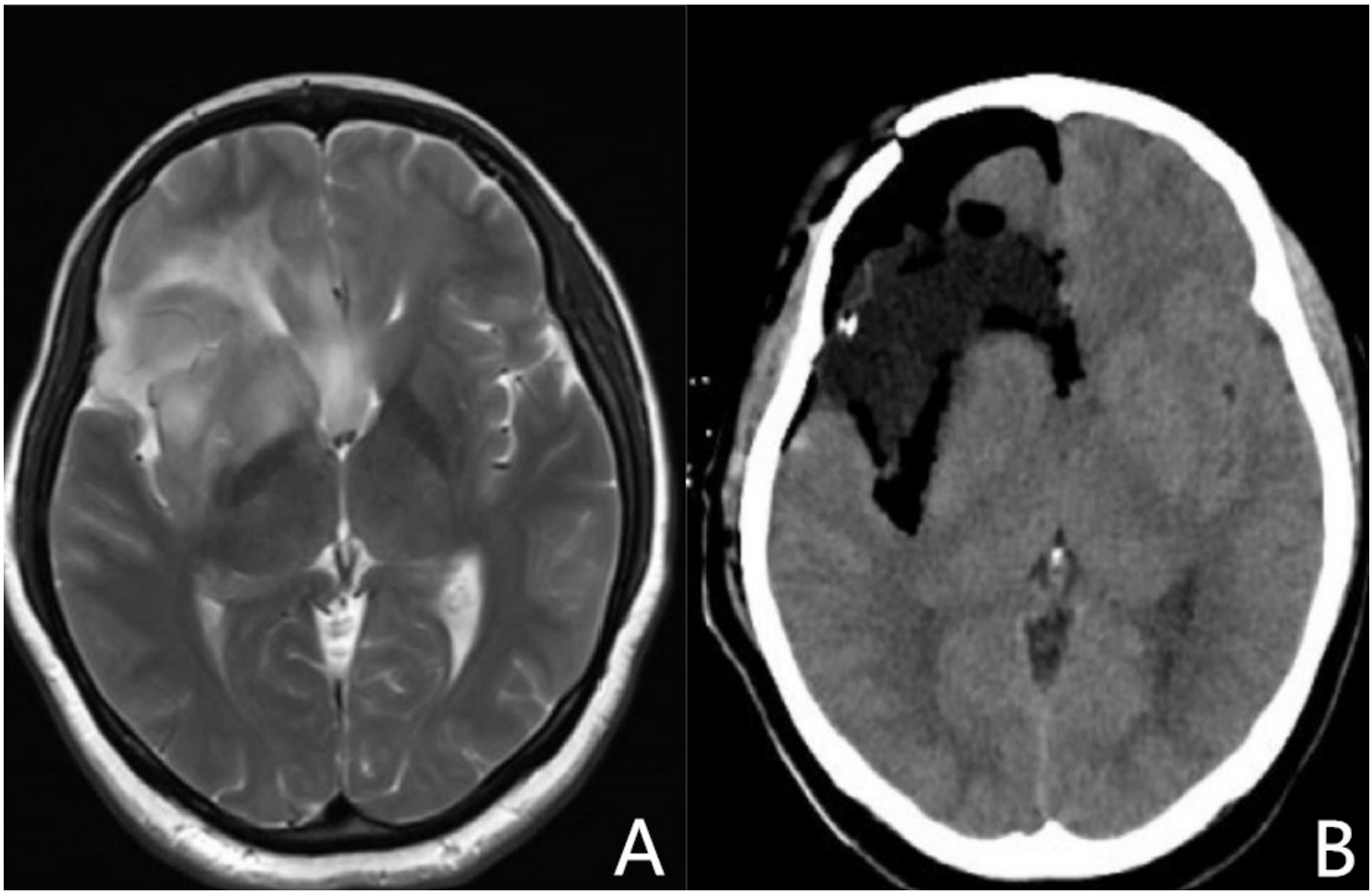

Figure 2

A, Preoperative MRI showed that basal ganglia was invaded by insular gliomas. B, Postoperative CT scan demonstrated the artificial profile of basal ganglia which was called “Basal Ganglia Reconstruction”.