Hemisensory paresthesia as the initial symptom of a SARS-Coronavirus-2 infection. A Case report.

Myriam Herrnberger (mdilsen@hotmail.com)

Department of Neurology, University Medical Center of the Johannes Gutenberg University Mainz, Germany

Nadine Durmazel

Medical group practice for primary care, Alzey, Germany

Frank Birklein

Department of Neurology, University Medical Center of the Johannes Gutenberg University Mainz, Germany

---

Case Report

Keywords: Covid-19, SARS-CoV-2, Encephalitis

Posted Date: May 3rd, 2020

DOI: https://doi.org/10.21203/rs.3.rs-26305/v1

Abstract

Neurological symptoms might be associated with a Covid-19 infection. There are frequent reports in the last weeks. The neurological symptoms range from harmless side effects of a viral infection to meningoencephalitis and acute haemorrhagic necrotizing encephalopathy.

Our patient reported burning headache and paresthesia as the initial symptoms mainly without other signs of viral infection like cough or fever. Such an initial neurological presentation seems to be rare. Most cases have neurological symptoms which can be expected after severe systemic viral infections like fever associated headache. Many COVID-19 patients with mild disease are at home and the further course is unknown. Our case shows, that neurological symptoms can be the first manifestation of an COVID-19 disease. While restricted paraesthesia has been reported in SARS-CoV-2 infections, hemisymptoms have not been described as initial symptoms.

Introduction

Neurological symptoms might be associated with a Covid-19 Infection. There are frequent reports in the last weeks. The neurological symptoms range from harmless side effects of a viral infection to meningoencephalitis [1] and acute haemorrhagic necrotizing encephalopathy [2]. The most important report comes from Wuhan [3]. Mao et al. retrospectively assessed 214 patients and 34.6% of them had neurological symptoms. The most common symptoms were unspecific like dizziness and headache, but also taste and smell impairment. Neurological symptoms were more common in severe cases. A case report from Japan confirms the neurotropic potential of SARS-CoV-2. A 24-year-old-man developed a meningoencephalitis [1]. On day 9 of the infection, the patient had a positive PCR in the cerebrospinal fluid but not in the nasopharyngeal swab. Initially he felt headache, fatigue and fever. In the later course there was a loss of consciousness and seizures which led to hospitalisation. Helms et al. presented MRI imaging and CSF findings in severely affected COVID-19 patients [4].

Case Report

We report the case of a 31-years-old woman who presented with a neurological manifestation without fever, cough or feeling sick. No previous illnesses are known. The symptoms began with a holocephalic burning headache after awakening. She described the burning character of the headache as something the patient never felt before. On day 2, paraesthesia of the left half of the face and left arm began, about 6 hours later paraesthesia included the left leg. The headache persisted and was of moderate pain (5/10 NRS). There was no response to acetaminophen, ibuprofen or dipyrone.

The patient was admitted to the hospital since paraesthesia worsened. Neurological examination confirmed hypesthesia of the left face and left arm and no further symptoms. Immediately a cerebral MRI was performed and showed normal brain morphology, no meningeal enhancement and normal arterial and venous vessels. The routine laboratory blood tests including renal and liver function, CRP, blood cell

count and muscle enzymes were normal. The CSF cell count was slightly increased (7 per microliter) with a lymphocytic cell pattern. Other CSF parameters including oligoclonal bands and standard microbiological and virologic tests were negative.

The patient is a general practitioner and harbours an increased risk of infection, so that a swab for SARS-CoV-2 and other respiratory viruses was taken. Only the PCR for SARS-CoV-2 was positive. Unfortunately, no PCR investigation of the CSF was performed. The infection source remained unknown.

On day 3 the patient was discharged home with stable clinical symptoms. Three days later she developed a significant fatique still without fever. A minor cough occurred. After 17 days there was a worsening with chest pain. Laboratory and ECG testing disclosed heart ischemia, chest x-ray showed no abnormalities. The suspected diagnosis was pleuritis. Blood cell count revealed a moderate leucocytosis and increased lactate dehydrogenase level. Par- and hypoesthesia of the left face are still present now for 3 weeks (see fig. 1).

Discussion

It is assumed that patients with neurological symptoms showed more severe infections. Our patient reported burning headache and paresthesia as the initial symptoms mainly without other signs of viral infection like cough or fever. Such an initial neurological presentation seems to be rare. Most cases have neurological symptoms which can be expected after severe systemic viral infections like fever associated headache [5], smell loss and even postinfectious GBS [6]. Further strokes, vigilance reduction and seizures, which could be primary to the infection or due to complications like hypoxic brain damage occur [3, 4, 7].

Symptoms and CSF of our patient suggested encephalitis. MRI, however showed no abnormalities. One severely affected patient from Japan with symptoms fitting to meningoencephalitis had 12 cells per microliter in the CSF and the MRI findings indicated a ventriculitis and encephalitis [1]. MRI findings in the report from Helms et al. were leptomeningeal enhancement in 8 patients and perfusion abnormalities in all 11 examined patients [4]. None of these patients had CSF pleocytosis.

Many COVID-19 patients with mild disease are at home and the further course is unknown. Our case shows, that neurological symptoms can be the first manifestation of an COVID-19 disease. While restricted paraesthesia has been reported in SARS-CoV-2 infections, hemisymptoms have not been described as initial symptoms.

The normal MRI disclosed stroke, haemorrhage or demyelination as a cause of the sensory loss on the hemibody. Although very small lesions can be overlooked one might speculate that the symptoms might be due to direct neurotropism of the virus. How the virus selectively reaches the somatosensory system of the brain is not known. Like other Coronaviruses, SARS-CoV-2 probably reaches the nervous system via different routes [7] [8], particularly via retrograde axonal path as suggested by taste and olfaction loss.

The present case underlines that it is important to consider a neurological manifestation as the leading symptoms in SARS-CoV-2 infections.

References

1. Moriguchi T, Harii N, Goto J et al. A first case of meningitis/encephalitis associated with SARS-Coronavirus-2. International Journal of Infectious Diseases 2020; 94: 55-58. doi:https://doi.org/10.1016/j.ijid.2020.03.062
2. Poyiadji N, Shahin G, Noujaim D et al. COVID-19-associated Acute Hemorrhagic Necrotizing Encephalopathy: CT and MRI Features. Radiology 2020. doi:10.1148/radiol.2020201187: 201187. doi:10.1148/radiol.2020201187
3. Mao L, Jin H, Wang M et al. Neurologic Manifestations of Hospitalized Patients With Coronavirus Disease 2019 in Wuhan, China. JAMA Neurology 2020. doi:10.1001/jamaneurol.2020.1127. doi:10.1001/jamaneurol.2020.1127
4. Helms J, Kremer S, Merdji H et al. Neurologic Features in Severe SARS-CoV-2 Infection. New England Journal of Medicine 2020. doi:10.1056/NEJMc2008597. doi:10.1056/NEJMc2008597
5. Marchioni E, Tavazzi E, Bono G et al. Headache Attributed to Infection: Observations on the IHS Classification (ICHD-II). Cephalalgia 2006; 26: 1427-1433. doi:10.1111/j.1468- 2982.2006.01213.x
6. Zhao H, Shen D, Zhou H et al. Guillain-Barre syndrome associated with SARS-CoV-2 infection: causality or coincidence? The Lancet Neurology 2020. doi:10.1016/s1474-4422(20)30109-5. doi:10.1016/s1474-4422(20)30109-5
7. Wu Y, Xu X, Chen Z et Nervous system involvement after infection with COVID-19 and other coronaviruses. Brain Behav Immun 2020. doi:10.1016/j.bbi.2020.03.031: S0889- 1591(0820)30357-30353. doi:10.1016/j.bbi.2020.03.031
8. Desforges M, Le Coupanec A, Dubeau P et al. Human Coronaviruses and Other Respiratory Viruses: Underestimated Opportunistic Pathogens of the Central Nervous System? Viruses 2019; 12. doi:10.3390/v12010014

Declarations

Corresponding author: Dr. Myriam Herrnberger, Klinik und Poliklinik für Neurologie, Langenbeckstr. 1, 55131 Mainz, Germany. E-mail: Myriam.Herrnberger@unimedizin-mainz.de

Authors' contributions: All authors were equally involved in data gathering and manuscript writing.

Conflicts of interest: The authors declare that they have no conflict of interest.

Funding: No funding applicable to this article

Consent: Written informed consent was obtained from the patient for publication of this case report.

Figures

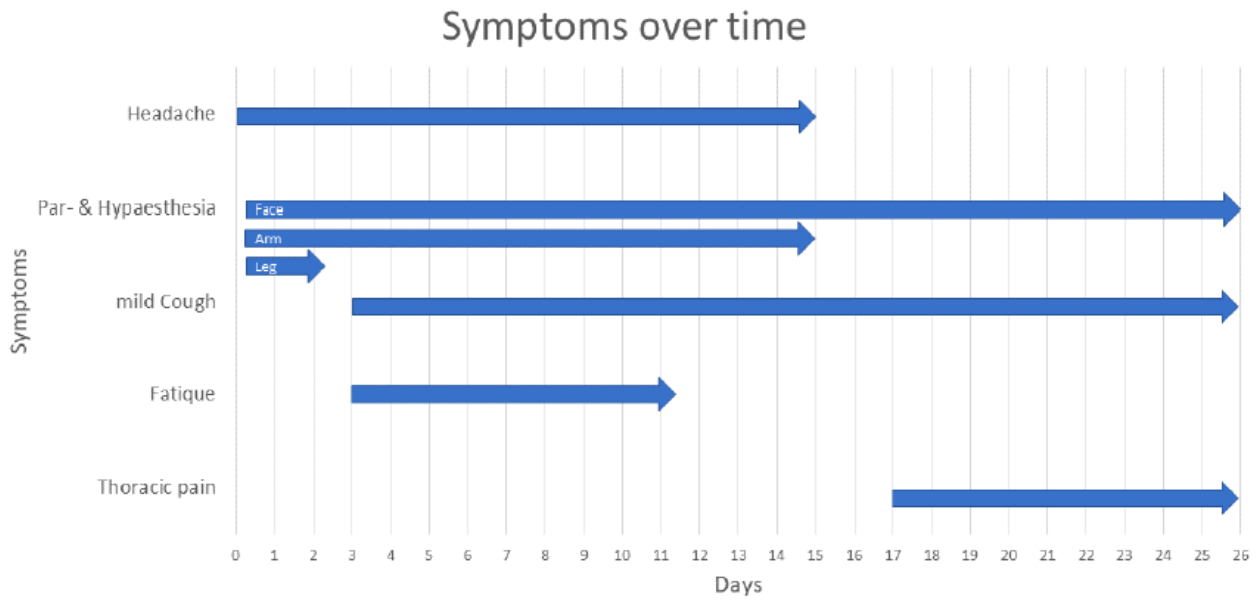

Figure 1

All symptoms that occurred in days.