Validation of a shortened MR imaging protocol for pediatric spinal pathology

Winnie Shu Yu Wu
Faculty of Medicine, University of Ottawa
Elka Miller
Department of Medical Imaging, University of Ottawa, CHEO
Julie Hurteau-Miller
Department of Medical Imaging, University of Ottawa, CHEO
Madhura Thipse
CHEO Research Institute
Cassandra Kapoor
Department of Medical Imaging, University of Ottawa, CHEO
Richard Webster
CHEO Research Institute
David McAuley
Division of Pediatric Neurosurgery, Department of Surgery, CHEO
Albert Tu (albert.d.tu@gmail.com)
Division of Pediatric Neurosurgery, Department of Surgery, CHEO

Research Article

Keywords: Spine, fast imaging, imaging, MRI, general anesthesia, pediatrics, quality improvement

Posted Date: March 6th, 2023

DOI: https://doi.org/10.21203/rs.3.rs-2631622/v1

Additional Declarations: No competing interests reported.

Version of Record: A version of this preprint was published at Child's Nervous System on March 31st, 2023. See the published version at https://doi.org/10.1007/s00381-023-05940-1.

Abstract

Objective

Conventional pediatric spine MRI protocols have multiple sequences resulting in long acquisition times. Sedation is consequently required. This study evaluates the diagnostic capability of a limited MRI spine protocol for selected common pediatric indications.

Methods

Spine MRIs at CHEO between 2017 and 2020 were reviewed across pediatric patients younger than four years old. Two blinded neuroradiologists reviewed limited scan sequences and results were independently compared to previously reported findings from the complete imaging series. T2 sagittal sequences from the craniocervical junction to sacrum and T1 axial sequence of the lumbar spine constitute the short protocol, with the outcomes of interest being cerebellar ectopia, syrinx, level of conus, filum < 2mm, fatty filum, and spinal dysraphism.

Results

105 studies were evaluated in 54 male and 51 female patients (mean age 19.2 months). The average combined scan time of the limited sequences was 15 minutes compared to 35 minutes for conventional protocols (delta = 20 minutes). The average percent agreement between full and limited sequences was > 95% in all but identifying a filum < 2mm, where the percent agreement was 87%. Using limited MR sequences had high sensitivity (> 0.91) and specificity (> 0.99) for the detection of cerebellar ectopia, syrinx, fatty filum, and spinal dysraphism.

Conclusion

This study demonstrates that selected spinal imaging sequences allow for consistent and accurate diagnosis of specific clinical conditions. A limited spine imaging protocol has potential as a screening test to reduce the need for full sequence MRI scans. Further work is needed to determine utility of selected imaging for other clinical indications.

Introduction

MRI is the imaging modality of choice for many pediatric nervous system pathologies. The acquisition of high quality sequences often requires long study times and that patients remain immobile. Young children and patients with developmental delay or mental health concerns may struggle with evaluation, and routinely require anesthesia to perform traditional MRI scans[1–4]. While sedating techniques in

pediatric patients have greatly improved over time, they remain not without risk[1–5]. In addition, the need for general anesthetic and airway support further risks aerosolizing pathogens that may endanger health care providers and has recently become a point of much greater concern[6].

Simplified imaging protocols have the potential to reduce the overall duration of studies and potentially obviates the need and inherent risks of sedation. Fast-brain MR imaging has been thoroughly described and it is actively being used alongside conventional brain MRI protocols to monitor abnormalities such as hydrocephalus, macrocephaly, Chiari malformation, intracranial cysts, and ventricular shunt malfunction[7–24]. The current literature on rapid spine MRI protocols is very limited and has not been validated in pediatric populations[15–24]. The aim of this study was to evaluate if a shortened imaging protocol would provide the adequate information to screen for specific pathologies that require attention for clinical management.

Methods

Demographic Data

A search of the Medical Imaging PACS system was conducted to identify clinical and imaging records of all children 0–4 years of age who underwent a non-contrast enhanced spine MRI either with or without sedation between January 1, 2017 to December 31, 2020. We limited our population to patients < 4 years old, given that this group would most likely benefit from undergoing a shortened MRI sequence due to their propensity for intolerance of prolonged imaging studies. Studies were excluded if i) a contrast agent was administered, ii) the images did not capture the entire spine, or iii) the scan sequences were incomplete (ie. study aborted). This validation study was approved by the institutional review board of the Children's Hospital of Eastern Ontario (CHEO).

Imaging acquisition and image selection

Studies were acquired on 1.5 T (Sigma HDxt, General Electric Healthcare Technologies, Waukesha, WI, USA 16.0) and 3T MRI scanners (Magnetom Skyra, Siemens Healthcare, Erlangen, Germany) using routine departmental protocols. The standard full spine MRI protocol included upper sagittal T1, upper sagittal T2, lower sagittal T1, lower sagittal T2, upper axial T1, upper axial T2, lower axial T1, and lower axial T2 to image the entire spine. The limited spine MRI protocol was developed by consensus opinion of the lead authors (EM, JHM, AT) and included a sagittal T2 weighted image of the entire spine and an axial T1 weighted image of the lumbosacral spine (Table 1).

Table 1
Sequences and duration of sequence per study

Full Spine MRI Protocol Sequence	Full Spine MRI Protocol Time (mins)	Limited Spine MRI Protocol Sequence (mins)	Number of Slices	Slice thickness	TR	TE
Upper Sag T1	4–6		12	2mm gap 0.3mm	350-650ms (1.5T) 650-950ms (3T)	minimum
Upper Sag T2	4–6	4–6	12	2mm gap 0.3mm	> 2000ms	100ms
Lower Sag T1	4–6		12	2mm gap 0.3mm	350-650ms (1.5T) 650-950ms (3T)	minimum
Lower Sag T2	4–6	4–6	12	2mm gap 0.3mm	> 2000ms	100ms
Upper Ax T1	4–6		~ 30	3-5mm gap 1mm	350-650ms (1.5T) 650-950ms (3T)	minimum
Upper Ax T2	4–6		~ 30	3-5mm gap 1mm	> 2000ms	100ms
Lower Ax T1	4–6	4–6	~ 30	3-5mm gap 1mm	350-650ms (1.5T) 650-950ms(3T)	minimum
Lower Ax T2	4–6		~ 30	3-5mm gap 1mm	> 2000ms	100ms

Limited Protocol Determination

Consensus opinion (AT, EM, JHM, DM) was used to determine findings with potentially greatest yield for evaluation with limited spinal MRI. Features including patient age range most likely to be intolerant of long studies, conditions where screening could potentially circumvent further evaluation, need for repeat imaging, and commonality of clinical conditions were all considered. Features for specific review on limited sequence were: the presence or absence of Chiari I malformation (tonsillar ectopia > 5mm), syrinx, spinal level of conus medullaris (n), presence of fatty infiltration of the filum, normal filum (< 2mm width), and the presence or absence of any type of spinal dysraphism. Features were scored for presence on a binary basis (y/n) with the exception of the presence of spinal dysraphism which was scored for presence (y/n) as well as qualitatively (ie. description).

Imaging Analysis

The limited MRI sequences were independently reviewed by two senior pediatric neuroradiologists (EM and JH each with > 20 years each of experience). Reviewers were blinded to the pre-existing report on the complete study, as well as any sequences other than those included in the limited protocol. Ten studies were reviewed by both imaging reviewers to ensure inter-rater reliability. Each reader then reviewed 50 MRI studies. The pre-existing radiology reports were reviewed independently by authors (WW, MT) who were blinded to the findings of the imaging reviewers. Ten patient records were reviewed by both the reviewers to ensure reasonable inter-rater reliability. Further information in the form of patient demographics (age at time of study, gender), sedation status (none vs general anesthesia) and clinical indication for investigation were also recorded. Study data were collected and managed using REDCap electronic data capture tools hosted at CHEO.

Discrepancies between the findings of the limited protocol with full MRI spine reports were formally reviewed by the authors and reconciled by group consensus. Discrepancies were classified as resulting from misdiagnosis or “true misses’ on limited protocol, or if they resulted from misinterpretation of the written report. Errors resulting from report misinterpretation were reviewed by lead authors (EM and AT) and recategorized appropriately.

Statistical methods

Sample size was predetermined assuming a 10% clinical difference between limited and full scan sequences. For the percent agreement metric, a sample size of 105 studies was adequate to determine a difference, at a 95% CI level. PRISM and Microsoft Excel were used to carry out statistical analysis as appropriate.

Results

A total of 128 patient MRI records met our search criteria. Twenty patients were excluded as a contrast agent (gadolinium) was administered, and the last 3 studies were excluded as we had met our target sample size. The 105 MRI studies that fit the inclusion criteria were performed in 54 male and 51 female patients. Patients scanned with anesthesia accounted for 67% (70/105; 95% CI: 57–75) and patients scanned without accounted for 33% (35/105; 95% CI: 25–43) of this cohort. The mean age at time of MRI

scan was 19.2 months (range: 0.13–46.8 months) with an average age of 27.8 and 1.44 months for the with and without anesthesia groups. The most common clinical indications for spinal imaging were workup for sacral dimple, lipomyelomeningocele, low lying conus, lipoma, spinal dysraphism, constipation/urinary incontinence, and neuroblastoma (Table 2).

Table 2
Clinical indications for spinal imaging

Clinical Indication for imaging	Number of studies	Percentage of studies without discrepancy
Sacral Dimple, Lipomyelomeningocele, Low Lying Conus, Lipoma, Spinal Dysraphism	34	91.2%
Constipation/Urinary Incontinence	12	100%
Neuroblastoma	8	100%
Infantile Idiopathic/Congenital Scoliosis	5	80%
Cyst	4	100%
VACTERL	3	66.7%
Chiari I Malformation	2	0%
Infection	2	100%
Other	35	91.4%
Note: these were the possible clinical diagnoses for workup with imaging, but did not necessarily denote the presence of the indication		

Radiologist and reviewer inter-rater reliabilities were 95.7% and 91.4% respectively. Agreement between limited and full spine imaging ranged from 99.0% (detection of cerebellar ectopia) to 86.7% (identifying a filum < 2mm in diameter) with an overall average of 95.4% (Table 3). There was no significant difference in mean agreement between 1.5T and 3T magnet strengths ($p = 0.36$) (Fig. 1) or between sedated and non-sedated patients ($p = 0.22$). Using the Wilson-Brown method, sensitivity ranged between 0.91 to 1.00 in the detection of cerebellar ectopia (1.00), syrinx (0.91), level of conus (0.98), filum < 2mm (0.97), fatty filum (0.94), and spinal dysraphism (1.00). Specificity ranged from 0.86 to 1.00 in the detection of cerebellar ectopia (1.00), syrinx (0.99), fatty filum (1.00), and spinal dysraphism (1.00). The specificity was lowest in determining a filum < 2mm in diameter (0.86) (Table 4). False positive and negative rates for each targeted finding are further summarized in Table 5. In 15 studies, some specific findings were indeterminate and could not be evaluated during the blinded review. These studies were thus excluded solely in the sensitivity and specificity analysis (total excluded n = 15). The findings that could not be scrutinized were: filum < 2mm (n = 10), fatty filum (n = 3), spinal dysraphism (n = 3), syrinx (n = 2), and cerebellar ectopia (n = 1),

Table 3
% Agreement between standard and limited protocol by finding

Clinical Indication	% Agreement
Presence of Cerebellar Ectopia	99.05%
Presence of Syrinx	96.19%
Level of Conus Appreciated	98.10%
Filum < 2mm	86.67%
Presence of Fatty Filum	95.24%
Presence of Spinal Dysraphism	97.14%

Table 4
Sensitivity, Specificity, and Predictive value of limited protocol for specific findings

Clinical Indication	Sensitivity	Specificity	Positive Predictive Value	Negative Predictive Value
Cerebellar Ectopia	1.00	1.00	1.00	1.00
Syrinx	0.91	0.99	0.91	0.99
Level of Conus Appreciated	0.98	-	1.00	0
Filum < 2mm	0.97	0.86	0.99	0.67
Fatty Filum	0.94	1.00	1.00	0.97
Spinal Dysraphism	1.00	1.00	1.00	1.00

Table 5
Discrepancy rate and type between full and limited protocol

Clinical Indication	Discrepancy (%)	(#) False Positive	(#) False Negative
Cerebellar Ectopia	0	0	0
Syrinx	1.9	1	1
Level of Conus	1.9	0	2
Filum < 2mm	4.2	1	3
Fatty Filum	1.9	0	2
Spinal Dysraphism	0	0	0

Discussion

Precedence for utilizing limited series imaging in pediatric populations already currently exists in the form of “fast” or “limited” imaging of the brain. Prior studies have investigated the diagnostic equivalency of T2, FLAIR, Diffusion-Weighted Imaging (DWI), echo planar imaging, T1 weighted 3D spoiled gradient echo, and fast imaging employing steady-state acquisition compared to conventional MRI imaging[7–14]. While these studies are only validated in the evaluation of patients with shunted hydrocephalus, they have found a vital role in avoiding repeated doses of ionizing radiation or prolonged periods of time inside a MRI machine[20]. The use of shortened imaging protocols for MRI of the spine is not a novel concept and has been previously reported in limited populations. Several studies have accepted the use of less information in order to answer a specific clinical question. In 1996, Robertson et al. utilized two single-effective long TR fast echo acquisition sequences in the sagittal and axial planes for imaging of lumbar spondylosis and achieved a reduction in total scan time from 28 to 2.5 minutes[25]. More recently, Gewirtz et al. developed an abbreviated pediatric spine MRI protocol to reduce acquisition time from 60 minutes to 2 minutes with rapid T1 and T2 imaging. These authors reported that in 43 of the 47 rapid imaging studies, the fast spine protocol sufficiently diagnosed syrinx, spinal dysraphism, and ruled out other asymptomatic pathologies. However, this study was not paired, and thus could not validate findings observed on fast spine MRI protocol. Moreover, only gross pathologies such as syringomyelia and spinal dysraphism were assessed[26]. In this study, we showed that in specific clinical conditions, we can use fewer sequences to make the same diagnosis and evaluation of common pediatric spine pathologies compared to the gold standard of a full MRI study.

This high diagnostic accuracy of using a limited series is encouraging for use in the screening for common spine pathologies. Currently available screening techniques such as spinal ultrasound are limited by anatomical restrictions (ie. extent of ossification with age) as well as inconsistent visualization of spine structures. While definitive management for many pathologies may require more detailed studies of greater resolution, limited imaging assists in the detection of those patients who would require no further intervention and avoid more involved investigation altogether. Even after an initial diagnosis has been made, there are many instances when routine follow up imaging may be required (ie. monitoring for syrinx progression in patients with Chiari I malformation) and sufficient information could be obtained using only limited imaging. In addition to the absolute reduction in time of the scan itself, there is potential circumvention of the need for anesthetic which further reduces the duration a given patient may spend in the radiology department. These consequences may further improve departmental throughput and reduce overall patient wait times.

One challenge that was observed in this study was the effect of expectation bias during the evaluation of the limited spine protocol. We found several discrepancies owing to missed identification during the reporting of the full imaging studies whereas they were detected during review of the limited studies. These discrepancies do not detract from the efficacy of limited imaging, but rather speak to the importance of anticipation and knowledge of clinical indication when reviewing sequences. Furthermore, we identified that identified a thickened filum (ie. Filum > 2mm) may not be as consistent using limited

sequences and thus, may specifically require more dedicated imaging. A major strength of this study is the reliance on an independent, blind comparison of a novel protocol with conventional spine imaging. This comparison allows for true validation of the use of this limited protocol in a number of common pediatric pathologies. Further, we found that magnet strength did not significantly affect diagnostic capability, suggesting that a limited imaging would be feasible in centers where only lower field strength MRI were available. While we selected pathologies based on common indications for imaging, it is very likely that limited a protocol would also be of utility for other conditions as well.

Conclusion

This study demonstrates that the use of selected spine imaging sequences provides consistent and accurate diagnosis for several common pediatric conditions. This limited protocol may be very effective as a screening tool or in routine follow up after an initial diagnosis has been made. Further prospective study is required to determine the utility of selected imaging for other potential indications.

Declarations

Ethics approval and consent to participate

This study was performed retrospectively and was approved by the CHEO Research Ethics Board.

Consent for publication

All authors have consented to publication.

Availability of data and material

The data that support the findings of this study are available from the corresponding author (AT) at reasonable request.

Competing interests

The authors declare no competing interests.

Funding

Not applicable.

Authors' contributions

WW – Data collection, statistical analysis, manuscript writing, preparation of tables and figures. MT – Data collection, preparation of reference list. EM, JHM, AT, DM – Protocol development. EM, JHM – Limited spine image review. CK – Data extraction. RW – Statistics review. AT, DM – Supervision. All authors reviewed and approved the final manuscript.

Acknowledgements

Not applicable.

Disclosure

The authors have no personal financial or institutional interest in any of the drugs, materials, or devices described in this article.

This study was approved by the CHEO Research Ethics Board

References

1. A. D. Edwards and O. J. Arthurs, “Paediatric MRI under sedation: is it necessary? What is the evidence for the alternatives?,” *Pediatr. Radiol.*, vol. 41, no. 11, pp. 1353–1364, Nov. 2011, doi: 10.1007/s00247-011-2147-7.
2. R. K. Harned and J. D. Strain, “MRI-compatible audio/visual system: impact on pediatric sedation,” *Pediatr. Radiol.*, vol. 31, no. 4, pp. 247–250, Apr. 2001, doi: 10.1007/s002470100426.
3. S. A. Vanderby, P. S. Babyn, M. W. Carter, S. M. Jewell, and P. D. McKeever, “Effect of anesthesia and sedation on pediatric MR imaging patient flow,” *Radiology*, vol. 256, no. 1, pp. 229–237, Jul. 2010, doi: 10.1148/radiol.10091124.
4. T. L. Slovis, “Sedation and anesthesia issues in pediatric imaging,” *Pediatr. Radiol.*, vol. 41 Suppl 2, pp. 514–516, Sep. 2011, doi: 10.1007/s00247-011-2115-2.
5. D. E. Saunders, C. Thompson, R. Gunny, R. Jones, T. Cox, and W. K. Chong, “Magnetic resonance imaging protocols for paediatric neuroradiology,” *Pediatr. Radiol.*, vol. 37, no. 8, pp. 789–797, Aug. 2007, doi: 10.1007/s00247-007-0462-9.
6. T. M. Cook, K. El-Boghdadly, B. McGuire, A. F. McNarry, A. Patel, and A. Higgs, “Consensus guidelines for managing the airway in patients with COVID-19: Guidelines from the Difficult Airway Society, the Association of Anaesthetists the Intensive Care Society, the Faculty of Intensive Care Medicine and the Royal College of Anaesthetists,” *Anaesthesia*, vol. 75, no. 6, pp. 785–799, Jun. 2020, doi: 10.1111/anae.15054.
7. M. Aribandi, “Limited MRI of the brain as an alternative to CT,” *Lancet Lond. Engl.*, vol. 368, no. 9533, pp. 365–366, Jul. 2006, doi: 10.1016/S0140-6736(06)69106-X.
8. A. Ba-Ssalamah *et al.*, “Preoperative fast MRI of brain tumors using three-dimensional segmented echo planar imaging compared to three-dimensional gradient echo technique,” *Magn. Reson. Imaging*, vol. 18, no. 6, pp. 635–640, Jul. 2000, doi: 10.1016/s0730-725x(00)00148-x.
9. A. M. Isaacs *et al.*, “Feasibility of fast brain diffusion MRI to quantify white matter injury in pediatric hydrocephalus,” *J. Neurosurg. Pediatr.*, pp. 1–8, Jul. 2019, doi: 10.3171/2019.5.PEDS18596.
10. D. A. Feinberg and K. Setsompop, “Ultra-fast MRI of the human brain with simultaneous multi-slice imaging,” *J. Magn. Reson. San Diego Calif 1997*, vol. 229, pp. 90–100, Apr. 2013, doi:

10.1016/j.jmr.2013.02.002.

11. C. Jaimes, E. Yang, P. Connaughton, C. D. Robson, and R. L. Robertson, “Diagnostic equivalency of fast T2 and FLAIR sequences for pediatric brain MRI: a pilot study,” *Pediatr. Radiol.*, vol. 50, no. 4, pp. 550–559, Apr. 2020, doi: 10.1007/s00247-019-04584-1.
12. D. M. Lindberg *et al.*, “Feasibility and Accuracy of Fast MRI Versus CT for Traumatic Brain Injury in Young Children,” *Pediatrics*, vol. 144, no. 4, p. e20190419, Oct. 2019, doi: 10.1542/peds.2019-0419.
13. K. Rozovsky, E. C. G. Ventureyra, and E. Miller, “Fast-brain MRI in children is quick, without sedation, and radiation-free, but beware of limitations,” *J. Clin. Neurosci. Off. J. Neurosurg. Soc. Australas.*, vol. 20, no. 3, pp. 400–405, Mar. 2013, doi: 10.1016/j.jocn.2012.02.048.
14. L. A. van der Kleij, J. de Bresser, J. Hendrikse, J. C. W. Siero, E. T. Petersen, and J. B. De Vis, “Fast CSF MRI for brain segmentation; Cross-validation by comparison with 3D T1-based brain segmentation methods,” *PloS One*, vol. 13, no. 4, p. e0196119, 2018, doi: 10.1371/journal.pone.0196119.
15. W. W. Ashley, R. C. McKinstry, J. R. Leonard, M. D. Smyth, B. C. Lee, and T. S. Park, “Use of rapid-sequence magnetic resonance imaging for evaluation of hydrocephalus in children,” *J. Neurosurg.*, vol. 103, no. 2 Suppl, pp. 124–130, Aug. 2005, doi: 10.3171/ped.2005.103.2.0124.
16. J. Pan *et al.*, “Rapid-sequence brain magnetic resonance imaging for Chiari I abnormality,” *J. Neurosurg. Pediatr.*, vol. 22, no. 2, pp. 158–164, Aug. 2018, doi: 10.3171/2018.2.PEDS17523.
17. T. P. Boyle *et al.*, “Comparison of rapid cranial MRI to CT for ventricular shunt malfunction,” *Pediatrics*, vol. 134, no. 1, pp. e47-54, Jul. 2014, doi: 10.1542/peds.2013-3739.
18. D. M. Patel, R. S. Tubbs, G. Pate, J. M. Johnston, and J. P. Blount, “Fast-sequence MRI studies for surveillance imaging in pediatric hydrocephalus,” *J. Neurosurg. Pediatr.*, vol. 13, no. 4, pp. 440–447, Apr. 2014, doi: 10.3171/2014.1.PEDS13447.
19. B. R. O’Neill *et al.*, “Rapid sequence magnetic resonance imaging in the assessment of children with hydrocephalus,” *World Neurosurg.*, vol. 80, no. 6, pp. e307-312, Dec. 2013, doi: 10.1016/j.wneu.2012.10.066.
20. K. Rozovsky, E. C. Ventureyra, and E. Miller, “Fast-brain MRI in children is quick, without sedation, and radiation-free, but beware of limitations,” *Journal of Clinical Neuroscience.,* vol. 20, no. 3, pp. 400-405, March. 2013, doi: 10.1016/j.jocn.2012.02.048
21. B. D. Niederhauser *et al.*, “Retrospective review of rapid pediatric brain MR imaging at an academic institution including practice trends and factors affecting scan times,” *AJNR Am. J. Neuroradiol.*, vol. 34, no. 9, pp. 1836–1840, Sep. 2013, doi: 10.3174/ajnr.A3510.
22. D. M. Patel, R. S. Tubbs, G. Pate, J. M. Johnston, and J. P. Blount, “Fast-sequence MRI studies for surveillance imaging in pediatric hydrocephalus,” *J. Neurosurg. Pediatr.*, vol. 13, no. 4, pp. 440–447, Apr. 2014, doi: 10.3171/2014.1.PEDS13447.
23. S. Prakkamakul *et al.*, “Ultrafast Brain MRI: Clinical Deployment and Comparison to Conventional Brain MRI at 3T,” *J. Neuroimaging Off. J. Am. Soc. Neuroimaging*, vol. 26, no. 5, pp. 503–510, Sep. 2016, doi: 10.1111/jon.12365.

24. O. Rapalino, “New Strategies for Protocol Optimization for Clinical MRI: Rapid Examinations and Improved Patient Care,” *T*, p. 4.
25. W. D. Robertson, J. G. Jarvik, J. S. Tsuruda, T. D. Koepsell, and K. R. Maravilla, “The comparison of a rapid screening MR protocol with a conventional MR protocol for lumbar spondylosis,” *AJR Am. J. Roentgenol.*, vol. 166, no. 4, pp. 909–916, Apr. 1996, doi: 10.2214/ajr.166.4.8610572.
26. J. I. Gewirtz *et al.*, “Use of fast-sequence spine MRI in pediatric patients,” *J. Neurosurg. Pediatr.*, pp. 1–6, Sep. 2020, doi: 10.3171/2020.5.PEDS20137.

Figures

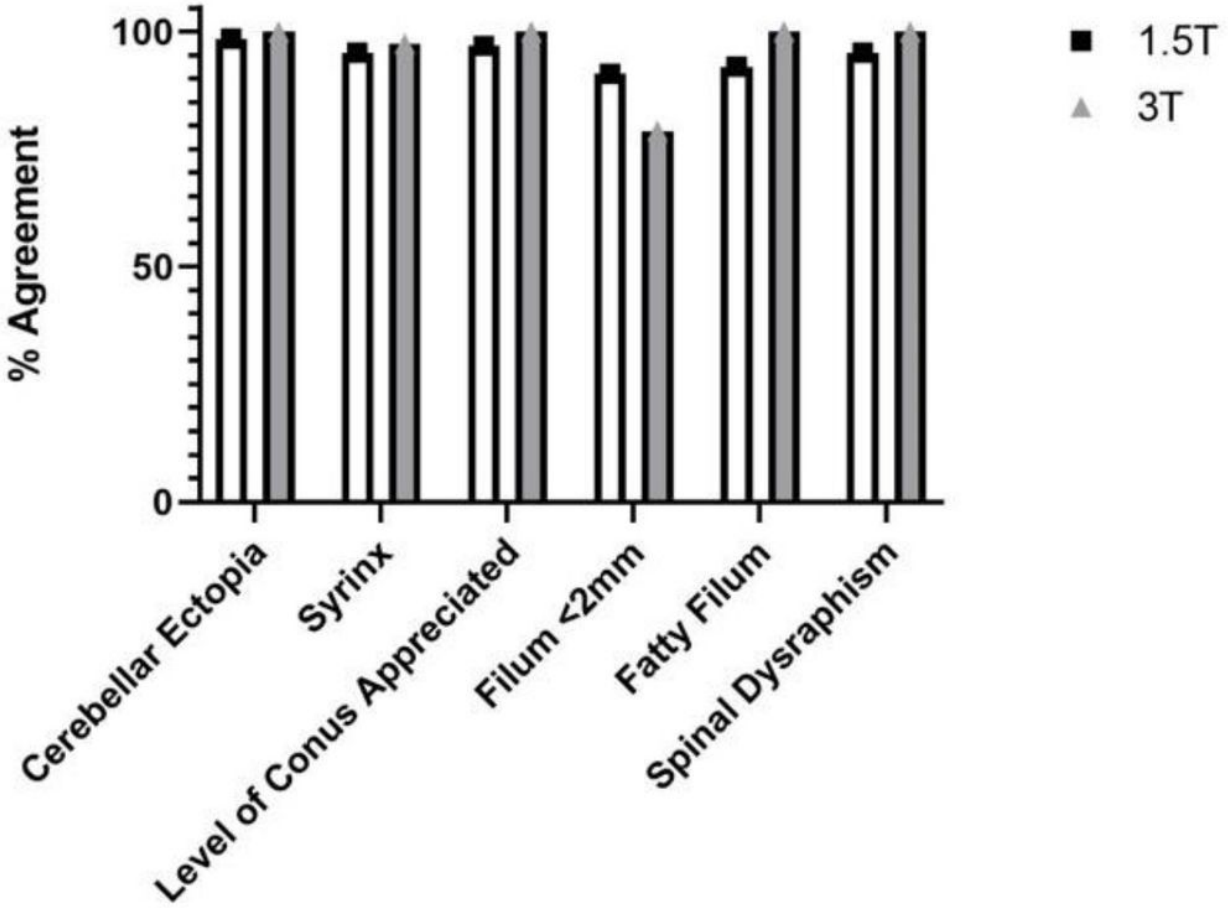

Figure 1

Average % Agreement of Full Sequence MRI vs Limited Spine Imaging Based on Magnet Strength.

This figure shows the average percentage agreement of the limited spine series compared to full sequence MRI across 6 different clinical indications based on magnet strength; 1.5T (white bars) and 3T

(grey bars)

Graphpad Prism was used to create this figure