Anatomical Identification of Ischial Spines Applicable to Intrapartum Transperineal Ultrasound Based on Magnetic Resonance Imaging of Pregnant Women

Eriko Yano
University of Tokyo
Takayuki Iriyama (iriyama-tky@umin.ac.jp)
University of Tokyo
Shouhei Hanaoka
University of Tokyo
Seisuke Sayama
University of Tokyo
Mari Ichinose
University of Tokyo
Masatake Toshimitsu
University of Tokyo
Takahiro Seyama
University of Tokyo
Kenbun Sone
University of Tokyo
Keiichi Kumasawa
University of Tokyo
Takeshi Nagamatsu
University of Tokyo
Koichi Kobayashi
JCHO Tokyo Yamate Medical Center
Tomoyuki Fujii
Sanno Hospital
Yutaka Osuga
University of Tokyo

Research Article

Keywords: ITU, IQR, SID, ultrasound, Gynecology

Posted Date: March 5th, 2021

DOI: https://doi.org/10.21203/rs.3.rs-269362/v1

Version of Record: A version of this preprint was published at The Journal of Maternal-Fetal & Neonatal Medicine on March 14th, 2022. See the published version at https://doi.org/10.1080/14767058.2022.2051007.

Anatomical identification of ischial spines applicable to intrapartum transperineal ultrasound based on magnetic resonance imaging of pregnant women

Eriko Yano*[1], Takayuki Iriyama*[1], Shouhei Hanaoka[2], Seisuke Sayama[1], Mari Ichinose[1], Masatake Toshimitsu[1], Takahiro Seyama[1], Kenbun Sone[1], Keiichi Kumasawa[1], Takeshi Nagamatsu[1], Koichi Kobayashi [3], Tomoyuki Fujii[4], and Yutaka Osuga[1]

[1] Department of Obstetrics and Gynecology, Faculty of Medicine, The University of Tokyo, Tokyo, Japan.

[2] Department of Radiology, Faculty of Medicine, The University of Tokyo, Tokyo, Japan.

[3] Department of Obstetrics and Gynecology, JCHO Tokyo Yamate Medical Center, Tokyo, Japan.

[4] Department of Obstetrics and Gynecology, Sanno Hospital, Tokyo, Japan.

* These authors contributed equally to this work.

Correspondence: Takayuki Iriyama M.D., Ph.D.

Department of Obstetrics and Gynecology, Faculty of Medicine, University of Tokyo 7-3-1 Hongo, Bunkyo-ku, Tokyo, 113-8655, Japan

Tel; +81-03-3815-5411

Fax; +81-03-5800-6937

Email; iriyama-tky@umin.ac.jp

Abstract

Intrapartum transperineal ultrasound (ITU) is considered useful in judging fetal head descent; however, the inability to detect ischial spines on ITU has been a drawback to its legitimacy. The current study aimed to determine the anatomical location of ischial spines, which can be directly applied to ITU. Based on magnetic resonance imaging of 67 pregnant women at 33^{+2} [31^{+6}-34^{+0}] weeks gestation (median [interquartile range: IQR]), we calculated the angle between the pubic symphysis and the midpoint of ischial spines (midline symphysis-ischial spine angle; mSIA), which is theoretically equivalent to the angle of progression at fetal head station 0 on ITU, by determining spatial coordinates of pelvic landmarks and utilizing spatial vector analysis. Furthermore, we measured symphysis-ischial spine distance (SID), defined as the distance between the vertical plane passing the lower edge of the pubic symphysis and the plane that passes the ischial spines. As a result, mSIA was 109.6 ° [105.1-114.0] and SID 26.4 mm [19.8-30.7] (median, [IQR]). There was no correlation between mSIA or SID and maternal characteristics, including physique. Our results provide valuable evidence to enhance the reliability of ITU in assessing fetal head descent by considering the location of ischial spines.

45 **Introduction**

46 Intrapartum transperineal ultrasound (ITU) has been proposed for evaluating
47 labor progression. The angle of progression (AoP), defined as the angle between the
48 midline of the pubic symphysis and a line running from the inferior edge of the symphysis
49 to the fetal skull, is regarded as more reliable in accuracy and reproducibility than vaginal
50 examination (VE) to assess fetal head descent [1-5]. However, some researchers have
51 questioned the accuracy of ITU in assessing fetal head descent because ischial spines, the
52 most important landmark in evaluating fetal head station (St), cannot be obtained by
53 ultrasound [6,7]. Previous studies have tried to identify a landmark equivalent to ischial spines
54 or St 0 on ITU images by evaluating the angle or the distance between the pubic symphysis
55 and the ischial spine [4,6-9]. Tustchek et al. depicted a plane perpendicular to the pubis, which
56 runs ischial spines (level of ischial spines), on ITU images; they reported that the AoP was
57 116° when the most presenting part of the fetus' head reached this plane [10,11]. This is one of
58 the reference angles for evaluating St on ITU images, which is covered by the International
59 Society of Ultrasound in Obstetrics and Gynecology (ISUOG) practice guidelines [12].
60 However, this plane was defined based on a symphysis-ischial spine distance (SID) of 3
61 cm, which was obtained based on single computed tomography (CT) images from only one
62 non-pregnant woman [9]. Considering the anatomical changes of the pelvis during pregnancy
63 and the differences in pelvic structure among individuals [13], this reference remains
64 arguable.

65 To date, there is only one report from France by Arthuis et al. that has evaluated
66 the anatomical position of ischial spines by analyzing pelvic images during pregnancy [7]. By

67 analyzing CT images of pregnant women, they calculated the angle between the upper-
68 lower edge of the pubic symphysis and the midpoint of ischial spines in a mid-sagittal plane
69 (midline symphysis-ischial spine angle; mSIA) and reported that it was 110°. This angle
70 was considered nearly equivalent to the AoP at St 0, and it contributed to the understanding
71 of the fetal head location on ITU images.

72 Considering racial or physique differences in pelvic anatomy [14,15], it has not been
73 clarified whether an mSIA 110° can be applied to other races; thus, more evidence needs to
74 be accumulated to determine ischial spines or St 0 on ITU images universally. Additionally,
75 if there is a method to evaluate the components of the bony pelvis more easily, we can
76 evaluate the pelvic structure and apply this further to ITU. Therefore, by calculating the
77 structural relationship between the pubis and other bony birth canal components, we can
78 establish an absolute index that divides the pelvic cavity, or the positional relationship
79 between the pubis and fetal head changes, quantitatively along the pelvic curve.

80 The current study aimed to quantify the relative position between ischial spines
81 and the pubic symphysis to assess St 0 on ITU images in an East Asian population by
82 establishing a novel and practical method to evaluate pelvic anatomy that can be applied to
83 ITU by analyzing three-dimensional coordinates of magnetic resonance images (MRI) in
84 pregnant women.

85

86 **Results**

87 There were 76 cases whose MRI scans were performed during pregnancy [31^{+6}
88 weeks to 34^{+0} weeks] between January 2016 and December 2018; 67 cases were analyzed

89 as nine cases were excluded due any of the landmarks, including the superior, or inferior
90 edge of pubic symphysis or ischial spines, was unclear. **Table 1** shows the maternal
91 characteristics; age, height, pre-pregnancy body mass index (BMI), and the gestational age
92 when the MRI was taken (35 years old [31-39] (median [interquartile range: IQR]), 159 cm
93 [156-162], 20.0 kg/m^2 [19.1-21.2], and 33^{+2} weeks [31^{+6} - 34^{+0}], respectively). Fifty
94 patients (74%) were primiparous, 11 cases (16.4%) had a history of vaginal delivery, and
95 six cases (8.9%) had a history of cesarean section. The indications for MRI were placental
96 previa, low set placenta, or placenta accreta (59 cases [88.0%]); fetal malformation (four
97 cases [5.9%]); and birth canal evaluation for maternal complication with Klippel-
98 Trenaunay-Weber syndrome (one case [1.5%]]. All pregnant women were East Asians.
99 We measured the spatial coordinates of each of the following points on MRI
100 images: superior edge of the pubic symphysis, inferior edge of the pubic symphysis, and
101 bilateral ischial spines, utilizing software as described in the Methods. Pubic symphysis
102 was evaluated using T2-weighted images (T2WI) (**Figure 1a-d**). We determined the mid-
103 sagittal plane using the sagittal and axial views. Next, we identified the superior edge of the
104 pubic symphysis (A) and inferior edge of the pubic symphysis (B) using mid-sagittal and
105 axial views and measured each coordinate: A (Ax, Ay, Az) and B (Bx, By, Bz). The left
106 ischial spine (C) and right ischial spine (D) were identified by evaluating the axial and
107 coronal views of T1-weighted images (T1WI) and measuring each coordinate: C (Cx, Cy,
108 Cz) and D (Dx, Dy, Dz) (**Figure 1e and f**). The point corresponding to the level of the
109 ischial spine in the mid-sagittal plane was calculated as the midpoint of the bilateral ischial
110 spines (E).

$$E\ (Ex, Ey, Ez) = \left(\frac{Cx+Dx}{2}, \frac{Cy+Dy}{2}, \frac{Cz+Dz}{2}\right) \quad (1)$$

The vector connecting the inferior edge of pubis (B) and the superior edge of pubis (A) is defined as the vector BA, and the vector connecting the inferior edge of the pubis (B) and midpoint of the ischial spines (E) is defined as the vector BE. The angle between the vector BA and BE is defined as θ, which corresponds to the midline symphysis-ischial spine angle (mSIA) on MRI (**Figure 2a**).

$$\text{Vector BA} = (Ax\text{-}Bx, Ay\text{-}By, Az\text{-}Bz) \quad (2)$$

$$\text{Vector BE} = (Ex\text{-}Bx, Ey\text{-}By, Ez\text{-}Bz) \quad (3)$$

The angle θ between line AB and BE was measured using the Arc cos function. Angle θ can be expressed by vector BA and BE, and the Arc cos function as follows (**Figure 2b**):

$$\theta = \text{Arc}\ \cos\left(\frac{BA \cdot BE}{|BA||BE|}\right) \quad (4)$$

In other words, the angle θ can be calculated by introducing the value obtained by taking the inner product of the vector BA and the vector BE as the numerator and multiplying the absolute values of the vectors BA and BE as the denominator into the Arc cos function. The angle θ obtained from this formula is 109.6° [105.1-114.0] (median

128 [IQR]. There was no significant statistical correlation between mSIA and maternal
129 characteristics (age, gestational days, height, body weight, BMI, or parity) (**Table 2**).
130 The infrapubic plane, which is defined as the plane perpendicular to the pubis,
131 which passes the inferior edge of the pubis, and the level of the ischial spines, which is
132 defined as the plane parallel to the infrapubic plane, which runs ischial spines, and the
133 distance between two planes is defined as the symphysis-ischial spine distance (SID)
134 (**Figure 3a**). E' is the foot of the perpendicular line drawn from the midpoint of the ischial
135 spine (E) to the extension of the pubis; the distance corresponding to the SID was
136 calculated as the distance (|BE'|) between the infrapubic plane (BB') and the level of the
137 ischial spine (EE') (**Figure 3b**). The distance between the infrapubic plane and the level of
138 ischial spines, |BE'| or SID, can be calculated as follows:

139 $$\mathrm{SID} = |\mathrm{BE}'| = |\mathrm{BE}| \cos\left(180\text{-}\theta\right) = -|\mathrm{BE}| \cos\left(\theta\right) \quad (5)$$

140 The median SID was 26.4 mm [19.8-30.7] (median [IQR]). There was no significant
141 statistical correlation with maternal characteristics (**Table 2**).
142
143 **Discussion**
144 The current study demonstrated the anatomical angles and distance that can help
145 identify the location of ischial spines on ITU by analyzing the anatomical relationship
146 between the pubic symphysis and ischial spines using MRI data from pregnant women in
147 the third trimester. In this study, we also established a novel method to measure the
148 components of the pelvic anatomy by analyzing the three-dimensional coordinates of MRI.

149 Although several studies have attempted to identify St 0 or ischial spines on ITU
150 images based on image analysis, there is only one report by Arthuis et al. prior to the
151 current study that measured the anatomical relationship between the ischial spines and the
152 pubis on the mid-sagittal plane using images during pregnancy [7]. Since it is known that
153 there are differences in pelvic size and structures depending on race or physique [14,15], it has
154 been questioned whether the mSIA of 110° calculated by Arthuis et al. can be applied to
155 other races. In the current study, we demonstrated that the mSIA was 109.6° [105.1-114.0]
156 (median [IQR]), regardless of the differences in maternal characteristics including height.
157 Arthuis et al. also demonstrated that the angle between the pubis and left ischial spine was
158 106° [105-109] (median [IQR]). Based on our MRI analysis, the angles between the pubis
159 and left or right ischial spine were 105.5° [102.0-107.9] and 106.8° [101.9-109.3] (median
160 [IQR]), respectively. Intriguingly, these values are almost equal to those reported by
161 Arthuis et al. Although they did not describe the target race, the height was 164 cm [160-
162 169] (median, [IQR]), which is different from ours, 159 cm [156-162] (median [IQR]),
163 obtained from our Japanese and East Asian population. This comparison shows that a
164 mSIA of 109.6° can be considered as a universal value corresponding to St 0 in applying to
165 ITU, regardless of race or physique.
166 According to ISUOG practice guidelines [12], AoP equivalent to ITU head station 0 is
167 116°, which is a result calculated based on single CT images of only one pregnant woman
168 reported by Tutchek et al [10,11]. They calculated this value, 116°, by depicting the level of
169 ischial spines on ITU images by drawing a perpendicular line to the pubis, which passes 30
170 mm from the lower edge of the pubis. The rationale for this distance, 30 mm, was based on

171 the measurement of the symphysis-ischial spine distance (SID), which was 30 mm,
172 although this was obtained from only one non-pregnant woman. Therefore, their result
173 remains controversial to be used as a universal value and is in fact different from our result
174 of 109°. In our study, we calculated SID to be 26.4 mm [19.8-30.7] (median [IQR]) based
175 on 67 pregnant women. Intriguingly, this SID value was almost the same at 26.1 mm [23.4-
176 29.5] (Median [IQR]) as Arthuis et al. reported [7], implying that SID may be consistent
177 among pregnant women. The pelvic cavity changes gradually but dramatically during
178 pregnancy to prepare for delivery, such as an increase in the mobility of the sacroiliac joint
179 and pubic symphysis [13]. For example, Barbera et al. calculated mSIA as 99° using 3DCT of
180 non-pregnant women [4], which is clearly different from our current result of 109.6°,
181 calculated from 67 pregnant women. Therefore, we speculate that mSIA increases during
182 pregnancy, which implies that the value obtained from non-pregnant women should not be
183 directly applied to pregnant women. Taken together, we must reconsider the value obtained
184 from one non-pregnant woman in assessing fetal head descent, which is still used to assess
185 head station in the ISUOG guidelines. The figure calculated from multiple pregnant women
186 is more reliable in accurately assessing fetal descent.
187 Arthuis et al. analyzed 3DCT of pregnant women and reported the angle between
188 the pubis and left ischial spine as 106° [105-109] (median [IQR]) [7]. However, since the
189 view equivalent to the ITU images is the mid-sagittal plane, this angle cannot be directly
190 applied to ultrasound. Although the midpoint of the ischial spines can be used as an index
191 for the ischial spine on ITU images, it cannot be measured directly by their method. Thus,
192 they calculated the angle between the pubis and the midpoint of the ischial spine (mSIA) as

193 110° by using the distance measurement by 3DCT and trigonometric function. In contrast,
194 the method that we newly developed enables us to calculate the mSIA directly and easily
195 by measuring the spatial coordinates of the lower and upper edges of the pubis and bilateral
196 ischial spines and applying them to vector calculation. Thus, the anatomical relationship on
197 the mid-sagittal plane can be easily obtained. Furthermore, as our method enables the
198 evaluation of anatomical landmarks other than the ischial spines, we can assess other
199 components of the birth canal, which has not been evaluated in previous studies, but is of
200 value in determining fetal descent, including the sacrum. We can easily quantify the
201 positional relation of the pubis, sacrum, and fetal head. According to the American College
202 of Obstetricians and Gynecologists (ACOG) forceps delivery classification [16], namely
203 mid/low/outlet, clinicians rely on VE to assess fetal descent, and its correspondence to ITU
204 findings is still undetermined. With our novel method for calculating the exact position of
205 the pubis, sacrum, and ischial spines within the pelvis, we might be able to theoretically
206 divide the pelvic cavity into a mid/low/outlet in relation to the position of pubic symphysis
207 as a future study, which would ultimately lead to safer application of operative vaginal
208 delivery.

209 The limitation of our study is that we did not consider the fetal head. Since the
210 fetal head progresses in the birth canal three-dimensionally, the presenting part does not
211 necessarily exist on the mid-sagittal plane. Since the presenting part is evaluated on the
212 mid-sagittal plane when evaluating AoP, there may be a discrepancy from VE findings.
213 Another limitation is that the pelvic anatomy may change during labor. To determine the
214 position of the ischial spines during labor more accurately, angle evaluation during labor

215 may be necessary. Another limitation is that we did not examine intra-observer or inter-
216 observer differences. However, identification of ischial spines and pubis on MRI images is
217 easy, and it is unlikely that a large error will occur.

218 We established a novel method to analyze the pelvic anatomy by evaluating
219 spatial coordinates on MRI images, and calculated the mSIA as 109.6° and SID as 26.4 mm
220 in pregnant women in the third trimester, which can be applied to ITU as positional
221 landmarks of ischial spines. Furthermore, since these values are almost equivalent to the
222 value from other races and physique, our figure can be a universal parameter. With this
223 index, the anatomical relation between the fetal head and the ischial spines can be evaluated
224 on ITU images, and it should increase the reliability and accuracy of labor progression
225 assessment using ITU.

226

227 **Methods**

228 Under the approval of the Institutional Review Board of the University of Tokyo
229 [3053-(4)], we retrospectively analyzed MRI scans performed during pregnancy between
230 January 2016 and December 2018 in our hospital. This was a retrospective observational
231 study, and consent was obtained in the form of opt-out on the internet homepage of our
232 institution, in accordance with the request of the ethics committee of the University of
233 Tokyo. All research was performed in accordance with the relevant guidelines and
234 regulations. Either MRI, 1.5T MAGNETOM Avanto (Siemens, Germany), or 1.5T
235 EXCITE HDX (GE Healthcare, United States) were used. The mid-sagittal plane of T2WI
236 and axial and coronal planes of fast-suppressed T1WI were taken with the patient placed in

237 a supine position with their knees bent. In 1.5T MAGNETOM Avanto (Siemens,
238 Germany), T2WI were acquired by 2D single shot fast spin echo with the following
239 settings: time of echo (TE) of 75 ms, time of repetition (TR) of 1500 ms, and slice interval
240 of 5 mm; fast-suppressed T1WI were acquired by 3-D spoiled gradient echo with TE of
241 1.07, TR of 3.2, and slice interval of 5 mm. In 1.5T EXCITE HDX (GE Healthcare, United
242 States), T2WI were acquired by 2D single-shot fast spin echo with TR of 1268 ms, TE of
243 91.50, and slice interval of 5 mm; fast-suppressed T1WI were acquired by 3D spoiled
244 gradient echo with TR of 3.532, TE of 1.688, slice interval of 1.5 mm.
245 MRI data were analyzed with OsiriX Lite (Pixmeo SARL, Switzerland), free and
246 open source of the Digital Imaging and Communications in Medicine (DICOM) viewer.
247 OsiriX Lite can simultaneously evaluate three cross sections of DICOM images: horizontal,
248 coronal, and sagittal sections. By selecting any point on the image, the spatial coordinates
249 (x, y, z) are automatically measured when the image is constructed in 3D. The
250 identification and measurement of each anatomical were conducted by the same
251 obstetrician (E. Y.) under the guidance of a radiologist (S. H.).
252 Data of background characteristics were expressed as median (interquartile range
253 [IQR]). Correlation analysis was conducted using Spearman's rank-order correlation with
254 JMP pro version 15 (SAS Institute Inc., Japan).
255
256 **Data availability**
257 All data generated or analyzed during this study are included in this published article.
258

References

1 Molina, F. S., Terra, R., Carrillo, M. P., Puertas, A. & Nicolaides, K. H. What is the most reliable ultrasound parameter for assessment of fetal head descent? *Ultrasound Obstet Gynecol* **36**, 493-499, doi:10.1002/uog.7709 (2010).

2 Ramphul, M. *et al.* Instrumental delivery and ultrasound : a multicentre randomised controlled trial of ultrasound assessment of the fetal head position versus standard care as an approach to prevent morbidity at instrumental delivery. *BJOG* **121**, 1029-1038, doi:10.1111/1471-0528.12810 (2014).

3 Duckelmann, A. M. *et al.* Measurement of fetal head descent using the 'angle of progression' on transperineal ultrasound imaging is reliable regardless of fetal head station or ultrasound expertise. *Ultrasound Obstet Gynecol* **35**, 216-222, doi:10.1002/uog.7521 (2010).

4 Barbera, A. F., Imani, F., Becker, T., Lezotte, D. C. & Hobbins, J. C. Anatomic relationship between the pubic symphysis and ischial spines and its clinical significance in the assessment of fetal head engagement and station during labor. *Ultrasound in Obstetrics and Gynecology* **33**, 320-325, doi:10.1002/uog.6322 (2009).

5 Barbera, A. F., Pombar, X., Perugino, G., Lezotte, D. C. & Hobbins, J. C. A new method to assess fetal head descent in labor with transperineal ultrasound. *Ultrasound Obstet Gynecol* **33**, 313-319, doi:10.1002/uog.6329 (2009).

6 Bamberg, C. *et al.* Relationship between fetal head station established using an open magnetic resonance imaging scanner and the angle of progression determined by transperineal ultrasound. *Ultrasound Obstet Gynecol* **37**, 712-716, doi:10.1002/uog.8944 (2011).

7 Arthuis, C. J., Perrotin, F., Patat, F., Brunereau, L. & Simon, E. G. Computed

287 tomographic study of anatomical relationship between pubic symphysis and
288 ischial spines to improve interpretation of intrapartum translabial ultrasound.
289 *Ultrasound Obstet Gynecol* **48**, 779-785, doi:10.1002/uog.15842 (2016).
290 8 Iliescu, D. *et al.* The Angle of Progression at Station 0 and in Magnetic
291 Resonance and Transperineal Ultrasound Assessment. *Case Rep Obstet*
292 *Gynecol* **2015**, 748327, doi:10.1155/2015/748327 (2015).
293 9 Henrich, W., Dudenhausen, J., Fuchs, I., Kamena, A. & Tutschek, B. Intrapartum
294 translabial ultrasound (ITU): sonographic landmarks and correlation with
295 successful vacuum extraction. *Ultrasound Obstet Gynecol* **28**, 753-760,
296 doi:10.1002/uog.3848 (2006).
297 10 Tutschek, B., Braun, T., Chantraine, F. & Henrich, W. A study of progress of
298 labour using intrapartum translabial ultrasound, assessing head station,
299 direction, and angle of descent. *BJOG* **118**, 62-69, doi:10.1111/j.1471-
300 0528.2010.02775.x (2011).
301 11 Tutschek, B., Torkildsen, E. A. & Eggebo, T. M. Comparison between ultrasound
302 parameters and clinical examination to assess fetal head station in labor.
303 *Ultrasound Obstet Gynecol* **41**, 425-429, doi:10.1002/uog.12422 (2013).
304 12 Ghi, T. *et al.* ISUOG Practice Guidelines: intrapartum ultrasound. *Ultrasound*
305 *Obstet Gynecol* **52**, 128-139, doi:10.1002/uog.19072 (2018).
306 13 Cunningham, F. G. *et al. Williams Obstetrics* 25 edn, Vol. 1 14-32 (McGraw Hill
307 Education, 2018).
308 14 Arima, H. *et al.* Differences in lumbar and pelvic parameters among African
309 American, Caucasian and Asian populations. *Eur Spine J* **27**, 2990-2998,
310 doi:10.1007/s00586-018-5743-5 (2018).
311 15 Handa, V. L. *et al.* Racial differences in pelvic anatomy by magnetic resonance
312 imaging. *Obstet Gynecol* **111**, 914-920, doi:10.1097/AOG.0b013e318169ce03
313 (2008).
314 16 ACOG Practice Bulletin No. 154: Operative Vaginal Delivery. *Obstet Gynecol*
315 **126**, e56-e65, doi:10.1097/AOG.0000000000001147 (2015).

Acknowledgements

None.

Author Information

Department of Obstetrics and Gynecology, Faculty of Medicine, The University of Tokyo, Tokyo, Japan

Eriko Yano, Takayuki Iriyama, Seisuke Sayama, Mari Ichinose, Masatake Toshimitsu, Takahiro Seyama, Kenbun Sone, Keiichi Kumasawa, Takeshi Nagamatsu, and Yutaka Osuga

Department of Radiology, Faculty of Medicine, The University of Tokyo, Tokyo, Japan

Shouhei Hanaoka

Department of Obstetrics and Gynecology, JCHO Tokyo Yamate Medical Center, Tokyo, Japan

Koichi Kobayashi

Department of Obstetrics and Gynecology, Sanno Hospital, Tokyo, Japan

Tomoyuki Fujii

Author contributions

E.Y. and T.I. designed the research. E.Y. and S.H. analyzed MRI images and acquired the data. E.Y., T.I., and S.S. wrote the manuscript. M.I, M.T., T.S., K.S., K.K., T.N., and K.K.

337 have made substantial contribution to study design, interpretation of data, and made critical
338 comments on the manuscript. T.F. and Y.O. organized this research as project managers.
339
340 **Competing interests**
341 The Authors declare no competing interests.
342
343 **Corresponding author**
344 Correspondence to Takayuki Iriyama
345
346 **Figure Legends**
347 **Figure 1. Identification of superior and inferior edge of the pubic symphysis and**
348 **bilateral ischial spines on magnetic resonance imaging (MRI) of pregnant women.**
349 Superior edge of the pubic symphysis (A) on T2 weighted mid-sagittal plane MRI (**a**) and
350 T1 weighted axial plane (**b**) MRI. Inferior edge of the pubic symphysis (B) on T2 weighted
351 mid-sagittal plane (**c**) and T1 weighted axial plane MRI (**d**). Right ischial spine (C) and left
352 ischial spine (D) on axial and coronal plane of T1 weighted image MRI (**e**, **f**).
353
354 **Figure 2. Calculation of the angle between pubic symphysis and midpoint of ischial**
355 **spines, termed the midline symphysis-ischial spine angle (mSIA).**
356 (**a**) T2-weighted mid-sagittal plane of MRI. θ is the angle between superior edge of the
357 pubic (A), inferior edge of pubic symphysis (B), and midpoint of ischial spines (E).

(**b**) Vectors and θ can be calculated by each coordinate (x, y, z) as follows:

$$\text{Vector BA} = (Ax-Bx,\ Ay-By,\ Az-Bz)$$

$$\text{Vector BE} = (Ex-Bx,\ Ey-By,\ Ez-Bz)$$

$$|BA| = \text{length of the vector BA} = \sqrt{(Ax-Bx)^2+(Ay-By)^2+(Az-Bz)^2}$$

$$BA \cdot BE = \text{inner product of the vector BA and the vector BE}$$

$$= (Ax-Bx)\cdot(Ex-Bx)+(Ay-By)\cdot(Ey-By)+(Az-Bz)\cdot(Ez-Bz)$$

$$\theta = \text{Arc}\ \cos\left(\frac{BA \cdot BE}{|BA||BE|}\right)$$

Figure 3. Calculation of symphysis-ischial spine distance (SID)

(**a**) Schema of the relationship between SID, pubic symphysis, infrapubic plane, and level of ischial spines. (**b**) T2-weighted mid-sagittal plane of MRI. E is defined as the midpoint of the ischial spines. E' is defined as the foot of the perpendicular line drawn from E on the extension line of the pubis. EE' (level of ischial spines) is parallel to the infrapubic plane. The distance between B and E' ($|B\ E'|$ =SID) can be calculated as follows:

$$SID = |BE'| = |BE| \cos\left(180-\theta\right) = -|BE| \cos\left(\theta\right)$$

$$|BE| = \text{length of the vector BE} = \sqrt{(Ex-Bx)^2+(Ey-By)^2+(Ez-Bz)^2}$$

377

378 **Table 1. Maternal characteristics of 67 pregnant women analyzed in the current study**

379

Characteristics	Value
Age (years)	35.0 [31.0-39.0]
Height (cm)	159.0 [156-162]
Pre-pregnancy weight (kg)	51.0 [48.0-54.0]
Weight gain during pregnancy (kg)	7.0 [5.2-9.0]
Pre-pregnancy BMI (kg/m^2)	20.0 [19.1-21.2]
Gestational age when MRI was taken	33^{+2} [31^{+6} – 34^{+0}]
Parity	
Nulliparous	50 (74.6)
History of vaginal delivery	11 (16.4)
History of caesarian section	6 (8.9)
Indication for MRI	
Placenta previa or low set placenta	59 (88.0)
Fetal malformation	4 (5.9)
Other	1 (1.5)
Race (East Asian)	67 (100)

401 The values are expressed as median [interquartile range] or number (%). BMI, body mass
402 index, MRI, magnetic resonance imaging.
403
404 **Table 2. Correlation analysis between maternal characteristics and midline**
405 **symphysis-ischial spine angle (mSIA) or symphysis-ischial spine distance (SID)**
406

Characteristics	mSIA		SID	
	correlation coefficient	P-value	correlation coefficient	P-value
Age	0.11	0.37	0.20	0.10
Height	-0.04	0.75	0.09	0.49
Pre-pregnancy weight	0.13	0.29	0.21	0.10
Pre-pregnancy BMI	0.16	0.2	0.16	0.2
Weight gain during pregnancy	0.09	0.49	0.08	0.55
Gestational age	-0.15	0.23	-0.14	0.24
History of vaginal delivery	-0.16	0.21	-0.21	0.09

407 The values of the correlation coefficient of mSIA or SID in each maternal characteristic by
408 Spearman's rank-order correlation and P-value are shown. Statistical significance was set at
409 $P < 0.05$. BMI, body math index.

410

Figure 1

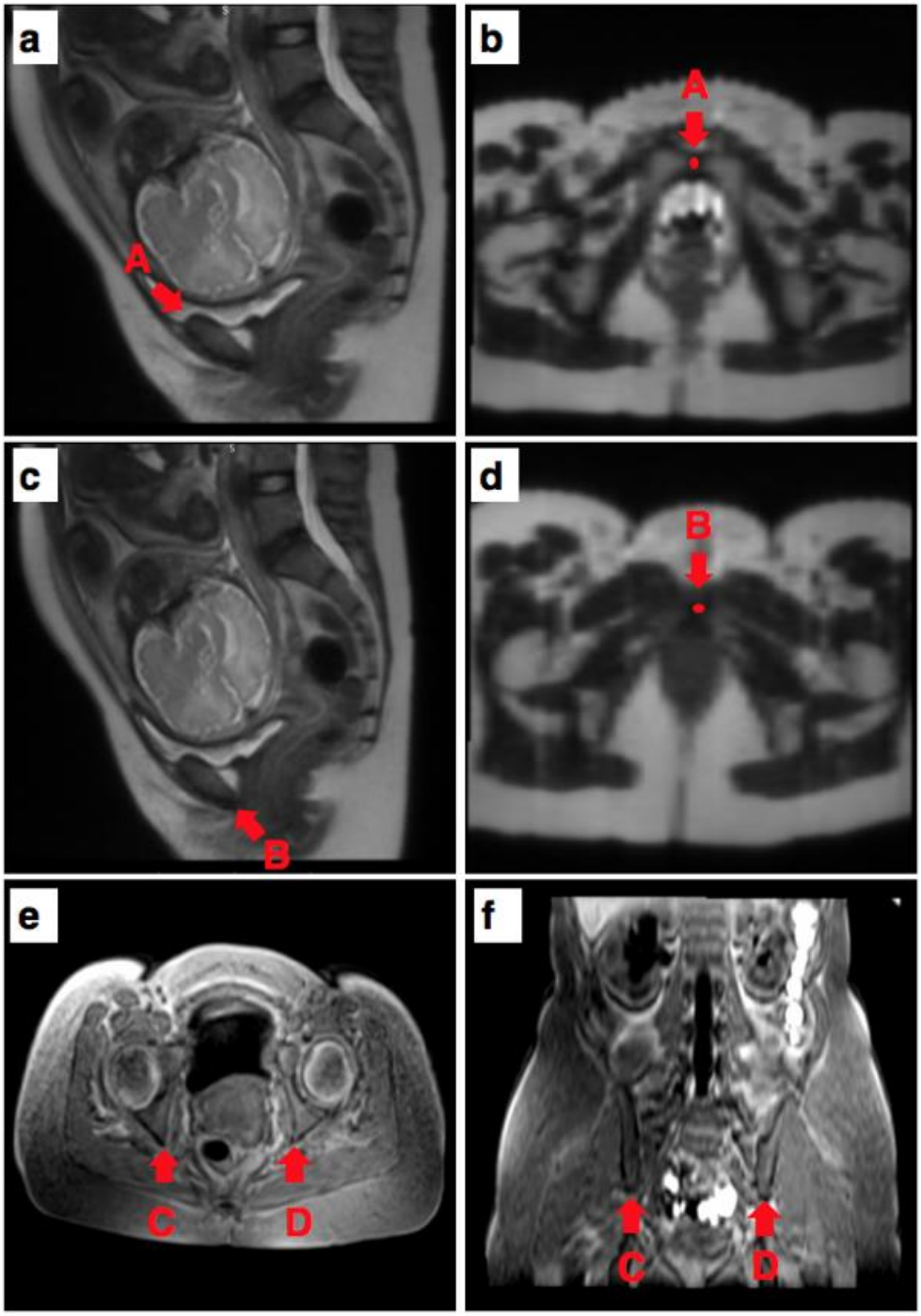

411

412

Figure 2

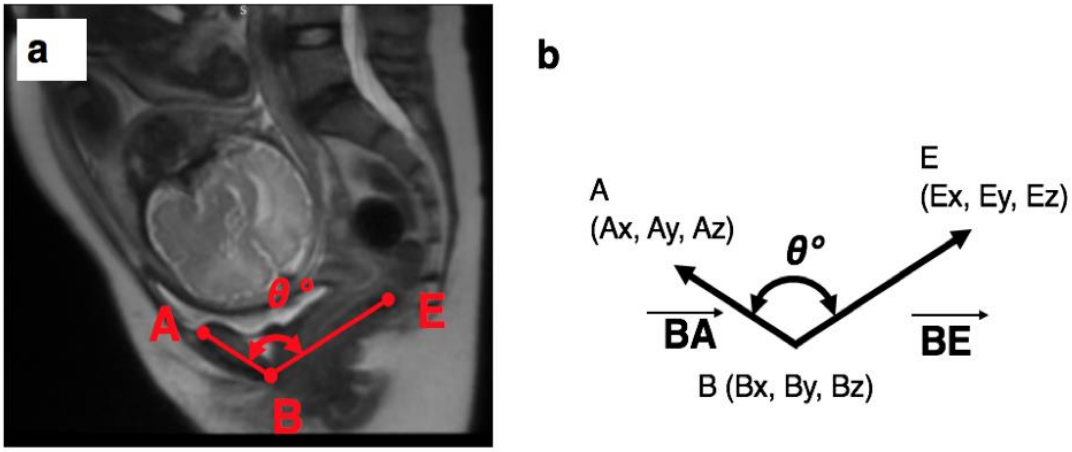

Figure 3

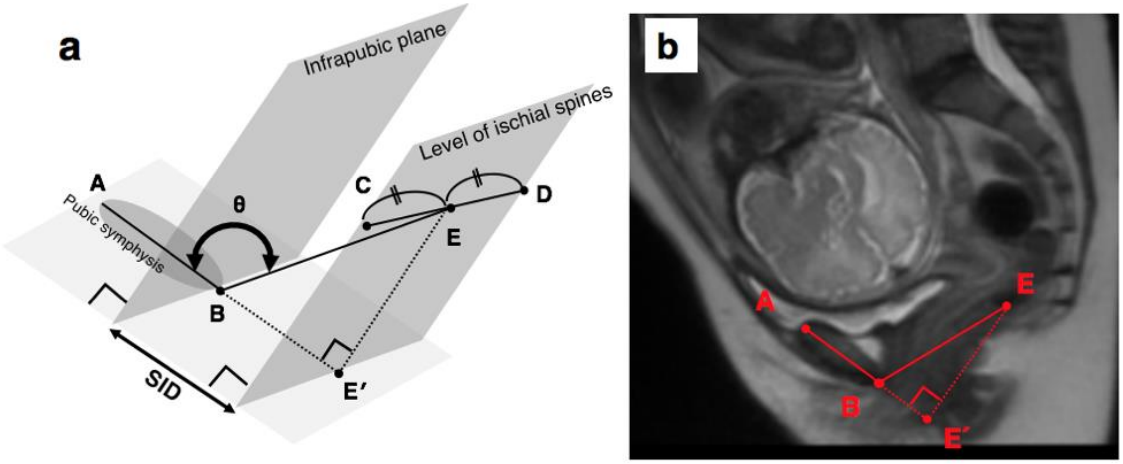

413

414

415

Figures

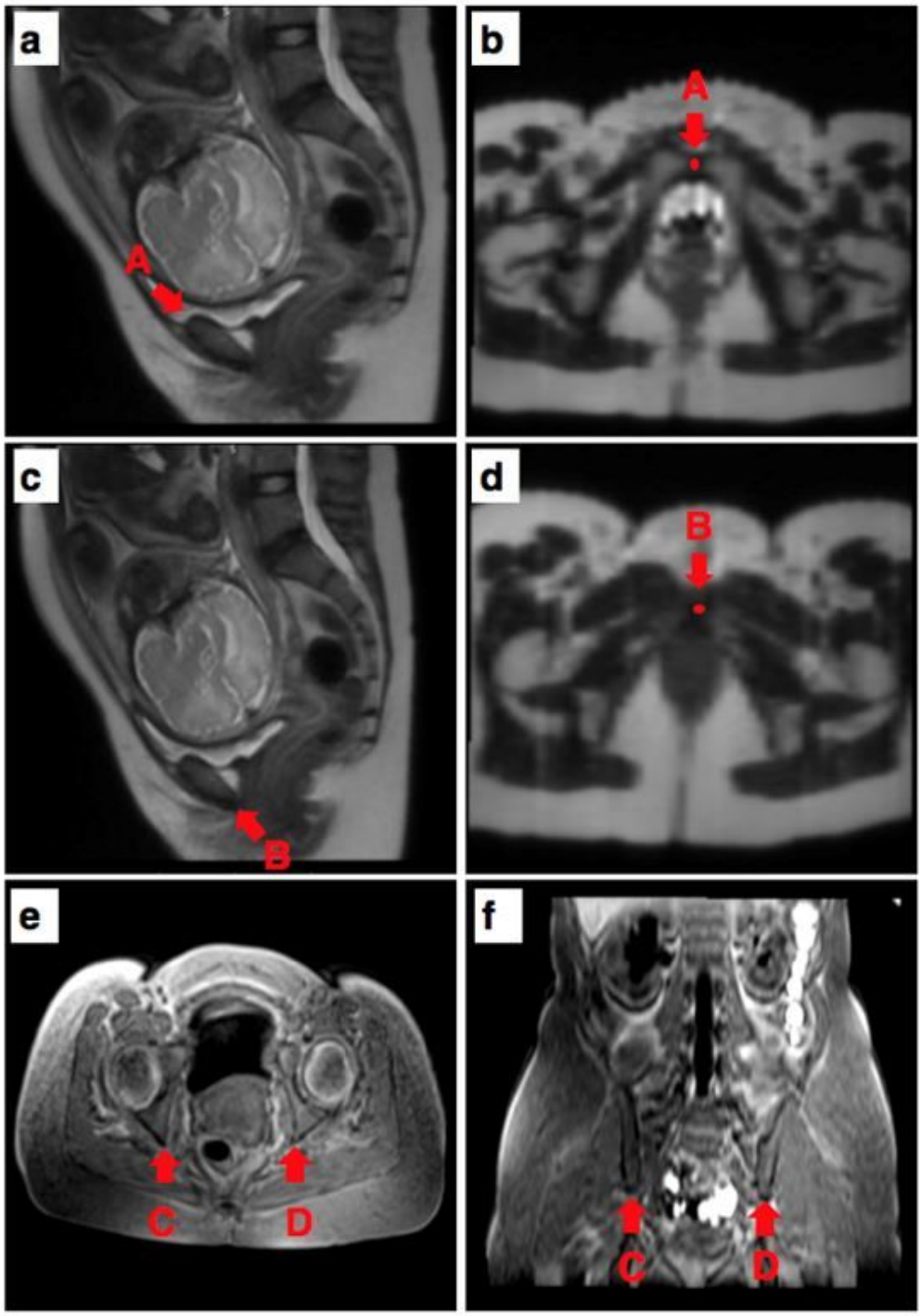

Figure 1

Identification of superior and inferior edge of the pubic symphysis and bilateral ischial spines on magnetic resonance imaging (MRI) of pregnant women. Superior edge of the pubic symphysis (A) on T2 weighted mid-sagittal plane MRI (a) and T1 weighted axial plane (b) MRI. Inferior edge of the pubic

symphysis (B) on T2 weighted mid-sagittal plane (c) and T1 weighted axial plane MRI (d). Right ischial spine (C) and left ischial spine (D) on axial and coronal plane of T1 weighted image MRI (e, f).

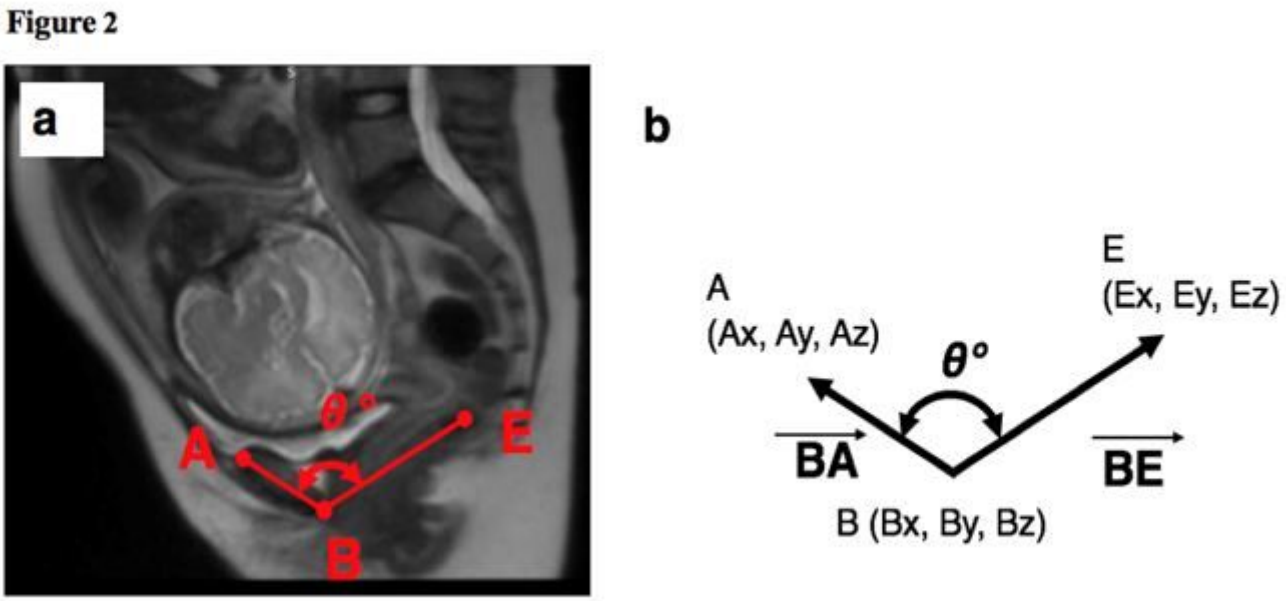

Figure 2

"See the Supplemental Files section for the complete figure caption".

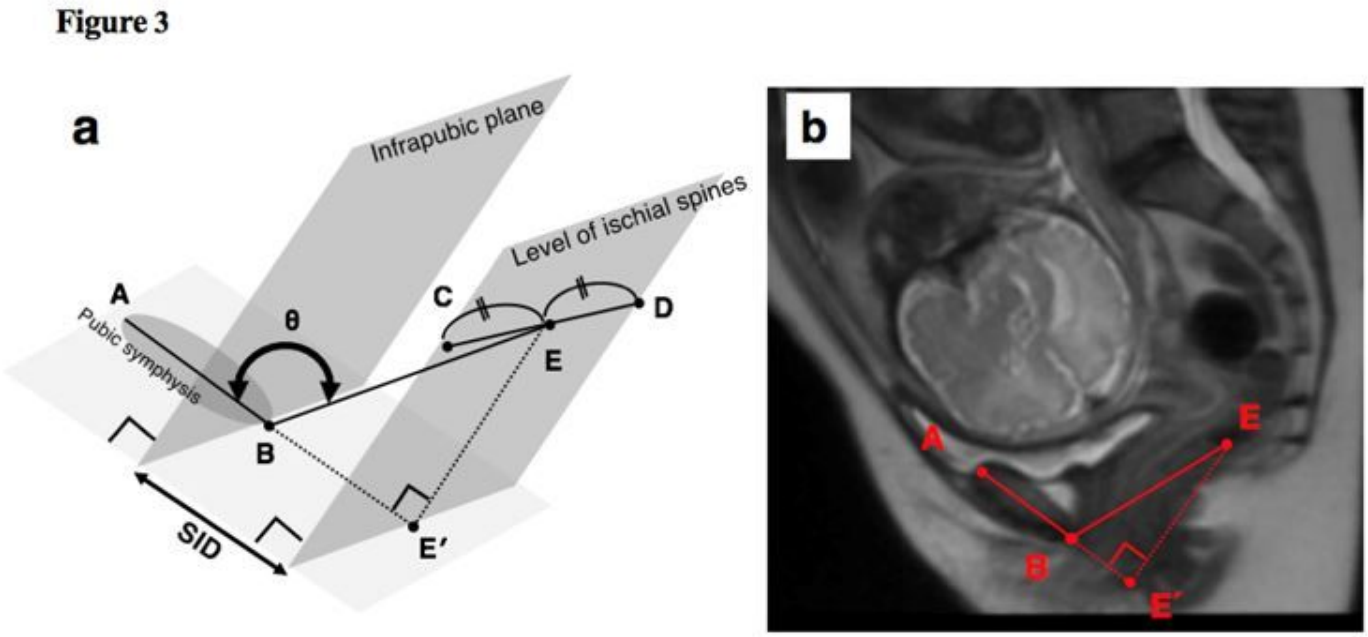

Figure 3

"See the Supplemental Files section for the complete figure caption".

Supplementary Files

This is a list of supplementary files associated with this preprint. Click to download.

- FigureCaptions.docx