Application of Improved Incision in the Protection of Superficial Temporal Artery.

Renchun Yan
Yijishan Hospital of Wannan Medical College https://orcid.org/0000-0003-1658-2677
Xinyun Fang (251432061@qq.com)
Yijishan Hospital of Wannan Medical College

Research Article

Keywords: superficial temporal artery, improved incision, moyamoya disease

Posted Date: March 16th, 2021

DOI: https://doi.org/10.21203/rs.3.rs-270488/v1

Abstract

Objective: To explain the clinical importance of protecting the superficial temporal artery and introduce a method of protecting the superficial temporal artery.

Methods: This study retrospectively analyzed the clinical data of 75 emergency patients undergoing frontotemporal craniotomy. The data was divided into traditional incision group and improved incision group according to the different surgical incision methods.

Results: There were 38 cases in the traditional incision group, 13 of which had superficial temporal artery injury. Only 8 cases (21%) underwent the anatomical separation of superficial temporal artery during the operation. Whereas there were 37 cases in the improved incision group, with none showing superficial temporal artery injury.

Conclusion: No strong consciousness of protecting the superficial temporal artery was shown in the clinical emergency surgery. The improved incision is a simple and easy way to protect the superficial temporal artery.

Introduction

The superficial temporal artery originates from the external carotid artery in the neck of the mandible. It passes through the parotid gland and going up and down to the subcutaneous and branching from the root of the zygomatic arch. It mainly includes the frontal and the parietal branch(Figure 1). It is commonly used to treat the artery that supplies blood in moyamoya disease and as a vascular pedicle to provide repair of fascial flap[1.2.6.8.12.14]. However, clinically no strong awareness has been shown to the protect the superficial temporal artery, and it can be easily injured and occluded in the emergency craniotomy. The relevant reports on protecting it are few[15]. This study we used an improved incision to replace the traditional incision to protect the superficial temporal artery, as summarized below.

Methods

Inclusion criteria: (1) emergency patients undergoing craniotomy; (2) first operation. Exclusion criteria: (1) those with contusion, laceration, bleeding, and infection on the skin area to be operated; (2) those with a history of vasculitis; (3) aneurysmal hemorrhage. A total of 75 patients undergoing craniotomy in the Neurosurgery Department of the First Affiliated Hospital (YiJiShan Hospital) of Wannan Medical College from January 2019 to January 2021 were enrolled in this study. They were divided into traditional incision group (38 cases) and improved incision group (37 cases) according to the different surgical incision methods.

Basic information: In the traditional incision group, there were 22 male and 16 female patients, aged 60.24±11.53 years. This included 19 patients with craniocerebral injury, 14 patients with spontaneous hemorrhage, and 5 patients with large-area cerebral infarction. In the improved incision group, there were

19 male and 18 female patients, aged 60.11±13.96 years. Among them, there were 17 patients with craniocerebral injury, 18 patients with spontaneous hemorrhage, and 2 patients with large-area cerebral infarction.

Image examination: All the patients underwent head CT examination before the operation. Head CTA examinations were performed on the patients with spontaneous cerebral hemorrhage without a history of hypertension. Among them, one patient was diagnosed with moyamoya disease by preoperative examination, three were diagnosed by CTA examination after operation, and four cases (12.5%) were confirmed by DSA examination.

Incision method: The traditional frontotemporal incision is at the level of the flat zygomatic arch, 1cm in front of the tragus, above the upper edge of the auricle arc, behind the parietal tuberosity and in front of the forehead hairline, 3cm apart from the midline. When no large trauma craniotomy is required, the incision should be adjusted according to the need of the condition. The improved incision starts at the extension line of the zygomatic arch after the inner ear and goes up and back around the parietal tubercle, forward to the forehead hairline, and 3cm from the midline. When a large bone flap is not required for craniotomy, the incision is adjusted according to the need of the condition, and the part at the back of the ear may also be extended downward according if required (Figure 2).

Results

There were 38 cases with traditional incision, including 13 cases with superficial temporal artery injury. Only 8 of these cases (21%) underwent intraoperative anatomical separation of the main trunk of the superficial temporal artery. Whereas there were 37 cases with improved incision and none had injury. As the improved incision completely avoided the proximal end of the trunk and branch of the superficial temporal artery, there was no need to dissect the superficial temporal artery during the operation. Also, there was no injury of the superficial temporal artery when the cutaneous muscle flap was separated. This shows the obvious advantages in the protection of the superficial temporal artery. The patients in this group were followed up for 6 months. There was no superficial temporal artery occlusion and related complications in the improved incision group, while 13 cases had superficial temporal artery occlusion in the traditional incision group.

Discussion

Importance of superficial temporal artery protection

In recent years, superficial temporal artery-middle cerebral artery anastomosis has been used in the treatment of moyamoya disease. This improves the blood supply in ischemic patients and reduces the rebleeding rate in hemorrhagic patients[3.5.9.11.16.17]. However, in moyamoya patients undergoing DSA cerebrovascular angiography, we often find that the superficial temporal artery on one side is not visible. A common reason for which is iatrogenic injury occurring during an earlier craniotomy, performed to clear

the hematoma in bleeding. When the bypass criteria are met, the opportunity is lost due to the donor blood vessel. In this group of cases, up to 40% of them suffer from superficial temporal artery injury, and the proportion will be even higher because there are still operations not described in the record. Delayed hemorrhage, and temporalis swelling, and atrophy often happens clinically[4.7], however, they are overshadowed due to more serious clinical manifestations after head injury or cerebral hemorrhage. Therefore, they are not taken seriously.

Causes of superficial temporal artery injury during operation

The superficial temporal artery is easily damaged during the craniotomy. The main reasons for which are as follows: First, insufficient attention given by the surgeon. During the operation, the protection of deep brain tissue is mostly advocated, followed by the dura mater, and skull, thereby less attention is given to the scalp. In emergency surgery, to optimize rescue time, there are few people who dissect deliberately considering the protection of superficial temporal artery. Most of the superficial temporal artery is injured and occluded, and there are no obvious clinical consequences after the surgery, showing limited awareness of the surgeon to protect it. In this group, the rate of the cases, wherein the surgeons actively protected the superficial temporal artery was only 21%. In hospitals that cannot perform bypass surgery, there is a lack of understanding, and the rate may be even lower, indicating the lower awareness in protecting superficial temporal artery. Secondly, this could be due to the anatomical characteristics of the superficial temporal artery itself. The imaging study of the superficial temporal artery by multi-slice spiral CT revealed that the bifurcation and branches of the superficial temporal artery are complex and changeable in the upper and lower zygomatic arches(Figure 3)[10.13]. It is therefore not as constant as traditionally considered . Its backbone is mostly located on the zygomatic arch, and the distance between its position and the tragus varies from person to person. It is not reliable to protect the superficial temporal artery by empirically cutting the scalp 1 cm before the tragus. In an operation, the shape is often marked out on the body surface by touching the pulse. In some patients, the pulsation is not obvious. At such times, ultrasound and navigation can be used to assist positioning for protecting the superficial temporal artery. However, in emergency surgery or in primary hospitals, it has not been popularized yet.

Advantages and disadvantages of improved incision

To better protect the superficial temporal artery, there is no need to deliberately dissect and separate the blood vessel. According to the experience, we suggest of using an improved incision that starts behind the ear(Figure 4). In this study, those who used the improved incision were able to expose the key foramen, the root of the zygomatic arch and other important skull marks during the operation, and successfully complete the operation to achieve the purpose of decompression. Also, they ensured the integrity of the main trunk and main branches of the superficial temporal artery. The advantage being that it completely avoids the main trunk of the superficial temporal artery and the branches of the facial nerve during the incision of the scalp and also the incision of the root of the temporal muscle. This reduces the intraoperative bleeding and complications related to postoperative temporal muscle injury. It also fully exposes the temporal lobe and the posterior part of the middle skull base. Part of the incision is

located behind the ear, which is preferable, than the traditional incisions in the appearance. However, its disadvantage is that it may erroneously enter the external auditory canal when the cutaneous muscle flap is separated, and the exposure of the front part of the middle cranial fossa is slightly limited. To overcome these shortcomings, we marked supramastoid crest when separating the cutaneous muscle flap to prevent it from erroneously entering the external auditory canal. On the exposure of the front part of the middle skull base, with the help of an assistant, the temporal muscle was peeled upwards. The surgeon removed the squamous part of the temporal bone and the base of the skull was fully decompressed.

Conclusion

The superficial temporal artery plays an important role in some of the patients, and the awareness of protecting it should be enhanced during the operation. The improved incision was a simple and easy way to protect the superficial temporal artery. At least the superficial temporal artery should be treated differently when using the traditional incision for craniotomy. Suspected patients with moyamoya disease should be well protected before surgery, and even if separation and cut-off are inevitable, this needs to be fully explained.

Declarations

Funding (This study was supported by the Young and Middle-aged subjects of Wannan medical college (WK2019F18)).

Conflicts of interest (The authors have no financial or other conflicts of interest in relation to this research and its publication).

Availability of data and material (The data of this study are true and transparent)

Code availability (Not applicable)

Ethics approval (The study was approved by the institutional review board of the Yijishan Hospital of Wannan Medical College)

Consent to participate (Informed consent was obtained from all individual participants included in the study)

Consent for publication (All authors of this study agreed to publish the study)

Authors' contributions (Conception and design: all authors. Acquisition of data: Xinyun Fang. Analysis and interpretation of data: Renchun Yan. Drafting the article: Renchun Yan. Critically revising the article: all authors. Reviewed submitted version of manuscript: Renchun Yan. Approved the final version of the manuscript on behalf of all authors:Xinyun Fang. Administrative/technical/material support: Xinyun Fang).

References

1. Al-Qattan Mohammad M,One Pedicled Superficial Temporal Artery Hair-bearing Flap to Reconstruct Three Different Anatomical Areas of the Burnt Face: A Personal Technique.[J]Ann Plast Surg, 2021, 86: 159–161
2. Arosio Alberto Daniele,Coden Elisa,Karligkiotis Apostolos et al. Temporoparietal Fascia Flap Endonasal Transposition in Skull Base Reconstruction: Surgical Technique.[J].World Neurosurg, 2021, 146: 118
3. Abhinav Kumar,Furtado Sunil V, Nielsen Troels H et al (2020) Functional Outcomes After Revascularization Procedures in Patients With. Hemorrhagic Moyamoya Disease[J]Neurosurgery 86:257–265
4. Apruzzi Luca,Bossi Matteo,Bugna Carlotta et al. Giant Post-Traumatic Pseudoaneurysm of the Superficial Temporal Artery[J]Ann Vasc Surg, 2021, 70: 566.e11–566.e14
5. Chen Z, Zhang L, Qu J et al. Clinical analysis of combined revascularization in treating ischemic Moyamoya disease in adults.[J].Neurochirurgie, 2018, 64: 49–52
6. Ding J, Liu C,Cui J et al (2021) Efficacy of pre-expanded forehead flap based on the superficial temporal artery in correction of cicatricial ectropion of the lower eyelid.[J]. Br J Oral Maxillofac Surg 59:58–63
7. Das Atman Ranjan,Meena Rajesh Kumar,Doddamani Ramesh S et al. Postcraniotomy Spontaneous Extradural Hematoma Due to Superficial Temporal Artery Rupture.[J].Neurol India, 2020, 68: 1255–1256
8. Eyraud Q, Grivet D,Gleizal A et al. Superficial temporal artery perforator flap for reconstruction of periorbital and eyelid defects, a variant of the classic flaps dissected in perforator flap.[J].J Stomatol Oral Maxillofac Surg, 2020, undefined: undefined
9. Ishiguro Taichi,Okada Yoshikazu,Ishikawa Tatsuya (2019) et al. Efficacy of superficial temporal artery-middle cerebral artery double bypass in patients with hemorrhagic moyamoya disease: surgical effects for operated hemispheric sides.[. J]Neurosurg Rev 42:559–568
10. Hardy J-P,Benoît Bihin,Françoise Kayser et al. Anatomy and external landmarks of the superficial temporal artery using 3-dimensional computed tomography.[J]Surg Radiol Anat, 2021, 43: 283–290
11. Kim Jang Hun,Yoon Wonki,Kim Chi Kyung (2021) et al. Efficacy and Safety of Timely Urgent Superficial Temporal Artery-to-Middle Cerebral Artery Bypass Surgery in Patients with Acute Ischemic Stroke: A Single-Institutional Prospective Study and a Pooled. Analysis[J]Cerebrovasc Dis 50:34–45
12. Lee R,Wheeler Jonathan,Crawford Haemish,Temporoparietal Fascial Flap for Soft Tissue Reconstruction of Pediatric and Young Adult Foot Defects: A Case Series.[J].J Foot Ankle Surg, 2021, 60: 140–145
13. Rusu MC, Jianu AM, Rdoi PM. Anatomic variations of the superficial temporal artery[J]. Surgical and Radiologic Anatomy, 2021(Pt 3):1–6

14. Schultz Jerette J, Viviano Stephen L, Ayyala Haripriya S et al. Superficial temporal artery perforator flaps for reconstruction of intraoral defects.[J].Microsurgery, 2021, 41: 119–123
15. Soto Jose M,Feng Dongxia,Sun Huaiyu et al Novel Decompressive Hemicraniectomy Technique for Traumatic Brain Injury: Technical Note.[J].World Neurosurg, 2021, 146: 15–19
16. Tao Xiaoyang,Liu Yin,Chen Jun (2018) et al. Assessment of Single-Barrel Superficial Temporal Artery-Middle Cerebral Artery Bypass in Treatment for Adult Patients with Ischemic-Type Moyamoya Disease. [J]Med Sci Monit 24:7469–7474
17. Zhao Yahui,Yu Shaochen,Lu Junlin et al. Direct Bypass Surgery Vs. Combined Bypass Surgery for Hemorrhagic Moyamoya Disease: A Comparison of Angiographic Outcomes.[J].Front Neurol, 2018, 9: 1121

Figures

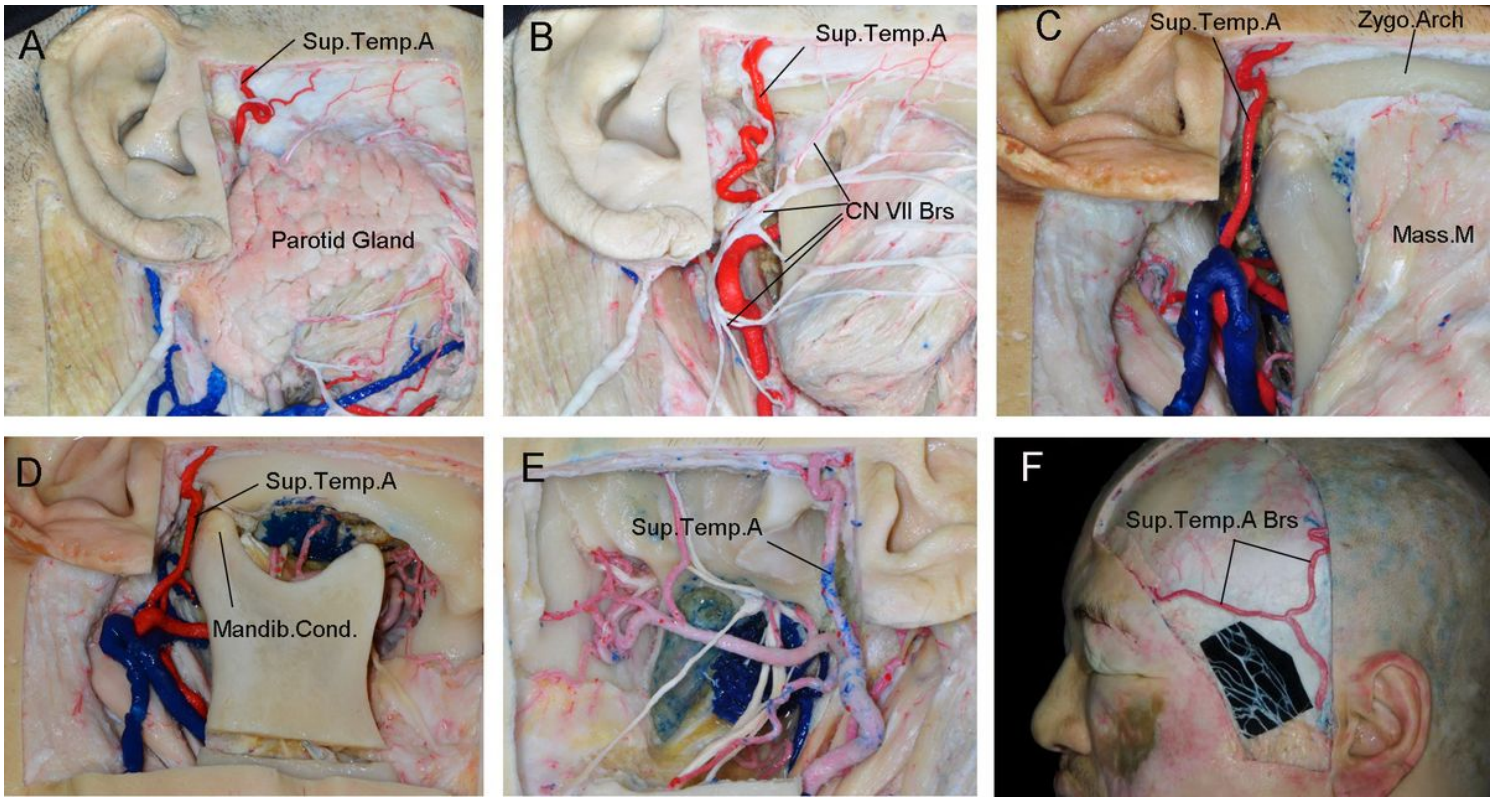

Figure 1

Layer by layer anatomy of superficial temporal artery. A.= artery; Brs.= branches;CN= cranial nerve; Cond.= condyle; M.= muscle; Mandib.=mandibular; N.=nerve; Proc.= process; Sup.= superior; Temp.= temporal, temporalis; Zygo.= zygomatic.

Figure 2

Traditional and improved incision lineation. A. Traditional incision B. Improved incision.

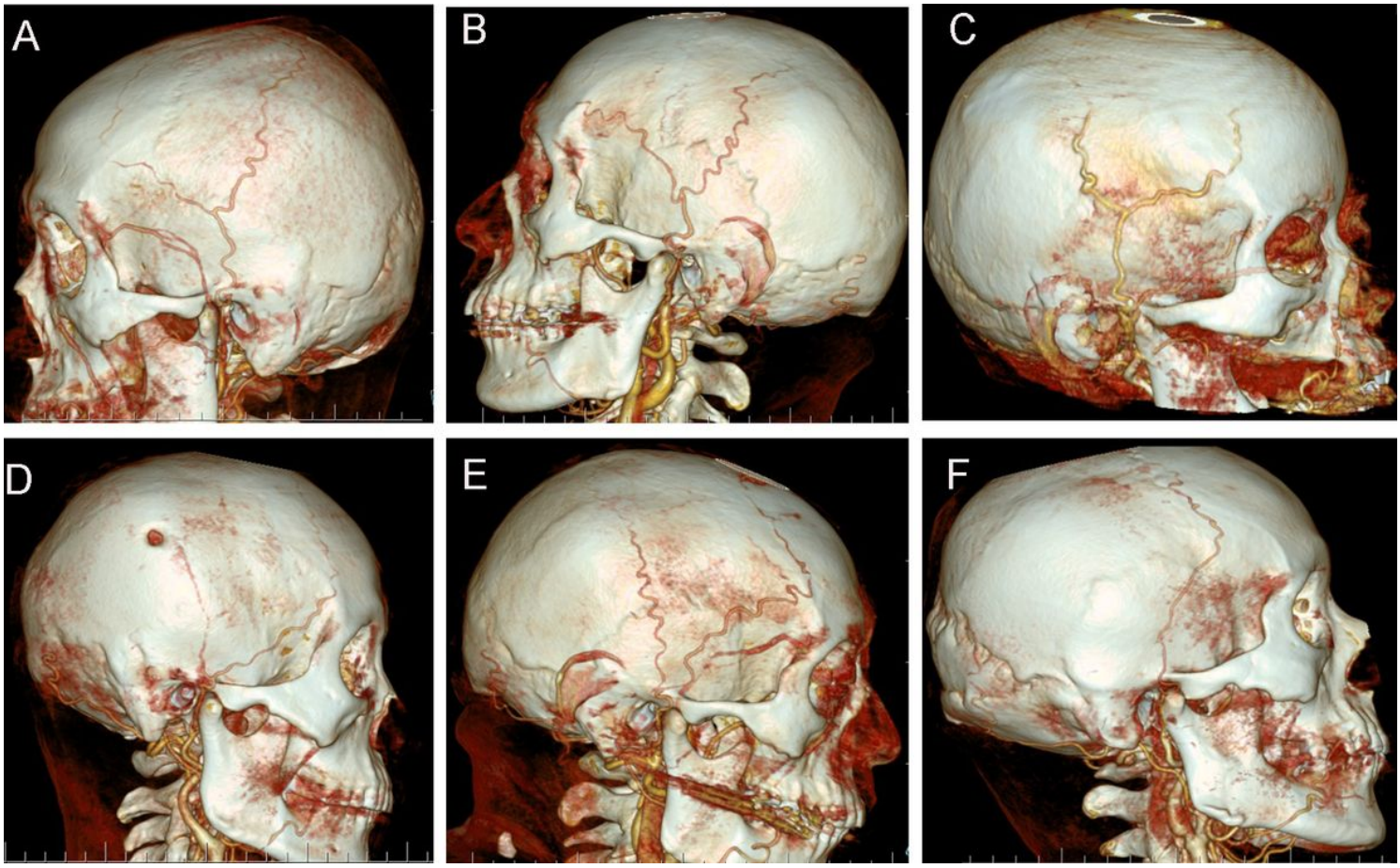

Figure 3

CTA showed different course and bifurcation of superficial temporal artery.

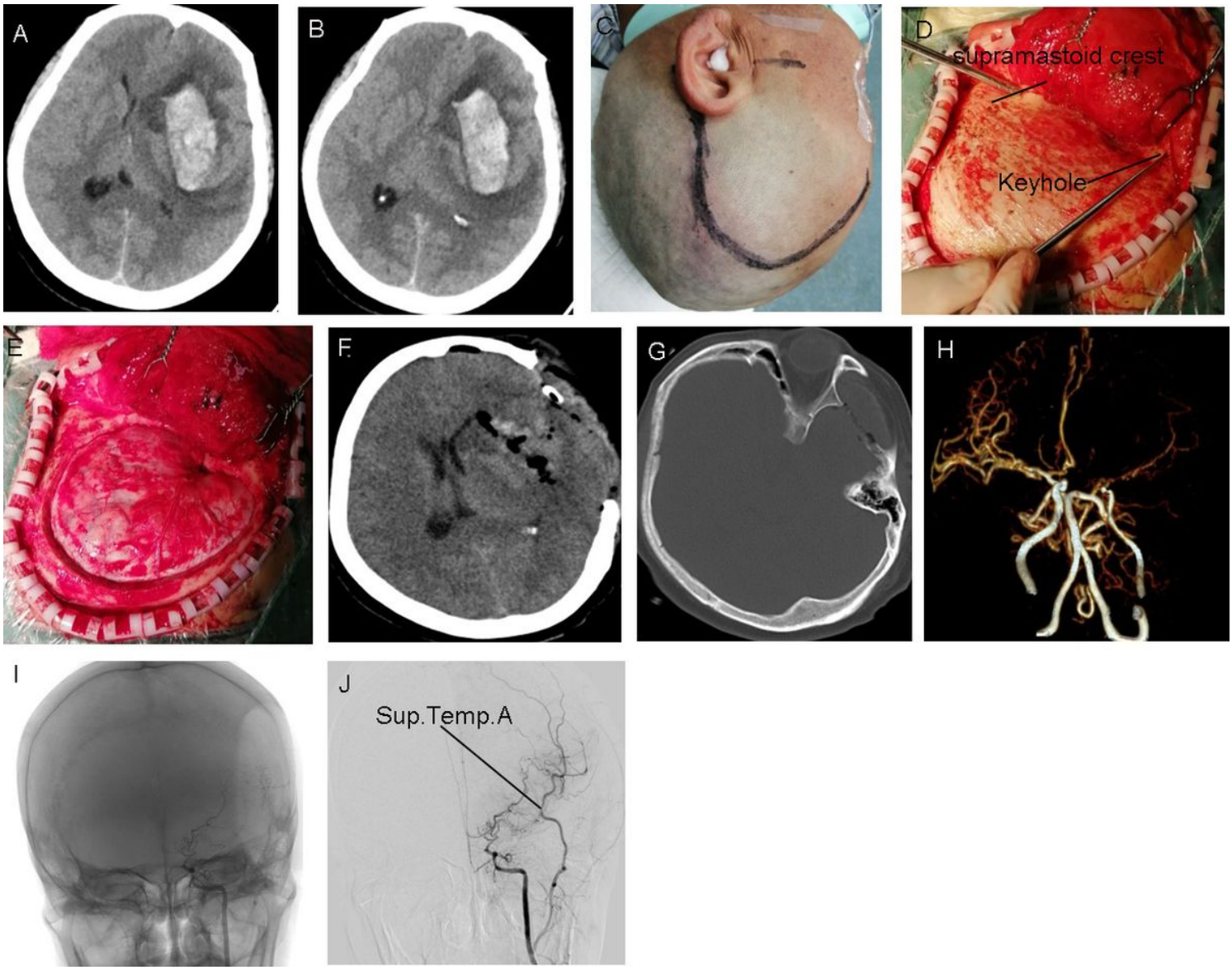

Figure 4

Clinical data of a case of spontaneous cerebral hemorrhage complicated with cerebral hernia. Because of cerebral hernia, there was no time for DSA examination before operation, the etiology could not be determined, moyamoya disease could not be ruled out, so we used the improved incision to protect the superficial temporal artery. A-B. Preoperative CT scan. C. Improved incision lineation. D-E. The intraoperative exposure was shown. F. The hematoma was completely removed after operation. G. The lower edge of bone window can also reach the level of middle skull base. H-I. Postoperative vascular examination showed moyamoya syndrome, superficial temporal artery intact protection.