

Assessment of Gentamicin and Cisplatin-Induced Kidney Damage Mediated via Necrotic and Apoptosis Genes in Albino Rats

Mohamed El_Sayed Barakat (✉ mambarakat2003@gmail.com)

Animal Health Research Institute <https://orcid.org/0000-0003-2778-619X>

Tarek Kamal Abouzed

Kafrelsheikh University

Eman Abd Elrahman Sherif

Kafrelsheikh University

Kadry Mohamed Sadek

Damanhur University

Adil Aldhahrani

Taif University

Nasr Elsayed Nasr

Kafrelsheikh University

Khaled Khailo

Kafrelsheikh University

Doaa Abdallha Dorghamm

Kafrelsheikh University

Research article

Keywords: Gentamycin, Cisplatin, Nephrotoxicity, TNF α , caspase 3, Bax, BCL2 genes

Posted Date: February 25th, 2021

DOI: <https://doi.org/10.21203/rs.3.rs-272049/v1>

License:   This work is licensed under a Creative Commons Attribution 4.0 International License.

[Read Full License](#)

Abstract

Background: Gentamycin (GM) is a low-cost, low-resistance antibiotic commonly used to treat gram-negative bacterial diseases. Cisplatin (Csp) is a platinum-derived anti-neoplastic agent. This experiment aimed to identify the early signs of gentamicin and cisplatin-induced nephrotoxicity in rats. 30 *Wistar* rats were divided into three groups of 10: a control group, which received no treatment; a gentamicin group administered by a dose of (100 mg/kg, IP) for 7 consecutive days, and a cisplatin group was administered intraperitoneal in a dose of (1.5mg/kg body weight) repeated twice a week for 3weeks. Results: Both experimental groups exhibited increased levels of creatinine, urea, and uric acid, with the cisplatin-treated group showing higher levels than the gentamicin group. Experimental groups also exhibited significantly increased malondialdehyde (MDA), reduced glutathione (GSH), and glutathione peroxidase (GSH-Px) with more pronounced effects in the cisplatin-treated group. Further, both experimental groups exhibited significant up-regulation of Tumor Necrosis Factor α (TNF- α), caspase-3, and Bax and downregulation of Bcl-2. Conclusion: These findings confirm the use of necrotic, apoptotic genes as early biomarkers in the detection of tubular kidney damage. Further, cisplatin was shown to have a greater nephrotoxic effect than gentamicin; therefore, its use should be constrained accordingly when co-administered with gentamicin.

Highlights On The Basic Findings Are

1. The early signs of gentamicin and cisplatin-induced nephrotoxicity in rats were identified.
2. Cisplatin was shown to have a greater nephrotoxic effect than gentamicin.

Background

The kidneys have a role within some key functions around homeostasis and detoxification, including the excretion of toxic metabolites and some medications [1]. As such, they play an important role in processing toxic drugs and are consequently more exposed to harmful substances via high renal blood flow, which transports metabolites and picks up toxic chemicals from the surrounding fluid [2]. Pharmacological interventions such as interleukin-2, Gentamicin, Ibuprofen, Vancomycin, Furosemide, and chemotherapeutic treatments containing cisplatin, carboplatin, and mitomycin, can have nephrotoxic effects [3].

The aminoglycoside, Gentamycin (GM) is a low-cost, low-resistance antibiotic commonly used to treat gram-negative bacterial diseases [4]. However, its nephrotoxicity and ototoxicity are significant factors leading to constraint in the use of aminoglycosides in general [5]. Gentamicin has the following nephrotoxic effects: 1) accumulation in the proximal convoluted tubule [6], which triggers 2) tubular necrosis and glomerular congestion, leading to glomerular and renal dysfunction [7]. Furthermore, it causes oxidative stress and inflammatory cascades, which are significant nephrotoxic factors [8].

Cisplatin or *cis-diamminedichloroplatinum II* (Csp) is a platinum-derived anti-neoplastic agent, commonly used in the treatment of carcinoma, lymphoma, and germ-cell tumors [9]. Despite being an efficient chemotherapeutic drug, cisplatin's nephrotoxicity limits its long-term use [10]. Consequently, it is mainly excreted by the kidneys [11] and accumulates in mitochondria, causing changes in bioenergetics [12]. Furthermore, cisplatin has been implicated in oxidative stress-induced kidney damage [13] as well as apoptosis of kidney tubular cells – although the mechanism for this is not well understood. Cisplatin's toxicity is thought to be mainly derived from DNA damage; prevention of protein formation; and damage to mitochondria, causing apoptosis [14]. Apoptosis is a significant cause of inflammation and implicated in several diseases of the kidney associated with nephrotoxic drugs [15, 16].

Apoptotic renal damage caused by gentamycin and cisplatin is heavily dependent on caspase-based signaling. Caspase-9 triggers the release of caspase-3 within the mitochondrial pathway [17]. The proteins Bax and Bcl-2 also play a significant role, with Bax serving a pro-apoptotic function and Bcl-2 as an anti-apoptotic. Specifically, Bcl-2 blocks cytochrome c activation by binding to the mitochondrial membrane [18]. Furthermore, nuclear translocation and the activation of TNF- α lead to oxidative stress and renal inflammation, which significantly impacts cytokine, chemokine, and adhesion molecule expression in the basal gene [19].

Results

Effects of Gentamicin and Cisplatin on biochemical parameters

Serum levels of creatinine, uric acid, and urea were significantly elevated in the gentamicin and cisplatin groups compared with the control group (Fig. 1), with cisplatin showing higher elevation.

Effects of Gentamicin and Cisplatin on kidney MDA, GSH, and GPx activities

MDA levels were significantly increased in the experimental groups compared with the control group, with the cisplatin-treated group showing the higher elevation. The cisplatin group also showed a significant decrease in GSH and GPx compared with the control group (Fig. 2).

Histopathological Analysis

Kidney tissue samples, previously stored in 10% neutral formalin, were paraffinised, sectioned, and stained with hematoxylin and eosin (H&E).

Quantitative determination of TNF- α , caspase-3, Bax, and Bcl-2 using real-time qPCR

Total RNA was isolated from kidney tissue using TRIzol, according to the manufacturer's instructions. RNA concentration was measured using the Nanodrop spectrophotometer (Nanodrop 2000c, Thermo Scientific, USA), while single strand complementary DNA was synthesized using the HiSenScript™ cDNA synthesis kit. This involved mixing 10 μ l 2X RT reaction buffer, 1 μ l enzyme mix solution, and 1 μ g RNA,

then made up to 20 μ l with RNase free water. This was incubated for 30 minutes at 50°C then 10 minutes at 85°C.

qPCR reactions were carried out using SYBR Green qPCR Master Mix and specific primers (see Table 1). The following protocol was used: Initial denaturation for 10 minutes at 92°C; 40 cycles at 92°C for 15s, 60°C for 30s and 72°C for 30s. The $2^{-\Delta\Delta Ct}$ method [64] was used to estimate the differences in gene expression. This was standardized against β -actin and mRNA levels were recorded relative to the control. After amplification, the products were verified using a melting curve analysis.

Statistical analysis

GraphPad Prism 5 (GraphPad Software, San Diego, USA) was used to conduct a one-way analysis of variance (ANOVA), followed by Tukey's multiple comparisons post hoc test. $P < 0.05$ was considered statistically significant, with results expressed as means \pm standard error (SE).

Discussion

Elevated serum creatinine and urea nitrogen levels can lead to renal dysfunction [20, 21]. In particular, increased serum levels of creatinine inhibits glomerular filtration [22], while high nitrogen levels in blood urea can indicate renal failure to cleanse urea [23]. This experiment found that administering gentamicin led to a significant increase in creatinine, urea, and uric acid in rats. These conform with findings by [24, 25], who also reported increased serum creatinine elevation and blood urea and uric acid, leading to the suggestion that gentamicin is nephrotoxic - although its exact mechanism is unclear. Some studies have implicated ROS formation caused by aminoglycoside antibiotics. Lipid peroxidation generates MDA in the tissues, which inhibits the amount of polyunsaturated fatty acids, which act as a substratum free radicals. This interaction, between phospholipids and aminoglycosides, is the first step in developing gentamycin toxicity [26]. Moreover, Gentamicin forms an Iron-GEN complex, with iron liberated from the renal cortical mitochondria. This also triggers free radical formation and enhances ROS generation [27].

The increased MDA levels observed in this experiment aligns with the previous research [9, 28], indicating either elevated serum creatinine and urea levels, or elevated MDA in the kidney tissue. This suggests a link between lipid peroxidation and nephrotoxicity, oxidative stress, and kidney dysfunction.

Glutathione plays a critical role in cell maintenance. However, xenobiotics or peroxide-dependent changes in GSH tissue and antioxidant enzyme activity are a contentious topic at the moment [24]. This experiment observed that GSH levels in the kidney are inhibited by gentamicin, correlating with the findings of [29–30]. These works found a link between gentamicin-induced nephrotoxicity, low GSH, and GSH-Px activity in the renal cortex, which might in turn lead to oxidative damage due to decreased antioxidant defenses. Inactivation of GSH-Px, CAT, and SOD would therefore fail to defend against the increased ROS levels produced by gentamicin. Gentamicin accumulates in the renal proximal convoluted tubules, degenerating the brush border membranes, generating free radicals, reducing antioxidant defenses, and causing glomerular congestion, acute tubular necrosis, and ultimately kidney failure [7, 31,

32]. Likewise, gentamicin administration causes renal oxidative damage due to antioxidant defense enzyme deficiencies [33, 34].

Tumor necrosis factor (TNF- α) is implicated in the pathogenesis of acute nephrotoxin-induced renal failure as well as other forms of kidney damage [35, 36]. The administration of gentamicin in our study caused TNF- α to increase significantly. These results are consistent with [7], who found that gentamicin-induced tubular injury caused inflammation at the site of the necrosis.

The pro-apoptotic gene, Bax, plays a key role, causing the release of cytochrome c, activating procaspase-9. This initiates various caspase streams including caspase-3 [37], which cleaves specific target proteins, causing the number of apoptotic cells to increase. Conversely, Bcl-2, an antiapoptotic protein, binds to the external membrane of mitochondria, blocking cytochrome c activation [18].

In this experiment, gentamicin upregulated TNF- α , Bax, and Caspase-3 mRNA expression, and downregulated Bcl-2 mRNA expression. This concurs with [38, 39], whose findings confirmed the same effects of gentamicin administration. From this, it can be concluded that gentamicin therapy can lead to inflammation and apoptosis in renal tissues, followed by necrosis.

The clinical effects of cisplatin are linked to dosage, but high doses can be both nephrotoxic and neurotoxic [40]. Concerning the renal system, cisplatin damages the proximal tubules [41].

This experiment found that cisplatin administered rats exhibited increased creatinine, urea, and uric acid and this effect was more pronounced than in rats treated with gentamicin, agreeing with the work by [42, 43]. Histopathological observations confirmed damage to the glomerular wall, epithelial degeneration, intertubular hemorrhage, and slight glomerular hypertrophy.

Cisplatin-generated ROS targets organelles, including two microsomes and the mitochondria [44, 45], causing apoptosis and necrosis [46, 47]. Some molecules are also targeted, such as lipids and proteins, causing an increase in MDA and a decrease in the antioxidants GSH and GPx [48, 49]. This work observed that rats administered with cisplatin exhibited increased tissue MDA and reduced kidney GSH, while the production of GSH-Px remained unchanged. These results agree with [50, 51], who recorded imbalanced antioxidant status caused by the buildup of excessive cisplatin-produced ROS. This led to depleted GSH and lipid peroxidation.

Apoptosis is central to many renal disorders, especially those that involve inflammatory processes or induced by nephrotoxic drugs [15, 16]. The present experiment found that cisplatin administration upregulated TNF- α , Bax, and caspase-3 mRNA expression, and downregulated Bcl-2 mRNA expression. These effects were more pronounced than in the gentamycin-administered group and agree with findings by [52–53].

Conclusion

This experiment confirmed the key pathogenic role played by ROS, TNF- α , and apoptotic proteins such as Bax, Bcl-2, and caspase-3 in gentamicin and cisplatin-induced nephrotoxicity. Furthermore, it found that of the two, cisplatin has the most damaging effect on the kidney.

Materials And Methods

Chemicals

Gentamicin ampoules 80mg (Alexandria Chemical Co., Egypt), creatinine kits (Diamond, Egypt), urea kits (Biomed, Egypt), uric acid kits (Spectrum, Egypt), malondialdehyde, glutathione reductase, and glutathione peroxidase (Biodiagnostics Co., Egypt), trizol (GENEzol™ RNA extraction reagent, Lot#:30117B07003; Genetix Biotech Asia Pvt. Ltd., India), single-strand complementary DNA kit (cat.No.25014, iNtRON Biotechnology, South Korea), SYBR Green qPCR (cat \neq RT500, Enzynomics, South Korea).

Animals

This experiment was designed using 'the ethical principles and guidelines for the care and use of laboratory animals', and granted ethical approval by the Research Ethics Committee, Faculty of Veterinary Medicine, Kafrelsheik University. Thirteen adult male Wistar rats, each weighing 160-200g, were obtained from faculty of Science lab, Kafrelsheikh University. The rats were kept at 25°C on a 12/12h light/dark cycle, in single plastic cages with bedding, with access to standard rat food and water *ad libitum*. They handled for one week before the study to adapt to their surroundings.

Experimental Design

Rats were randomly (ranking method) assigned to one of three groups (10 rats/group): 1) Control group, who received no intervention and maintained a regular diet; 2) Gentamicin group, who were administered 100 mg/kg BW IP gentamicin daily for 7 days [54, 55]; 3) Cisplatin group, who were administered 1.5 mg/kg BW IP twice a week for three weeks [lass="CitationRef">56].

Blood Sample

Following the experimental phase, rats were anesthetized using 5% isoflurane in an induction chamber [57]. Following the loss of righting reflex, rats were rapidly transferred to a nose cone mask, and maintained with isoflurane with room air. Isoflurane anesthesia was performed using a rodent inhalant anesthesia apparatus (SomnoSuite Small Animal Anesthesia System, Kent Scientific Corporation, Connecticut). The flow rate of isoflurane was determined using following formula; Flow rate (ml/min) = $0.65 \times$ body weight (g). and blood samples (6 samples/group) were collected from retro-orbital venous

plexuses (7ml blood/sample). The selection was not based on any pre-specified effect. The samples were centrifuged for 15 minutes at 3000 rpm in non-heparinized tubes. Sera were separated and stored at -20°C for later use. The investigators were not blinded during data collection. Blinding was used during analysis. Computational analysis was not performed blinded.

Tissue Sample

Rats were anesthetized with isoflurane and executed via cervical dislocation (euthanasia) and the kidneys were removed. The left kidneys were washed with liquid nitrogen then stored at -80°C for real-time assessment, while a portion was separated (1g/sample) and stored at -20°C for MDA, GSH, and GSH-Px analysis. Each tissue sample (6 samples/group) was homogenized in 5 ml phosphate buffer pH 7.4 using an electrical homogenizer where the sample was maintained on ice. After homogenization, N-ethylmaleimide was added directly to prevent oxidation of GSH. Tissue homogenate was centrifuged at $1200 \times g$ for 20 min at 4 °C. The resulting supernatant was isolated and used in the assessment of the MDA, GSH, and GSH-Px in the renal tissue. The right kidneys were stored in 10% formalin for histopathological analysis. All rats and remnants of the samples were buried in the strict hygienically controlled properly constructed burial pit.

Biochemical Analysis

Colorimetric analysis was carried out on creatinine [58], urea [59], and uric acid [60], while calorimetric analysis of kidney homogenate measured malondialdehyde [61], reduced glutathione [62], and glutathione peroxidase [63].

Declarations

Ethics approval and consent to participate

Ethical approval for the experimental procedures of the study was obtained from the Animal Ethics Committee at Kafrelsheikh University, Egypt.

Consent for publication

Not applicable

Availability of data and materials

The datasets used and/or analyzed during the current study are available from corresponding author on reasonable request.

Competing interests

The authors declare that they have no competing interests

Funding

This research received no funding from any personal or public institute.

Authors' Contribution

All authors conducted the experiment and data analysis, and contributed to the preparation of this paper.

References

1. Ferguson MA, Vaidya VS, Bonventre JV. Biomarkers of nephrotoxic acute kidney injury. *Toxicology*. 2008;245(3):182–93.
2. Bennett WM. Drug nephrotoxicity: an overview. *Ren Fail*. 1997;19(2):221–4.
3. Schetz M, Dasta J, Goldstein S, Golper T. Drug-induced acute kidney injury. *Curr Opin Crit Care*. 2005;11(6):555–65.
4. del Valle DS, Imbrogno M, Fernandez E. Gentamicin in pediatric infections caused by gram-negative organisms. *The Journal of infectious diseases*. 1969;119(4/5):453–6.
5. Sun X, Zhang B, Hong X, Zhang X, Kong X. Histone deacetylase inhibitor, sodium butyrate, attenuates gentamicin-induced nephrotoxicity by increasing prohibitin protein expression in rats. *European journal of pharmacology* 2013, 707, (1–3), 147–154.
6. Ali B. Gentamicin nephrotoxicity in humans and animals: some recent research. *General Pharmacology: The Vascular System*. 1995;26(7):1477–87.
7. Balakumar P, Rohilla A, Thangathirupathi A. Gentamicin-induced nephrotoxicity: do we have a promising therapeutic approach to blunt it? *Pharmacological Research* 2010, 62, (3), 179–186.
8. Bledsoe G, Shen B, Yao Y-Y, Hagiwara M, Mizell B, Teuton M, Grass D, Chao L, Chao J. Role of tissue kallikrein in prevention and recovery of gentamicin-induced renal injury. *Toxicological sciences*. 2008;102(2):433–43.
9. Atessahin A, Yilmaz S, Karahan I, Ceribasi AO, Karaoglu A. Effects of lycopene against cisplatin-induced nephrotoxicity and oxidative stress in rats. *Toxicology* 2005, 212, (2–3), 116–123.
10. Çayır K, Karadeniz A, Şimşek N, Yıldırım S, Karakuş E, Kara A, Akkoyun HT, Şengül E. Pomegranate seed extract attenuates chemotherapy-induced acute nephrotoxicity and hepatotoxicity in rats. *J Med Food*. 2011;14(10):1254–62.
11. Ciarimboli G, Deuster D, Knief A, Sperling M, Holtkamp M, Edemir B, Pavenstädt H, Lanvers-Kaminsky C; am Zehnhoff-Dinnesen A, Schinkel AH, Organic cation transporter 2 mediates cisplatin-induced oto- and nephrotoxicity and is a target for protective interventions. *The American journal of pathology* 2010, 176, (3), 1169–1180.
12. Santos N, Bezerra CC, Martins N, Curti C, Bianchi M, Santos A. Hydroxyl radical scavenger ameliorates cisplatin-induced nephrotoxicity by preventing oxidative stress, redox state unbalance,

- impairment of energetic metabolism and apoptosis in rat kidney mitochondria. *Cancer chemotherapy and pharmacology* 2008, 61, (1), 145.
13. Hosohata K. Role of oxidative stress in drug-induced kidney injury. *Int J Mol Sci.* 2016;17(11):1826.
 14. Santos N, Catao C, Martins N, Curti C, Bianchi M, Santos A. Cisplatin-induced nephrotoxicity is associated with oxidative stress, redox state unbalance, impairment of energetic metabolism and apoptosis in rat kidney mitochondria. *Arch Toxicol.* 2007;81(7):495–504.
 15. Sahu BD, Tatireddy S, Koneru M, Borkar RM, Kumar JM, Kuncha M, Srinivas R, Sistla R. Naringin ameliorates gentamicin-induced nephrotoxicity and associated mitochondrial dysfunction, apoptosis and inflammation in rats: possible mechanism of nephroprotection. *Toxicol Appl Pharmacol.* 2014;277(1):8–20.
 16. Servais H, Van Der Smissen P, Thirion G, Van der Essen G, Van Bambeke F, Tulkens PM, Minget-Leclercq M-P. Gentamicin-induced apoptosis in LLC-PK1 cells: involvement of lysosomes and mitochondria. *Toxicol Appl Pharmacol.* 2005;206(3):321–33.
 17. Chen Y-C, Chen C-H, Hsu Y-H, Chen T-H, Sue Y-M, Cheng C-Y, Chen T-W. Leptin reduces gentamicin-induced apoptosis in rat renal tubular cells via the PI3K-Akt signaling pathway. *European journal of pharmacology* 2011, 658, (2–3), 213–218.
 18. Kalkan Y, Kapakin KAT, Kara A, Atabay T, Karadeniz A, Simsek N, Karakus E, Can I, Yildirim S, Ozkanlar S. Protective effect of Panax ginseng against serum biochemical changes and apoptosis in kidney of rats treated with gentamicin sulphate. *J Mol Histol.* 2012;43(5):603–13.
 19. Donate-Correa J, Martín-Núñez E, Muros-de-Fuentes M, Mora-Fernández C, Navarro-González JF, Inflammatory cytokines in diabetic nephropathy. *Journal of diabetes research* 2015, 2015.
 20. Patel Manali B, Deshpande S, Shah G. Evaluation of efficacy of vitamin E and N-acetyl cysteine in gentamicin-induced nephrotoxicity in rats. *Ren Fail.* 2011;33(3):341–7.
 21. Pai PG, Chamari Nawarathna S, Kulkarni A, Habeeba U, Reddy C, Teerthanath S, Shenoy S, J. P., Nephroprotective effect of ursolic acid in a murine model of gentamicin-induced renal damage. *ISRN pharmacology* 2012, 2012.
 22. Vaidya VS, Ferguson MA, Bonventre JV. Biomarkers of acute kidney injury. *Annu Rev Pharmacol Toxicol.* 2008;48:463–93.
 23. Arora MK, Reddy K, Balakumar P. The low dose combination of fenofibrate and rosiglitazone halts the progression of diabetes-induced experimental nephropathy. *Eur J Pharmacol.* 2010;636(1–3):137–44.
 24. Ateşşahin A, Karahan I, Yilmaz S, Çeribaşı A, Princci I. The effect of manganese chloride on gentamicin-induced nephrotoxicity in rats. *Pharmacol Res.* 2003;48(6):637–42.
 25. Al-Majed AA, Mostafa AM, Al-Rikabi AC, Al-Shabanah OA. Protective effects of oral arabic gum administration on gentamicin-induced nephrotoxicity in rats. *Pharmacological Research* 2002, 46, (5), 445–451.
 26. Wiland P, Szechcinski J. Proximal tubule damage in patients treated with gentamicin or amikacin. *Pol J Pharmacol.* 2003;55(4):631–7.

27. Yanagida C, Ito K, Komiya I, Horie T. Protective effect of fosfomycin on gentamicin-induced lipid peroxidation of rat renal tissue. *Chemico-Biol Interact.* 2004;148(3):139–47.
28. Cuzzocrea S, Mazzon E, Dugo L, Serraino I, Di Paola R, Britti D, De Sarro A, Pierpaoli S, Caputi AP, Masini E. A role for superoxide in gentamicin-mediated nephropathy in rats. *Eur J Pharmacol.* 2002;450(1):67–76.
29. Kehrer JP. Free radicals as mediators of tissue injury and disease. *Critical reviews in toxicology* 1993, 23, (1), 21–48.
30. Abdel-naim Ab, Abdel-wahab Mh, Attia F. f., Protective effects of vitamin E and probucol against gentamicin-induced nephrotoxicity in rats. *Pharmacol Res.* 1999;40(2):183–7.
31. Whiting P, Brown P. The relationship between enzymuria and kidney enzyme activities in experimental gentamicin nephrotoxicity. *Ren Fail.* 1996;18(6):899–909.
32. Abdel-Raheem IT, Abdel-Ghany AA, Mohamed GA. Protective effect of quercetin against gentamicin-induced nephrotoxicity in rats. *Biological Pharmaceutical Bulletin.* 2009;32(1):61–7.
33. Maldonado PD, Barrera D, Medina-Campos ON, Hernández-Pando R, Ibarra-Rubio MaE, Pedraza-Chaverrí J. Aged garlic extract attenuates gentamicin induced renal damage and oxidative stress in rats. *Life Sciences* 2003, 73, (20), 2543–2556.
34. Pedraza-Chaverrí J, Maldonado PD, Medina-Campos ON, Olivares-Corichi IM; de los Ángeles Granados-Silvestre, M. a.; Hernández-Pando R, Ibarra-Rubio M a. E., Garlic ameliorates gentamicin nephrotoxicity: relation to antioxidant enzymes. *Free Radical Biology and Medicine* 2000, 29, (7), 602–611.
35. Shulman LM, Yuhas Y, Frolkis I, Gavendo S, Knecht A, Eliahou HE. Glycerol induced ARF in rats is mediated by tumor necrosis factor- α . *Kidney international.* 1993;43(6):1397–401.
36. Deng J, Kohda Y, Chiao H, Wang Y, Hu X, Hewitt SM, Miyaji T, Mcleroy P, Nibhanupudy B, Li S. Interleukin-10 inhibits ischemic and cisplatin-induced acute renal injury. *Kidney international.* 2001;60(6):2118–28.
37. Wang K. Molecular mechanisms of hepatic apoptosis. *Cell death & disease* 2014, 5, (1), e996.
38. El Gamal AA, AlSaid MS, Raish M, Al-Sohaibani M, Al-Massarani SM, Ahmad A, Hefnawy M, Al-Yahya M, Basoudan OA, Rafatullah S. Beetroot (*Beta vulgaris* L.) extract ameliorates gentamicin-induced nephrotoxicity associated oxidative stress, inflammation, and apoptosis in rodent model. *Mediators of inflammation* 2014, 2014.
39. Juan S-H, Chen C-H, Hsu Y-H, Hou C-C, Chen T-H, Lin H, Chu Y-L, Sue Y-M. Tetramethylpyrazine protects rat renal tubular cell apoptosis induced by gentamicin. *Nephrology Dialysis Transplantation.* 2006;22(3):732–9.
40. O'Dwyer PJ, Stevenson JP, Johnson SW. Clinical status of cisplatin, carboplatin, and other platinum-based antitumor drugs. *Cisplatin: chemistry and biochemistry of a leading anticancer drug* 1999, 29–69.
41. Gonzalez-Vitale JC, Hayes DM, Cvitkovic E, Sternberg SS. The renal pathology in clinical trials of cisplatinum (II) diamminedichloride. *Cancer* 1977, 39, (4), 1362–1371.

42. Wang L, Lin S, Li Z, Yang D, Wang Z. Protective effects of puerarin on experimental chronic lead nephrotoxicity in immature female rats. *Human & experimental toxicology* 2013, 32, (2), 172–185.
43. Liu C-M, Ma J-Q, Sun Y-Z. Puerarin protects rat kidney from lead-induced apoptosis by modulating the PI3K/Akt/eNOS pathway. *Toxicol Appl Pharmacol.* 2012;258(3):330–42.
44. Liu H, Baliga R. Cytochrome P450 2E1 null mice provide novel protection against cisplatin-induced nephrotoxicity and apoptosis. *Kidney international.* 2003;63(5):1687–96.
45. Pabla N, Dong Z. Cisplatin nephrotoxicity: mechanisms and renoprotective strategies. *Kidney international* 2008, 73, (9), 994–1007.
46. Çetin R, Devrim E, Kılıçoğlu B, Avcı A, Çandır Ö, Durak İ. Cisplatin impairs antioxidant system and causes oxidation in rat kidney tissues: possible protective roles of natural antioxidant foods. *J Appl Toxicol.* 2006;26(1):42–6.
47. Bai J, Cederbaum AI. Mitochondrial catalase and oxidative injury. *Neurosignals.* 2001;10(3–4):189–99.
48. Sahu BD, Kalvala AK, Koneru M, Kumar JM, Kuncha M, Rachamalla SS, Sistla R. Ameliorative effect of fisetin on cisplatin-induced nephrotoxicity in rats via modulation of NF- κ B activation and antioxidant defence. *PloS one* 2014, 9, (9), e105070.
49. Sahu BD, Kuncha M, Sindhura GJ, Sistla R. Hesperidin attenuates cisplatin-induced acute renal injury by decreasing oxidative stress, inflammation and DNA damage. *Phytomedicine.* 2013;20(5):453–60.
50. Kim Y-H, Kim Y-W, Oh Y-J, Back N-I, Chung S-A, Chung H-G, Jeong T-S, Choi M-S, Lee K-T. Protective effect of the ethanol extract of the roots of *Brassica rapa* on cisplatin-induced nephrotoxicity in LLC-PK1 cells and rats. *Biological Pharmaceutical Bulletin.* 2006;29(12):2436–41.
51. Sugihara K, Nakano S, Koda M, Tanaka K, Fukuishi N, Gemba M. Stimulatory effect of cisplatin on production of lipid peroxidation in renal tissues. *The Japanese Journal of Pharmacology* 1987, 43, (3), 247–252.
52. Means TK, Pavlovich RP, Roca D, Vermeulen MW, Fenton MJ. Activation of TNF- α transcription utilizes distinct MAP kinase pathways in different macrophage populations. *J Leukoc Biol.* 2000;67(6):885–93.
53. Nowak G. Protein kinase C-and ERK1/2 mediate mitochondrial dysfunction, decreases in active Na transport, and cisplatin-induced apoptosis in renal cells. *J Biol Chem.* 2002;277:43377–88.
54. Cekmen M, Otunctemur A, Ozbek E, Cakir SS, Dursun M, Polat EC, Somay A, Ozbay N. Pomegranate extract attenuates gentamicin-induced nephrotoxicity in rats by reducing oxidative stress. *Ren Fail.* 2013;35(2):268–74.
55. Otunctemur A, Ozbek E, Cekmen M, Cakir SS, Dursun M, Polat EC, Somay A, Ozbay N. Protective effect of montelukast which is cysteinyl-leukotriene receptor antagonist on gentamicin-induced nephrotoxicity and oxidative damage in rat kidney. *Ren Fail.* 2013;35(3):403–10.
56. Hamers FP, Brakkee JH, Cavalletti E, Tedeschi M, Marmonti L, Pezzoni G, Neijt JP, Gispen WH. Reduced glutathione protects against cisplatin-induced neurotoxicity in rats. *Cancer research.* 1993;53(3):544–9.

57. Tsukamoto A, Uchida K, Maesato S, Sato R, Kanai E, Inomata T. Combining isoflurane anesthesia with midazolam and butorphanol in rats. *Exp Anim.* 2016;65(3):223–30.
58. Young DS, *Effects of drugs on clinical laboratory tests.* AACCC press Washington, DC: 1995; Vol. 4.
59. Chaney AL, Marbach EP. Modified reagents for determination of urea and ammonia. *Clin Chem.* 1962;8:130–2.
60. Fossati P, Prencipe L, Berti G. Use of 3, 5-dichloro-2-hydroxybenzenesulfonic acid/4-aminophenazone chromogenic system in direct enzymic assay of uric acid in serum and urine. *Clinical chemistry.* 1980;26(2):227–31.
61. Ohkawa H, Ohishi N, Yagi K. Assay for lipid peroxides in animal tissues by thiobarbituric acid reaction. *Analytical biochemistry* 1979, 95, (2), 351–358.
62. Beutler E, Duron O, Kelly M. Colorimetric method for determination of glutathione reduced. *J Lab Clin Med.* 1963;61:882.
63. Paglia DE, Valentine WN. Studies on the quantitative and qualitative characterization of erythrocyte glutathione peroxidase. *J Lab Clin Med.* 1967;70(1):158–69.
64. Yuan JS, Reed A, Chen F, Stewart CN. Statistical analysis of real-time PCR data. *BMC Bioinform.* 2006;7(1):85.

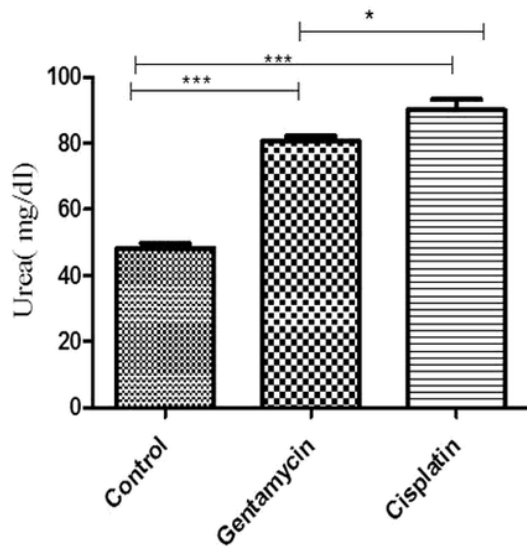
Tables

Table (1): Sequences of primers used in qPCR.

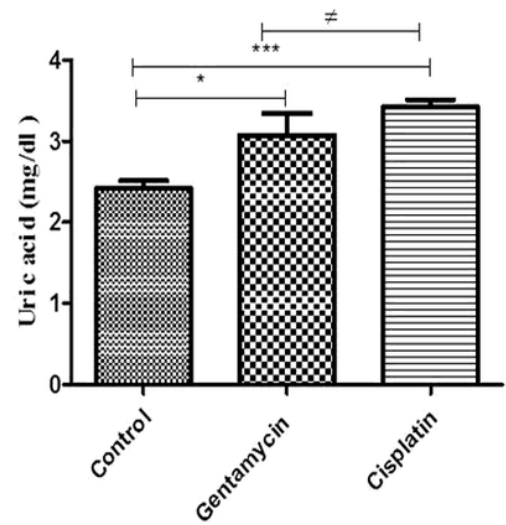
Gene	Accession no	Direction	Primer sequence
Bcl2	L14680	Sense	GACTTCGCCGAGATGTCCAG
		Antisense	GTGCAGGTGCCGGTTCAGG
Bax	U49729	Sense	AGGTCTTTTTCCGAGTGGCAGC
		Antisense	CCGGAGGAAGTCCAATGTCC
Caspase 3	GCA-00000189504	Sense	GGTATTGAGACAGACAGTGG
		Antisense	CATGGGATCTGTTTCTTTGC
TNF-a	GCA-00000189504	Sense	AAATGGGCTCCCTCTCATCAGTTC
		Antisense	TCTGCTTGGTGGTTTGCTACGAC
β-actin	V01217	Sense	GGACCTGACAGACTACC
		Antisense	GGCATAGAGGTCTTTACGG

Figures

A



B



C

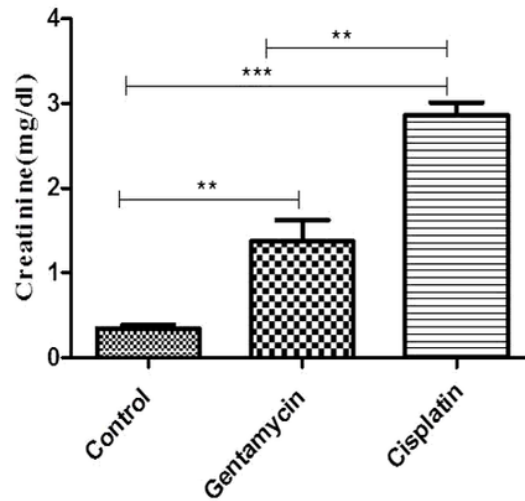


Figure 1

Figure 1

Effect of Gentamycin and cisplatin (a) Urea (mg/dl) (b) Uric acid (mg/dl) , (c) creatinine (mg/dl) the result represent the means \pm SEM * $P < 0.05$

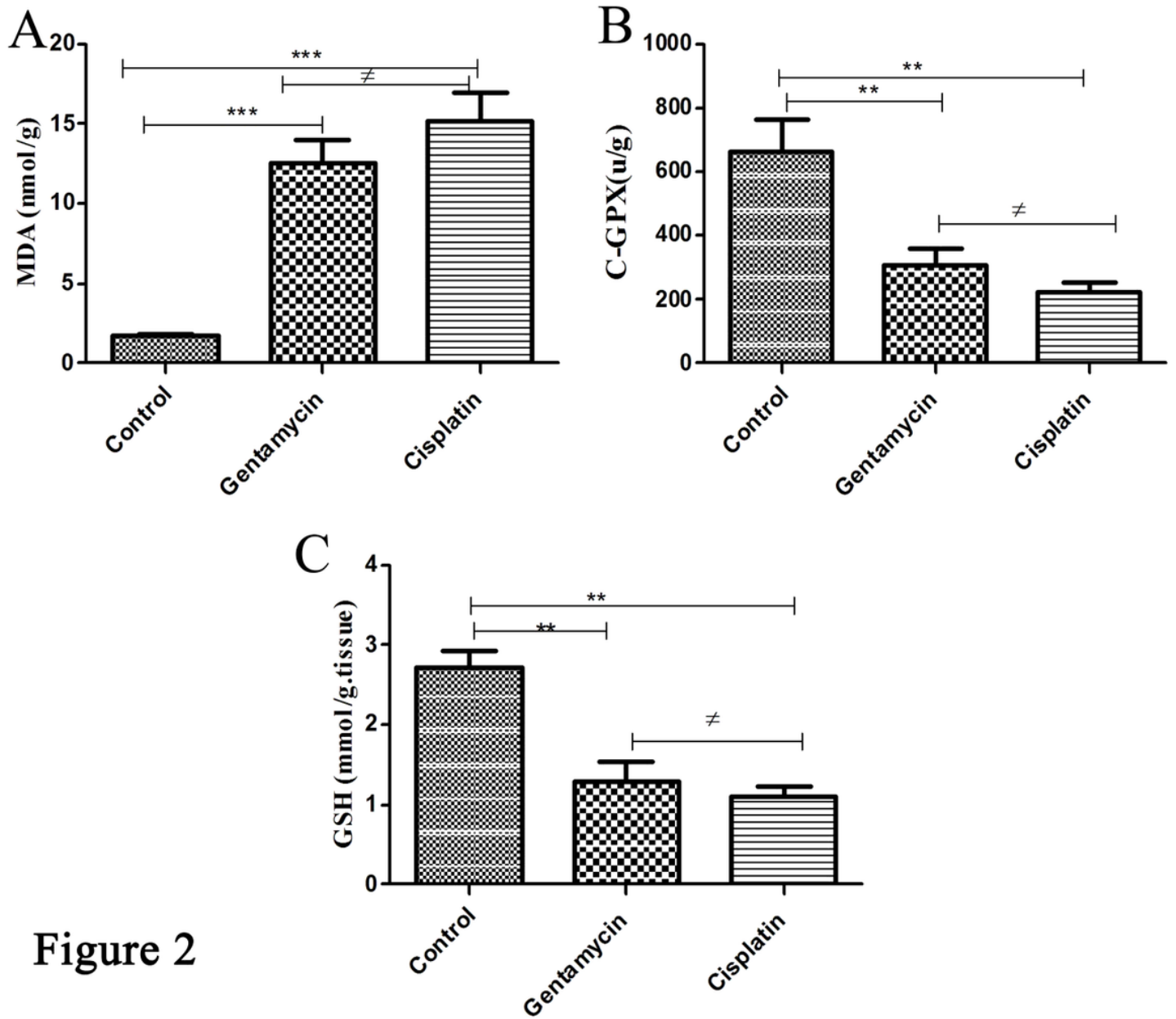


Figure 2

Figure 2

Effect of Gentamycin and cisplatin (a) MDA (nmol/g) (b) C-GPX (mg/dl) , the result represent the means \pm SEM * $P < 0.05$

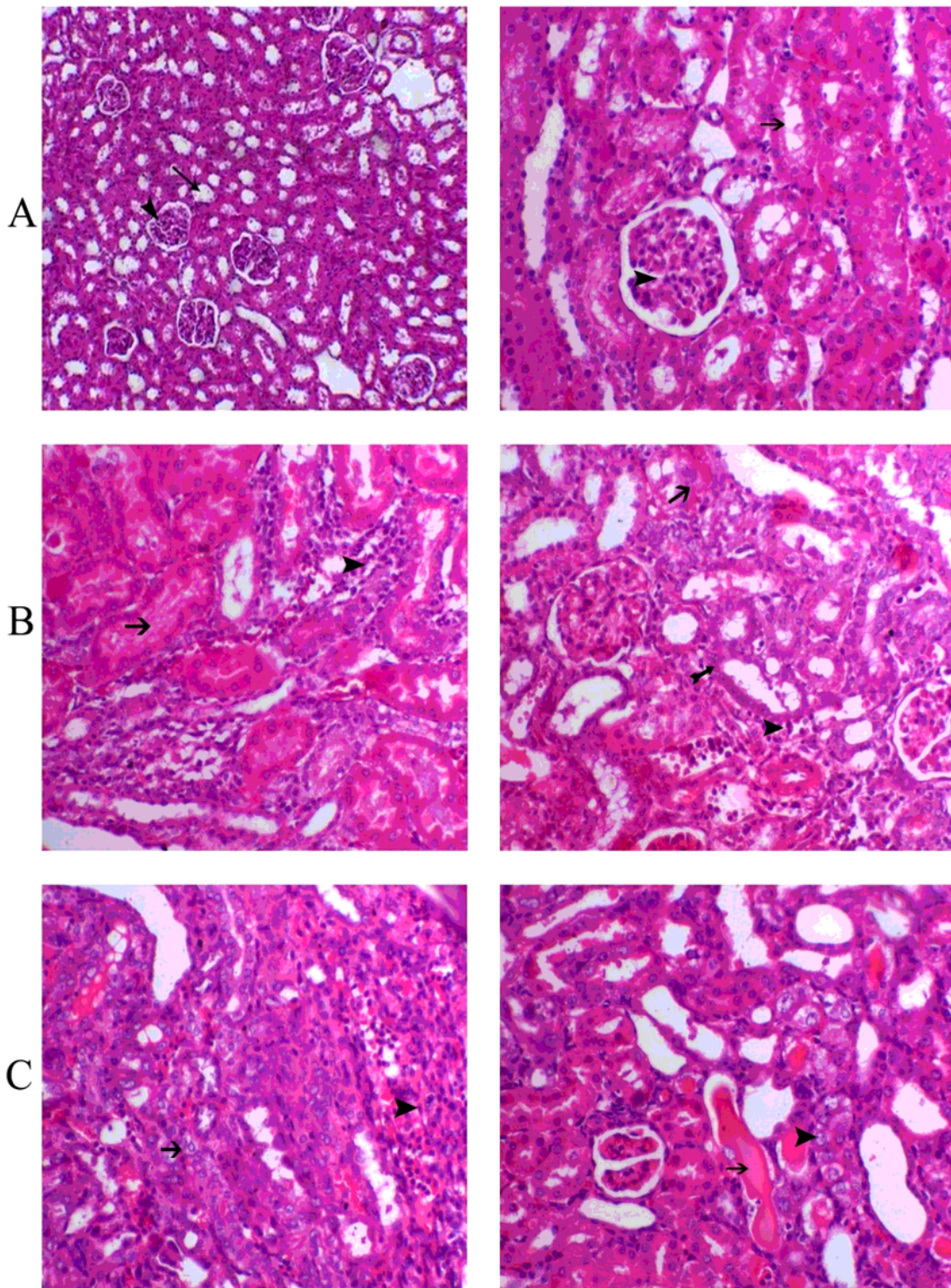


Figure 3

Figure 3

(A): Control (renal tubules are normal) (B): gentamycin group C) cisplatin group. Many cortical convoluted tubules were revisited by necrotic epithelial cells (horizontal solid arrows) or vacuolated swell cells (arrow heads), glomeruli exhibited swelling with reduction of bowman's capsular space. Shown are numerous inflammatory cells (small hollow vertical arrow) in the glomerular and tubular structures in the outer medulla.

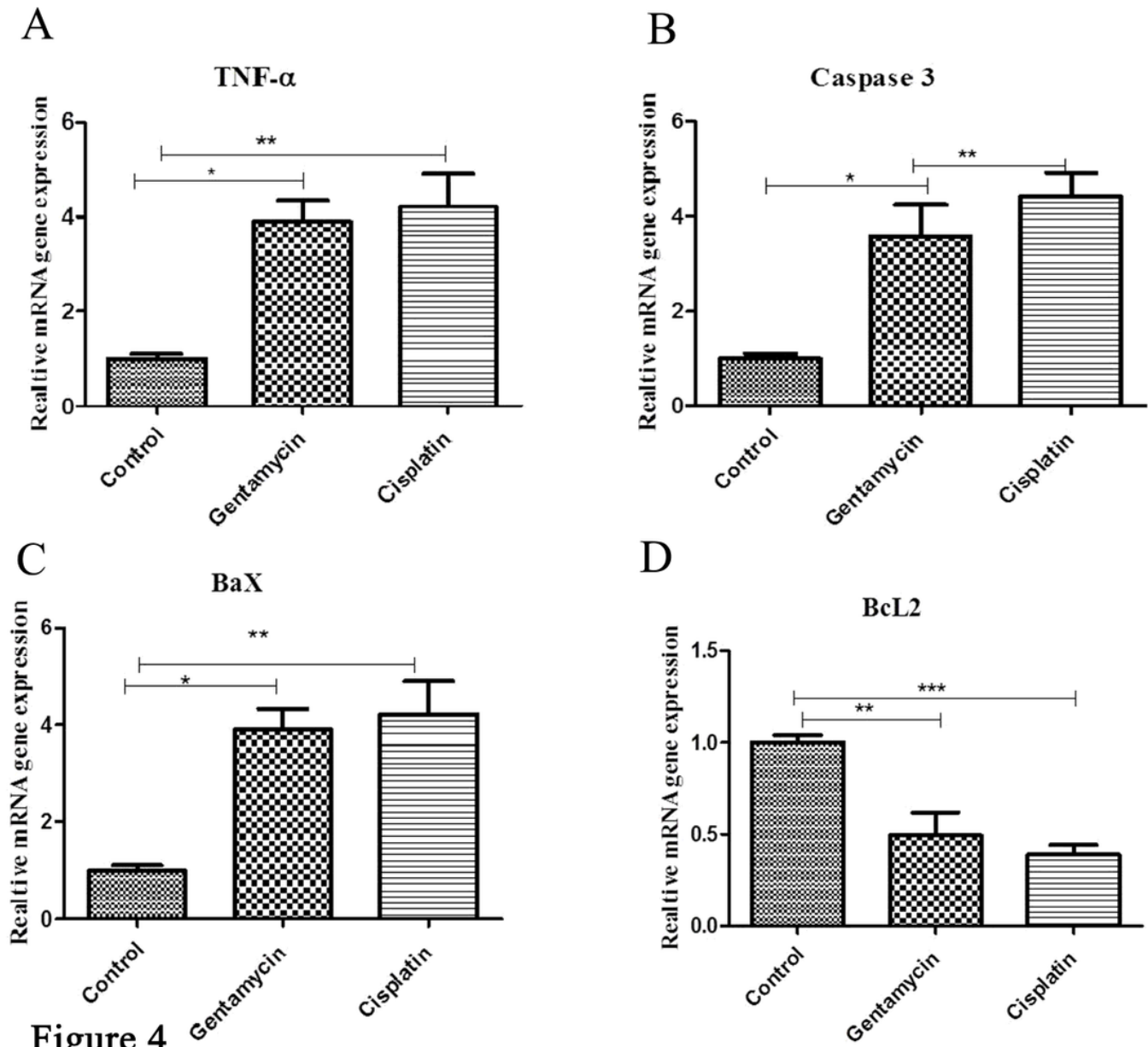


Figure 4

Figure 4

Effect of Gentamycin and cisplatin on mRNA expression (a) TNF- α (b) Caspase 3 , (c) Bax and (D) BCL2 the result represent the means \pm SEM * $P < 0.05$

Supplementary Files

This is a list of supplementary files associated with this preprint. Click to download.

- [AuthorChecklistFull.pdf](#)