Diagnosis of Coronavirus Disease 2019 (COVID-19): Neither Chest CT nor RT-PCR Fits All

Yue Teng
the First Affiliated Hospital of Soochow University https://orcid.org/0000-0002-8284-5044
Hui Dai
the First Affiliated Hospital of Soochow University
Yalei Shang
the First Affiliated Hospital of Soochow University
Jianguo Xia
Taizhou People's Hospital, Hospital Affiliated 5 to Nantong University
Yuehua Chen
the Third Hospital Affiliated of Nantong University
Weizhong Tian
Taizhou People's Hospital, Hospital Affiliated 5 to Nantong University
Tao Zhang
the Third Hospital Affiliated of Nantong University
Yonggang Li (liyonggang224@163.com)
the First Affiliated Hospital of Soochow University

Research Article

Keywords: coronavirus disease 2019, computed tomography, chest, reverse transcription-polymerase chain reaction

Posted Date: May 7th, 2020

DOI: https://doi.org/10.21203/rs.3.rs-27336/v1

Abstract

Background

Computed tomography (CT) and reverse-transcription polymerase chain reaction (RT-PCR) are the recommended tools for the diagnosis of coronavirus disease 2019 (COVID-19). The present study aimed to investigate the correlation between chest CT and RT-PCR while describing the atypical CT imaging features of COVID-19.

Methods

In this study, 418 patients in Jiangsu, China, clinically diagnosed with COVID-19 from January 10 to February 17, 2020, were included. Patients who fulfilled the following conditions were evaluated further: (1) Patients had positive RT-PCR and negative CT; (2) Patients had initial negative RT-PCR and positive CT, and follow-up PT-PCR tests were positive; (3) Patients had atypical CT findings.

Results

Of the 418 initial chest CT scans, 30 (7.2%) patients had normal CT presentation, and 6 (1.4%) patients had initial negative RT-PCR results and positive CT scans. Next, 10 (2.4%) cases of patients showed atypical CT findings, including 2 case of solid nodule, 4 cases of halo sign (solid nodule or mass surrounded by ground glass opacity), and 4 cases of predominant fibrous stripes.

Conclusions

False-negative results can be found on both chest CT and RT-PCR; hence, the diagnosis of COVID-19 should consider both CT and RT-PCR. CT manifestations, such as solitary nodule, halo sign, and pulmonary fibrous stripes, might indicate the possibility of COVID-19 to the radiologists.

Background

In December 2019, many “unknown viral pneumonia” cases were detected in Wuhan, China. A novel virus sample was obtained from throat swabs of affected patients and named severe acute respiratory syndrome coronavirus 2 (SARS-CoV–2) by World Health Organization (WHO). The disease caused by SARS-CoV–2 was termed as coronavirus disease 2019 (COVID–19) [1]. By April 4, 2020, there were 1040772 confirmed cases of COVID–19 from 205 countries and territories.

According to the diagnosis and treatment protocols from the National Health Commission of the People’s Republic of China, chest computed tomography (CT) and reverse-transcription polymerase chain reaction (RT-PCR) are the major tools for the diagnosis of COVID–19 [2]. However, RT-PCR test may be falsely negative due to the limitations of sample collection and transportation. Negative or atypical CT findings might make diagnosis difficult. In order to understand the diagnostic value of chest CT and RT-PCR, we evaluated 418 patients with suspected COVID–19.

Methods

Patients and clinical data

This multicenter study included 418 inpatients from 13 hospitals during 39 days (from January 10 to February 17, 2020) in Jiangsu, China (These cases were also reported in the manuscript “High-resolution Chest CT Features and Clinical Characteristics of Patients Infected with COVID–19 in Jiangsu, China”). All the cases were confirmed based on the criteria for COVID–19 established by National Health Commission of the People’s Republic of China. These were consistent with one of the following two conditions, according to the pathogenic evidence: 1) positive RT-PCR detection of novel coronavirus nucleic acid in specimens from respiratory tract or blood; 2) virus was highly homologous to the known novel coronavirus in genetic sequencing analyses in specimens from the respiratory tract or blood [2].

All cases underwent an additional microbiological evaluation for excluding other suspected respiratory infections. Those with a proven additional concurrent acute illness or other preexisting medical conditions were also excluded.

Clinical data with respect to age, gender, epidemic history, and initial symptoms were recorded. The confirmed patients were divided into mild, moderate, severe, and critical types according to the clinical manifestations [2].

This study was conducted in accordance with the amended Declaration of Helsinki. Independent ethics committees approved the protocol and written informed consent was obtained from all patients before the study.

CT scanning

Each subject underwent a chest CT examination within 24 h after the admission. Inspiratory phase chest CT examination was performed during a single-breath hold at full inspiration. The CT scanner models from the hospitals involved in this multicenter study were as follows: GE Bright Speed Elite 16, Neusoft 16, SOMATOM Emotion, SOMATOM definition AS, Philips MX–16, Philips 64-row spiral Ingenuity, and United Imaging Elite 16. The scanning parameters were as follows: tube voltage 120 kV, tube current 110 mA, pitch 1.0, rotation time ranging from 0.5–0.75 s, and slice thickness 5 mm with 1 mm or 1.5 mm section thickness for axial, coronal, and sagittal reconstructions.

Chest CT evaluation

This was a retrospective study of CT manifestations of 418 patients diagnosed with COVID–19 in Jiangsu province. The records of patients who fulfilled the following conditions were reviewed:

1. Patients had positive RT-PCR and negative CT scan.

2. Patients had initial negative RT-PCR results (throat swab) and positive CT scans, and follow-up PT-PCR tests (oral or anal swabs) were positive.
3. Patients had atypical CT findings. Typical CT findings were defined as: multiple ground glass opacity (GGO), crazy-paving pattern (GGO with superimposed inter- and intralobular septal thickening), and consolidation [3–5]. Also, images of patients with positive CT findings that do not correspond to typical signs were reviewed.

All CT images were reviewed separately by two attending radiologists who were blinded to the clinical data of the patients. The discrepancy in the opinion was adjudicated by an expert group, containing three senior radiologists with >10 years of experience.

Results

Clinical data

Of the 418 patients with COVID–19, 46 met the criteria described above. The cohort consisted of 17 (37%) men and 29 (63%) women, with an average age of 34±18 (range: 6–82-years-old). Clinical information, including epidemic history and initial symptoms, as well as age and gender of the patients, were recorded (Table 1). The most frequent initial symptoms were fever (39%) and cough (41%).

Chest CT evaluation

30/418 (7.2%) patients had positive RT-PCR and a negative CT scan. 12/30 patients underwent follow-up chest CT scan, and 4/12 underwent two follow-up scans. The mean time between the initial chest CT and the follow-up scan was 4 (range, 2–6) days. All examinations displayed negative CT findings.

6/418 (1.4%) patients had an initial negative RT-PCR result (throat swab) and positive CT scans. 3/6 patients showed positive results in the follow-up RT-PCR test (throat swab), and the remaining 3 presented negative throat swab and positive anal swab tests. All 6 patients showed multiple, patchy, or sub-segmental GGO with varying degrees of consolidation (Fig. 1). 4/6 patients underwent follow-up chest CT during the study date range. The mean time between the onset of symptoms and the initial CT scan was 3 (range, 2–5) days. 1/4 patient underwent three follow-up CT scans, after demonstrating multiple patchy GGO and consolidation in the initial examination. The follow-up CT scans revealed progressed GGO and consolidation, crazy-paving pattern, and fibrosis, respectively (scan interval: 2, 6, and 10 days after initial CT scan).

10/418 (2.4%) patients had atypical CT findings, including 2 case of solid nodule (Fig. 2), 4 cases of solid nodule or mass surrounded by GGO (halo sign) (Fig. 3), and 4 cases of predominant fibrous stripes (Fig. 4). Seven patients underwent follow-up chest CT scan, 1/7 underwent two follow-up scans. 4/7 patients demonstrated mild progression, and the remaining 3 patients showed mild improvement in the disease condition. The mean time between the onset of symptoms and initial CT scan was 7.1 (range, 5–9) days.

Discussion

COVID–19 is a new disease outbreak with potentially far-reaching public health ramifications. The early diagnosis of COVID–19 is crucial for the treatment and control of the disease. Chest CT imaging is a rapid method to diagnose and assess COVID–19 with high sensitivity and low specificity [6], while RT-PCR lacks sensitivity, has insufficient stability, and prolonged processing time, which are detrimental to the control of the disease epidemic [7]. Thus, the results of chest CT and RT-PCR tests must be interpreted cautiously.

Among the 418 patients, 30/418 (7.2%) showed positive RT-PCR and negative CT. These findings were also reported by Kanne et al. [8] and Chung et al. [9]. In the current study, the ratio (7.2%) of negative CT scan was higher as compared to the report by Ai et al. (3%) [6]. This phenomenon could be attributed to the factor that patients in their study were from a top-level hospital in the central area of COVID–19 outbreak in Wuhan, China, while our patient was of moderate type. Xie et al. [10] mentioned that 1 patient who was subjected to CT scan later became positive for pneumonia. However, in the current study, 12 patients who underwent follow-up CT scans presented unaltered negative results. Consequently, negative CT findings could not exclude COVID–19, and a follow-up CT scan in the subsequent 3–5 days is recommended [3].

6/418 (1.4%) patients had initial negative RT-PCR results (throat swab) and positive CT scans. Moreover, the significant CT findings constituted multiple, patchy, and sub-segmental GGO with varying degrees of consolidation. The review of these six cases suggested that typical CT findings aid in the early screening of suspected cases and might predict severe complications, such as acute respiratory diseases. Xie et al. found that of 167 patients evaluated, 5 (3%) presented initially negative RT-PCR and positive chest CT [10]. The RT-PCR test for COVID–19 may be falsely negative due to laboratory error or insufficient viral material in the specimen. Thus, it should be noted that three patients were sampled from both oral and anal swab, and only samples from anal swab presented positive results. Chinese Novel Coronavirus Pneumonia Emergency Response Epidemiology Team reported more anal swab positives than throat swab positives in a later stage of infection, indicating a possible transmittance through oral-fecal route for SARS-CoV–2 [11]. The CT features of viral pneumonia might suspect COVID–19 despite negative RT-PCR results. In such cases, repeat anal and throat swab analysis should be considered.

10/418 (2.4%) patients had atypical CT findings. Two patient had solitary nodules in the lower lobe. This manifestation had not been described previously. The throat swab was sampled on the same day as the positive result of the initial CT scan, indicating SARS-CoV–2 infection. One patient underwent follow-up scan after 5 days revealed crazy-paving pattern. The solitary nodule was a common lesion in the chest CT, but with definite epidemic history, and hence, COVID–19 should not be excluded.

Four patients had a halo sign in the initial CT scan. Li et al. also reported the same in COVID–19 patient [12]. Halo sign was defined as GGO surrounding a pulmonary nodule or mass [13]. The CT halo sign has been classically described in hemorrhagic nodules, typically seen in angioinvasive aspergillosis. However, viral infections and organizing pneumonia are known differential causes for the halo sign [14]. The CT

halo sign can be nonspecific for an infection, but in the context of travel history or exposure, the presence of the halo sign should alert the radiologists about the possibility of COVID–19.

Four patients exhibited predominant fibrous stripes in the CT. The pulmonary fibrous stripes are considered as a sign of recovery. The disease was improved in the follow-up CT in all 4 patients, which appeared as decreased extent and consolidation as compared to the baseline chest CT. It's worth noting that although the presence of pulmonary fibrous stripes is a sign of recovery, the four patients in our study still had positive RT-PCR results which suggest that the patients were still contagious. At the same time many other lung diseases have the presentation of pulmonary fibrous stripes in the recovery stages. Therefore, if pulmonary fibrous stripes are present in a suspect case, PT-PCR testing and quarantine of the patient are necessary in order to contain the spread of disease. Pan et al. found that fibrous stripes normally appeared in the peak stage (9–13 days after the onset of the initial symptom) and absorption stage (≥14 days after the onset of the initial symptom) [15]. The mean time between the onset of symptoms and the initial CT scan of our patients was 5–7 days. The fibrous stripes appeared within 7 days possibly due to mild disease and lack of symptoms in the early stage.

Nevertheless, the present study has several limitations. First, 90% of our patients had a moderate type of COVID–19 infection, and severe and critical patients were lacking. Second, heterogeneity in the CT data was observed due to different CT models. Finally, further longitudinal research was needed to focus on the dynamic correlation between chest CT and RT-PCR tests.

Conclusions

In the current study, we found that neither chest CT or RT-PCR was sufficient for an accurate diagnosis. Infected patients with negative imaging showed that chest CT lacks complete sensitivity to exclude COVID–19 alone. Also, the latest reference standard (RT-PCR) has a limitation of a high false-negative rate. The anal swab should be considered as a complementary method to throat swab. Atypical CT manifestation such as solitary nodule, halo sign, and pulmonary fibrous stripes might indicate the possibility of COVID–19 to the radiologist. In summary, the diagnosis of COVID–19 should be based on the combination of CT findings and RT-PCR test.

Declarations

Ethics approval and consent to participate

This study was conducted in accordance with the amended Declaration of Helsinki. Independent Ethics Committee (IEC) for Clinical Research of the First Affiliated Hospital of Soochow University approved the protocol (reference number: 2020-030), and written informed consent was obtained from all patients before the study.

Consent for publication

Not applicable.

Availability of data and materials

The data supporting the conclusions of this article are available upon request. Please contact Dr. Yue Teng (email: tengyue@suda.edu.cn).

Competing interests

The authors declare that they have no competing interests.

Funding

This work was mainly supported by the National Natural Science Foundation of China (grant numbers: 81971573 and 81671743), the Clinical Key Diseases Diagnosis and Therapy Special Project of Health and Family Planning Commission of Suzhou (LCZX201801), the Project of Invigorating Health Care through Science, Technology and Education, Jiangsu Provincial Medical Youth Talent (QNRC2016709), the High-level Health Personnel “Six-one” Project of Jiangsu Province (LGY2016035) and Program for Advanced Talents within Six Industries of Jiangsu Province (WSW-057). The funders had no role in the study design, data collection and analysis, the decision to publish, or preparation of the manuscript.

Authors’ Contributions

Conceived and designed the study: HD, YL, WT, and TZ. Analyzed the data: YS and JX. Wrote the manuscript: YT. All authors have read and approved the manuscript.

Acknowledgments

Not applicable.

Author Information

Affiliations

Department of Radiology, The First Affiliated Hospital of Soochow University, Suzhou city, Jiangsu province, China.

Yue Teng, Hui Dai, Yalei Shang, Yonggang Li

Institute of Medical Imaging, Soochow University, Suzhou city, Jiangsu province, China.

Hui Dai, Yonggang Li

Department of Radiology, The People's Hospital of Taizhou, Taizhou city, Jiangsu province, China.

Jianguo Xia, Weizhong Tian

Department of Radiology, NanTong No3 Hospital, Nantong City, Jiangsu province, China.

Yuehua Chen, Tao Zhang

Corresponding Author

Correspondence to Yonggang Li.

Abbreviations

COVID-19: Coronavirus Disease 2019

GGO: Ground Glass Opacity

SARS-Cov-2: Severe Acute Respiratory Syndrome Coronavirus 2

RT-PCR: Reverse-Transcription Polymerase Chain Reaction

WHO: World Health Organization

References

1. Zhu N, Zhang D, Wang W, Li X, Yang B, Song J, et al. A Novel Coronavirus from Patients with Pneumonia in China, 2019. N Engl J Med. 2020;382:727–33.
2. General Office of National Health Committee. Office of state administration of traditional Chinese medicine. Notice on the issuance of a programme for the diagnosis and treatment of novel coronavirus (2019-nCoV) infected pneumonia (trial fifth edition) (2020-02-26) [EB/OL]. http://bgs.satcm.gov.cn/zhengcewenjian/2020-02-06/12847.html. Accessed 28 Feb 2020.
3. Chinese Society of Radiology. Chinese Society of Radiology. Radiological diagnosis of new coronavirus infected pneumonitis: Expert recommendation from the Chinese Society of Radiology (First edition). Chin J Radiol. 2020;54:E001–E001.
4. Zu ZY, Jiang MD, Xu PP, Chen W, Ni QQ, Lu GM, et al. Coronavirus Disease 2019 (COVID-19): A Perspective from China. Radiology. 2020;200490.
5. Koo HJ, Lim S, Choe J, Choi S-H, Sung H, Do K-H. Radiographic and CT Features of Viral Pneumonia. RadioGraphics. 2018;38:719–39.
6. Ai T, Yang Z, Hou H, Zhan C, Chen C, Lv W, et al. Correlation of Chest CT and RT-PCR Testing in Coronavirus Disease 2019 (COVID-19) in China: A Report of 1014 Cases. Radiology. 2020;200642.
7. Yang Y, Yang M, Shen C, Wang F, Yuan J, Li J, et al. Evaluating the accuracy of different respiratory specimens in the laboratory diagnosis and monitoring the viral shedding of 2019-nCoV infections. medRxiv. 2020.02.11.20021493.
8. Kanne JP. Chest CT Findings in 2019 Novel Coronavirus (2019-nCoV) Infections from Wuhan, China: Key Points for the Radiologist. Radiology. 2020;200241.

9. Chung M, Bernheim A, Mei X, Zhang N, Huang M, Zeng X, et al. CT Imaging Features of 2019 Novel Coronavirus (2019-nCoV). Radiology. 2020;200230.
10. Xie X, Zhong Z, Zhao W, Zheng C, Wang F, Liu J. Chest CT for Typical 2019-nCoV Pneumonia: Relationship to Negative RT-PCR Testing. Radiology. 2020;200343.
11. Novel Coronavirus Pneumonia Emergency Response Epidemiology Team. [The epidemiological characteristics of an outbreak of 2019 novel coronavirus diseases (COVID-19) in China]. Zhonghua Liu Xing Bing Xue Za Zhi Zhonghua Liuxingbingxue Zazhi. 2020;41:145–51.
12. Li X, Zeng X, Liu B, Yu Y. COVID-19 Infection Presenting with CT Halo Sign. Radiol Cardiothorac Imaging. 2020;2:e200026.
13. Pinto PS. The CT Halo Sign. Radiology. 2004;230:109–10.
14. Franquet T. Imaging of Pulmonary Viral Pneumonia. Radiology. 2011;260:18–39.
15. Pan F, Ye T, Sun P, Gui S, Liang B, Li L, et al. Time Course of Lung Changes On Chest CT During Recovery From 2019 Novel Coronavirus (COVID-19) Pneumonia. Radiology. 2020;200370.

Table

Table 1 Summary of Patient Characteristics (n = 46)

Parameter	Value
Gender	
Men	17 (37%)
Women	29 (63%)
Age (y)	
Mean	34
Standard deviation	18
Range	6-82
Exposure history	
Recent travel to Wuhan	21 (46%)
Exposure to infected patient	14 (30%)
Unknown exposure	11 (24%)
Symptoms	
Fever	18 (39%)
Fatigue	2 (4%)
Headache	2 (4%)
Cough	19 (41%)
Muscle soreness	1 (2%)
Nausea	0 (0%)
Nasal discharge	3 (7%)
No obvious symptoms	10 (22%)
Note: data are numbers of patients, with percentages in parentheses.	

Figures

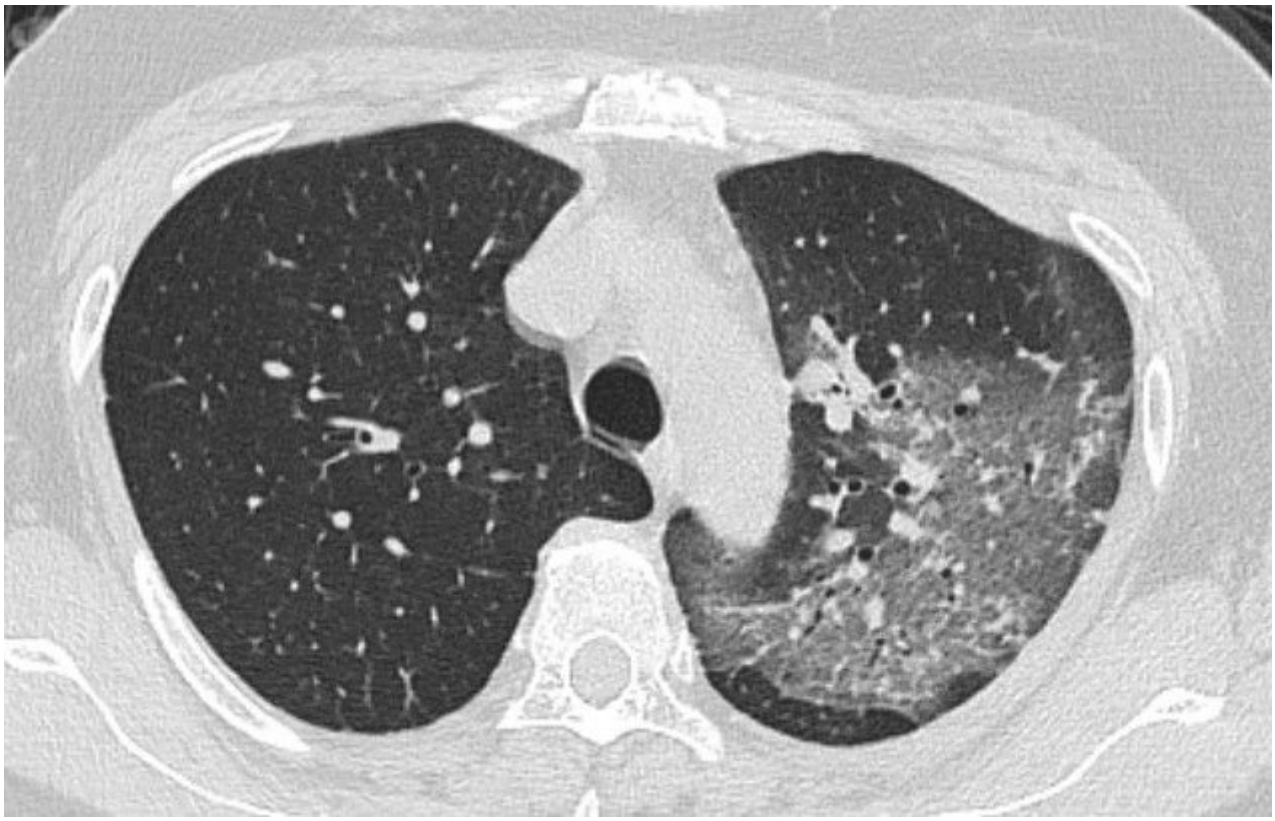

Figure 1

Image of a middle-aged female with history of recent travel to Wuhan presented with fever and headache. The initial RT-PCR test was negative. Axial unenhanced HRCT image shows typical GGO in left upper lobe. Follow-up RT-PCR test after 5 days had a positive result.

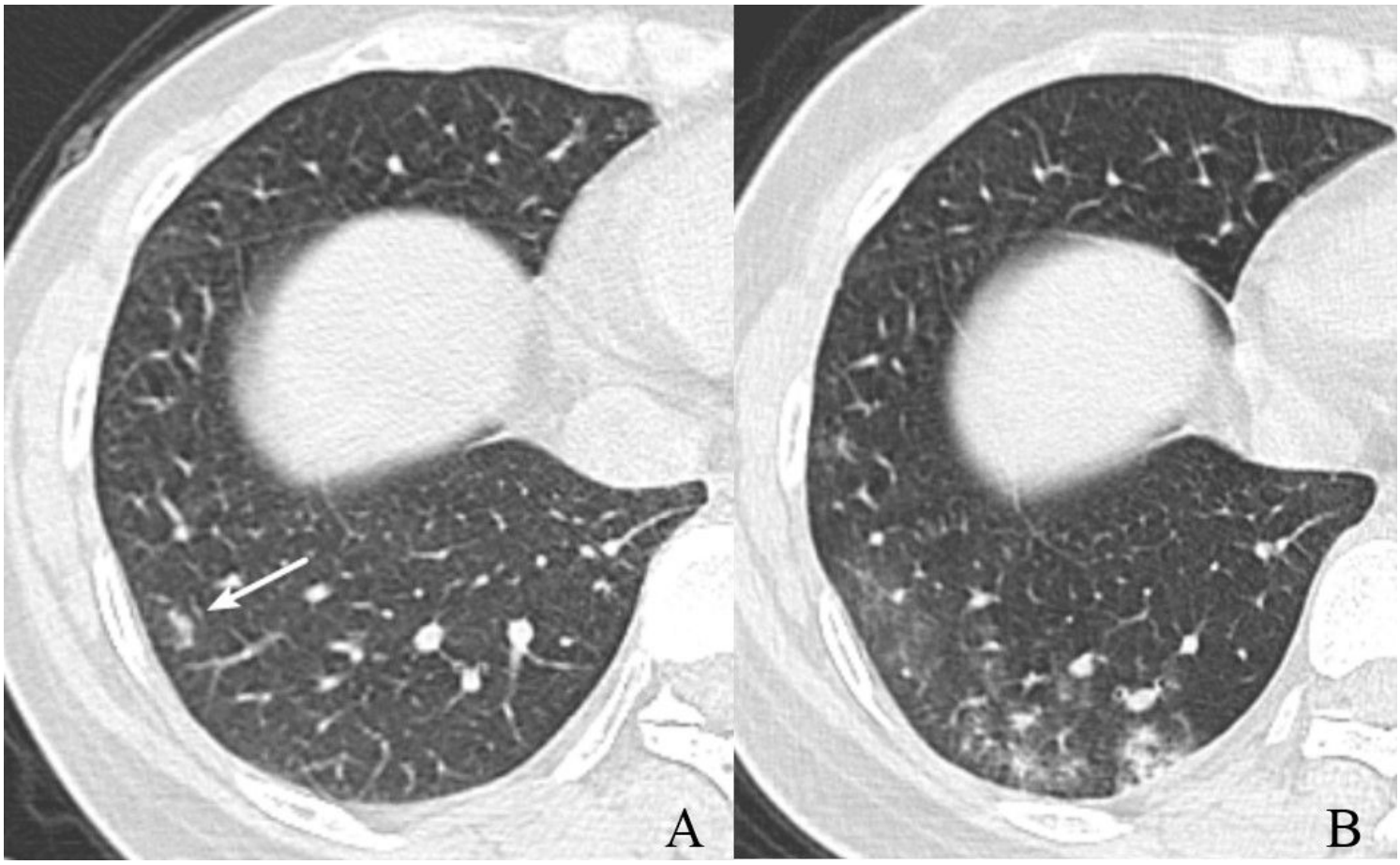

Figure 2

Image of a middle-aged female who had close contact with COVID-19 patient presented with fever and cough. A. The initial chest CT shows solitary nodule in right lower lobe (arrow). B. Follow-up chest CT after 5 days revealed crazy-paving pattern.

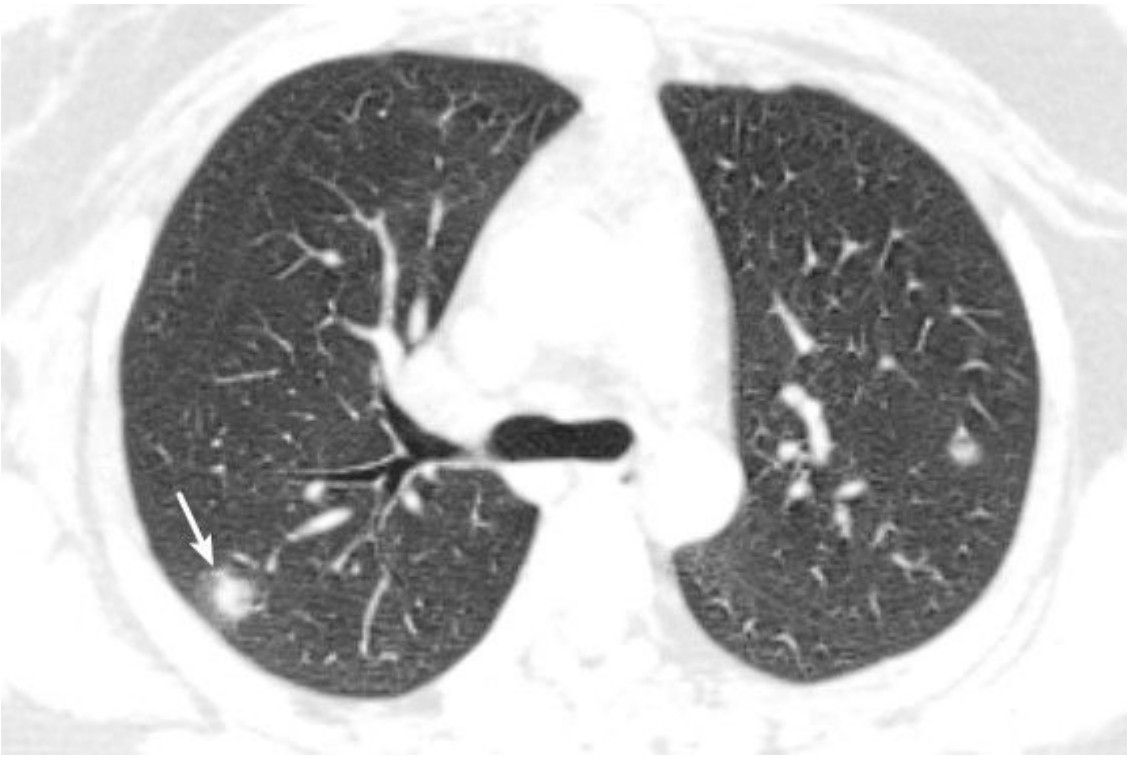

Figure 3

Image of a young female who had close contact with COVID-19 patient presenting fever and cough. Axial unenhanced HRCT image shows halo sign in right upper lobe (arrow).

Figure 4

Image of a middle-aged male who had close contact with COVID-19 patient presented with fever and cough. Axial unenhanced CT image shows fibrous stripes in the left lower lobe (arrow).