# A New Treatment-Oriented Classification and Treatment Algorithm for Comminuted Mandibular Fractures

**Xiaofeng Xu**
Shanghai Ninth People's Hospital
**Fangxing Zhu**
Shanghai Ninth People's Hospital
**Fawen Wang**
Shanghai Ninth People's Hospital
**Qian Liao**
Shanghai Ninth People's Hospital
**Wenbin Zhang**
Shanghai Ninth People's Hospital
**Bing Xu**
Shanghai Ninth People's Hospital
**Jun Shi** ( 563109046@qq.com )
Shanghai Ninth People's Hospital

---

**Research Article**

**Keywords:** Mandible fracture, Comminuted fracture management, Titanium mesh, Open reduction and internal fixation, Staged operations

**Posted Date:** March 10th, 2021

**DOI:** https://doi.org/10.21203/rs.3.rs-275587/v1



---

# Abstract

This study aimed at proposing a new treatment-oriented classification and treatment algorithm of comminuted mandibular fractures which has a guidance effect on choosing management methods. Patients with comminuted mandibular fractures were retrospectively reviewed in the study and all the patients were classified as follows: Type I: mandibular morphology is sound without bone defect and treated conservatively with intermaxillary fixation (IMF); Type II: mandibular morphology is damaged while the degree of comminution is low and treated by open reduction internal fixation (ORIF) with miniplates; Type III: mandibular morphology is also damaged, but with a higher comminution degree and mass of comminuted. The occlusal relationship can be effectively regained by IMF and was done in the primary debridement. 7-10 days after that, ORIF with titanium meshes was performed in the staged operation; Type IV: comparing to the type III fracture, the occlusal relationship is unable to be regained only by IMF and reconstruction plates were used in ORIF; Type V: the occlusal relationship and mandibular morphology are both damaged with segmental bone defect and mandibular continuity losing and bone flap transplantation was performed for reconstruction; 75 patients were included in the study. Type II fractures are the most common type, followed by type III fractures. 44 of the patients were treated according to the classification and algorithm, and 2 patients of type I and IV manifested infection, 1 patient of type III showed malocclusion in the group of patients who were managed according to our treatment algorithm. Of those who were not in the treatment algorithm, 2 patients of type II and 2 of type III manifested infection, 2 patients of type 3 manifested bone un-union, 2 patients of type II and IV displayed malocclusion and 1 patient of type IV showed mandibular asymmetry. The results of this study suggest the treatment-oriented classification and algorithm for comminuted mandibular fractures has a certain guiding effect on the choice of treatment methods and is able to decrease the complication rate.


# Introduction

Mandibular fractures are common among the maxillofacial trauma[1]. Of these mandibular fractures, comminuted mandibular fractures account for approximately 5%-7%[2], and are defined as the presence of multiple fracture lines resulting in many small pieces of bone within the same area of mandible (2 separated bone pieces at least)[3].

The treatment of comminuted mandibular fractures is quite a challenge for most surgeons, because many serious postoperative complications may occur, such as infection, malocclusion, facial deformity, bone un-union and even bone defect. All these complications can severely affect the appearances and functions of the patients[2, 4–6].

The recommendation of Association for the Study of Internal Fixation (AO/ASIF) for comminuted mandibular fractures is rigid fixation with large mandibular reconstruction plates. It is considered that using IMF or miniplates fixation indiscriminately does not produce stable osteosynthesis and therefore it is incorrect and the main factor of postoperative complications in comminuted mandibular fractures [2]. Nevertheless, it is complicated in clinical practice and this method may not cover the managements of all

kinds of comminuted mandibular fractures. We reviewed copious literatures and unfortunately, there was no classification that can give a practical guidance to the specific management choice.

In this study, we summarized a series of treatment algorithm and proposed a new classification of comminuted mandibular fractures based on three-dimension computed tomography (3DCT) scans and clinical features according to our clinical experiences in the past 10 years.

## Results

# Etiology

A total of 75 patients (54 males and 21 females) ranged from 8 to 58 years averaged 30.40 years were included in the study. The follow-up periods ranged from 6 months to 4 years, averaged 10.56 months. The causes of the fractures were high fall injury in 27(36%), traffic accidents in 19(25.33%), blunt injury in 17(22.67%), trip in 9(12.16%), gunshot wounds in 2(2.67%), and explosion in 1 patient (1.33%).

# Classification

According to the 3DCT scans, type II fractures are the most common ones (40.00%, [n = 30]), followed by type III fractures (28.00%, [n = 21]) and type I fractures (17.33%, [n = 13]), while the two rarest fracture types are type IV fractures (10.67%, [n = 8]) and type V fractures (4.00%, [n = 3]).

# Managements and complications

At least one year of follow-up visits were required for all patients. 44 of the patients were treated according to the classification and algorithm, and 2 patients of type I and IV manifested infection, 1 patient of type III showed malocclusion in the group of patients who were managed according to our treatment algorithm. Of those who were not in the treatment algorithm, 2 patients of type II and 2 of type III manifested infection, 2 patients of type 3 manifested bone un-union, 2 patients of type II and IV displayed malocclusion and 1 patient of type IV showed mandibular asymmetry (Table 1).

## Discussion

Comminuted mandibular fractures can be successfully treated by a number of methods, including IMF, external fixation with Kirschner pin, and ORIF with small plates or reconstruction plates[6, 8, 9]. ORIF with load-bearing reconstruction plates is advocated by an increasing number of scholars [10, 11] and has been regarded as the first place internationally for the treatment of comminuted mandibular fractures.

However, in clinical practice, the imageologies of comminuted mandibular fractures are widely divergent from each other and the applicable treatment methods are also different. Especially for comminuted mandibular fractures with high comminution degrees, reconstruction plates are difficult to handle and shape, which usually leads to secondary facial deformity and it is also hard to retain small fracture segments[11]. Thus, an appropriate classification with treatment algorithm is necessary.

There are plenty of factors which would exert an influence on the management choices of comminuted mandibular fractures. Our treatment-oriented classification is based on the following factors, namely, whether a stable occlusal relationship could be regained, the morphology of the mandible after trauma, the degree of comminution and whether or not a segmental mandibular bone defect occurred (Fig. 1).

Facing comminuted mandibular fractures treatment, the top priority task is judging whether a segmental mandibular bone defect has occurred. If it has, then a bone transplantation should be performed. This type of patients is the most severe type of all comminuted fractures of the mandible. It is mostly caused by severe injuries such as explosions and gunshots. The treatment is also the most complicated. (type V)

When no segmental bone defect is found, mandibular morphology is the key factor that determines the management method. An intact or slightly damaged mandibular shape may only require conservative treatment like observation or IMF since the continuity of mandible is not damaged. In other words, the displacement extent of the comminuted bone segments directly determines whether an open surgery is necessary or not and in most cases of the patients with intact mandibular morphology, their occlusal relationships are also intact or can be restored through IMF. (type I)

In cases of damaged mandibular morphologies without segmental bone defects, comminution degree may pose a significant effect on determining the treatment methods. Damaged mandibular morphology is an indication for open surgery as it can only be restored by open surgeries and the specific surgery approaches depend on the degree of comminution. In the patients with a low or minimum degree of comminution, the bone segments are big enough to maintain blood supply well. Thus, it is almost the same as the management method of mandibular multiple fracture that is fixed with miniplates. The postoperative infection is often related to the inappropriate soft tissue management which would lead to blood supply damage during surgery. (type II)

However, when it comes to fractures with high comminution degree, it is the occlusal relationship that plays an important role in the choice of management methods. If a stable occlusal relationship could be obtained based on the relatively intact dentition, then IMF in the primary debridement should be performed. When intraoral soft tissue wounds heal, the second stage ORIF with titanium meshes can be performed[7]. For titanium mesh is easier to adapt and bent to the desired shape than reconstruction plates, thus it is suitable for mandibular reconstruction and in particular for the treatment of complex mandibular fractures, which can achieve better stabilization of these fractures than miniplates do. Complications such as infection and bone un-union can largely be avoided and bone tissues can be reserved[12]. (type III)

In terms of those severely comminuted mandibular fractures with seriously impaired dentition in which a stable occlusal relationship cannot be pieced, it is better to follow the principle of AO/ASIF. A load-bearing fixation appliance, the reconstruction plate, should be used to totally bear the functional bite force and to avoid relative motion and functional load[2]. (type IV)

It is worth noting that this classification mainly considers restoring the patient's morphology and function with the least potential trauma while minimizing the occurrence of complications. When difficult-definition fractures or misjudgment occurred, other treatment methods should be applied without hesitation. For example, if it is judged as a type III fracture before surgery and a stable occlusal relationship cannot be obtained during surgery, then the titanium mesh should be immediately abandoned and replaced with traditional reconstruction plates. If always stereotyping to the classification, both function or morphology will not be guaranteed, which will affect the surgical effect.

In conclusion, we believe that the traditional management using reconstruction plates cannot cover all kinds of comminuted mandibular fractures. In this study, a new treatment-oriented classification and algorithm for comminuted mandibular fractures were created, which has a certain guiding effect on the choice of treatment methods and is able to decrease complication rate, but further clinical research is needed.

## Methods

# Patients

All patients diagnosed as comminuted mandibular fractures presenting to our department, between January 2011 and January 2020, were involved in this retrospective study. Those who had been treated in other hospitals should be excluded. A 3DCT scan (CT, slice thickness, 1.25mm, GE Healthcare, Buckinghamshire, England) was required for all patients. An informed consent was obtained from all participants or, if participants were under 18, from the parents and/or legal guardians and consent to publish was obtained from all the patients or, if patients were under 18, from the parents and/or legal guardians for publishing the images and radiological documents. This retrospective study was conducted at department of oral and cranio-maxillofacial surgery in Shanghai ninth people's hospital and approved by Shanghai Ninth People's Hospital constitutional ethics committee. All the surgical methods carried out in the study were in accordance with relevant guidelines and regulations in oral and maxillofacial surgery.

# Classification

In literature review up to February 2020, there was no classification for comminuted mandibular fractures which had a guidance effect on the management. According to our long-term clinical observation, all the patients were classified based on these factors: whether a stable occlusal relationship could be regained, the morphology of the mandible after trauma, the degree of comminution and whether or not segmental mandibular bone defect occurred. Five types of comminuted mandibular fractures were summarized according to the severity of injury. (Fig. 1).

Type I: mandibular morphology is sound without any obvious mandibular continuity destruction or bone defect (Fig. 2A);

Type II: mandibular morphology is damaged, but the degree of comminution is low. The mandible is mainly broken into several large fracture pieces but the mandibular continuity is intact without obvious bone defect (Fig. 2B);

Type III: mandibular morphology is also damaged, but compared with type II, it has a higher comminution degree and mass of comminuted(even invascularized)small bone pieces, but the mandibular continuity is intact without obvious bone defect. The dentitions are relatively intact and the occlusal relationship can be effectively regained by IMF (Fig. 2C);

Type IV: comparing to the type III fracture, the occlusal relationship in this kind of fracture is unable to be regained only by IMF (Fig. 2D);

Type V: the occlusal relationship and mandibular morphology are both damaged with segmental bone defect and mandibular continuity losing (Fig. 2E).

# Management

Most patients with type I fractures can be managed conservatively: for patients with a sound and stable occlusal relationship, no treatment is required; for patients with malocclusion, IMF with Winter's arch and elastic traction for 2–3 weeks is performed since the extent of displacement is not serious enough.

For patients with type II, type III and type IV fractures, open reduction and internal fixation (ORIF) is necessary.

For type II fracture, we use an intraoral vestibular incision (sometimes combined with extraoral incision) and fix fracture segments with miniplates (Fig. 3A, Fig. 3B).

For type III fracture, The ORIF surgical procedure for comminuted mandibular fractures was performed 7 to 10 days after primary debridement [7]. In primary debridement we stop bleeding, close the wound in the oral cavity, clean the area around the fracture regions, and restore and maintain occlusal relationship by IMF. If a combined maxillary or condylar fracture is presented, we also perform ORIF for the maxillary fracture and condylar fracture if it is necessary during the primary operation to obtain a favorable occlusal relationship (Fig. 4A, Fig. 4B). 7–10 days later, the occlusal relationship is restored and all intraoral wounds healed. We reopen the extraoral wound and reduce the bone segments according to the occlusal relationship and fix the fracture segments with shaped 0.6 mm titanium mesh (Stryker, Kalamazoo, MI, USA). For some patients, the larger mandibular segments are fixed with miniplates. The wound is sutured and antibiotics are required for three days after surgery. All patients get their IMF removed 7–10 days after the surgeries (Fig. 4C, Fig. 4D).

For patients with type IV fracture, we suggest using an extraoral incision approach and fixing with large mandibular reconstruction plates (Fig. 5A, Fig. 5B).

For patients with type V fracture, bone transplantation is a good choice to reconstruct the mandible. The donor sites include fibula and iliac, etc.

## Abbreviations

AO/ASIF: Association for the Study of Internal Fixation;

IMF: intermaxillary fixation;

3DCT: three-dimension computed tomography;

ORIF: open reduction and internal fixation.

## Declarations

# Acknowledgement

We are extremely grateful to all of our study participants for allowing their (anonymized) data to be published. This work was supported by Ninth People's Hospital affiliated to Shanghai Jiao Tong University, School of Medicine "Multi-Disciplinary Team" Clinical Research Project (201701013).

# Author contributions

XFX, FXZ and FWW wrote the article. FWW and QL collected the data. WBZ, BX and JS performed the surgeries, conceived and designed the experiments.

# Competing interests

The authors declare no competing interests

## References

1. Haihua, Z., Kun, L., Rongtao, Y., Rongtao, Y., Zhi, L. & Zubing, L. Mechanics in the Production of Mandibular Fractures: A Clinical, Retrospective Case-Control Study. *Plos One*. **11(2),** e0149553; 10.1371/journal.pone.0149553. eCollection (2016).
2. Alpert, B., Tiwana, P.S., Kushner, G.M. Management of Comminuted Fractures of the Mandible. *Oral Maxillofac. Surg. Clin. North Am*. **21(2),** 185-192, v (2009).
3. Finn, R.A. Treatment of comminuted mandible fractures by closed reduction. *J. Oral Maxillofac. Surg*. **54(3),** 320-327 (1996).
4. Iizuka, T., Lindqvist, C., Hallikainen, D. & Paukku, P. Infection after rigid internal fixation of mandibular fractures: A clinical and radiologic study. *J. Oral Maxillofac. Surg*. **49(6),** 585-593 (1991).
5. Kuriakose, M.A., Fardy, M., Sirikumara, M., Patton, D.W. & Sugar, A.W. A comparative review of 266 mandibular fractures with internal fixation using rigid (AO/ASIF) plates or mini-plates. *Br. J. Oral*

*Maxillofac. Surg*. **34(4),** 315-321 (1996).

6. Ellis E, Muniz O & Anand K. Treatment considerations for comminuted mandibular fractures. *J. Oral Maxillofac. Surg*. **61(8),** 861-870 (2003).
7. Dai J, Shen G, Yuan H, Zhang W, Shen S & Shi J. Titanium Mesh Shaping and Fixation for the Treatment of Comminuted Mandibular Fractures. *J. Oral Maxillofac. Surg*. **74(2),** 337.e1-337.e11 (2016).
8. Abreu, M. E. *et al*. Treatment of comminuted mandibular fractures: a critical review. *Med. Oral Patol. Oral Cir. Bucal*. **14(5),** E247-251 (2009).
9. Smith, B. R., Teenier, T. J. Treatment of comminuted mandibular fractures by open reduction and rigid internal fixation. *J. Oral Maxillofac. Surg*. **54(3)**, 328-331 (1996).
10. Zhi, L., Zubing, L. Clinical characteristics and treatment of multiple site comminuted mandible fractures. *J. Craniomaxillofac. Surg*. **39(4),** 296-9 (2011).
11. Scolozzi, P., Richter, M. Treatment of severe mandibular fractures using AO reconstruction plates. *J. Oral Maxillofac. Surg*. **61(4),** 458-61 (2003).
12. Schug, T., Rodemer, H., Neupert, W., Dumbach, J. Treatment of complex mandibular fractures using titanium mesh. *J. Craniomaxillofac. Surg*. **28(4),** 235-7 (2000).

# Table

**Tab. 1:** Treatment tactics and complication manifested.

| Number / Treatment tactics / Fx classification | Follow algorithm | | Unfollow algorithm | |
|---|---|---|---|---|
| | With complications | No Complication | With complications | No Complication |
| I | 1 | 7 | 0 | 13 |
| II | 0 | 19 | 3 | 30 |
| III | 0 | 10 | 4 | 21 |
| IV | 1 | 3 | 2 | 8 |
| V | 1 | 2 | 0 | 3 |
| Total | 3 | 41 | 9 | 22 |

# Figures

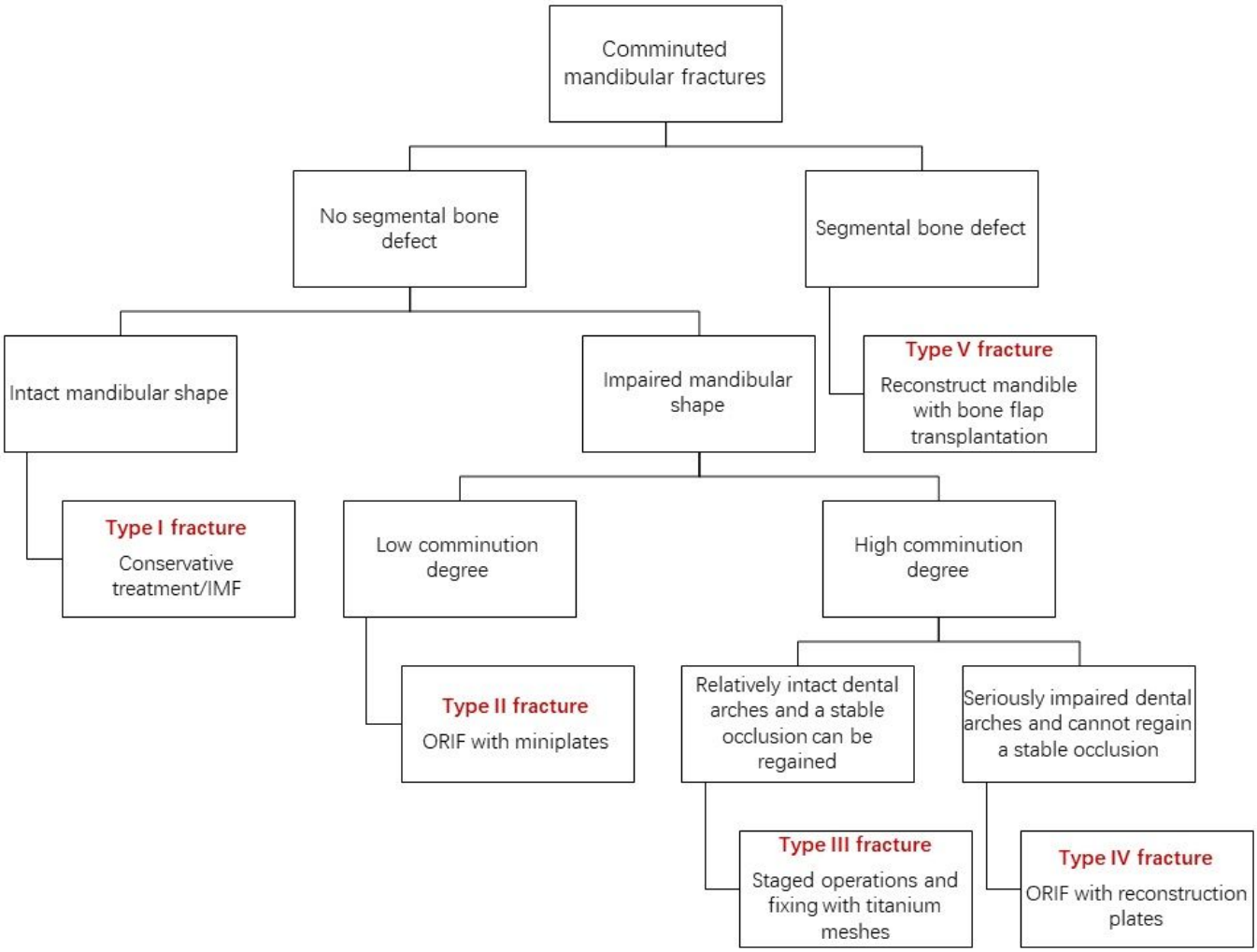


**Figure 1**

the new classification and treatment algorithm of Comminuted mandibular fractures.

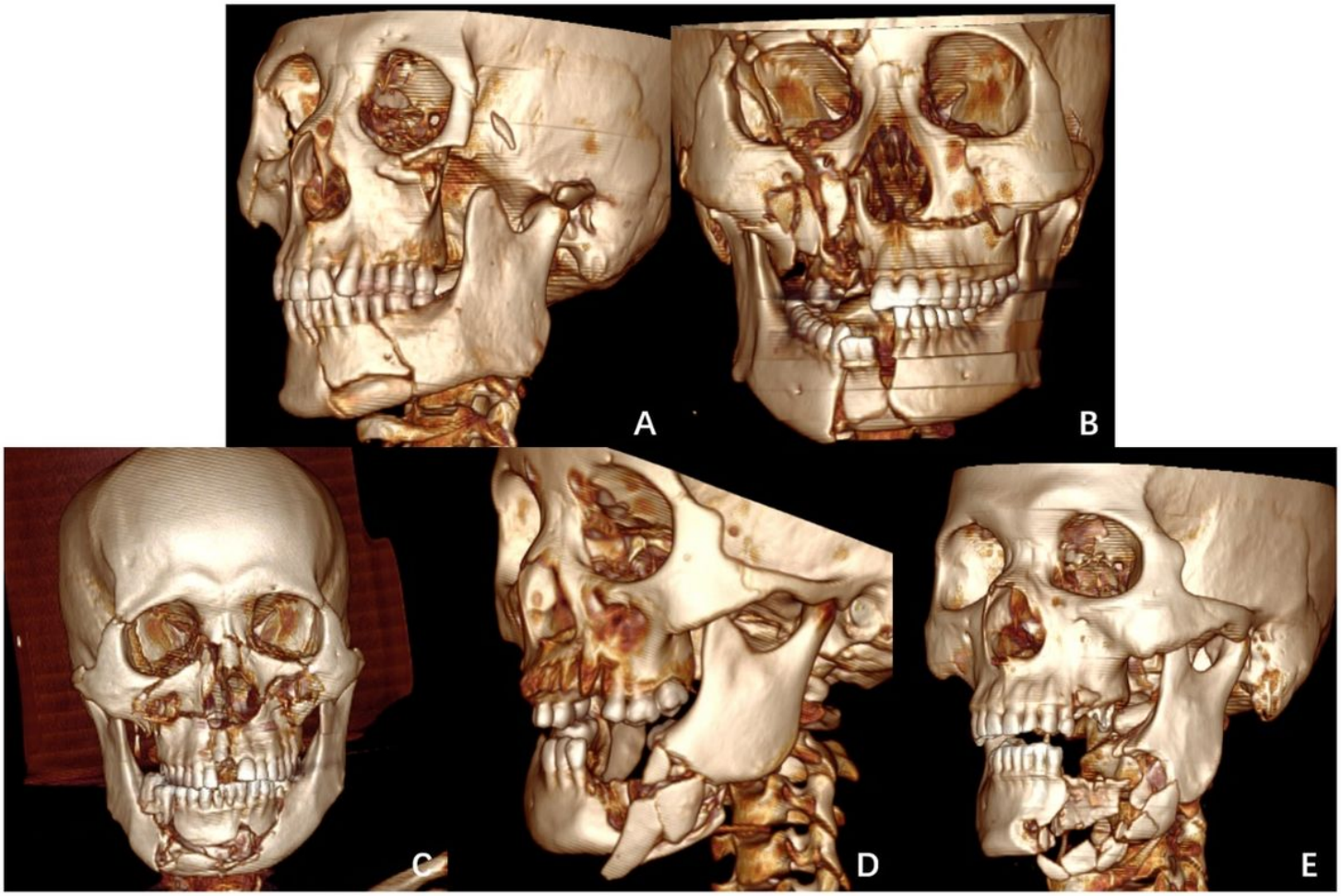


**Figure 2**

the new classification of Comminuted mandibular fractures. (A) type I fracture; (B) type II fracture; (C) type III fracture; (D) type IV fracture; (E) type V fracture.

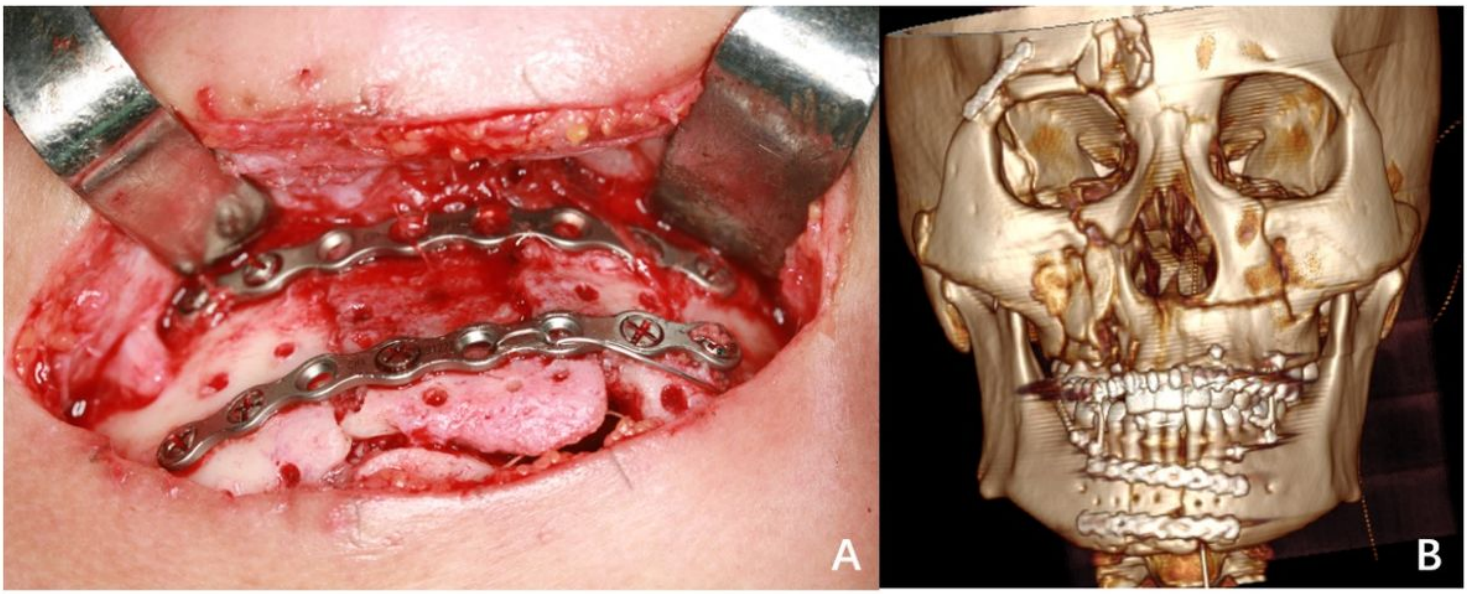


**Figure 3**

the treatment of type II fracture. (A) bone segments were reduced and fixed with miniplates. (B) the postoperation 3DCT, the occlusal relationship was sound and stable.

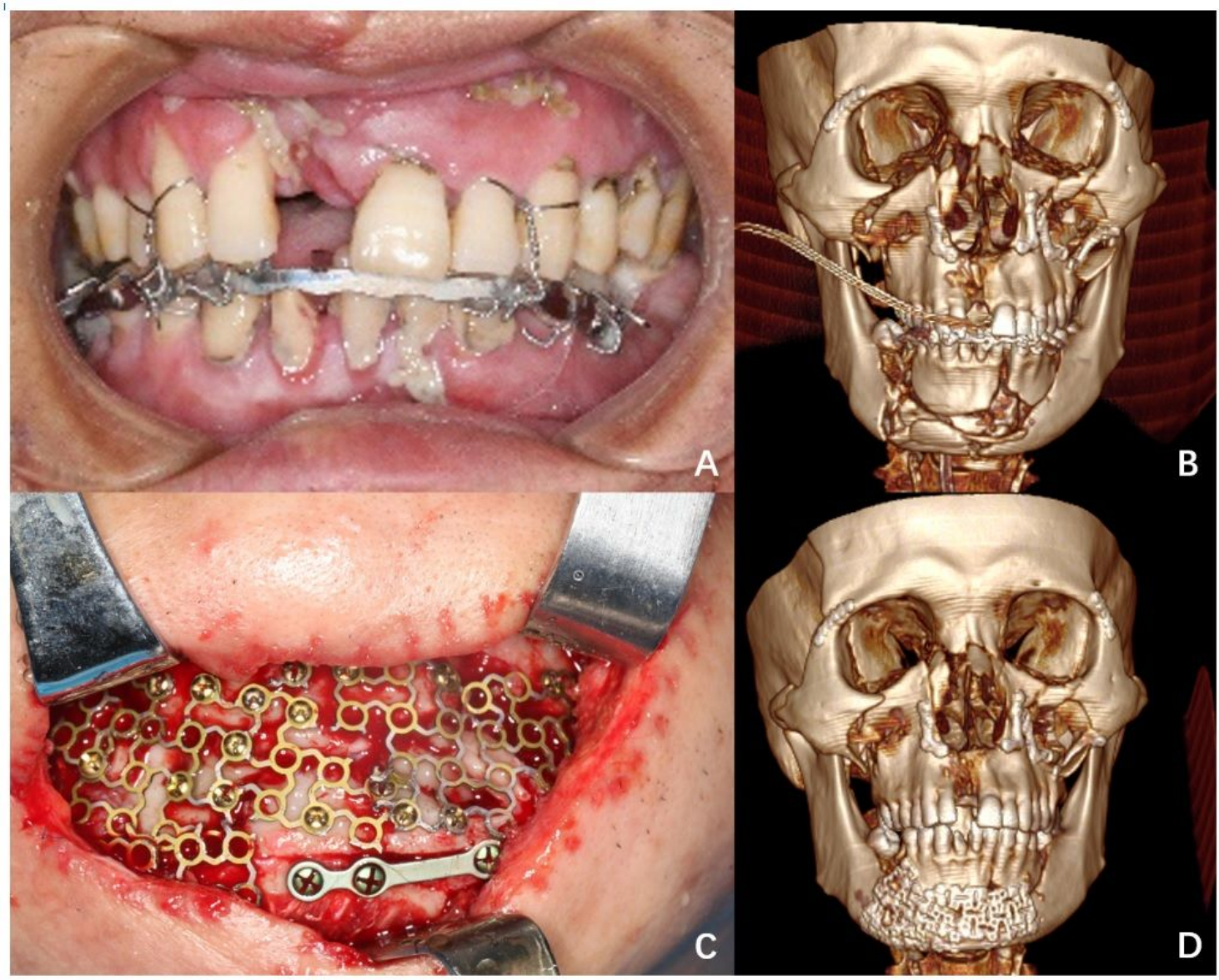


**Figure 4**

the treatment of type III fracture. (A) IMF was used for retaining occlusal relationship at stage one operation; (B) 3DCT after stage one operation and fractures were reducted and fixed except the CMF; (C) the titanium mesh used in stage two operation; (D) 3DCT after stage two operation.

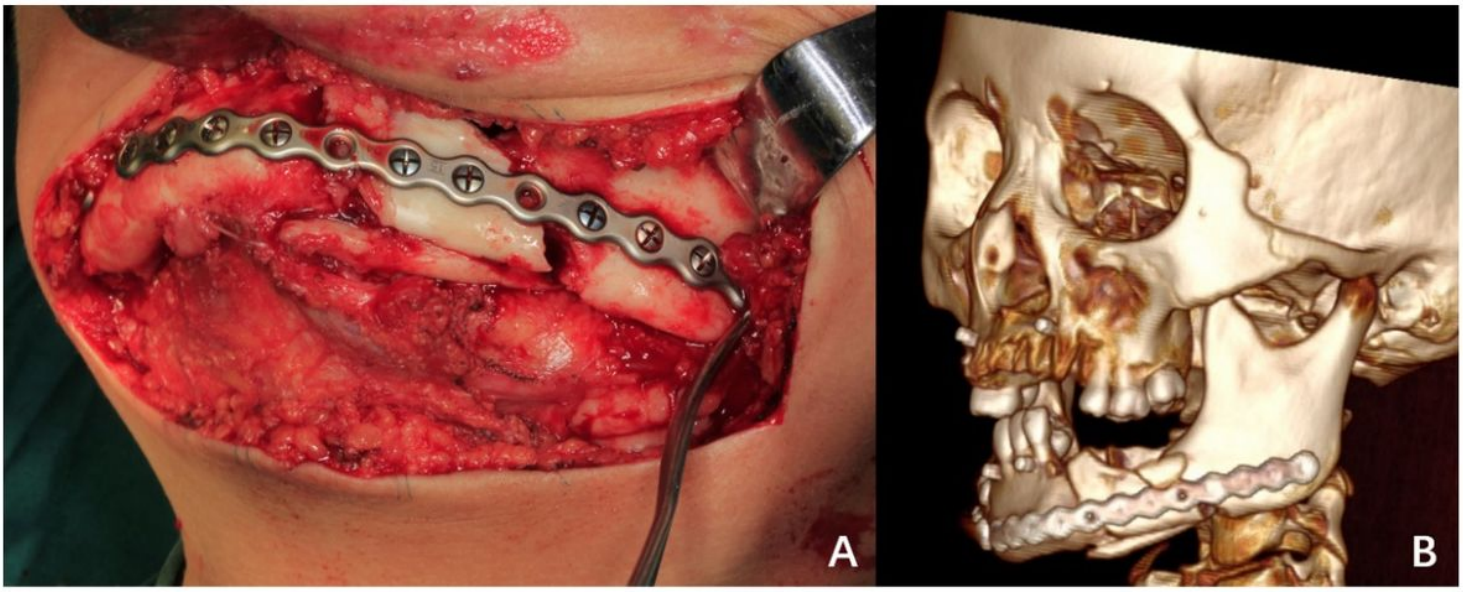


**Figure 5**

the treatment of type IV fracture. (A) bone segments were reduced and fixed with reconstruction plates and a miniplate. (B) the postoperation 3DCT, the occlusal relationship was sound and stable.