

Association Between Cervical Dysplasia and Female Genital Schistosomiasis Diagnosed by Genital PCR in Zambian Women

Hannah Rafferty

London School of Hygiene & Tropical Medicine

Amy Sturt

London School of Hygiene & Tropical Medicine

Comfort Rutty Phiri

Zambart

Emily Webb

London School of Hygiene & Tropical Medicine

Maina Mudenda

Livingstone Central Hospital

Joyce Mapani

Livingstone Central Hospital

Paul Corstjens

Leiden University Medical Center

Govert Van Dam

Leiden University Medical Center

Ab Schaap

Zambart

Helen Ayles

London School of Hygiene & Tropical Medicine

Richard Hayes

London School of Hygiene & Tropical Medicine

Lisette Van Lieshout

Leiden University Medical Center

Isaiah Hansingo

Livingstone Central Hospital


Amaya L. Bustinduy (✉ Amaya.Bustinduy@lshtm.ac.uk)

London School of Hygiene & Tropical Medicine

Keywords: Cervical dysplasia, cervical cancer, female genital schistosomiasis, neglected tropical diseases, urogenital schistosomiasis, *Schistosoma haematobium*, visual inspection with acetic acid, VIA, PCR

Posted Date: March 11th, 2021

DOI: <https://doi.org/10.21203/rs.3.rs-279255/v1>

License:  This work is licensed under a Creative Commons Attribution 4.0 International License.
[Read Full License](#)

Version of Record: A version of this preprint was published at BMC Infectious Diseases on July 17th, 2021. See the published version at <https://doi.org/10.1186/s12879-021-06380-5>.

Abstract

Background: Female genital schistosomiasis (FGS) is a neglected tropical gynaecological disease that affects millions of women in sub-Saharan Africa (SSA). FGS is caused by *Schistosoma* (*S.*) *haematobium*, a parasitic carcinogen involved in the pathogenesis of squamous cell carcinoma of the bladder. Cervical cancer incidence and mortality are highest in SSA, where pre-cancerous cervical dysplasia is often detected on screening with visual inspection with acetic acid (VIA). No studies have evaluated the association between VIA positivity and FGS diagnosed by genital PCR.

Methods: Women were recruited from the BILHIV study in Zambia, which compared genital self-sampling to provider obtained cervicovaginal-lavage for the diagnosis of FGS in women aged 18-31. FGS was defined as positive *Schistosoma* DNA from any genital PCR. Urogenital schistosomiasis diagnostics included urine circulating anodic antigen, urine microscopy and portable colposcopy. Participants were offered cervical cancer screening using VIA at Livingstone Central Hospital. Associations of PCR confirmed FGS and other diagnostics with VIA positivity were assessed using multivariable logistic regression.

Results: VIA results were available from 237 BILHIV participants. A positive *Schistosoma* PCR in any genital specimen was detected in 14 women (5.9%), 28.6% (4/14) of these women had positive VIA compared to 9.0% (20/223) without PCR evidence of schistosome infection. *Schistosoma* PCR positivity in any genital specimen was strongly associated with VIA positivity (OR: 6.08, 95% CI: 1.58-23.37, $P=0.02$).

Conclusions: This is the first study to find an association between FGS and positive VIA, a relationship that may be causal. Further longitudinal studies are needed.

Introduction

Female genital schistosomiasis (FGS) is a neglected parasitic gynaecological disease that affects an estimated 56 million women in sub-Saharan Africa (1, 2). It is most commonly caused by *Schistosoma* (*S.*) *haematobium*, freshwater flukes which lay eggs in the vesicular plexus (2). These eggs become entrapped in the urogenital mucosa resulting in inflammation and reproductive morbidity (3). Cervical cancer is a leading cause of cancer-related deaths in African women (4–6). *S. haematobium* infection causes squamous cell carcinoma (SCC) of the bladder, therefore a role in cervical cancer pathogenesis is plausible (7). This is a prescient prospect given the recent launch by WHO of a global initiative to eliminate cervical cancer by 2030 (8).

In the absence of a reference standard, making a FGS diagnosis can be challenging and often requires the use of multiple diagnostic modalities. FGS is associated with typical genital mucosal visible lesions, however parasite eggs can be found in macroscopically normal tissue (9, 10). Sandy patches (grainy and homogenous) and abnormal blood vessels have been associated with *S. haematobium* eggs on pap smear (11). Cervicovaginal lavage (CVL) or genital swabs can be used to detect *Schistosoma* DNA by

PCR (12, 13). Community-based approaches have shown that FGS diagnosis using self-collected cervical and vaginal swabs is acceptable to participants, has comparable sensitivity to CVL (12), and provides an objective alternative to imaging (14). Urine microscopy for eggs or the detection of circulating anodic antigen (CAA) can diagnose active schistosome infection, but do not necessarily reflect genital involvement (12, 15).

Pre-cancerous stages of cervical cancer are treatable and can be detected with screening (16). Human papillomavirus (HPV) testing is WHO-recommended for cervical screening (17). In resource-constrained settings where HPV testing is unavailable, visual inspection with acetic acid (VIA) can visualise pre-cancerous lesions (18). Identified lesions are treated with cryotherapy or loop electrosurgical excision procedure (LEEP). The co-existence of FGS and cervical malignancy is well-documented in pathology reports (19, 20), and homogenous sandy patches have been associated with the presence of high risk HPV (21), however this association is not universally reported (22). This study aimed to evaluate the association between FGS and cervical dysplasia diagnosed by VIA in Zambian women.

Materials And Methods

Participant recruitment

Between January and August 2018, 18–31 year-old, non-pregnant, sexually active participants in two schistosomiasis low-endemic communities in Zambia were consecutively recruited after the 36-month HPTN 071 (PopART) study visit to the bilharzia and HIV (BILHIV) study (12, 23).

As previously described, after informed consent, participants self-collected a urine sample, and cervical and vaginal swabs. During clinic follow-up, midwives performed CVL and portable colposcopy (MobileODT, Tel Aviv, Israel) to capture images of the vagina and cervix (12).

Cervicovaginal images were evaluated by one reviewer and classified as suggestive of '*visual FGS*' if homogenous sandy patches, grainy sandy patches, rubbery papules, or abnormal blood vessels were present, and negative if none were present (24). Women with evidence of schistosome infection by any diagnostic, or by midwife's clinical examination (24) were treated with 40mg/kg praziquantel as recommended by WHO (24). Participants with suspected sexually transmitted infections (STI) were offered syndromic management, as per Ministry of Health guidelines (25). Routine STI testing was not performed at the point-of-care in this study. Laboratory-based fourth-generation HIV-1 testing (Abbott Architect HIV Ag/Ab Combo Assay, Wiesbaden, Germany) was performed for HPTN 071 (PopART) participants at each study visit (23).

Visual inspection with acetic acid

Due to high community HIV prevalence (26), all women regardless of age, are routinely offered cervical cancer screening with VIA at the Cervical Cancer Clinic (CCC), in Livingstone Central Hospital by the Zambian Health Service. After CVL, midwives applied 3–5% acetic acid to the cervix. An opaque white

reaction was classified as positive and no change was negative (18). VIA results were documented in the clinical records at the CCC and were not collected as part of BILHIV. Later, data matching was performed to identify BILHIV participants that had also attended the CCC. All BILHIV participants with an available VIA result from routine Zambia Health Service screening were included if data could be matched from both sources.

***Schistosoma* diagnostics**

DNA isolation was performed at Leiden University Medical Center (LUMC), followed by real time-PCR for the detection of *Schistosoma* DNA, as previously described (12, 27, 28). CAA quantification was performed using an up-converting reporter particle lateral flow assay (UCP-LF) at LUMC (29). Analysing the equivalent of 417 µL urine, a CAA value of > 0.6 pg/mL was considered positive based on a series of negative controls (highest value plus 2 SDs) (29).

Ethics:

Ethical approval was granted by LSHTM (reference 16451) and University of Zambia Biomedical Research Ethics Committee (reference: 011-08-17). Livingstone Central Hospital Superintendent gave permission to conduct the study.

Statistical methods:

Cervical dysplasia diagnosed by VIA was the dependent variable. Univariable logistic regression analysis was carried out to assess associations between all exposure variables and VIA, multivariable logistic regression analysis was used to assess associations between FGS variables and VIA adjusted for age and HIV status as *a priori* confounders. No further potential confounders could be included due to the small number of women with positive VIA. P-values were generated using likelihood ratio tests. All data were analysed using STATA 15 (30).

Results

A total of 237/527 (44.9 %) women from the BILHIV study also had VIA results available and were included in the analysis (see Fig. 1).

The median age was 24 years (IQR 22–27) and the majority had some secondary education and were not currently employed. All 24 women (10.1%) with positive VIA (Table 1) were treated; 20 with cryotherapy (83.3%) and 4 with LEEP (16.7%). There was no association between any demographic factors and VIA positivity (S1 table).

Table 1
Baseline characteristics and diagnostic test results amongst 237 participant women.

Characteristics		n (%)
Demography		
Age (years)	18–22	64 (27.0)
	23–26	91 (38.4)
	27–31	82 (34.6)
Education	None or primary	74 (31.2)
	Secondary or higher	163 (68.8)
Employment	Unemployed	163 (68.8)
	Employed	74 (31.2)
Marital status	Currently single	116 (49.0)
	Currently married	121 (51.1)
Ever pregnant	Never	36 (15.2)
	Yes	201 (84.8)
Contraception	Yes	183 (77.2)
	No	54 (22.8)
Previous bilharzia diagnosis or treatment	Yes	29 (12.2)
	Unsure	10 (4.2)
	No	198 (83.5)
HIV		
HIV status***	Positive	56 (23.8)
	Negative	179 (76.2)
HIV status self-reported****	Positive	42 (17.8)
	Negative	194 (82.2)
HIV seroconversion during HPTN 071 ***	Yes	5 (2.1)
	No	230 (97.9)
Cervical dysplasia		
*n = 216, 21 women with uninterpretable images; **n = 236, one urine vial arrived to LUMC empty; ***n = 235, 2 results missing from HPTN-071 (PopART) database; ****n = 236, one woman declined to disclose status		

Characteristics		n (%)
VIA	Positive	24 (10.1)
	Negative	213 (89.9)
Treatment	No treatment	208 (87.8)
	Cryotherapy	20 (8.4)
	LEEP	4 (1.7)
	Antibiotics	5 (2.1)
<i>Schistosoma</i> diagnostics		
Genital <i>Schistosoma</i> PCR	Positive	14 (5.9)
	Negative	223 (94.1)
Imaging findings suggestive of FGS*	Present	70 (29.5)
	Absent	146 (61.6)
CAA**	Positive	35 (14.8)
	Negative	201 (84.8)
Urine microscopy	Positive	15 (6.3)
	Negative	222 (93.7)
*n = 216, 21 women with uninterpretable images; **n = 236, one urine vial arrived to LUMC empty; ***n = 235, 2 results missing from HPTN-071 (PopART) database; ****n = 236, one woman declined to disclose status		

The prevalence of active *S. haematobium* infection was 6.3% (15/237) by urine microscopy, and 14.8% (35/237) by urine CAA (Table 1). *Schistosoma* PCR in any genital specimen (CVL, cervical or vaginal swab) was positive in 14/237 (5.9%). Colposcopy images were interpretable in 216 women, of these 70 had 'visual FGS' (29.5%). HIV-1 prevalence was 23.8% (56/235).

Of 14 women with positive *Schistosoma* PCR, 4 were VIA positive (28.6%), compared to 20 of 223 with negative PCR (9.0%). The adjusted odds ratio for FGS diagnosed by genital PCR and positive VIA was 6.08 (95% CI: 1.58–23.37) with strong evidence for this association ($P = 0.016$). There was no evidence for an association between VIA positivity and 'visual FGS' (OR: 0.58, 95% CI: 0.20–1.69, $P = 0.30$) or urine CAA/microscopy (OR 2.21, 95% CI 0.83–5.89, $P = 0.13$) (see Fig. 2).

Discussion

This study is the first to provide evidence for an association between FGS and cervical dysplasia. These are two common gynaecological conditions in SSA, which together lead to significant morbidity and mortality. Chronic inflammation due to *S. haematobium* egg deposition is thought to be on the causal pathway to bladder squamous cell carcinoma (7). We hypothesize that the consequences of *S. haematobium* egg deposition in FGS could similarly contribute to cervical cancer pathogenesis (Fig. 3). Possible mechanistic synergies include FGS-related epithelial disruption (31) allowing HPV to establish infection, and the recruitment of immune cells that may influence the interaction of HIV or HPV with cervical tissue. Additionally, changes in local pro-inflammatory cytokines may promote HPV persistence or transcription (32) and a systemic Th2 environment may be associated with cervical lesion progression (33). This finding has important clinical implications in endemic areas where FGS is not yet considered a risk factor for cervical cancer (34). If this association is substantiated FGS diagnosis and treatment could become an important component of cervical cancer prevention.

Several previous studies have investigated the association between *S. haematobium* and cervical dysplasia. However, heterogeneous methods in diagnosing both the exposure (FGS) and the outcome (cervical dysplasia) make cross-study comparisons challenging. In a South African study, no association was found between FGS diagnosed by CVL PCR, pap-smear and cervical dysplasia diagnosed with cytology. However, over 97% of pap-smears from women with FGS were uninterpretable, limiting the sample size (22). A population-based cross-sectional study in Zimbabwe showed an association between the presence of typical FGS homogenous yellow sandy patches and high-risk HPV (35). After 5 years of follow-up in this cohort, sandy patches were not associated with high risk HPV persistence or cervical dysplasia but again, conclusions were limited by low power (21).

To our knowledge, VIA has not previously been used for the diagnosis of cervical dysplasia in the context of FGS. A meta-analysis found a pooled sensitivity of 78% and specificity of 88% for CIN2+/high-grade squamous intraepithelial lesion detection by VIA (36), and was preferable in terms of resources and availability (37). However, we cannot exclude that our findings are related to the lower specificity of VIA compared with cytology. In our cohort we found a low uptake of cervical cancer screening (44.9%), which has previously been demonstrated in Zambia (43). This may reflect known barriers to cervical cancer screening such as limited health education and stigma (44). Indeed, a 2016 cross-sectional study in Lusaka, Zambia found that only 36.8% of participants had heard of cervical cancer and only 20.7% of women had ever attended screening (45). VIA has been extensively used in Zambia and has been shown to be effective in reducing cervical cancer related mortality (38), and can be effectively scaled up to reach a higher proportion of the population (39).

This study included young women aged 18–31. There is a lack of evidence surrounding age of initiation for cervical screening, in part due to reduced cervical cancer incidence in women under 25 (4), lesion regression in younger women (40), and potential of harm with cervical interventions (41). Zambian guidelines suggest screening initiation at 25 and WHO recommends screening HIV-positive women regardless of age (42). Due to high HIV prevalence, all women presenting to Livingstone Central Hospital

are offered VIA screening (26). Including only younger women in this study may limit its generalisability and further investigation including older women may be required.

This study is the first to illustrate how FGS diagnostics could be integrated into existing cervical cancer screening programmes, potentially facilitating the diagnosis and treatment of two common and morbid gynaecological conditions at a single clinic visit. Given the cross-sectional study design, we cannot ascertain causality between FGS and cervical dysplasia. Lack of HPV testing, and absence of tissue biopsy to confirm VIA results also limit our conclusions. A longitudinal study is needed to investigate a temporal relationship between FGS, HPV, and cervical dysplasia across age groups and geographic locations. Mechanistic studies are also needed to elucidate the potential synergy between *S. haematobium* and HPV in cervical dysplasia. However, VIA remains a real-world diagnostic approach in low and middle income countries and is the recommended WHO screening modality in these settings (17).

In conclusion, this study shows an association between FGS, diagnosed by genital PCR, and VIA-positivity. Further research is needed to evaluate the association between FGS and cervical dysplasia and cervical cancer. If a causal link is established, FGS diagnosis and treatment may garner further importance to help reduce the burden of cervical cancer and achieve the WHO 2030 goal of cervical cancer elimination.

Abbreviations

CAA – Circulating anodic antigen, CI – Confidence interval, FGS – female genital schistosomiasis, HIV – Human immunodeficiency virus, OR – odds ratio, PCR – polymerase chain reaction, VIA – Visual inspection with acetic acid

Declarations

All methods were carried out in accordance with relevant guidelines and regulations.

Ethics and consent to participate:

Informed consent was obtained from all study participants. Ethical approval was granted by LSHTM (reference 16451) and University of Zambia Biomedical Research Ethics Committee (reference: 011-08-17). Livingstone Central Hospital Superintendent gave permission to conduct the study.

Consent for publication:

Informed consent was obtained from all study participants for publication and dissemination of results. All authors gave consent for publication.

Acknowledgements:

We would like to acknowledge the participants, and the efforts of field workers and midwives: N. Chola, E. Mwansa, M. Lukonga, R. Mwanza, M. Kantukaleza, J. Lungu, J. Mapani and M. Mudenda. We thank E. Kjetland for her image reviews. We gratefully acknowledge E. Briennen (LUMC) for performing the *Schistosoma* PCR, C. deDood (LUMC) and P. Hoekstra (LUMC) for performing the CAA analysis.

Author Contributions:

H. Rafferty: Conceptualisation, Methodology, Formal analysis, Investigation, Writing – Original Draft. **A.S. Sturt:** Methodology, Investigation, Data curation, Writing- Review & Editing, Project administration. **C.R. Phiri:** Project administration, Writing- Review & Editing. **E.L. Webb:** Formal analysis, Supervision, Data curation, Writing- Review & Editing. **M. Mudenda:** Investigation, project administration. **J. Mapani:** Investigation, project administration. **P.L.A.M. Corstjens:** Investigation, Writing – Review & Editing. **G. J. Van Dam:** Investigation, Writing – Review & Editing. **A. Schaap:** Data curation **H. Ayles:** Resources, Writing – Review & Editing. **R. J. Hayes:** Resources, Writing – Review & Editing. **L. Van Lieshout:** Investigation, Writing- Review & Editing. **I. Hansingo:** Resources, Project administration, Writing- Review & Editing **A.L. Bustinduy:** Conceptualization, Methodology, Writing – Review and Editing, Supervision, Project administration, Funding acquisition

Authors report no conflict of interest and give consent for publication

Funding:

ALB is supported by a grant from the Wellcome Trust (205954/Z/17/Z) <https://wellcome.ac.uk>. ELW and RH received salary funding from MRC Grant Reference MR/K012126/1. This award is jointly funded by the UK Medical Research Council (MRC) and the UK Department for International Development (DFID) under the MRC/DFID Concordat agreement and is also part of the EDCTP2 program supported by the European Union. The funders had no role in study design, data collection and analysis, decision to publish, or preparation of the manuscript.

Data Availability:

Due to the sensitive nature of the data collected in the BILHIV study, data will be available upon request by contacting the study PI Dr. Amaya Bustinduy. The data will be available on LSHTM Data Compass. Data will available on request, which is advised by the LSHTM information management team. The data will be available by request on LSHTM Data Compass.

References

1. Hotez PJ, Harrison W, Fenwick A, Bustinduy AL, Ducker C, Sabina Mbabazi P, et al. Female genital schistosomiasis and HIV/AIDS: Reversing the neglect of girls and women. PLoS neglected tropical diseases. 2019.

2. Kjetland EF, Leutscher PDC, Ndhlovu PD. A review of female genital schistosomiasis. Vol. 28, Trends in Parasitology. 2012. p. 58–65.
3. Christinet V, Lazdins-Helds JK, Stothard JR, Reinhard-Rupp J. Female genital schistosomiasis (FGS): From case reports to a call for concerted action against this neglected gynaecological disease. International Journal for Parasitology. 2016.
4. The Union International Cancer Control. New Global Cancer Data: GLOBOCAN 2018 | UICC. Geneva, Switzerland, 12 Sept 2018 [Internet]. 2018;(September):1. Available from: <https://www.uicc.org/new-global-cancer-data-globocan-2018>
5. Jedy-Agba E, Joko WY, Liu B, Buziba NG, Borok M, Korir A, et al. Trends in cervical cancer incidence in sub-Saharan Africa. Br J Cancer. 2020;123(1).
6. WHO Africa. Cervical cancer common amongst African women. 2018.
7. IARC. Schistosomes, Liver Flukes and Helicobacter pylori. Iarc Monogr Eval Carcinog Risks To Humans. 1994;
8. World Health Organisation. A Global Strategy for elimination of cervical cancer. Who. 2019.
9. Poggensee G, Kiwelu I, Weger V, Göppner D, Diedrich T, Krantz I, et al. Female Genital Schistosomiasis of the Lower Genital Tract: Prevalence and Disease-Associated Morbidity in Northern Tanzania. J Infect Dis. 2000;
10. Poggensee G, Sahebali S, Van Marck E, Swai B, Krantz I, Feldmeier H. Diagnosis of genital cervical schistosomiasis: Comparison of cytological, histopathological and parasitological examination. Am J Trop Med Hyg. 2001;
11. Norseth HM, Ndhlovu PD, Kleppa E, Randrianasolo BS, Jourdan PM, Roald B, et al. The Colposcopic Atlas of Schistosomiasis in the Lower Female Genital Tract Based on Studies in Malawi, Zimbabwe, Madagascar and South Africa. PLoS Negl Trop Dis. 2014;
12. Sturt A, Webb E, Phiri C, Mweene T, Chola N, van Dam G, et al. Genital Self-Sampling Compared with Cervicovaginal Lavage for the Diagnosis of Female Genital Schistosomiasis in Zambian Women: the BILHIV Study. PLoS Negl Trop Dis. 2020;14(7).
13. Kjetland EF, Ten Hove RJ, Gomo E, Midzi N, Gwanzura L, Mason P, et al. Schistosomiasis PCR in vaginal lavage as an indicator of genital Schistosoma haematobium infection in rural Zimbabwean women. Am J Trop Med Hyg. 2009;
14. Phiri C, Sturt A, Webb E, Chola N, Hayes R, Shanaube K, et al. Acceptability and feasibility of genital self-sampling for the diagnosis of female genital schistosomiasis: a cross-sectional study in Zambia [version 1; peer review: awaiting peer review]. Wellcome Open Res. 2020;5:61.
15. Poggensee G, Kiwelu I, Saria M, Richter J, Krantz I, Feldmeier H. Schistosomiasis of the lower reproductive tract without egg excretion in urine. Am J Trop Med Hyg. 1998;
16. Jenkins D. Histopathology and cytopathology of cervical cancer. Vol. 23, Disease Markers. 2007.
17. WHO. Guidelines for screening and treatment of precancerous lesions for cervical cancer prevention. WHO Guidel. 2013;

18. Sankaranarayanan R, Wesley R, Thara S, Dhakad N, Chandralekha B, Sebastian P, et al. Test characteristics of visual inspection with 4% acetic acid (VIA) and Lugol's iodine (VILI) in cervical cancer screening in Kerala, India. *Int J Cancer*. 2003;
19. Gwavava C., Harrison N.J.T., Gwata D.J. TFZ. Incidence of Schistosomiasis in surgical biopsies: a review of 284 cases. *Cent Afr J Med*. 1984;30(12):241–5.
20. Youssef AF, Fayad MM, Shafeek MA. BILHARZIASIS OF THE CERVIX UTERI. *BJOG An Int J Obstet Gynaecol*. 1970;
21. Kjetland EF, Ndhlovu PD, Mduluza T, Deschoolmeester V, Midzi N, Gomo E, et al. The effects of genital *Schistosoma haematobium* on human papillomavirus and the development of cervical neoplasia after five years in a Zimbabwean population. *Eur J Gynaecol Oncol*. 2010;31(2):169–73.
22. Pillay P, Van Lieshout L, Taylor M, Sebitloane M, Zulu SG, Kleppa E, et al. Cervical cytology as a diagnostic tool for female genital schistosomiasis: Correlation to cervical atypia and *Schistosoma* polymerase chain reaction. *Cytojournal*. 2016;13(1).
23. Hayes, R, Donnell, D, Floyd, S, Mandla, S, Bwalya, J, Sabapathy, K, Yang, B, Phiri, M, Schaap, A, Eshleman, S, Piwowar-Manning, E, Kosloff, BM.Sc., et al. Effect of Universal Testing and Treatment on HIV Incidence – HPTN 071 (PopART). *N Engl J Med*. 2019;381:207–18.
24. World Health Organisation. Female genital schistosomiasis. A pocket atlas for clinical health-care professionals. *Who/Htm/Ntd/20154*. 2015;
25. Health ZM of. Guidelines for the Etiological and Clinical Management of Sexually Transmitted Infections in Zambia. 2017;
26. UNAIDS. UNAIDS Country Factsheet: Zambia 2018. 2018.
27. Obeng BB, Aryeetey YA, De Dood CJ, Amoah AS, Larbi IA, Deelder AM, et al. Application of a circulating-cathodic-antigen (CCA) strip test and real-time PCR, in comparison with microscopy, for the detection of *Schistosoma haematobium* in urine samples from Ghana. *Ann Trop Med Parasitol*. 2008;102(7).
28. Pillay P, Taylor M, Zulu SG, Gundersen SG, Verweij JJ, Hoekstra P, et al. Real-time polymerase chain reaction for detection of *Schistosoma* DNA in small-volume urine samples reflects focal distribution of urogenital schistosomiasis in primary school girls in KwaZulu Natal, South Africa. *Am J Trop Med Hyg*. 2014;90(3).
29. Corstjens PLAM, de Dood CJ, Knopp S, Clements MN, Ortu G, Umulisa I, et al. Circulating Anodic Antigen (CAA): A Highly Sensitive Diagnostic Biomarker to Detect Active *Schistosoma* Infections—Improvement and Use during SCORE. *Am J Trop Med Hyg*. 2020;
30. STATA. STATA Glossary and Index Release 15. *Stata - Manual Usuari*. 2013.
31. Sturt AS, Webb EL, Francis SC, Hayes RJ, Bustinduy AL. Beyond the barrier: Female Genital Schistosomiasis as a potential risk factor for HIV-1 acquisition. Vol. 209, *Acta Tropica*. 2020.
32. Scott ME, Shvetsov YB, Thompson PJ, Hernandez BY, Zhu X, Wilkens LR, et al. Cervical cytokines and clearance of incident human papillomavirus infection: Hawaii HPV cohort study. *Int J Cancer*. 2013;133(5).

33. Bais AG, Beckmann I, Ewing PC, Eijkemans MJC, Meijer CJLM, Snijders PJF, et al. Cytokine release in HR-HPV(+) women without and with cervical dysplasia (CIN II and III) or carcinoma, compared with HR-HPV(-) controls. *Mediators Inflamm.* 2007;2007.
34. Cohen PA, Jhingran A, Oaknin A, Denny L. Cervical cancer. Vol. 393, *The Lancet*. 2019.
35. Kjetland EF, Ndhlovu PD, Mdulaza T, Gomo E, Gwanzura L, Mason PR, et al. Simple clinical manifestations of genital schistosoma *Haematobium* infection in rural Zimbabwean women. *Am J Trop Med Hyg.* 2005;72(3):311–9.
36. Catarino R, Schäfer S, Vassilakos P, Petignat P, Arbyn M. Accuracy of combinations of visual inspection using acetic acid or lugol iodine to detect cervical precancer: a meta-analysis. *BJOG: An International Journal of Obstetrics and Gynaecology*. 2018.
37. De Vuyst H, Claeys P, Njiru S, Muchiri L, Steyaert S, De Sutter P, et al. Comparison of pap smear, visual inspection with acetic acid, human papillomavirus DNA-PCR testing and cervicography. *Int J Gynecol Obstet.* 2005;
38. Parham GP, Mwanahamuntu MH, Sahasrabuddhe V V., Westfall AO, King KE, Chibweshwa C, et al. Implementation of cervical cancer prevention services for HIV-infected women in Zambia: Measuring program effectiveness. *HIV Ther.* 2010;4(6).
39. Parham GP, Mwanahamuntu MH, Kapambwe S, Muwonge R, Bateman AC, Blevins M, et al. Population-level scale-up of cervical cancer prevention services in a low-resource setting: Development, implementation, and evaluation of the cervical cancer prevention program in Zambia. *PLoS One.* 2015;
40. Tainio K, Athanasiou A, Tikkinen KAO, Aaltonen R, Cárdenas J, Hernández, et al. Clinical course of untreated cervical intraepithelial neoplasia grade 2 under active surveillance: Systematic review and meta-analysis. *BMJ (Online)*. 2018.
41. Kyrgiou M, Koliopoulos G, Martin-Hirsch P, Arbyn M, Prendiville W, Paraskevaides E. Obstetric outcomes after conservative treatment for intraepithelial or early invasive cervical lesions: Systematic review and meta-analysis. *Lancet.* 2006;
42. WHO. WHO guidelines: essential prevention and care interventions for adults and adolescents living with HIV in resource limited settings. 2008.
43. Siziya, PhD S, Kabalika, MBChB C, Mulenga, MPH D, Mazaba, MSc ML. Acceptance of Cervical Cancer Screening and its Correlates Among Women of a Peri-Urban High-Density Residential Area in Ndola, Zambia. *Int J MCH AIDS.* 2018;
44. Pierz AJ, Randall TC, Castle PE, Adedimeji A, Ingabire C, Kubwimana G, et al. A scoping review: Facilitators and barriers of cervical cancer screening and early diagnosis of breast cancer in Sub-Saharan African health settings. Vol. 33, *Gynecologic Oncology Reports*. 2020.
45. Nyambe A, Kampen JK, Baboo SK, Van Hal G. Knowledge, attitudes and practices of cervical cancer prevention among Zambian women and men. *BMC Public Health.* 2019;

Figures

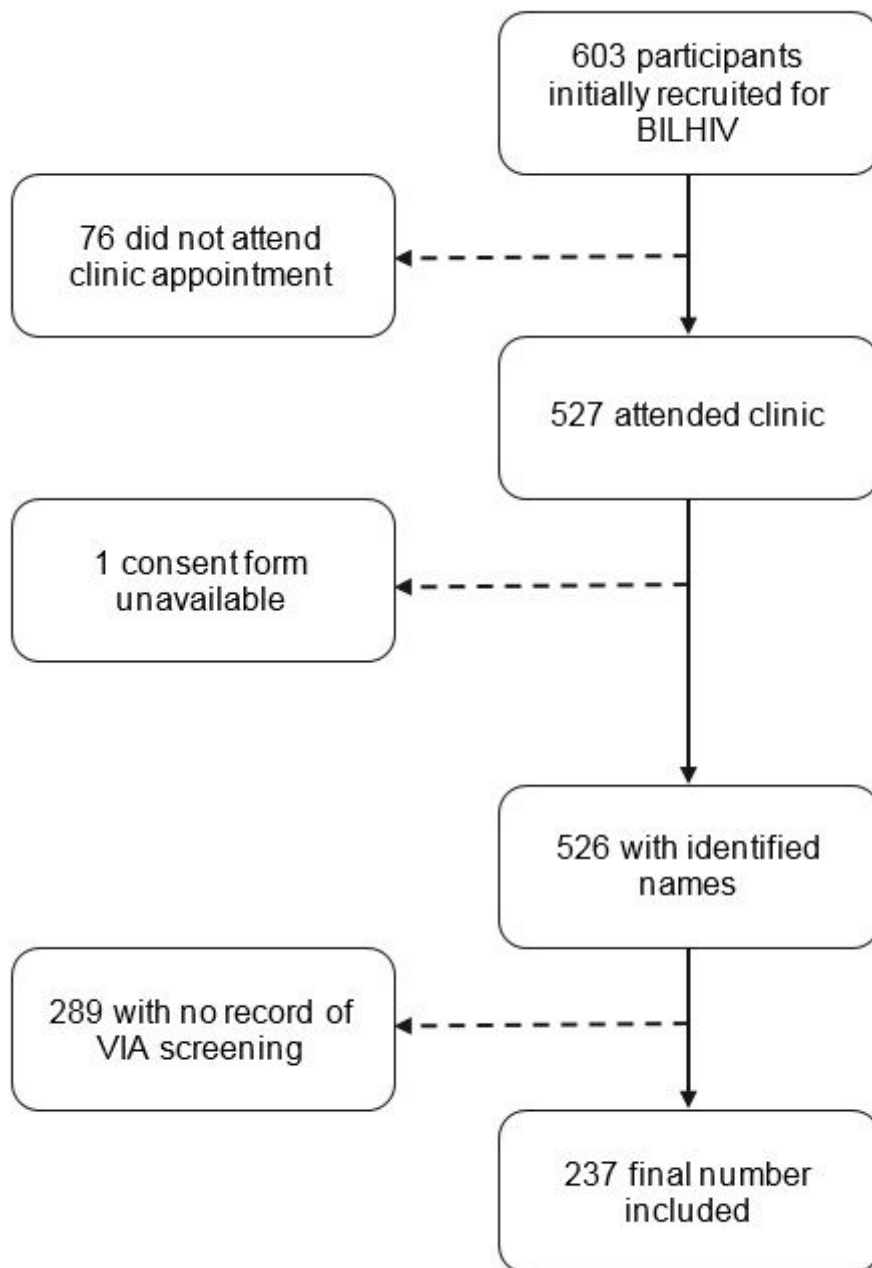


Figure 1

Participant recruitment of 237 women in the BILHIV study who underwent VIA

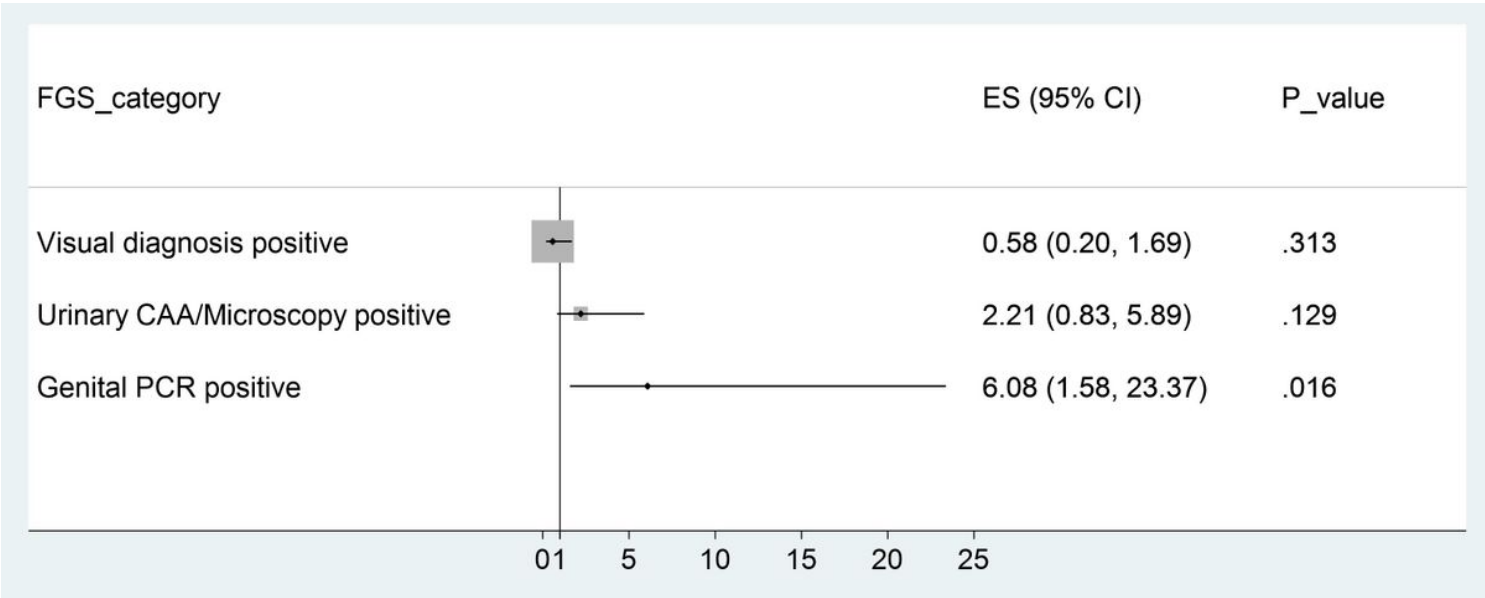


Figure 2

Forest Plot of the association of diagnostic methods with positive visual inspection with acetic acid

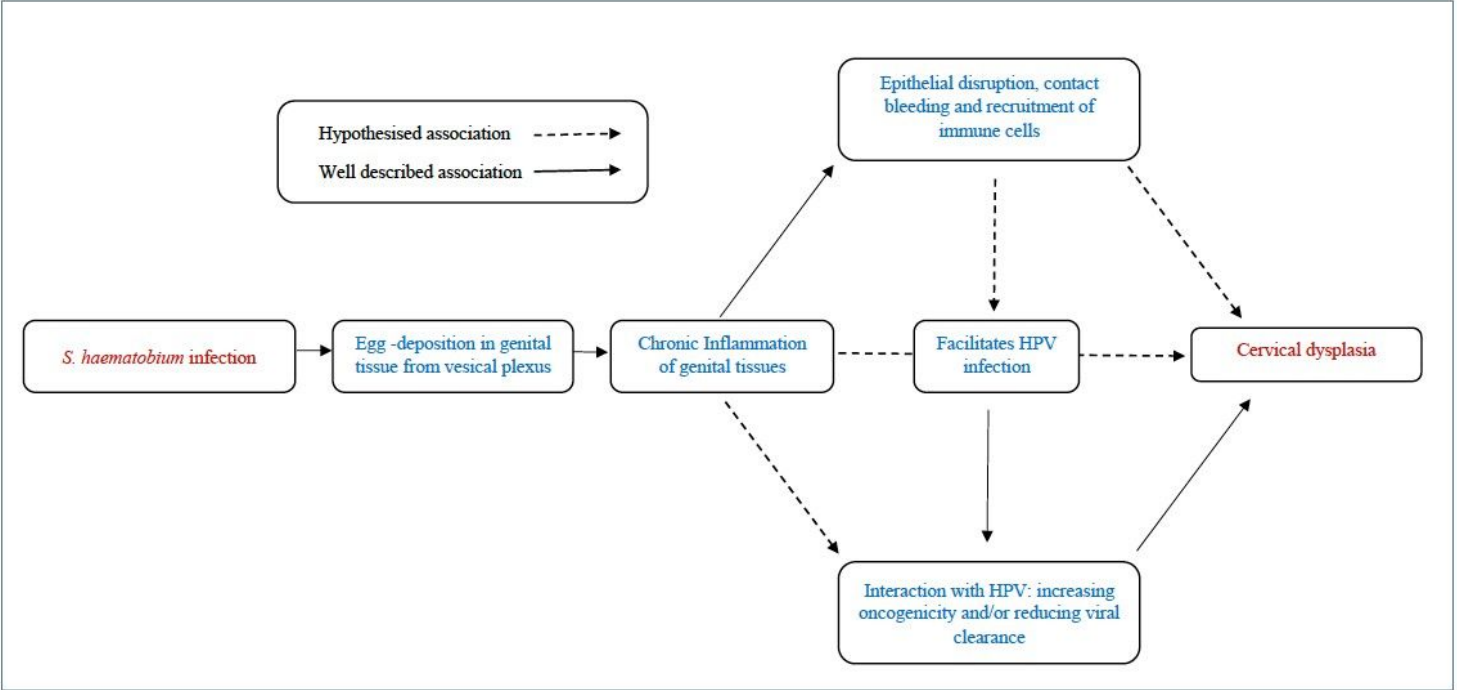


Figure 3

conceptual pathway highlighting possible mechanisms linking female genital schistosomiasis and cervical dysplasia

Supplementary Files

This is a list of supplementary files associated with this preprint. Click to download.

- [RaffertySupplementalmaterial.docx](#)