The Failure Risk of Surgical Therapy for Corneal Perforations Using Cryopreserved Donor Corneas

Miki Hata Mizuno
Keio University School of Medicine

Yuichi Uchino (hmpgx653@yahoo.co.jp)
Keio University School of Medicine

Shigeto Shimmura
Keio University School of Medicine

Kazuo Tsubota
Keio University School of Medicine

Research article

Keywords: corneal perforation, therapeutic keratoplasty, frozen donor grafts

Posted Date: May 19th, 2020

DOI: https://doi.org/10.21203/rs.3.rs-27962/v1

Abstract

Background To evaluate the long-term results of therapeutic keratoplasty for a consecutive case series of corneal perforation.

Methods The cases comprised 41 eyes (41 patients) that underwent therapeutic keratoplasty using cryopreserved donor grafts at the Keio University Hospital between January 2012 and December 2016. The eyes were evaluated regarding the cause of corneal perforation, surgical procedure, size of the perforation, presence of anterior chamber collapse, visual prognosis, and complications.

Results The major causative diseases included herpetic keratitis (n = 11), bacterial and fungal corneal ulcer (n = 4), Mooren's ulcer (n = 5), severe dry eye (n = 4), and neuroparalytic keratitis (n = 4). Penetrating keratoplasty was performed in 28 eyes (68.2%), lamellar keratoplasty in 8 eyes (19.5%), and keratoepithelioplasty in 5 eyes (12.2%).

Background

Corneal perforation is caused by various conditions such as trauma, infections, inflammatory corneal ulcer, neurotrophic disorders, and lagophthalmos. Corneal perforation is a vision-threatening condition that usually requires emergency surgical intervention to recover the anatomical structure of the eye.[1] Severe sequelae such as angle-closure glaucoma, choroidal detachment, or endophthalmitis may occur, which may lead to permanent blindness. There have been several reports on treatment techniques for corneal perforation, including bandage soft contact lenses,[2–4] cyanoacrylate glue,[5] suture of the perforated area,[4] conjunctival flaps,[2] amniotic membrane transplantation (AMT),[2,6–8] tarsorrhaphy,[9] and penetrating or lamellar keratoplasty in cases of large corneal perforations.[2,10–15] Therapeutic keratoplasty is a better surgical technique for closing large corneal perforations.[6,10,16] However, surgical techniques and postoperative management may be difficult.[17–20] In Japan, there is a shortage of donor corneas available for all corneal diseases including corneal perforation. Therefore, fresh donors are often not available in cases of an emergency, and corneal perforation patients rarely undergo surgery using a fresh donor graft. In this study, we report the clinical outcomes of the therapeutic corneal transplantation with cryopreserved grafts performed in consecutive cases over five years in the Keio University Hospital, Tokyo, Japan.

Methods

This study included 41 eyes (41 patients, 26 males and 15 females) that underwent therapeutic keratoplasty between January 2012 and December 2016 in the Keio University Hospital. All surgical procedures were performed by corneal specialists (S.S, Y.M, T.K, Y.I, M.F). In this study, clinical data including the cause of the corneal perforation, surgical procedure, anatomical recovery, size of the corneal perforation, size of the donor graft, pre-surgical condition of the iris, depth of the anterior chamber, visual prognosis, and complications were analyzed in a retrospective manner. We divided cases into two groups

according to the corneal perforation size (small, < 4 mm vs large, ≥ 4 mm), as well as into two groups according to the donor graft size in cases of penetrating keratoplasty (PKP; small, < 8.5 mm vs large, ≥ 8.5 mm). Tectonic success was defined as the successful reconstruction of the anatomical integrity of the eye, with no leakage of aqueous humor and no further surgical intervention required for the original corneal perforation. Postoperative results ending in phthisis and enucleation were excluded from tectonic success cases.

Surgical Procedures

Only one case of keratoplasty was performed under general anesthesia, whereas all other cases were done under local anesthesia including retrobulbar and sub-tenon anesthesia. All 41 keratoplasty cases used cryopreserved donor tissue stored in storage medium (Optisol) at -80 °C.

The surgical procedure of PKP was started by marking the center of the recipient cornea, and then a trephination was performed using the Hessburg-Barron vacuum trephine (Katena Products, Inc., Denville, NJ). A 0.25–0.50 mm oversized donor graft was prepared using a donor punch (Katena Products, Inc.). The recipient's corneal dissection was completed using corneal scissors. The donor tissue was placed on the host bed by an interrupted suture with 10 − 0 monofilament nylon, and all knots were buried.

For the lamellar keratoplasty (LKP), the Hessburg-Barron vacuum trephine was used to partially cut both the recipient and donor corneal stromal tissue. Lamellar dissection of the stroma was done using a disposable lamellar knife (FEATHER Safety Razor Co., Ltd., Osaka, Japan). The donor cornea was sutured with 10 − 0 monofilament nylon sutures to the recipient bed using the same suturing techniques as for the PKP.

Keratoepithelioplasty (KEP) is a surgical procedure used to treat a perforation of peripheral corneal ulcers such as in Mooren's ulcer or rheumatoid arthritis.[21] First, a conjunctival peritomy was performed along the corneal limbus. Hemorrhages were cauterized with bipolar cautery forceps. A corneal incision was made to almost 80% depth of the cornea using a knife to prepare the recipient bed. A trephine 0.25 mm larger than the ulcer was used to make a donor graft in the shape of a fan. An ophthalmic visco-surgical device was used to return the iris to the correct position in the anterior chamber. The graft was fixed to the recipient bed using 10 − 0 monofilament nylon sutures.

Subconjunctival injection of dexamethasone and gentamicin was administered after transplantation in all cases except in active bacterial and fungal cases, where only the antibiotic was injected. The postoperative treatment included topical antibacterial drops for infection control. Topical steroid therapy was also maintained except in cases of fungal infections, where the topical steroid was not used immediately after surgery. Topical steroid administration was started from twice a day after corneal epithelialization was achieved without any signs of fungal recurrence. The frequency of topical steroid application was gradually increased to four times a day and maintained for at least 1 year. Oral valacyclovir 1000 mg/day was used for herpetic keratitis for 2–3 weeks postoperatively. Optical PKP was

performed if the inflammation was controlled and no signs of recurrence were observed for at least 6 months.

Statistical Analysis

All data are reported as mean ± standard deviation. The Fisher's exact probability test and Chi-squared test were used for group comparisons. All statistical analyses were performed using Microsoft Office Excel 2016 software, version 1711 (TTT, North Carolina, USA). Categorical variables were presented as frequency (%) and compared between groups using the Chi-square test and Fisher's probability exact test. Significant differences were considered when the *P*-value was < 0.05.

Results

The study included 41 eyes of 41 patients, 26 males (63.4%) and 15 females (36.6%) with a mean age of 66.1 ± 16.3 years (range, 28–92 years). The mean follow-up period was 30.9 ± 26.3 months (range, 3–92 months).

The causes of corneal perforation (n = 41) were classified into two groups, an infectious (n = 20) and a non-infectious (n = 21) group. The causes in the infectious group included herpetic keratitis (n = 11), bacterial ulcer (n = 4), fungal ulcer (n = 4), and lacrimal canaliculitis (n = 1). The causes in the non-infectious group included Mooren's ulcer (n = 5), severe dry eye (n = 4), neuroparalytic keratitis (n = 4), lagophthalmos (n = 2), trauma (n = 2), alkali burn (n = 2), and rheumatoid arthritis (n = 2; Table 1).

Table 1
Anatomical Cure and Donor Graft Size (Penetrating Keratoplasty Cases)

Group	Graft size (mm)	Anatomical cure, n (%)	Failure, n (%)	*P*
All	≥ 8.5	3	7	< 0.01**
	< 8.5	18	0	
	Total	21 (75.0)	7 (25.0)	
Infection	≥ 8.5	3	5	< 0.01**
	< 8.5	10	0	
	Total	13 (72.3)	5 (27.7)	
Non-infection	≥ 8.5	0	2	0.02*
	< 8.5	8	0	
	Total	8 (80.0)	2 (20.0)	

Fisher's exact probability test; **$P < 0.01$, *$P < 0.05$

A tectonic cure was successfully achieved in 28 (68.3%) of 41 eyes after the first therapeutic keratoplasty procedure. A total of 14 eyes (34.1%) required additional surgical procedures, and a final tectonic cure was achieved in 34 (82.9%) of 41 eyes. Phthisis caused by a failed graft or endophthalmitis was observed in 7 eyes (17.1%). All 41 (100%) cases used cryopreserved donor tissue.

In PKP cases (28 eyes), the patients were divided into two categories according to the corneal graft size. The donor graft size was 8.5 mm or larger in 10 eyes, and 18 eyes received a donor graft with a size smaller than 8.5 mm. Donor grafts smaller than 8.5 mm achieved a significantly higher successful anatomical recovery compared to grafts larger than 8.5 mm ($P < 0.01$), especially in the infection group ($P < 0.01$; Table 2).

Table 2
Reoperation Procedures

Group	Procedure	n (%)
Infection	Optical PKP	4 (57.1)
	PKP + unplanned ICCE	1 (14.3)
	Therapeutic PKP	1 (14.3)
	IOL	1 (14.3)
	Total	7
Non-infection	Amniotic membrane transplant	3 (42.6)
	Anterior chamber washing out	1 (14.1)
	PKP + ECCE	1 (14.1)
	PVR	1 (14.1)
	RD	1 (14.1)
	Total	7

PKP, penetrating keratoplasty; ICCE, intracapsular cataract extraction; IOL, intraocular lens insertion; ECCE, extracapsular cataract extraction; PVR, proliferative vitreoretinopathy; RD, retinal detachment.

A total of 14 eyes required additional surgery (7 eyes in the infectious group and 7 eyes in the non-infectious group). Among participants of the infectious group, 4 eyes underwent optical PKP with fresh donor grafts, 1 eye underwent a double procedure (PKP with fresh donor graft and unplanned intracapsular cataract extraction), and optical cataract removal and intraocular lens implantation were performed in another eye. An emergency therapeutic PKP with a frozen donor graft for graft destruction due to herpetic ulcer and melting was performed in only 1 eye. Anatomical recovery among cases with required additional surgeries was achieved in 7 eyes (100%) in the infection group, and in the non-infection group, it was achieved in 5 eyes (71.4%) after reoperation (Table 3).

Table 3
Pre- and Post-Operative Visual Acuity

		Improvement, n (%)	Unchanged or decreased, n (%)	*P*
Infection	Infection	15	5	< 0.01[a]
	Non-infection	7	14	
	Total	22 (53.7)	19 (46.3)	
Anterior chamber	Deep□shallow	10	9	0.9[a]
	Elimination	12	10	
	Total	22 (53.7)	19 (46.3)	
Iris incarceration	+	4	6	0.26[b]
	-	18	13	
	Total	22 (53.7)	19 (46.3)	
Size of perforation	≥ 4 mm	13	9	0.27[a]
	< 4 mm	8	11	
	Total	21 (51.3)	20 (48.7)	
Donor size (penetrating keratoplasty cases)	≥ 8.5 mm	5	5	0.56[a]
	< 8.5 mm	11	7	
	Total	16 (57.2)	12 (42.8)	

[a]Chi-squared test; [b]Fisher's exact probability test

Visual acuity (VA) after the first transplantation did not significantly improve compared to preoperative VA values when comparing the infection and non-infection groups ($P = 0.31$). However, the final VA after reoperation was significantly improved in the infection group compared to the non-infection group ($P < 0.01$). In the infection group requiring reoperation, the VA improved in 5 of 7 eyes (71.4%), the VA did not change in 2 eyes (28.5%), and no case experienced a decreased VA. On the other hand, in the non-infection group requiring reoperation, the VA improved in 2 of 7 eyes (28.5%), the VA did not change in 1 eye (14.2%), and the VA decreased in 4 eyes (57.1%; Table 4).

Table 4
Anatomical Cure and Surgical Methods

Group	Procedure	Anatomical cure, n (%)	Failure, n (%)
Infection	PKP	14 (82.4)	3 (17.6)
	LKP	3 (100)	0 (0)
	Total	17 (85.0)	3 (15.0)
Non-infection	PKP	9 (82.0)	2 (18.0)
	LKP	4 (80.0)	1 (20.0)
	KEP	5 (100)	0 (0)
	Total	18 (85.8)	3 (14.2)

PKP, penetrating keratoplasty; LKP, lamellar keratoplasty; KEP, keratoepithelioplasty.

We also evaluated the depth of the anterior chamber, iris incarceration, size of the perforation, and donor size at the time of the perforation and analyzed the correlation of these parameters with the final VA improvement. However, no statistically significant relationship was found between these parameters and the final VA values (Table 4).

Anatomical recovery was no difference between in the infection group and the non-infection group (P = 0.64). A PKP was performed in 28 eyes (68.2%), LKP in 8 eyes (19.5%), and KEP in 5 eyes (12.2%). There were 20 eyes in the infection group (PKP, 17 eyes; LKP, 3 eyes) and 21 eyes in the non-infection group (PKP, 11 eyes; LKP, 5 eyes; and KEP, 5 eyes). Tectonic cure was achieved in 14 of 17 eyes (82.3%, PKP infection group), 3 of 3 eyes (100%, LKP infection group), 9 of 11 eyes (81.8%, PKP non-infection group), 4 of 5 eyes (80%, LKP non-infection group), and 5 of 5 eyes (100%, KEP non-infection group; Table 5).

Table 5
Anatomical Cure and Surgical Methods

Group	Procedure	Anatomical cure, n (%)	Failure, n (%)
Infection	PKP	14 (82.3)	3 (17.6)
	LKP	3 (100)	0 (0)
	Total	17 (85.0)	3 (15.0)
Non-infection	PKP	9 (81.8)	2 (18.0)
	LKP	4 (80.0)	1 (20.0)
	KEP	5 (100)	0 (0)
	Total	18 (85.7)	3 (14.2)

PKP, penetrating keratoplasty; LKP, lamellar keratoplasty; KEP, keratoepithelioplasty.

The major postoperative complications in all cases included disease recurrence (7 of 41 eyes [17.1%]; 4 eyes with a herpes infection, 2 eyes with Mooren's ulcer, and 1 eye with fungal keratitis) and phthisis (7 eyes [17.1%]). A persistent corneal epithelial defect was observed in 3 eyes (7.3%) requiring AMT. Secondary glaucoma was the main complication in previous reports,[9,22] but we experienced in our study population only 1 eye (1.8%) with ocular hypertension that did not respond to glaucoma eye drops and eventually required tube shunt surgery.

Discussion

In this study, the primary goal of sealing the corneal perforation was achieved in 28 eyes (68.3%) of the 41 eyes after the first operation, and in 34 eyes (82.9%) of 41 eyes on final observation. We used cryopreserved donor corneas for therapeutic keratoplasty (41 eyes, 100%). In Japan, donor organs including corneas are in short supply. Thus, ophthalmologists do not always have access to fresh donor organs when needed on an emergency basis. A previous report suggested that cryopreserved donor corneas have a high risk for recurrence of reperforation and infection.[4] According to their study, sometimes a second keratoplasty using fresh donor grafts is needed to recover corneal transparency.[4] However, in the report by Hanada et al. with 67% fresh donor corneas used in therapeutic corneal transplantation, the cure rate was 80%, which is not so different from that of our study, and there was also no difference in the rate of complications.[13]

If in bacterial or fungal keratitis the infected lesion was incompletely removed, reoccurrence of the infectious keratitis was sometimes observed. A previous report showed that it is necessary to remove the focus of infection by oversizing 0.5 mm to 1.0 mm.[23] Yokogawa et al.[23] reported corneal transplantation for corneal perforation by bacterial and fungal keratitis performed with small grafts, however, a second large graft was eventually required for all cases. Li et al. reported therapeutic corneal transplantation in 116 cases of fungal keratitis and found that graft rejection and secondary glaucoma were more likely to occur in large grafts.[11] Other reports described that large grafts are associated with poor postoperative prognosis and complications.[24–26] On the other hand, there are reports that a large graft size does not influence the postoperative prognosis.[10,27] Considering these study findings, publications regarding the effects of the graft size on anatomical recovery rate and complications were gathered only for cases of infectious keratitis such as bacterial, fungal, and acanthamoeba keratitis, and they were similar to the results in the present study. The group with grafts 8.5 mm or larger was less controlled with appropriate treatment than that with grafts smaller than 8.5 mm. Among the cases using 8.5 mm or larger grafts in the infection group, all 5 eyes with bacterial or fungal keratitis did not achieve the sealing of the corneal perforation. Koçluk et al. reported 25 cases of bacterial and fungal keratitis divided into two groups according to the time until the surgical intervention (> 15 days vs ≤ 15 days). As a result, there were more large grafts (diameter ≥ 9.5 mm) in the group with the longer time until intervention.[24] Our findings may demonstrate some important points when sealing corneal perforations in cases of bacterial and fungal keratitis; primarily that infected lesion should be completely removed and secondly that therapeutic keratoplasty should be performed before the focus of infection reaches the vicinity of the limbus.

Among the cases with secondary surgery for infections, both the proportion of optical indications and the cure rate were high. In non-infectious cases, there was a higher incidence of tectonic surgery. After the second transplantation, the cure rate was 100% in infectious cases, of which the visual acuity improved in 71.4%, and there were no cases with decreased visual acuity. This shows that a second optical operation is good option for visual acuity improvement after the infection is under control.

Penetrating keratoplasty is the most common surgical procedure in both infectious and non-infectious diseases with corneal perforations. Recently, some authors reported that LKP and deep anterior lamellar keratoplasty (DALK) for corneal perforation is safer in terms of endothelial rejection.[10,19,21,27–33] Other studies have noted that Descemet stripping automated endothelial keratoplasty (DSAEK) is effective for perforation cases.[33] Nevertheless, a disadvantage of LKP is the possibility that the infected lesion may not be completely removed and interface opacity may cause blurred vision.[21] Shimmura et al. proposed that good visual acuity was achieved by DALK performed on therapeutic transplantation and that it is necessary to select a surgical method with the depth of the infected lesion in consideration.[12] In the current study, LKP was chosen for 2 cases of herpetic and 1 case of bacterial keratitis. Although one herpetic case required optical transplantation, all cases were cured.

In our study, herpetic keratitis was the most common disease in the infection group, whereas Mooren's ulcer was most frequent in the non-infection group. The original diseases recurred in 4 of 11 eyes in herpetic keratitis (36.7%) and 2 of 5 eyes in Mooren's ulcer (40%) after the first therapeutic keratoplasty. This is a similar recurrence rate compared to previous studies reporting the recurrence in herpetic keratitis and Mooren's ulcer.[23,34,35] Cyclosporine,[36] tacrolimus,[37] and oral immunosuppressants[34,38] reportedly suppress Mooren's ulcer after surgery. Some studies mention that LKP, but not AMT, is effective in Mooren's ulcer.[3,36] In our study, KEP was performed in all cases of Mooren's ulcer using cryopreserved donor corneas. KEP was reported by Kinoshita et al. as the preferred surgical treatment for perforations in Mooren's ulcers.[24] We additionally excised the conjunctiva with a depth of 2–3 mm along the corneal limbs and the corneal tissue around the ulcer. We also removed the immune cells at the bottom of the ulcer (Brown).[39] KEP with conjunctival resection was performed in 3 of 5 eyes with Mooren's ulcers and showed no recurrence. However, the other 2 eyes, in which conjunctival resection was not preformed, resulted in recurrence after keratoplasty. We performed conjunctival resection in both cases and consequently controlled the inflammation with surgical success. KEP in addition to conjunctival resection may suppress inflammation by maintaining the space between the cornea and immune cells of the conjunctiva.

Ti et al. reported that 11 eyes (11.9%) in 92 fungal keratitis cases perforated. Perforation risk factors of fungal keratitis included misdiagnosis, extensive infectious area,[11] usage of topical steroids,[10] and delayed treatment.[40–42] In our study, when the cornea perforated in cases of bacterial and fungal keratitis, we washed out the anterior chamber during the operation.[22,43] Furthermore, topical steroids were not used for fungal keratitis for at least 2 weeks postoperatively and only if fungal infiltration was not observed.[38,44] Thus, two cases of fungal keratitis achieved anatomical recovery with frozen donor tissue.

In one case, the fungal keratitis recurred after therapeutic penetrating surgery but was finally controlled with conservative eye drop treatment. However, one case of fungal keratitis used topical steroids after misdiagnosis as herpes keratitis and had to undergo therapeutic transplantation due to perforation. This case eventually ended up with phthisis bulbus. In the treatment of fungal keratitis, misdiagnosis and early use of steroids may result in detrimental consequences.

The main complications after therapeutic keratoplasty were recurrence of the original disease (7 eyes; 17.1%) and phthisis bulbi (7 eyes; 17.1%). In a previous report, secondary glaucoma and corneal epithelial defect were the main complications.[9,27] Iris anterior synechiae preoperatively may induce secondary glaucomas.[45] If conservative treatment is not effective and the anterior chamber is not reformed, irreversible iris anterior synechiae may occur. Therefore, if iris anterior synechiae did not return to the original position for more than 2 weeks, we intervened surgically to separate the synechiae to reconstruct the anterior chamber. When in bacterial and fungal keratitis the graft margin was close to the limbus, postoperative inflammation causes trabeculitis and glaucoma.[23] In our study, all cases of large grafts resulted in phthisis bulbi, perhaps because the ciliary body function was weakened.

A limitation of the current study is the low number of cases. However, our results show that it is necessary to correctly diagnose the original cause of the disease resulting in corneal perforation and to carefully determine the time of surgical treatment.

Conclusions

Therapeutic keratoplasty using cryopreserved corneas for corneal perforation is good option for achieving an anatomical cure. As the graft size affects the prognosis, it is important to perform surgical treatment before the infected lesion reaches the limbus, especially in infectious keratitis. We found that a good cure rate was achieved regardless of using cryopreserved donor corneas in all cases. It is necessary to diagnose the cause of the disease at an early stage and provide appropriate conventional and surgical treatments.

List Of Abbreviations

AMT; amniotic membrane transplantation, PKP; penetrating keratoplasty, LKP; lamellar keratoplasty, KEP; keratoepithelioplasty, VA; visual acuity, DALK; deep anterior lamellar keratoplasty, DSAEK; Descemet stripping automated endothelial keratoplasty

Declarations

Ethics approval and consent to participate

The Institutional Review Board of Keio University, Tokyo, Japan approved the protocol (#2017-0219), and all participants undergoing surgery provided written informed consent. The research methods adhered to the tenets of the Declaration of Helsinki.

Consent for publication

Parental consent for publication was obtained for this report.

Availability of data and materials

The datasets used and analyzed during the current study available from the corresponding author on reasonable request.

Competing Interests

Yuichi Uchino and Miki Mizuno declare that they have no competing interests.

Shigeto Shimmura Research funding received from Santen Pharmaceutical Co., Rhoto Pharmaceuticals CO, and Sumitomo Dainippon Pharma Co.

Kazuo Tsubota: Consultant and research funding received from Santen Pharmaceutical Co., Ltd., research funding received from Kowa Company, and holds the patent rights for the method and the apparatus used for the measurement of the functional visual acuity (US patent no: 7470026). Founder of Tsubo Labo, Tokyo, Japan.

Funding

There is no sponsorship of funding arrangements relating to our research.

Authors' contributions

MM had contributed to the conception and design of the study, analysis and interpretation of data, and drafted the article. YU and SS had made contributions to the conception of the study and critical revision of the article for important intellectual content. KT has made contributions to the conception of the work.

Acknowledgements

Not applicable.

References

1. Solomon A, Meller D, Prabhasawatet P. al. Amniotic membrane grafts for nontraumatic corneal perforations, descemetoceles, and deep ulcers. Ophthalmology. 2002;109:694–703.
2. Jhanji V, Young AL, Mehta JS, et al. Management of corneal perforation. Surv Ophthalmol. 2011;56:522–38.
3. Vilaplana F, Temprano J, Riquelme JL, et al. Mooren's ulcer: 30 years of follow-up. Arch Soc Esp Oftalmol. 2016;91:337–40.
4. Ikema K, Matsumoto K, Sasaki K, et al. Therapeutic keratoplasty for non-traumatic corneal perforation. Journal of the Eye. 2004;21:1233–6.

5. Kobayashi A, Yokogawa H, Sugiyama K. Management of a small paracentral corneal perforation using iatrogenic iris incarceration and tissue adhesive. Case Rep Ophthalmol. 2012;3:226–9.
6. Hanada K, Shimazaki J, Shimmura S, et al. Multilayered amniotic membrane transplantation for severe ulceration of the cornea and sclera. Am J Ophthalmol. 2001;131:324–31.
7. Rodríguez-Ares MT, Touriño R, López-Valladares MJ, et al. Multilayer amniotic membrane transplantation in the treatment of corneal perforations. Cornea. 2004;23:577–83.
8. Prabhasawat P, Tesavibul N, Komolsuradej W. Single and multilayer amniotic membrane transplantation for persistent corneal epithelial defect with and without stromal thinning and perforation. Br J Ophthalmol. 2001;85:1455–63.
9. Bouazza M, Bensemlali AA, Elbelhadji M, et al. Non-traumatic corneal perforations: Therapeutic modalities. J Fr Ophtalmol. 2015;38:395–402.
10. Ti SE, Scott JA, Janardhanan P, et al. Therapeutic keratoplasty for advanced suppurative keratitis. Am J Ophthalmol. 2007;143:755–62.
11. Li C, Zhao GQ, Che CY, et al. Effect of corneal graft diameter on therapeutic penetrating keratoplasty for fungal keratitis. Int J Ophthalmol. 2012;5:698–703.
12. Shimmura S, Shimazaki J, Tsubota K. Therapeutic deep lamellar keratoplasty for cornea perforation. Am J Ophthalmol. 2003;135:896–7.
13. Hanada K, Igarashi S, Muramatsu O, et al. Therapeutic keratoplasty for corneal perforation: clinical results and complications. Cornea. 2008;27:156–60.
14. Nobe JR, Moura BT, Robin JB, et al. Results of penetrating keratoplasty for the treatment of corneal perforations. Arch Ophthalmol. 1990;108:939–41.
15. Portnoy SL, Insler MS, Kaufman HE. Surgical management of corneal ulceration and perforation. Surv Ophthalmol. 1989;34:47–58.
16. Loya-Garcia D, Serna-Ojeda JC, Pedro-Aguilar L, et al. Non-traumatic corneal perforations: aetiology, treatment and outcomes. Br J Ophthalmol. 2017;101:634–9.
17. Dohlman CH, Boruchoff SA, Sullivan GL. A technique for the repair of perforated corneal ulcers. Arch Ophthalmol. 1967;77:519–25.
18. Hill JC. Use of penetrating keratoplasty in acute bacterial keratitis. Br J Ophthalmol. 1986;70:502–6.
19. Nurözler AB, Salvarli S, Budak K, et al. Results of therapeutic penetrating keratoplasty. Jpn J Ophthalmol. 2004;48:368–71.
20. Bernauer W, Ficker LA, Watson PG, et al. The management of corneal perforations associated with rheumatoid arthritis. An analysis of 32 eyes. Ophthalmology. 1995;102:1325–37.
21. Kinoshita S, Ohashi Y, Ohji M, et al. Long-term results of keratoepithelioplasty in Mooren's ulcer. Ophthalmology. 1991;98:438–45.
22. Xie L, Zhai H, Dong X, et al. Primary diseases of corneal perforation in Shandong Province, China: a 10-year retrospective study. Am J Ophthalmol. 2008;145:662–6.

23. Yokogawa H, Kobayashi A, Yamazaki N, et al. Surgical therapies for corneal perforations: 10 years of cases in a tertiary referral hospital. Clin Ophthalmol. 2014;8:2165–70.
24. Koçluk Y, Sukgen EA. Results of therapeutic penetrating keratoplasty for bacterial and fungal keratitis. Int Ophthalmol. 2017;37:1085–93.
25. Cristol SM, Alfonso EC, Guildford JH, et al. Results of large penetrating keratoplasty in microbial keratitis. Cornea. 1996;15:571–6.
26. Hirst LW, Lee GA. Corneoscleral transplantation for end stage corneal disease. Br J Ophthalmol. 1998;82:1276–9.
27. Bersudsky V, Blum-Hareuveni T, Rehany U, et al. The profile of repeated corneal transplantation. Ophthalmology. 2001;108:461–9.
28. Krysik K, Dobrowolski D, Lyssek-Boron A, et al. Differences in surgical management of corneal perforations, measured over six years. J Ophthalmol. 2017;2017:1582532.
29. Anshu A, Parthasarathy A, Mehta JS, et al. Outcomes of therapeutic deep lamellar keratoplasty and penetrating keratoplasty for advanced infectious keratitis: a comparative study. Ophthalmology. 2009;116:615–23.
30. Ang M, Mehta JS, Arundhati A, et al. Anterior lamellar keratoplasty over penetrating keratoplasty for optical, therapeutic, and tectonic indications: a case series. Am J Ophthalmol. 2009;147:697–702.e2.
31. Park JC, Habib NE. Tectonic lamellar keratoplasty: simplified management of corneal perforations with an automated microkeratome. Can J Ophthalmol. 2015;50:80–4.
32. Watson SL, Tuft SJ, Dart JK. Patterns of rejection after deep lamellar keratoplasty. Ophthalmology. 2006;113:556–60.
33. Graue-Hernandez EO, Zuñiga-Gonzalez I, Hernandez-Camarena JC, et al. Tectonic DSAEK for the management of impending corneal perforation. *Case Rep Ophthalmol Med.* 2012:2012:916528.
34. Bauer D, Schmitz A, Van Rooijen N, et al. Conjunctival macrophage-mediated influence of the local and systemic immune response after corneal herpes simplex virus-1 infection. Immunology. 2002;107:118–28.
35. Zegans ME, Srinivasan M, McHugh T, et al. Mooren ulcer in South India: serology and clinical risk factors. Am J Ophthalmol. 1999;128:205–10.
36. Tandon R, Chawla B, Verma K, et al. Outcome of treatment of mooren ulcer with topical cyclosporine A 2%. Cornea. 2008;27:859–61.
37. Lee YJ, Kim SW, Seo KY. Application for tacrolimus ointment in treating refractory inflammatory ocular surface diseases. Am J Ophthalmol. 2013;155:804–13.
38. Mandell KJ, Colby KA. Penetrating keratoplasty for invasive fungal keratitis resulting from a thorn injury involving phomopsis species. Cornea. 2009;28:1167–9.
39. Cordero-Coma M, Benito MF, Fuertes CL, et al. Adalimumab for Mooren's ulcer. Ophthalmology. 2009;116:1589.

40. Prajna NV, Krishnan T, Rajaramanet R. al. Predictors of corneal perforation or need for therapeutic keratoplasty in severe fungal keratitis: A secondary analysis of the Mycotic Ulcer Treatment Trial II. JAMA Ophthalmol. 2017;135:987–91.
41. Miedziak AI, Miller MR, Rapuano CJ, et al. Risk factors in microbial keratitis leading to penetrating keratoplasty. Ophthalmology. 1999;106:1166–70.
42. Vemuganti GK, Garg P, Gopinathanet U. al. Evaluation of agent and host factors in progression of mycotic keratitis: A histologic and microbiologic study of 167 corneal buttons. Ophthalmology. 2002;109:1538–46.
43. Yao YF, Zhang YM, Zhou P, et al. Therapeutic penetrating keratoplasty in severe fungal keratitis using cryopreserved donor corneas. Br J Ophthalmol. 2003;87:543–7.
44. Gupta G, Feder RS, Lyon AT. Fungal keratitis with intracameral extension following penetrating keratoplasty. Cornea. 2009;28:930–2.
45. Dada T, Aggarwal A, Minudath KB, et al. Post-penetrating keratoplasty glaucoma. Indian J Ophthalmol. 2008;56:269–77.

Figures

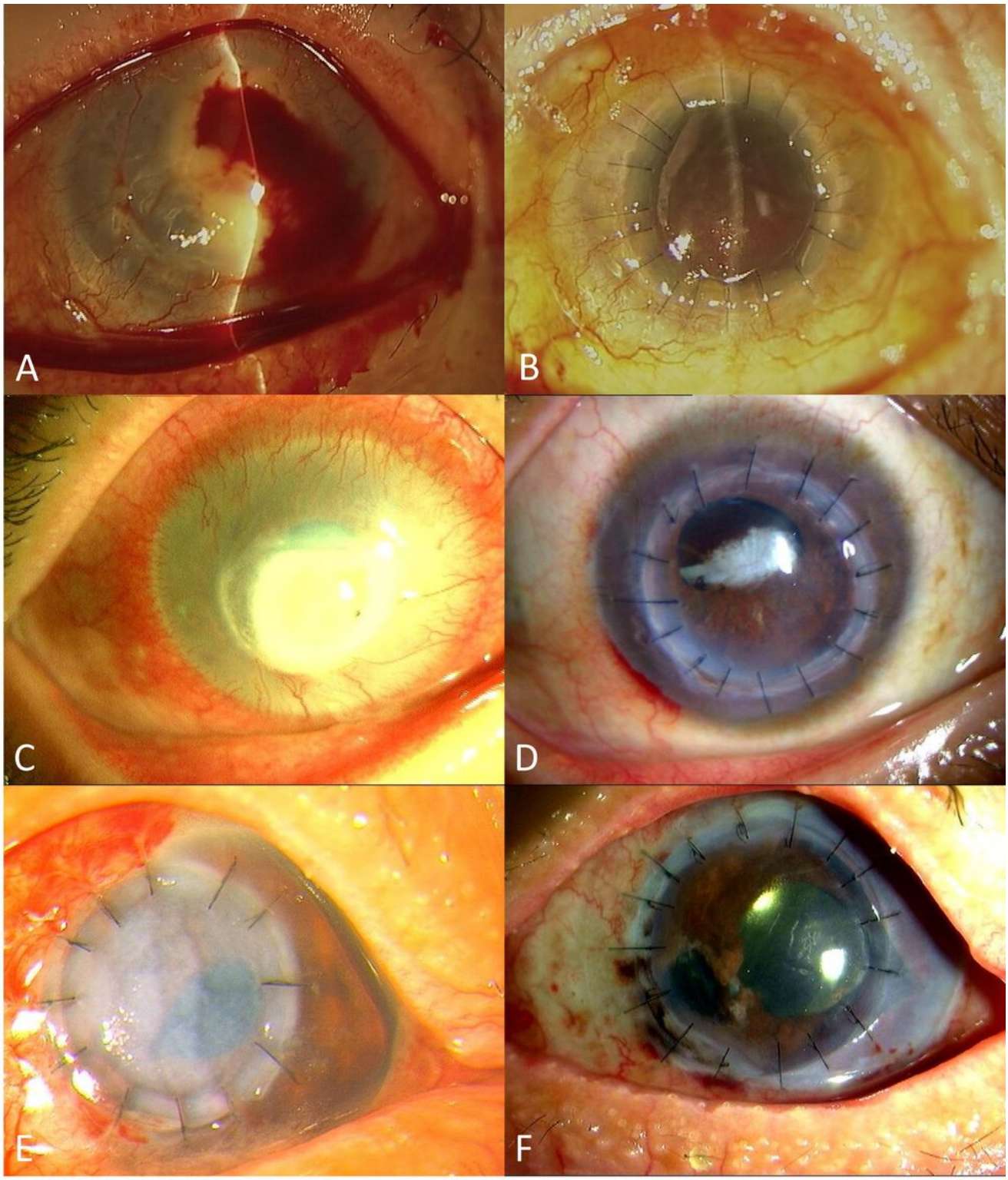

Figure 1

Surgical procedures in corneal perforation cases. A) A case of bacterial keratitis with corneal perforation and hemorrhage. B) Full-size therapeutic penetrating keratoplasty in bacterial keratitis. C), D) Therapeutic PKP in fungal keratitis. E), F) Mooren's ulcer with secondary bacterial keratitis and perforation treated by therapeutic PKP. Optical PKP was performed after the inflammation had been controlled. PKP, penetrating keratoplasty.