

Anterior column realignment via a minimally invasive hybrid approach in adult spinal deformity surgery: an analysis of radiographic and clinical outcomes

Da Peng Feng

The Second Affiliated Hospital of Dalian Medical University

Ming Quan Liu

Xi'an No.3 Hospital

Wei Zhang

The Second Affiliated Hospital of Dalian Medical University

Jia Qi Wang

The Second Affiliated Hospital of Dalian Medical University

Zheng Wei Li (✉ liumingquan@tom.com)

The Second Affiliated Hospital of Dalian Medical University

Research Article

Keywords: adult spinal deformity, Oblique lumbar interbody fusion, Anterior lumbar interbody fusion, Anterior column realignment

Posted Date: April 19th, 2023

DOI: <https://doi.org/10.21203/rs.3.rs-2798421/v1>

License:   This work is licensed under a Creative Commons Attribution 4.0 International License.

[Read Full License](#)

Additional Declarations: No competing interests reported.

Version of Record: A version of this preprint was published at BMC Musculoskeletal Disorders on December 19th, 2023. See the published version at <https://doi.org/10.1186/s12891-023-07106-1>.

Abstract

Background Osteotomy and Orthopedics is the leading way to treat adult spinal deformity (ASD), but there are many surgical complications. meanwhile, oblique lumbar interbody fusion(OLIF) and anterior lumbar interbody fusion (ALIF) have becoming an increasingly popular surgical method of spinal surgery. Thus, the purpose of this study is to explore the feasibility and safety of minimally invasive anterior column realignment(ACR) in the treatment of adult spinal deformities.

Methods:A total of 64 patients were included in the study. All patients received OLIF and/or ALIF and ACR, combined with Percutaneous pedicle screw fixation(PPSF). The surgical effect was evaluated by the operation time, bleeding volume, intervertebral space angle (IVA), lumbar lordosis (LL), the sagittal vertical axis (SVA), visual analog pain score (VAS), Japanese orthopedic association scores (JOA) and complications.

Results: All patients completed 173 fusion segments; For 155 segments of ACR surgery, the average sagittal correction angle of each ACR segment was $15.3^{\circ} \pm 5.8^{\circ}$. The mean preoperative and postoperative lumbar lordosis were, respectively, $-16.7^{\circ} \pm 6.4^{\circ}$ and $-48.6^{\circ} \pm 10.7^{\circ}$ ($p < 0.001$). JOA, VAS and other scores were significantly improved compared with those before operation.

Conclusion: Anterior column realignment via a minimally invasive hybrid approach for adult spinal deformity can achieve good clinical outcome and deformity correction.

Background

Adult spinal deformity (ASD) is a serious and complex group of spinal disorders that not only affects the physical appearance and psychological state of the patient, but is often associated with neurological impairment. The treatment of adult spinal deformities focuses on correcting and maintaining spinal balance in three dimensions, as well as stopping the progression of the deformity. Conservative treatment only changes part of a patient's clinical symptoms and does not radically alter the essence of the deformity. For ASD patients, surgery is the most appropriate way to correct spinal deformities effectively. The conventional surgical procedures for the treatment of adult spinal deformities are mostly osteotomies and orthopedic procedures, including Smith-Petersen osteotomy (SPO), pedicle subtraction osteotomy (PSO), and vertebral column resection (VCR). Although osteotomies are widely performed in clinical practice and their effectiveness has been demonstrated by clinical studies[1]. However, osteotomy has many disadvantages, such as long operation time, high risk of nerve damage, and high blood loss[2–5]. The percentage of postoperative complications increases significantly with the extent of the osteotomy, with studies showing a 28% complication rate for SPO and a 61% complication rate for VCR[6].

Recently, with the development of minimally invasive surgical techniques, numerous new surgical techniques have been employed in the treatment of spinal deformities in adults. Oblique lateral interbody fusion (OLIF) and anterior interbody fusion (ALIF) are currently the most popular procedures in spinal

surgery[7]. The two procedures can restore the physiological lordosis of the patient's lumbar spine, return the height of the intervertebral space and have low surgical complications[8, 9].

For severe spinal deformities, a single minimally invasive hybrid approach is extremely difficult to perform due to the obstruction of the anterior vertebral ligaments and the bony flank, resulting in unsatisfactory orthopedic consequences and even increasing the possibility of endplate injury. To further correct the sagittal imbalance in adult patients with spinal deformities, our team has combined an anterior spinal column reconstruction technique based on a minimally invasive hybrid approach.

To the best of our knowledge, ACR via a minimally invasive hybrid approach has not been previously explored in the literature[10, 11]. In this study, we aimed to characterize the radiographic and clinical outcomes of ACR via a minimally invasive hybrid approach in patients with ASD.

Methods

The clinical data of ASD patients who underwent ACR via a minimally invasive hybrid approach in the Second Affiliated Hospital of Dalian Medical University from January 2018 to June 2021 were retrospectively collected and analyzed. This study was approved by the Ethics Review Committee of the Second Affiliated Hospital of Dalian Medical University and obtained the unique identification number of research registration. This study met guidelines of the responsible local governing agency and complied with the principles of the Declaration of Helsinki. Each patient signed a written informed consent form.

Inclusion and exclusion criteria

The inclusion criteria include: Patients with clinically diagnosed adult spinal deformity. Radiographic assessment: SVA>5 cm, PI-LL mismatch>10 °, PT>25 °, TK>60 °, Coronal Cobb angle>20°; ACR via a minimally invasive hybrid approach was performed.

The exclusion criteria include: Lack of information including demographics, surgical data, radiographic data. Adolescent idiopathic scoliosis patients who developed later in adulthood. Trauma, inflammation, tumor or neuromuscular origin; Severely rigid spinal sagittal imbalance (SVA>20cm or PI-LL>40 °); with previous lumbar surgery.

A total of 64 patients were enrolled after applying the inclusion and exclusion criteria.

Data collection

The patient's clinical and radiological information is obtained by accessing the electronic record system. The standard demographics, including age, sex. Several variables pertinent to the operative data were recorded for each patient, including operative time, estimated blood loss (EBL), method for interbody fusion. The imaging data mainly includes: pelvic incidence (PI), lumbar lordosis (LL), Intervertebral space angle of the surgical segment (IVA) sagittal vertical axis (SVA). Intraoperative or postoperative complications were recorded.

At 1, 3, and 6 months postoperative follow-up, frontal and lateral radiographs of the lumbar spine were obtained to measure IVA, lumbar lordosis, and sagittal vertebral axis respectively. CT examinations were performed at 3 months postoperatively to assess fusion and internal fixation stability. Pre-operative and post-operative follow-ups were performed using the visual analog scale (VAS) and lumbar JOA score to assess the clinical outcome.

Surgical technique

The anterior longitudinal ligament ALL can enhance the stability of the spine and as a barrier to prevent anterior dislodgement of the interbody cage. However, concerning sagittal deformity correction, ALL is also the main obstacle to against anterior column lengthening and deformity correction. Therefore, ACR technology includes the release of ALL and lateral ligament complex, and the placement and fixation of a hyperlordotic cage to correct focal kyphosis.

In the pre-operative stage of the procedure, the patient was placed in the standard lateral position in the same manner as for a lateral lumbar interbody fusion. Use the retroperitoneal approach to access the intervertebral disc space, and then the retractor is placed to expose the intervertebral disc in front of the posterior retractor blade. Gentle dissection is performed to identify and separate the plane between ALL and the anterior structure. Two-thirds of all anterior intervertebral discs must be removed to facilitate ALL release. Release the anterior longitudinal ligament and anterior vascular structure, a narrow abdominal retractor is inserted between them, and then release ALL with a long-handled scalpel. Use a reamer to break through and disconnect the contralateral remaining annulus. After that, sequential implant trialing and insertion are then performed using standard techniques.

Considering that ALL release will make the fusion cage move forward, it is very important to Internal fixation the implants to the vertebral body with 1 or 2 screws to reduce the risk of implant movement. When posterior pressure release and additional lordosis are generated, fixing the cage to only 1 vertebral body is recommended. For the high iliac crest, L5/S1 segment cannot be performed at the same incision. Usually, the anterior approach is via the abdominal or retroperitoneal approach. Posterior routine percutaneous screw fixation, and screw compression if necessary to obtain additional lordosis correction.

Perioperative management

On the first or second day after the operation, lumbar spine x-rays was repeated with the duration postoperative activity determined by the patient's status. Most patients were able to walk after surgery day 1-3, protected by a lumbar brace. Methylprednisolone, omeprazole, parecoxib, and rivaroxaban were used for conventional treatment 3 days after operation.

Data analysis

The SPSS 25.0 software was used to analyze the data. The statistical results were described, with continuous variables shown as means and standard deviations, and classification shown as a

percentage. To compare the differences between pre-and post-operative related parameters, the Paired samples t-test has been used. $P < 0.05$ was regarded as statistically significant.

Results

Analysis of surgical details

We performed ACR via a minimally invasive combination approach for ASD, ALIF-ACR for L5-S1 segment and OLIF-ACR for L2-L5, effectively combining the advantages of both approaches with significant results. All 64 patients in this group completed ACR via a minimally, including 5 cases of OLIF-ACR alone and 3 cases of ALIF-ACR alone; In 56 cases of ALIF-ACR combined with OLIF-ACR, all patients completed 173 ALIF or OLIF fusion segments; A total of 155 segments of ACR were completed, including 96 segments of OLIF-ACR and 59 segments of ALIF-ACR.

Table 1 summarizes the bleeding and surgical time during different surgical approaches. The operation time of ALIF-ACR was 40-80 min, with an average of 50.4 ± 22.1 min; The intraoperative bleeding volume was 30-80 ml, with an average of 50.2 ± 23.6 ml. The operation time of single-segment OLIF-ACR was 40-90 min, with an average of 66.2 ± 19.4 min; The intraoperative bleeding volume was 50-100 ml, with an average of 70.2 ± 31.6 ml. The operation time of two-stage OLIF-ACR was 70-140 min, with an average of 96.2 ± 27.4 min; The intraoperative bleeding volume was 50-140 ml, with an average of 87.2 ± 38.6 ml; The operation time of three-segment OLIF-ACR was 80-140 min, with an average of 106.2 ± 37.4 min; The intraoperative bleeding volume was 80-240 ml, with an average of (117.2 ± 36.7) ml. percutaneous pedicle screw fixation with an average of (4.6 ± 1.66) nail; The operation time of simple nail placement was 50-140 min, with an average of (78.9 ± 52.4) min; The intraoperative bleeding volume was 80-210ml, with an average of (130.6 ± 98.2) ml. All patients did not receive blood transfusions.

Analysis of Radiographic and clinical results

Table 2 summarizes the radiological evaluations of spinopelvic parameters preand postoperatively. There were significant differences in LL, IVA(ALIF-IVA; OLIF-IVA), SVA between before surgery and at the final observation. Among the 59 patients followed up, 55 underwent CT examination of the lumbar spine at 3 months postoperatively. In 53 of these cases, continuous trabecular formation between the upper and lower endplates was seen, achieving a fusion with a 96.36% fusion rate at 3 months postoperatively. The remaining 2 cases achieved bony fusion at 6 months postoperatively.

As shown in Table 3, 59 patients were followed up for 6-33 months with a mean of 17.7 ± 7.8 months. The mean preoperative VAS score was 6.8 ± 1.6 , the mean postoperative score was 2.1 ± 0.7 and the mean score at the last follow-up s was 1.8 ± 0.8 , achieving a 69.1% improvement rate before and after surgery, with a statistically significant difference ($p < 0.01$). The mean preoperative lumbar JOA score was 7.8 ± 2.9 , the mean postoperative score was 19.1 ± 2.7 and the mean at the last follow-up s was 22 ± 3.9 , achieving an improvement rate of 59.2% before and after surgery, a statistically significant difference ($P < 0.01$).

Complications

In our study, a total of 19 patients developed one or more complications, representing 29.69% of the patients. According to the Glassman classification criteria[12], major postoperative complications include nerve damage, vascular damage, and organ damage, and secondary complications included sensory impairment, motor impairment, hematoma, and incisional infection.

4 patients developed major complications after surgery, accounting for 6.25% of the patients. 2 patients presented with lower limb muscle weakness after surgery, one was a 58-year-old female who underwent L4-5 segment OLIF-ACR and developed right ankle muscle weakness after surgery, (preoperative muscle strength grade 4, postoperative muscle strength grade 2) muscle strength recovered to grade 4 after 3 months of rehabilitation; The other case was a 49-year-old male who underwent L5-S1 segmental ALIF-ACR and had lower extremity muscle weakness (preoperative grade 5, postoperative grade 1) which recovered to grade 3 after 9 months of rehabilitation; two patients had vascular injuries, one underwent L4-5 segmental OLIF-ACR with intraoperative damage to the segmental artery and one underwent L4-5 OLIF-ACR with an intraoperative partial tear of the common iliac artery which was repaired with silk sutures assisted by a vascular surgeon Repair.

There were 15 cases of secondary complications, accounting for 23.43% of the patients. 14 patients developed postoperative numbness in the inguinal region, anterior and lateral thighs, of which 11 recovered within 1 month after surgery and 3 gradually recovered between 3 and 6 months after surgery. 8 patients experienced left-sided hip flexion weakness, all of which recovered within 1 month after surgery, which was considered to be a side effect related to intraoperative pulling of the psoas major muscle and incision. 11 patients developed temporary abdominal pain and bloating all of them recovered within 1 week after surgery.

Case Presentation

A 58-year-old woman with degenerative spinal deformities was indicated for anterior column reconstruction via a minimally invasive hybrid approach(Fig. 1). Figure 1a and Fig. 1b are full-standing X-rays before operation. Preoperative SVA = 46mm, PI = 60.3 °, LL=-17.4 °, Cobb (T12-L3) = 22.8, | PI-LL |=42.9 °. IVA(L2-3 = 5.8°;L3-4 = 0° L4 - 5 = - 1.2° L5-S1 = 6.7°) Patients accepted L2-3 OLIF; L3-L5 OLIF-ACR L5-S1 ALIF-ACR. Figure 1c, and Fig. 1d are full-standing X-rays after the operation. Postoperative SVA = 4mm, LL=-60.4 °, Cobb (T12-L3) = 8.7 °. IVA L2-3 = 7.2° L3-4 = 14.1° L4-5 = 14.9° L5-S1 = 18.1°

Discussion

Adult spinal deformity is a continuously progressive three-dimensional spinal deformity[13]. With advancing age, there is a loss of intervertebral space height and asymmetric degeneration of the bilateral synovial joints, which in turn leads to scoliosis deformity. The loss of anterior convexity of the lumbar spine as the disease progresses results in a forward shift of the patient's trunk center of gravity and

compensatory pelvic posterior rotation to maintain overall trunk balance, leaving the muscles of the low back in a state of chronic fatigue, resulting in intractable lower back pain and functional impairment[14].

The restoration of sagittal balance and spinopelvic balance is therefore essential in the treatment of adult spinal deformities[15]. In patients with sagittal imbalance, traditional treatment modalities such as Smith-Petersen osteotomy or PSO osteotomy are effective in restoring sagittal balance, but osteotomy is prone to a variety of complications such as excessive blood loss, neurological deficits and pseudoarthrosis[16]. Meanwhile, degenerative disease is often combined with spinal stenosis, The objective is to restore sagittal and coronal equilibrium while simultaneously decompressing the spinal canal and minimizing surgical complications[17].

In recent years, minimally invasive surgery has developed into an alternative method to avoid the complications of traditional open surgery, which can effectively reduce the incidence of complications related to the surgical approach and accelerate postoperative rehabilitation, and has become the development direction of surgery[18]. ACR is a new alternative method to treat ASD. ACR technology includes lumbar discectomy, anterior longitudinal ligament (ALL) disconnection, and wedge-shaped interbody fusion cage placement. If necessary, percutaneous or open technology is used for posterior release and fixation to complete lumbar lordosis reconstruction[19, 20]. A systematic review by Cheung ZB[21], showed that at each ACR level, the increased range of focal segmental lordosis was 1-34 °, and the average improvement range of LL was 12.7-39 °. In our study, the average sagittal correction angle of each ACR segment was 15.3 °, lumbar lordosis increased by 31.9 °, and SVA improved from 65.1 mm to 29.5 mm. All imaging parameters were significantly improved, which was close to Cheung ZB.

ACR, as a minimally invasive alternative to osteotomy, achieved similar radiographic results as PSO and with significantly less estimated blood loss[22]. However, due to the release of anterior longitudinal ligament, there is a risk of injury to the autonomic nerve plexus, visceral organs or large vessels. Although nerve injury may occur at any level, the femoral nerve injury rate is highest at the L4/5 level. It is important to distinguish between true motor weakness distributed along the femoral nerve and pain limiting weakness caused by hip flexion. The reported range of true motor weakness is 3.4-23.7%, the incidence of sensory abnormalities is 0.7-30%, and the reported range of numbness is 8.3-42.4%[23-25]. The commonly affected sensory nerves are the reproductive femoral nerve, the lateral femoral cutaneous nerve and the anterior femoral cutaneous nerve. Most motor and sensory disorders are temporary and can be restored, with a recovery of 50% in 90 days and 90% in 1 year[26]. In this study, the incidence of complications was 29.69%, but most of them were secondary complications such as transient muscle weakness and abdominal distension (23.43%). Except for one case where muscle strength did not fully recover, the rest recovered within six months and no serious complications occurred

Anterior approach interbody fusion is considered to be an effective treatment for degenerative disc disease (with or without neurological dysfunction) and lumbar spondylolisthesis[27]. but OLIF and ALIF, as an indirect decompression technique, do not directly remove the posterior bony ligaments and hypertrophic ligaments, and decompression is not as radical as posterior laminectomy decompression.

However, a retrospective study of lateral approach lumbar fusion has recently shown that additional posterior decompression is still clinically effective in patients with reduced stenosis but still with calf pain and a positive straight leg raise test or femoral nerve stretch test after lateral approach lumbar fusion[28]. Therefore, in patients with a degenerative disease, We believe that posterior decompression is necessary in cases of lumbar stenosis of grade D in the Schizas[29] classification, lumbar spondylolisthesis of degree II or greater and prolapsed lumbar disc herniation where effective disc removal is not possible anteriorly or laterally.

Conclusions

Our study confirms a minimally invasive hybrid access-based ACR procedure with satisfactory clinical outcomes. Despite complications such as vascular and anterior plexus injuries, the ACR technique has significant advantages in restoring local intervertebral space angulation and correcting the overall sagittal balance. It also has the advantages of minimal muscle damage, low risk of nerve injury, low bleeding, and rapid post-operative recovery. We are confident that the ACR via a minimally invasive hybrid approach is a safe and effective strategy.

Abbreviations

ASD:Adult spinal deformity; ACR:Anterior column realignment; SPO:Smith-Petersen osteotomy; PSO:Pedicle subtraction osteotomy; VCR:Vertebral column resection; OLIF:Oblique lumbar interbody fusion; ALIF:Anterior lumbar interbody fusion; PI:Pelvic incidence; LL:Lumbar lordosis; IVA:Intervertebral space angle of the surgical segment SVA:Sagittal vertical axis ;VAS:Visual analog scale; ALL:Anterior longitudinal ligament; PPSF:Percutaneous pedicle screw fixation

Declarations

Ethics approval and consent to participate

This study was approved by the Ethics Review Committee of the Second Affiliated Hospital of Dalian Medical University and obtained the unique identification number of research registration . Each patient signed a written informed consent form. In this study,

all methods were performed in accordance with the Declaration of Helsinki relevant guidelines and regulations.

Consent for publication

Not applicable.

Competing interests

The authors declare that they have no competing interests.

Funding

This research received no specific grant from any funding agency in the public, commercial or not-for-profit sectors.

Authors' contributions

Conceptualization and Methodology Da Peng Feng; Ming Quan Liu

Data Curation and Formal analysis: Ming Quan Liu, Wei Zhang, Jia Qi Wang

Writing - Original Draft: Ming Quan Liu

Writing - Review & Editing: Da Peng Feng; Zheng Wei Li*

Acknowledgements

Not applicable.

Availability of data and materials

Data cannot be provided due to identifying information of participants but are available from the corresponding author on reasonable request.

References

1. Heary RF. Evaluation and treatment of adult spinal deformity. Invited submission from the Joint Section Meeting on Disorders of the Spine and Peripheral Nerves, March 2004.[J] .J Neurosurg Spine, 2004, 1: 9-18. DOI: 10.3171/spi.2004.1.1.0009
2. Dorward IG,Lenke LG. Osteotomies in the posterior-only treatment of complex adult spinal deformity: a comparative review.[J] .Neurosurg Focus, 2010, 28: E4. DOI: 10.3171/2009.12.FOCUS09259
3. Hyun SJ, Rhim SC. Clinical outcomes and complications after pedicle subtraction osteotomy for fixed sagittal imbalance patients : a long-term follow-up data.[J] .J Korean Neurosurg Soc, 2010, 47: 95-101.DOI: 10.3340/jkns.2010.47.2.95
4. Gill JB, Levin A, Burd T, Longley M. Corrective osteotomies in spine surgery. The Journal of bone and joint surgery. American volume, 2008. 90(11): p. 2509-20.DOI: 10.2106/JBJS.H.00081
5. Bridwell KH,Lewis SJ,Edwards C,et al. Complications and outcomes of pedicle subtraction osteotomies for fixed sagittal imbalance. Spine, 2003. 28(18): p. 2093-101.DOI: 10.1097/01.BRS.0000090891.60232.70
6. Smith JS, Sansur CA, Donaldson WF, et al. Short-term morbidity and mortality associated with correction of thoracolumbar fixed sagittal plane deformity: a report from the Scoliosis Research

- Society Morbidity and Mortality Committee. Spine, 2011. 36(12): p. 958-64.DOI: 10.1097/BRS.0b013e3181eabb26
7. Phan K, Maharaj M, Assem Y, et al. Review of early clinical results and complications associated with oblique lumbar interbody fusion (OLIF).[J] .J Clin Neurosci, 2016, 31: 23-9.DOI: 10.1016/j.jocn.2016.02.030
 8. Ohtori S, Orita S, Yamauchi K, et al. Mini-Open Anterior Retroperitoneal Lumbar Interbody Fusion: Oblique Lateral Interbody Fusion for Lumbar Spinal Degeneration Disease.[J] .Yonsei Med J, 2015, 56: 1051-9.DOI: 10.3349/ymj.2015.56.4.1051
 9. Li JX, Phan K, Mobbs R. Oblique Lumbar Interbody Fusion: Technical Aspects, Operative Outcomes, and Complications.[J] .World Neurosurg, 2017, 98: 113-123.DOI: 10.1016/j.wneu.2016.10.074
 10. Hills JM, Yoon ST, Rhee JM, et al. Anterior Column Realignment (ACR) With and Without Pre-ACR Posterior Release for Fixed Sagittal Deformity. International journal of spine surgery, 2019. 13(2): p. 192-198.DOI: 10.14444/6026
 11. Akbarnia BA, Mundis GM, Moazzaz P, et al. Anterior column realignment (ACR) for focal kyphotic spinal deformity using a lateral transpsoas approach and ALL release.[J] .J Spinal Disord Tech, 2014, 27: 29-39.DOI: 10.1097/BSD.0b013e318287bdc1
 12. Glassman SD, Hamill CL, Bridwell KH, et al. The impact of perioperative complications on clinical outcome in adult deformity surgery.[J] .Spine (Phila Pa 1976), 2007, 32: 2764-70.DOI: 10.1097/BRS.0b013e31815a7644
 13. Wewel JT, Godzik J, Uribe JS. The utilization of minimally invasive surgery techniques for the treatment of spinal deformity.[J] .J Spine Surg, 2019, 5: S84-S90.DOI: 10.21037/jss.2019.04.22
 14. Pellisé F, Vila-Casademunt A, Ferrer M, et al. Impact on health related quality of life of adult spinal deformity (ASD) compared with other chronic conditions.[J] .Eur Spine J, 2015, 24: 3-11.DOI: 10.1007/s00586-014-3542-1
 15. Ailon T, Shaffrey CI, Lenke LG, et al. Progressive Spinal Kyphosis in the Aging Population.[J] .Neurosurgery, 2015, null: S164-72.DOI: 10.1227/NEU.0000000000000944
 16. Liu H, Yang C, Zheng Z, et al. Comparison of Smith-Petersen osteotomy and pedicle subtraction osteotomy for the correction of thoracolumbar kyphotic deformity in ankylosing spondylitis: a systematic review and meta-analysis. Spine, 2015. 40(8): p. 570-9.DOI: 10.1097/BRS.0000000000000815
 17. Neal CJ, McClendon J, Halpin R, et al. Predicting ideal spinopelvic balance in adult spinal deformity. [J] .J Neurosurg Spine, 2011, 15: 82-91.DOI: 10.3171/2011.2.SPINE1018
 18. Logroscino CA, Proietti L, Pola E, et al. A minimally invasive posterior lumbar interbody fusion for degenerative lumbar spine instabilities.[J] .Eur Spine J, 2011, null: S41-5.DOI: 10.1007/s00586-011-1762-1
 19. Barone G, Scaramuzzo L, Zagra A, et al. Adult spinal deformity: effectiveness of interbody lordotic cages to restore disc angle and spino-pelvic parameters through completely mini-invasive transpsoas and hybrid approach.[J] .Eur Spine J, 2017, 26: 457-463.DOI: 10.1007/s00586-017-5136-1

20. Saigal R, Mundis GM, Eastlack R, et al. Anterior Column Realignment (ACR) in Adult Sagittal Deformity Correction: Technique and Review of the Literature.[J] .Spine (Phila Pa 1976), 2016, null: S66-73.DOI: 10.1097/BRS.0000000000001483
21. Cheung ZB,Chen DH,White SJW,et al. Anterior Column Realignment in Adult Spinal Deformity: A Case Report and Review of the Literature.[J] .World Neurosurg, 2019, 123: e379-e386.DOI: 10.1016/j.wneu.2018.11.174
22. Mundis GM, Turner JD, Kabirian N, et al., Anterior Column Realignment has Similar Results to Pedicle Subtraction Osteotomy in Treating Adults with Sagittal Plane Deformity. World neurosurgery, 2017. 105: p. 249-256.DOI: 10.1016/j.wneu.2017.05.122
23. Pimenta L, Oliveira L, Schaffa T, et al. Lumbar total disc replacement from an extreme lateral approach: clinical experience with a minimum of 2 years' follow-up.[J] .J Neurosurg Spine, 2011, 14: 38-45.DOI: 10.3171/2010.9.SPINE09865
24. Rodgers WB, Gerber EJ, Patterson J. Intraoperative and early postoperative complications in extreme lateral interbody fusion: an analysis of 600 cases.[J] .Spine (Phila Pa 1976), 2011, 36: 26-32.OID: 10.1097/BRS.0b013e3181e1040a
25. Cummock MD, Vanni S, Levi AD, et al. An analysis of postoperative thigh symptoms after minimally invasive transpsoas lumbar interbody fusion.[J] .J Neurosurg Spine, 2011, 15: 11-8.DOI: 10.3171/2011.2.SPINE10374
26. Uribe JS, Isaacs RE, Youssef JA, et al. Can triggered electromyography monitoring throughout retraction predict postoperative symptomatic neuropraxia after XLIF? Results from a prospective multicenter trial.[J] .Eur Spine J, 2015, null: 378-85.DOI: 10.1007/s00586-015-3871-8
27. Rao PJ, Loganathan A, Yeung V, et al. Outcomes of anterior lumbar interbody fusion surgery based on indication: a prospective study.[J] .Neurosurgery, 2015, 76: 7-23; discussion 23-4.DOI: 10.1227/NEU.0000000000000561
28. Li J, Li H, Zhang N, et al. Radiographic and clinical outcome of lateral lumbar interbody fusion for extreme lumbar spinal stenosis of Schizas grade D: a retrospective study.[J] .BMC Musculoskelet Disord, 2020, 21: 259.DOI: 10.1186/s12891-020-03282-6
29. Schizas C, Theumann N, Burn A, et al. Qualitative grading of severity of lumbar spinal stenosis based on the morphology of the dural sac on magnetic resonance images.[J] .Spine (Phila Pa 1976), 2010, 35: 1919-24.DOI: 10.1097/BRS.0b013e3181d359bd

Tables

Table 1 Surgery-related data.

Variable	Bleeding volume(ml)	Operation time(min)	n
ALIF-ACR	50.2±23.6	50.4±22.1	59
OLIF-ACR			
1	70.2±31.6	66.2±19.4	24
2	87.2±38.6	96.2±27.4	29
3	117.2±36.7	106.2±37.4	3
PPSF			
	130.6±98.2	78.9±52.4	64

PPSF: Percutaneous pedicle screw fixation

Table 2 Comparison of the preoperative and postoperative Radiographic date

	Preoperative	postoperative	Final follow-up	T	P
LL °	16.7±6.4	48.6±10.7	47.1±3.6	4.20	0.010
IVA mm	4.1±1.8	19.4±3.9	18.5±3.8	15.07	0.01
ALIF-IVA	4.9±2.5	22.7±4.9	17.1±3.6	17.60	0.01
OLIF-IVA	6.9±3.1	18.8±4.4	16.1±3.3	8.34	0.01
SVA mm	65.1±10.1	29.5±12.5	31.5±14.3	2.98	0.01

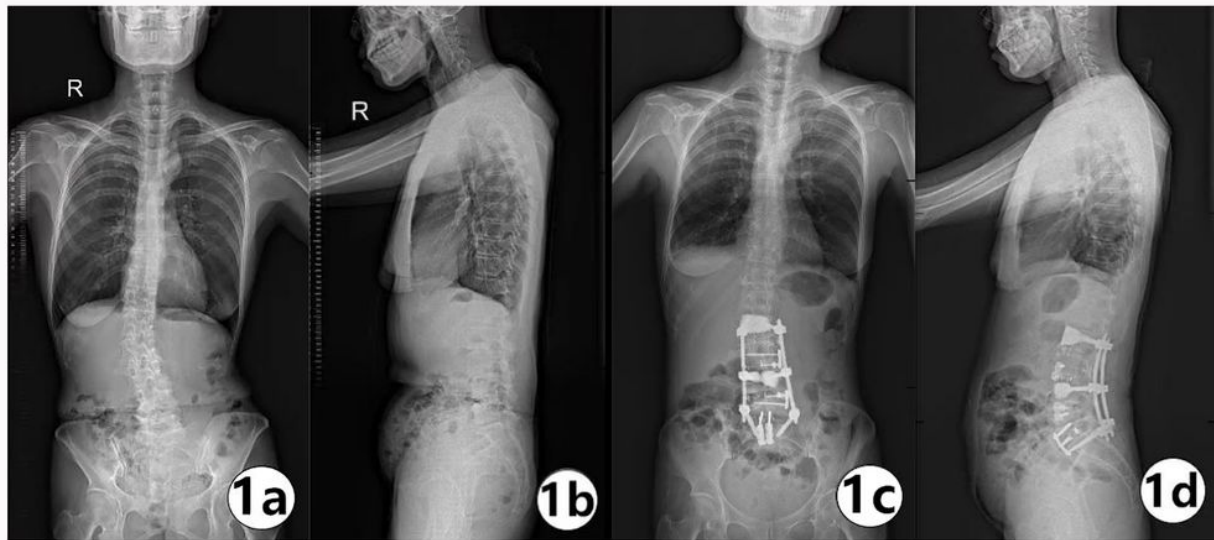
LL:lumbar lordosis; IVA: Intervertebral space angle of the surgical segment SVA:sagittal vertical axis

Table 3 Comparison of the preoperative and postoperative clinical outcomes

	Preoperative	postoperative	Final follow-up	T	P
VAS	6.8±1.6	2.1±0.7	1.8±0.8	5.51	0.01
JOA	7.8±2.9	19.1±2.7	22±3.9	16.13	0.01

VAS:visual analog scale;

Figures



**Fig 1 a/b Preoperative frontal and lateral view radiographs
c/d Postoperative frontal and lateral view radiographs**

Figure 1

See image above for figure legend.