Anatomic features of mandibular second molars root canals in a Yemeni population: cone-beam computed tomography

Elham M. Senan (elhamdent06@yahoo.com)
College of Dentistry, University of Science and Technology https://orcid.org/0000-0003-3471-5031

Hatem A. Alhadainy
University of North Carolina at Chapel Hill

Ahmed A. Madfa
(1) Restorative and Prosthodontic Department, College of Dentistry, University of Science and Technology. (2) Department of Conservative Dentistry, Faculty of Dentistry, Thamar University.

Research article

Keywords: Cone-beam computed tomography, C-shaped canal, mandibular second molar, morphology, root canal, Yemen

Posted Date: July 28th, 2019

DOI: https://doi.org/10.21203/rs.2.12016/v1

Abstract

Background: This study aimed to identify and characterize root and canal morphology and the prevalence of C-shaped canals of mandibular second molars (MSMs) in a Yemeni population using cone-beam computed tomography (CBCT). Methods: CBCT images of 500 right and left MSMs with mature roots were taken from 250 Yemeni individuals and analyzed for the following features: number of roots, total number of canals orifices within the tooth and number of canals orifices in each root, type of roots, either fused or separated, shape of root in cross section, type of canal configuration in each root, presence of C-shaped canal, and primary variations in the morphology of root and canal systems. Results: Molars with separated two roots predominated (89.6%), fused two roots were 9%, separated three roots were 0.6% and one root MSMs were 0.8%. Molars with three canals orifices were the most common. Mesial root was mainly ribbon-shaped (60.5%) and distal root was mainly kidney-shaped (50.7%). Type II and Type I canal configurations were the most frequent in mesial root (56.9%) and distal root (91.3%), respectively. C-shaped canals were found in 9%. Six variants were found with variant 3 was the most common (71%). Conclusions: Yemeni permanent MSMs have mainly two separated roots. Mesial root is mostly ribbon-shaped and distal root is mainly kidney-shaped. Vertucci type II and I canal configurations showed the higher incidence in mesial and distal roots, respectively. C-shaped canals were found in 9%.

Keywords: Cone-beam computed tomography, C-shaped canal, mandibular second molar, morphology, root canal, Yemen

Background

Sufficient knowledge of teeth internal anatomy is a crucial pre-requisite for a proper root canal treatment. Long term success of endodontic treatment depends mainly on appropriate cleaning and shaping of the different anatomical details within pulp system including all canals along the root length and their divisions and fusions [1].

Several studies reported that root canal morphology of the mandibular second molars (MSMs) have various and complex anatomical features [2-9] which represent a challenge along endodontic treatment procedures starting from canal recognition to obturation [4]. One of the anatomical variations of MSMs is the number of their roots; although two roots are most commonly noticed, a single root was found in 22-25% in Asian populations [3, 6] and in 8.93-14.29% in Caucasians [10]. Three-rooted MSMs were reported in 1.2% of a Thai population [6], 3.5% of Brazilians [2] and 3.45% of Turkish [11].

The C-shaped canal configuration is most frequently found in MSMs despite its presence in a number of posterior teeth such as mandibular first premolar [12], mandibular first molar [13], maxillary first and second molars [14]. Failure of fusion of epithelial root sheath on root surface either buccally or lingually was believed to be the main cause of C-shaped roots and canals occurrence [15]. The prevalence of C-shaped canal was found to be 4.1% in a Turkish population [11], 6-44.5% in Eastern Asian populations [3, 4, 6, 7], 10% in an African [5] and European population [10], 3.5-10% in southern American populations [2, 10], and 10.6% in an Arab population [16].

Few studies have evaluated root and canal morphology of MSMs in Arabic populations, particularly the occurrence of C-shaped canals [5, 17-20]. Furthermore, no published study has been found about the prevalence of C-shaped canals in MSMs in Yemen. Therefore, this study aimed to identify and characterize root and canal morphology of MSMs and to report the prevalence and anatomic features of C-shaped canals in these teeth in a Yemeni population using Cone Beam Computed Tomography (CBCT).

Methods

The study sample included 250 Yemeni (125 males and 125 females) attending University of Science and Technology (UST) dental clinics at Sana'a, Yemen to receive various dental treatments provided by dental students during the years of 2016 to 2018. The patients were referred to a digital radiology center where small-field CBCT images of 500 MSMs were performed. The protocol of this study was approved by the Medical Ethics Committee of Faculty of Medicine and Health Sciences at UST (MECA NO.: EAC/UST139). Each participant provided verbal and written consents to be included in the study.

The inclusion criteria were fully-erupted bilateral permanent MSMs with mature apices. The teeth should be sound or with initial decay without cavitations, no previous root canal treatment, no posts and/or crown restorations and no root resorption, calcification, or fractures.

Pax-Flex3D imaging system (VATECH Global, Korea) was used to obtain the CBCT scans applying manufacturer's recommendation protocol with the following standardized settings: 50-90 kVp, 2-10 mA, 50×50 mm field of view (FOV), 15-24 seconds exposure time, and 120 μm voxel size for each tooth from each individual on both sides.

Two endodontists evaluated all CBCT scans after calibration to the anatomical criteria and variants used in this study. Disagreement in images interpretation was discussed between the two endodontists until a decision is made. Ez3D Plus image software (VATECH Global, Korea) was used to analyze the CBCT scans of each tooth in the three sections (Axial, coronal, and sagittal). Contrast and brightness of CBCT images were adjusted when required to obtain the best possible image for proper reading and analysis.

The following morphological features were recorded:

1. Number of roots
2. Total number of canals orifices within the tooth and number of canals orifices in each root
3. Type of roots (fused or separated)
4. Shape of root in cross section
5. Type of canals within each root based on Vertucci's [1]
6. C-shaped canals which were evaluated in root cross sections coronally, middle and apically as follows: coronal level: 2 mm apical to the canal orifice level; middle: root length was divided by two; and apically: 2 mm coronal to the root apex. Afterwards, these canals were classified according to Fan et al. [21] classifications (C1, C2, C3c, C3d, C4 and C5).

Three anatomical features should be present for a MSM to be categorized as having a C-shaped canal system: fused roots, a longitudinal groove lingually, buccally or on both surfaces of their roots, and at least one cross-section of the C-shaped canal to be C1, C2 or C3 class configuration.

7. Primary variations in root and canal systems morphology based on Zhang et al. [3] ten variants.

Bilateral and unilateral occurrences of similar anatomical features were recorded and their relations to gender and tooth location were determined. Statistical software (SPSS for Windows version 21.0, SPSS Inc., Chicago, IL, USA) was used to analyze the recorded data using Chi square and Fisher's exact tests. Statistical significance was defined at $p \leq 0.05$.

Results

Number of roots and canal orifices

MSMs had mostly two roots (98.6%, n=493) with only 0.8% (n=4) had one root and 0.6% (n=3) had three roots. Molars with three canals orifices are the most common (77%, n=385), followed by two canals orifices (21%, n=105) whereas one canal orifice was found only in 1.4% (n=7). All three-rooted molars have four canals orifices (0.6%, n=3). A bilateral occurrence of similar number of canals orifices on both sides was recorded in 80.8% (n=202 individual). No significant difference was found between females and males regarding frequency distribution of the total number of root canal orifices ($p>0.05$).

One-rooted and three-rooted molars occurred more in males than females. Molars with two roots were found to almost occur equally on both sides. All three-rooted molars occurred on the left side while one-rooted molars occurred more on the right side. Similar number of roots in right and left MSMs appeared in 98% (n=245 individual).

Type of roots

Molars with separated two roots predominated (89.6%, n=448), fused two roots were 9% (n=45) and separated three roots were 0.6% (n=3). Table 1 showed correlations between types of roots (separated or fused) with gender and tooth location. Bilateral existence of same type of roots was found in 94% (n=235). No significant difference of roots type was found between genders.

Shape of roots in cross section

Within the separated two-rooted molars, mesial root was mainly ribbon-shaped in cross section (60.5%, n=271), followed by kidney-shaped (19%), long oval (12.7%), and bowling pin (7.8%). Distal root was mainly kidney-shaped (50.7%, n=227), followed by oval (34.4%), long oval (14.5%), and round (0.4%). All molars with fused two roots showed a C-shaped root cross section. In three-rooted molars, mesial root was ribbon-shaped, distal root was either kidney-shaped or oval, and DL root was either oval or round. The four one-rooted molars showed an irregular shape in their root's cross section.

Root canal types

Three of the four one-rooted MSMs showed Vertucci type I canal and the fourth one showed type III canal.

Within the separated two-rooted MSMs (n=448), mesial root showed type II as the most frequent canal type in both genders accounting for 56.9% (n=255), followed by type IV (18.8%, n=84). In distal root, type I was the most prevalent type (91.3%, n=409). Canal types other than Vertucci's classification were found in mesial root but not found in distal root (Table 2).

Of the 45 MSMs (9%) with fused two roots, four teeth (8.9%) had one shallow groove along the buccal root surface, fourteen tooth (31.1%) had one deep groove along the lingual root surface, and the remaining twenty seven teeth (60%) had both (Figure 1). Fused two-root showed a C-shaped canal which was more in females (60%) than males (40%). C-shaped canals occur in a close frequency in both sides (48.9% on the right and 51.1% on the left).

The details of cross-sectional shapes of C-shaped canals at different root levels are shown in Table 3 and Figures 2-3. The majority of canals (68.9%) demonstrated an uninterrupted C-shape (C1) at the orifice root level, while three-separate canals shape (C3c) was the dominant shape at the coronal (55.6%), middle (66.7%), and apical (46.7%) levels. Semicolon shape (C2) was found more at coronal level (35.6%) than any other root levels. Two-separate canals shape (C3d) and single oval or round canal shape (C4) were found more frequent at apical level and in close percentages (26.7% and 24.4 respectively). C5 (no canal lumen) was not detected in this study.

C-shape canal configuration remains unchanged from orifice to apical level in two teeth only (4.4%). Teeth showed unchanged configuration from coronal to apical level in 37.8% of (17 teeth: C3c in 16 teeth and C3d in one tooth) while the C-shaped canal changed along the root length in the remaining 28 teeth (62.2%). From orifice to coronal level, class changed in 27 teeth, remains unchanged in eight teeth. From coronal to middle level, class changed in 18 teeth, remains unchanged in 27 teeth. From middle to apical level, class changed in 22 teeth, remains unchanged in 23 teeth.

Table 4 showed the distribution of the bilateral and unilateral occurrences of C-shaped canals. MSMs with C-shaped canals observed in 30 individuals with bilateral occurrence in 15 individuals (50%). Frequency of bilateral distribution was more in females than males, while unilateral occurrence did not differ with gender or tooth location.

The three-rooted molars (n=3) exhibited type II canal in mesial root and type I in both distal and DL roots.

Variations in morphology of root canal systems according to Zhang et al. [3]

Only variants 1, 3, 6, 8, 9 and 10 were observed within the included 500 MSMs (Figure 4). Variant 3 represented the most common morphology (71%), followed by variant 1 (18.6%). The other variants were found in smaller percentages (variant 10: 5.2%, variant 9: 3.2%, variant 8: 1.4% and variant 6: 0.6%). No

significant difference of variants distribution was found with gender or tooth location. Only 75.6% of individuals presented similar variants on both sides.

Discussion

Anatomical variations of external and internal teeth morphologies associated with ethnicity have been well documented [22]. Differences in root and root canal morphology of MSMs have been reported by several studies around the world with different percentages of each anatomical feature [2-9]. The current study presents the first description of the root and canal anatomy of Yemeni MSMs.

Yemeni MSMs had mostly separated two roots (89.6%). This is close to the findings reported in Iranians (79.2%, 81.6%, and 86.7%) [8, 23, 24], Turkish (85.4%, 90%) [11, 25], Indians (79.35%, 88.8%) [9, 26], Belgians (83.93%) and Chileans (86.61%) [10]. The observed one-rooted MSMs in Yemeni population was 0.8% which is in the same line with the findings in Turkish (1.29%) [11]. Nevertheless, higher percentages were reported in Iranians (13.3%, 19.8%) [8, 23], Indians (8.7%) [26], Chileans (8.93%) [10], Turkish (10%) [25], Belgians (14.29%) [10] and Chinese (22%) [3]. We found only 0.6% of three-rooted MSMs, which was in accordance with other studies in Iranians (0.6%) [24] and Belgians (0.89%) [10] but was higher than that reported in Koreans (0.3%) [27]. However, higher percentages were reported in Thai (1.2%) [6], Turkish (3.45%) [11], Brazilians (3.5%) [2], Chileans (3.57%) [10] and Indians (7.53%) [9]. No statistical gender- or tooth location-related differences were found in the occurrence of root numbers of molars within this study similar to Nur et al. study findings in Turkish [25].

MSMs with fused roots were 9% in this study. Close results were reported in Turkish (8.97%) [11] and south Indians (13.12%) [9]. However, higher percentages (24% and 39%) were found in Chinese [3, 4].

Root cross section of separated two-rooted MSMs was different in both roots such that mesial root was ribbon-shaped and distal root was kidney-shaped. Extreme care should be exercised while preparing root canals to avoid any complications that may occur due to thin dentin sections (danger zones).

MSMs with three orifices were the most common in this study (77%), followed by two orifices (21%). This is similar to findings in Turkish (72.8% with three orifices and 22.8% with two) [11] and Chinese (46% with three orifices followed by 38% with two) [3].

Mesial root of MSMs with separated two roots showed mainly type II canal, followed by type IV. This agrees with the results in Iranians [8, 23], but disagrees with numbers reported in Sudanese [5], Chinese [3], Indians [9], Iranians [24] and Turkish [11, 25] where mesial roots mainly had type IV canal. Our results also do not agree with findings in Belgians and Chileans [10] where type III canal was the most common type followed by type V. We found distal root had mostly type I canal which was the same as in Thai [6], Sudanese [5], Iranians [8, 23, 24], Chinese [3], Indians [9], Turkish [11, 25], Belgians and Chileans [10].

C-shaped canals in this study were found in 9% of MSMs, similar to that found in Saudis (9.1%) [28]. Closer percentages were reported in Chileans (8.93%) [10], Indians (8.1%, 9.7%, 13.12%) [9, 26, 29],

Sudanese (10%) [5], Belgians (10.71%) [10] and Iranians (6.7%) [23]. However, it was far lower than results in Iranians (17.6%, 21.4%) [8, 24], Lebanese (19.1%) [30], Chinese (29%, 38.6%) [3, 4], Koreans (39.8%, 44.5%) [7, 31] and Malaysians (48.7%) [32]. Nevertheless, the incidence of C-shaped canals in Yemenis was higher than Brazilians (3.5%) [2], and Turkish (4.1%) [11].

C-shaped canals were found in females more than males with no significant difference same as reported in Chinese [4], Indians [29] and Iranians [8]. Similar results but with a statistically significant difference were found in Koreans [31], Saudis [28] and Malaysians [32]. Regarding tooth location, C-shaped canals occurred almost even on both sides in this study with no significant difference similar to reports in Chinese [4], Iranians (35), Indians [29], and Koreans [31].

MSMs with C-shaped root showed mainly both lingual and buccal grooves, followed by lingual groove only and then by buccal groove only unlike study's findings in Saudis [28], Koreans [7] and Chinese [4, 21] which showed mainly lingual groove only. Moreover, Wadhwani et al. [29] reported MSMs mainly with a buccal groove only in Indians.

C1 was found to be the prevalent shape at orifice level which agreed with the findings in Chinese [4]. C3c was the dominant shape coronally, followed by C2. C3c was also the dominant shape in the middle third. These findings differed from those of Zheng et al. [4] where C1 followed by C3d were the dominant shapes coronally and C3d was the most prevalent in the middle third. However, C3c followed by C3d were the dominant shapes apically in both Yemenis and Chinese. A study in Iranians [8] reported different results in which C1 was the most frequent in the coronal third and C3d was the major shape in both middle and apical thirds. Moreover, Kim et al. [31] reported that C2 is the most common configuration at the orifice level.

C-shaped canal configuration remains unchanged from orifice to apical level in 4.4%. Similar findings were recorded in Iranians [8] and Chinese [4] where 4.9% and 5.9% of C-shaped canals remained unchanged along the root length, respectively. This agrees with the results of Fan et al. [21] who reported that C-shaped canals vary in shape and number along the root length. Therefore, the shape of the canal orifice cannot be considered as an indicator of the C-shaped canal anatomy along the tooth root to its apex. There was no constant change in the configuration of the C-shape canal between two adjacent root levels. This was also reported by Zheng et al. [4].

The occurrence of C1 and C2 shapes decreased from the coronal to the apical levels, however, C3c shape increased toward the middle level and C3d type increased toward the apical level. This revealed a high possibility of division of C-shaped canals into two or three canals towards the apex. Similar results were reported earlier in Chinese [21]. This necessitates the emphasis of applying the available techniques for canal debridement to ensure proper cleaning of such complex anatomy at different root levels.

The bilateral and unilateral occurrences of C-shaped canals were found to be equal. Janani et al. [8] reported a slightly higher occurrence of bilateral C-shaped canals (15.6%) than their unilateral occurrence (11.76%) in Iranians with no significant difference. However, there was a much higher percentage of

bilateral C-shaped canals occurrence (81.3%) than unilateral occurrence (18.7%) in Chinese [4]. Similarly, a 71% of bilateral occurrence of C-shaped canals was reported in Koreans [31]. The unilateral occurrence of C-shaped canals was higher on Saudis (53.85%) [28]. In relation to gender, bilateral occurrence of C-shaped canals in this study was more in females than males unlike Zheng et al. [4] who showed no difference of bilateral distribution with gender. Unilateral occurrence of C-shaped canals showed no significant difference regarding gender or tooth location in this study, similar to findings in Chinese [4].

Six variants (1, 3, 6, 8, 9 and 10) were observed in the root and root canal morphology of the studied MSMs. Other studies showed more variants such as seven variants (1, 3, 4, 6, 8, 9 and 10) in Brazilians [2], and eight variants (1, 3, 4, 5, 6, 8, 9 and 10) in Chinese [3]. Variant 3 was the most common morphology in Yemenis followed by variant 1, similar to previous study reports in Brazilians [2] and Chinese [3]. Yemeni MSMs showed a higher percentage of variant 3 (71%) than that found in Thai (54%) [6], Brazilians (54%) [2], and Chinese (42%) [3].

Root and canal morphology of Yemeni MSMs when compared with different populations showed the presence of morphological differences that should be taken into consideration during clinical practice. Therefore, a thorough radiographical examination during endodontic treatment is essential to identify the canal shape at each root level and facilitate planning for canal debridement and subsequent obturation.

Conclusions

Yemeni permanent MSMs have mainly two separated roots, in which mesial root is mainly ribbon-shaped and distal root is predominantly kidney-shaped in cross sections. Vertucci type II and I canal configurations showed the higher incidence in mesial and distal roots, respectively. C-shaped canals were found in 9% of the study sample.

The results of the present study further confirm that CBCT is a clinically effective tool for diagnosis and radiographic evaluation of the anatomical features of C-shaped canals with their varying morphology along the root length for proper canal debridement and obturation.

List Of Abbreviations

MSMs: mandibular second molars; CBCT: cone-beam computed tomography; UST: University of Science and Technology; MEC: Medical Ethics Committee

Declarations

Ethics approval and consent to participate

The current study was approved by the Medical Ethics Committee of Faculty of Medicine and Health Sciences at University of Science and Technology, Sana’a, Yemen (MECA NO.: EAC/UST139). Each participant provided verbal and written consents to be included in this study.

Consent to publish

“Not applicable”

Availability of data and materials

The data analyzed during the current study are available from the corresponding author on request.

Competing interests

The authors declare that they have no competing interests.

Funding

This study was partially funded by University of Science and Technology, Sana’a, Yemen.

Authors' Contributions

ES contributed with research concept, sample collection, reading CBCT, data collection, statistical analysis, results interpretation, writing the original draft and reviewing and editing the final manuscript.

HA contributed with research concept, supervision, results interpretation, writing the original draft and critical reviewing and editing of the final manuscript.

AM contributed with supervision, reading CBCT, statistical analysis, results interpretation, writing the original draft and reviewing and editing the final manuscript.

Acknowledgements

The authors would like to acknowledge the co-operation received from the staff of the radiology imaging center.

Authors' Information

ES is a Lecturer of Endodontics at the Restorative and Prosthodontic Department, College of Dentistry, University of Science and Technology, Sana’a, Yemen.

HA is a Professor of Endodontics at Faculty of Medicine and Dentistry, University of North Carolina, Chapel Hill, North Carolina, USA. On leave from the Department of Endodontics, Faculty of Dentistry, Tanta University, Tanta, Egypt.

AM is an Associate Professor of Endodontics at the Department of Conservative Dentistry, Faculty of Dentistry, Thamar University, Dhamar, Yemen, and at the Restorative and Prosthodontic Department, College of Dentistry, University of Science and Technology, Yemen.

References

1. Vertucci FJ. Root canal anatomy of the human permanent teeth. Oral surgery, oral medicine, oral pathology. 1984;58:589-99.
2. Silva EJNL, Nejaim Y, Silva AV, Haiter-Neto F, Cohenca N. Evaluation of root canal configuration of mandibular molars in a Brazilian population by using cone-beam computed tomography: an in vivo study. Journal of endodontics. 2013;39:849-52.
3. Zhang R, Wang H, Tian YY, Yu X, Hu T, Dummer PMH. Use of cone-beam computed tomography to evaluate root and canal morphology of mandibular molars in Chinese individuals. International endodontic journal. 2011;44:990-9.
4. Zheng Q, Zhang L, Zhou X, Wang Q, Wang Y, Tang L, Song F, Huang D. C-shaped root canal system in mandibular second molars in a Chinese population evaluated by cone-beam computed tomography. International endodontic journal. 2011;44:857-62.
5. Ahmed H, Abu-bakr N, Yahia N, Ibrahim Y. Root and canal morphology of permanent mandibular molars in a Sudanese population. International Endodontic Journal. 2007;40:766-71.
6. Gulabivala K, Opasanon A, Ng YL, Alavi A. Root and canal morphology of Thai mandibular molars. International Endodontic Journal. 2002;35:56-62.
7. Jin G-C, Lee S-J, Roh B-D. Anatomical study of C-shaped canals in mandibular second molars by analysis of computed tomography. Journal of endodontics. 2006;32:10-3.
8. Janani M, Rahimi S, Jafari F, Johari M, Nikniaz S, Ghasemi N. Anatomic Features of C-shaped Mandibular Second Molars in a Selected Iranian Population Using CBCT. Iranian Endodontic Journal. 2018;13:120-5.
9. Pawar A, Pawar M, Kfir A, Singh S, Salve P, Thakur B, Neelakantan P. Root canal morphology and variations in mandibular second molar teeth of an Indian population: an in vivo cone-beam computed tomography analysis. Clinical oral investigations. 2017;21:2801-9.
10. Torres A, Jacobs R, Lambrechts P, Brizuela C, Cabrera C, Concha G, Pedemonte ME. Characterization of mandibular molar root and canal morphology using cone beam computed tomography and its variability in Belgian and Chilean population samples. Imaging science in dentistry. 2015;45:95-101.
11. Demirbuga S, Sekerci AE, Dinçer AN, Cayabatmaz M, Zorba YO. Use of cone-beam computed tomography to evaluate root and canal morphology of mandibular first and second molars in Turkish individuals. Medicina oral, patologia oral y cirugia bucal. 2013;18:737.
12. Fan B, Yang J, Gutmann JL, Fan M. Root canal systems in mandibular first premolars with C-shaped root configurations. Part I: Microcomputed tomography mapping of the radicular groove and associated root canal cross-sections. Journal of endodontics. 2008;34:1337-41.
13. Raghavendra SS, Napte BD, Desai NN, Hindlekar AN. Single C-shaped canal in mandibular first molar: A case report. Journal of conservative dentistry: JCD. 2015;18:168.
14. Jo H-H, Min J-B, Hwang H-K. Analysis of C-shaped root canal configuration in maxillary molars in a Korean population using cone-beam computed tomography. Restorative dentistry & endodontics.

2016;41:55-62.

15. Manning S. Root canal anatomy of mandibular second molars: Part II C-shaped canals. International Endodontic Journal. 1990;23:40-5.
16. Al-Fouzan K. C-shaped root canals in mandibular second molars in a Saudi Arabian population. International Endodontic Journal. 2002;35:499-504.
17. Al-Nazhan S. Incidence of four canals in root-canal-treated mandibular first molars in a Saudi Arabian sub- International endodontic journal. 1999;32:49-52.
18. Ahmad IA. Root and root canal morphology of Saudi Arabian permanent dentition. Saudi Endodontic Journal. 2015;5:99-106.
19. Mukhaimer RH. Evaluation of Root Canal Configuration of Mandibular First Molars in a Palestinian Population by Using Cone-Beam Computed Tomography: An Ex Vivo Study. International Scholarly Research Notices. 2014;2014:
20. Al-Qudah A, Awawdeh L. Root and canal morphology of mandibular first and second molar teeth in a Jordanian population. International endodontic journal. 2009;42:775-84.
21. Fan B, Cheung GS, Fan M, Gutmann JL, Bian Z. C-shaped canal system in mandibular second molars: Part I–Anatomical features. Journal of endodontics. 2004;30:899-903.
22. De Pablo ÓV, Estevez R, Sánchez MP, Heilborn C, Cohenca N. Root anatomy and canal configuration of the permanent mandibular first molar: a systematic review. Journal of endodontics. 2010;36:1919-31.
23. Akhlaghi NM, Abbas FM, Mohammadi M, Shamloo MRK, Radmehr O, Kaviani R, Rakhshan V. Radicular anatomy of permanent mandibular second molars in an Iranian population: A preliminary study. Dental research journal. 2016;13:362.
24. Madani ZS, Mehraban N, Moudi E, Bijani A. Root and canal morphology of mandibular molars in a selected Iranian population using cone-beam computed tomography. Iranian endodontic journal. 2017;12:143-8.
25. Nur BG, Ok E, Altunsoy M, Aglarci OS, Colak M, Gungor E. Evaluation of the root and canal morphology of mandibular permanent molars in a south-eastern Turkish population using cone-beam computed tomography. European journal of dentistry. 2014;8:154-9.
26. Felsypremila G, Vinothkumar TS, Kandaswamy D. Anatomic symmetry of root and root canal morphology of posterior teeth in Indian subpopulation using cone beam computed tomography: a retrospective study. European journal of dentistry. 2015;9:500.
27. Choi M-R, Moon Y-M, Seo M-S. Prevalence and features of distolingual roots in mandibular molars analyzed by cone-beam computed tomography. Imaging science in dentistry. 2015;45:221-6.
28. Alfawaz H, Alqedairi A, Alkhayyal AK, Almobarak AA, Alhusain MF, Martins JN. Prevalence of C-shaped canal system in mandibular first and second molars in a Saudi population assessed via cone beam computed tomography: a retrospective study. Clinical oral investigations. 2019;23:107-12.

29. Wadhwani S, Singh MP, Agarwal M, Somasundaram P, Rawtiya M, Wadhwani P. Prevalence of C-shaped canals in mandibular second and third molars in a central India population: A cone beam computed tomography analysis. Journal of conservative dentistry: JCD. 2017;20:351.
30. Haddad GY, Nehme WB, Ounsi HF. Diagnosis, classification, and frequency of C-shaped canals in mandibular second molars in the Lebanese population. Journal of endodontics. 1999;25:268-71.
31. Kim H-S, Jung D, Lee H, Han Y-S, Oh S, Sim H-Y. C-shaped root canals of mandibular second molars in a Korean population: a CBCT analysis. Restorative Dentistry & Endodontics. 2018;43:1-7.
32. Pan JYY, Parolia A, Chuah SR, Bhatia S, Mutalik S, Pau A. Root canal morphology of permanent teeth in a Malaysian subpopulation using cone beam computed tomography. BMC Oral Health. 2019;19:1-15.

Tables

Table 1 Correlations between type of roots with gender and tooth side position

		Gender			Tooth Position		
		Male	Female	Total	Right	Left	Total
One-rooted ***n*** (%)		3 (0.6)	1 (0.2)	4 (0.8)	3 (0.6)	1 (0.2)	4 (0.8)
Two-rooted	Separated ***n*** (%)	227 (45.4)	221 (44.2)	448 (89.6)	225 (45)	223 (44.6)	448 (89.6)
	Fused ***n*** (%)	18 (3.6)	27 (5.4)	45 (9)	22 (4.4)	23 (4.6)	45 (9)
Three-rooted ***n*** (%)		2 (0.4)	1 (0.2)	3 (0.6)	0(0)	3 (0.6)	3 (0.6)
Total ***n*** (%)		250 (50)	250 (50)	500 (100)	250 (50)	250 (50)	500 (100)

Table 2 Variations of root canal types of mesial and distal roots of molars with separated two roots

Root		Vertucci's Canal Types								Non-Vertucci's Canal Types			Total
		I	II	III	IV	V	VI	VII	VIII	2-3-1	2-3-2	2-3-2-1	
Mesial	***n***	18	255	70	84	5	5	0	0	1	4	6	448
	%	4	56.9	15.6	18.8	1.1	1.1	0	0	0.2	0.9	1.3	100
Distal	***n***	409	0	35	0	4	0	0	0	0	0	0	448
	%	91.3	0	7.8	0	0.9	0	0	0	0	0	0	100

Table 3 Cross-sectional canal shapes of C-shaped canals at different levels

Root level		C-shape cross section					Total
		C1	C2	C3c	C3d	C4	
Orifice	***n***	31	11	3	0	0	45
	% from C-shaped group	68.9	24.4	6.7	0	0	100
	% from total teeth sample	6.2	2.2	0.6	0	0	9
Coronal	***n***	3	16	25	1	0	45
	% from C-shaped group	6.7	35.6	55.6	2.2	0	100
	% from total teeth sample	0.6	3.2	5	0.2	0	9
Middle	***n***	0	9	30	5	1	45
	% from C-shaped group	0	20	66.7	11.1	2.2	100
	% from total teeth sample	0	1.8	6	1	0.2	9
Apical	***n***	0	1	21	12	11	45
	% from C-shaped group	0	2.2	46.7	26.7	24.4	100
	% from total teeth sample	0	0.2	4.2	2.4	2.2	9

Table 4 Distribution of unilateral and bilateral occurrences of C-shaped canals in relation to gender and tooth position

Occurrences		Number of individuals			Number of Teeth		
		Male	Female	Total ***n*** (%)	Male	Female	Total ***n*** (%)
Unilateral	Right	4	3	7 (23.3)	4	3	7 (15.6)
	Left	4	4	8 (26.7)	4	4	8 (17.7)
Bilateral		5	10	15 (50)	10	20	30 (66.7)
Total		13	17	30 (100)	18	27	45 (100)

Figures

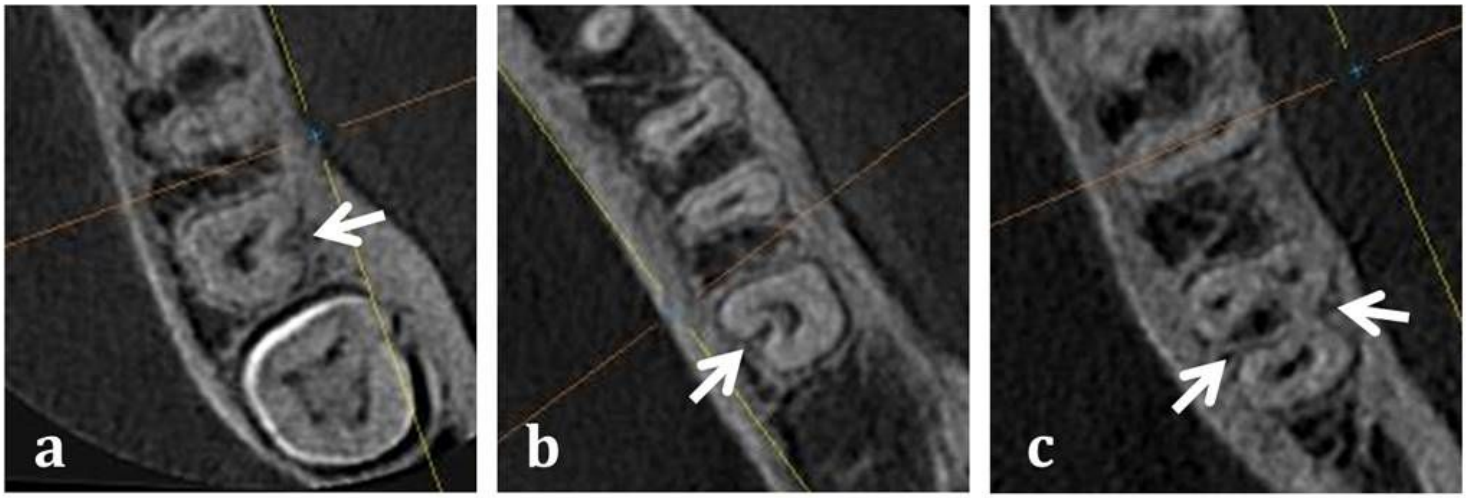

Figure 1

Root morphology of MSMs with fused two roots showing C-shaped cross section: a) Buccal groove, b) Lingual groove, c) Buccal and lingual grooves (white arrows).

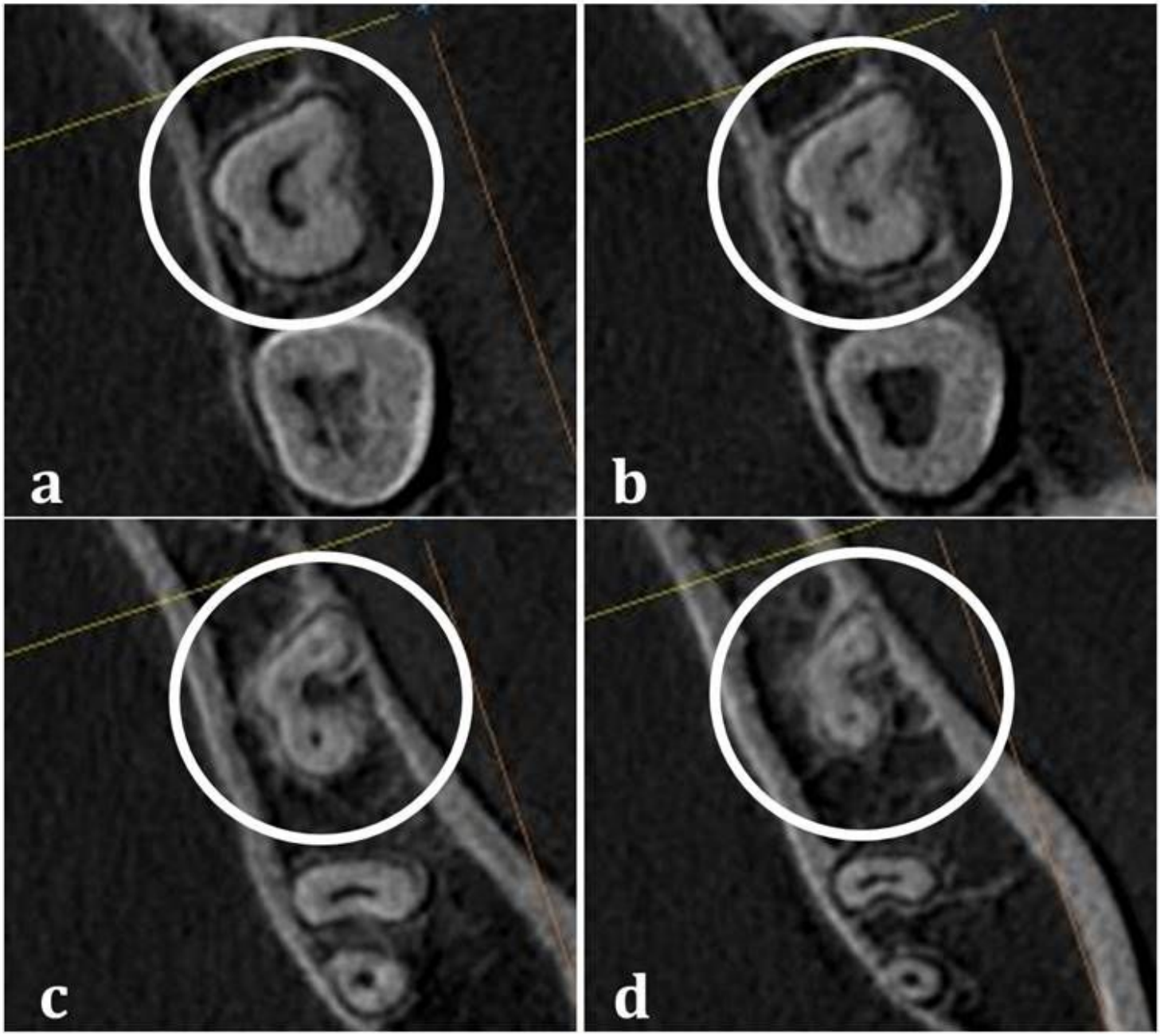

Figure 2

C-shaped canal system at different root levels: a) Canal orifice, b) Coronal third, c) Middle third, and d) apical third.

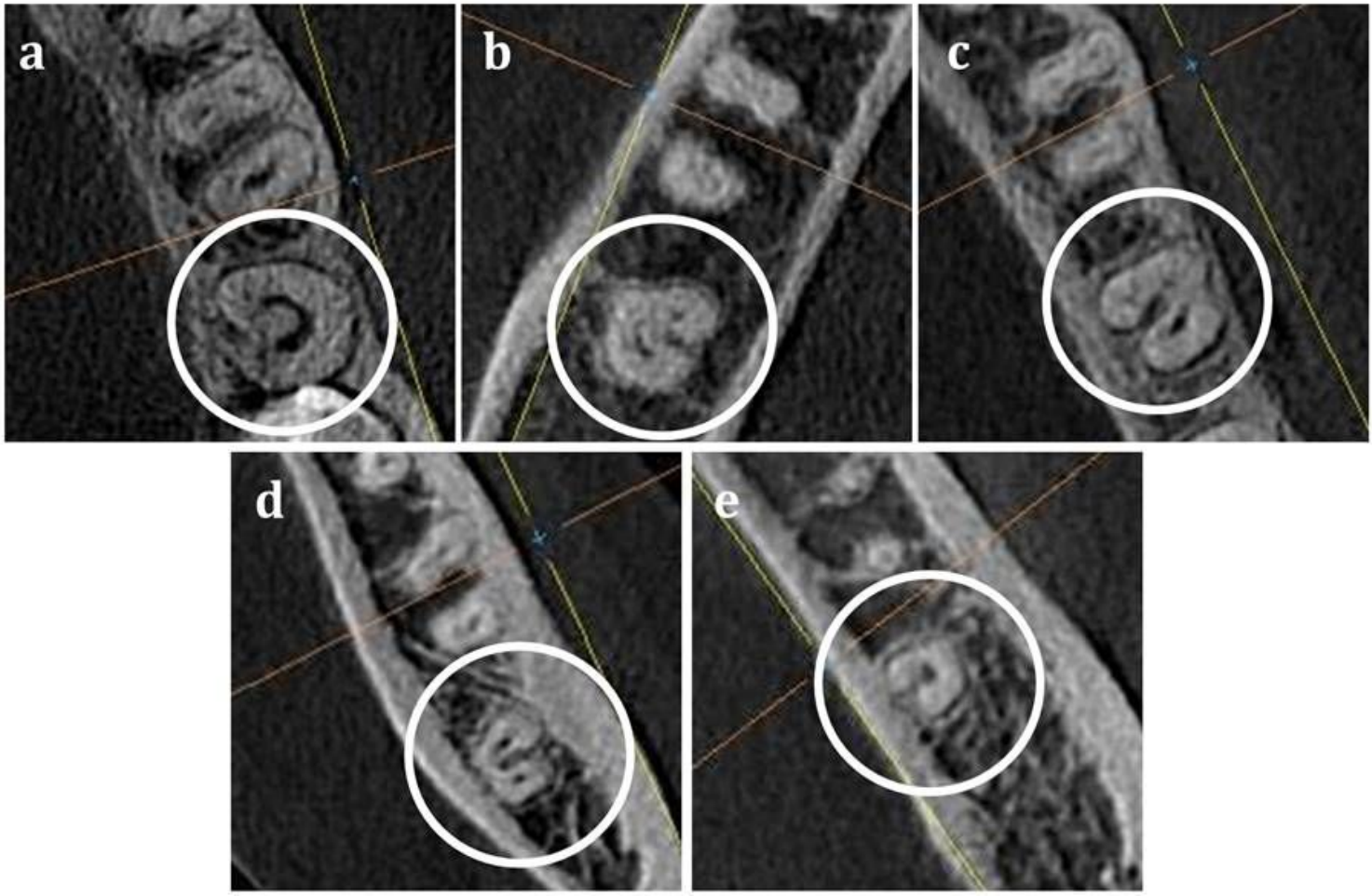

Figure 3

Classes of C-shaped canals: a) C1: continuous C-shaped canal, b) C2: MB-D canal and an ML canal (semicolon-shaped), c) C3c: three separate canals, d) C3d: two separate canals, e) C4: single round or oval canal

Figure 4

Variants of roots and root canals: a) variant 1, b) variant 3, c) variant 6, d) variant 8, e) variant 9 and f) variant 10.