Role of novel deep-learning-based CT used in management and discharge of COVID-19 patients at a “square cabin” hospital in China

Qingcheng Meng
affiliated cancer hospital of Zhengzhou university

Wentao Liu
affiliated cancer hospital of Zhengzhou university

Xinmin Dou
affiliated cancer hospital of Zhengzhou university

Jiaqi Zhang
Beijing Medical Intelligent Technology Co. Ltd

Anlan Sun
Beijing Medical Intelligent Technology Co. Ltd

Jia Ding
Beijing Medical Intelligent Technology Co. Ltd

Hao Liu
Beijing Medical Intelligent Technology Co. Ltd

Ziqiao Lei (ziqiao_lei@hust.edu.cn)
Wuhan Union Hospital

Xuejun Chen (zlyychenxuejun1943@zzu.edu.cn)
affiliated cancer hospital of Zhengzhou university

Research Article

Keywords: X ray, computed tomography, SARS-CoV-2; coronavirus disease 2019 (COVID-19); infectious disease; lung disease; deep learning

Posted Date: May 12th, 2020

DOI: https://doi.org/10.21203/rs.3.rs-28201/v1

Abstract

Background: The chest computed tomography (CT) had been used to define the diagnostic and discharge criteria for COVID-19. However, it is difficult to determine the suitability for discharge of a patient with COVID-19 based on CT features in a clinical setting. Deep learning (DL) technology has demonstrated great success in the medical imaging.

Purpose: This study applied the novel deep learning (DL) on chest computed tomography (CT) of COVID-19 patients with consecutive negative respiratory pathogen nucleic acid test results at a “square cabin” hospital in Wuhan, China, with the intent to standardize criteria for discharge.

Methods*:* The study included 270 patients (102men, 168 women; mean age, 51.9 ± 15.6[18–65] years) who had two consecutive negative respiratory pathogen tests (sampling interval: ≥1 day) and underwent low-dose CT 1 day after the first negative test, with strict adherence to epidemic prevention standards. The chest CT of COVID-19 patients with negative nucleic acid tests were evalued by DL, and the standard for discharge was a total volume ratio of lesions to lung of less than 50% determined by DL.

Results: The average intersection over union is 0.7894. Fifty-seven (21.1%) and 213 (78.9%) patients exhibited normal lung findings and pneumonia, respectively. 54.0% (115/213) involved mild interstitial fibrosis. 18.8% (40/213) had total volume ratio of lesions to lung of more than and equal to 50% according to our severity scale and were monitored continuously in hospital, and three cases of which had a positive follow-up nucleic acid test during hospital observation. None of the 230 discharged cases later tested positive or exhibited pneumonia progression.

Conclusions: The novel DL enables the accurate management of COVID-19 patients and can help avoid cluster transmission or exacerbation due to patients with false negitive acid test.

Summary

Forty of the total 270 cases (18.8%) remained hospitalized for continuous observation and three cases again presented with a positive nucleic acid test during isolation period. DL enables the accurate management and discharge of COVID-19 patients quantitatively and can help avoid cluster transmission or exacerbation.

Key Results

- The average IOU 0f our novel DL is 0.7894. Forty of the total 270 cases (18.8%) remained hospitalized for continuous observation according to the discharge standard of DL, and three of the 40 hospitalized cases again presented with a positive nucleic acid test during a 14-day isolation period.
- Two hundard and thirty (81.2%) cases were discharged, all of which didn’t have a subsequent positive nucleic acid test or manifested pneumonia progression. In our study, 57 (21.1%) cases had

normal lung features and 213 (78.9%) had pneumonia. Of the latter group, Additionally, 100 (46.9%) and 15 (7.0%) of the 213 cases had mild or moderate interstitial fibrosis.

Background

Coronavirus disease 2019 (COVID-19) caused by a novel coronavirus (SARS-CoV-2) has expanded to the level of a pandemic emergency worldwide [1] since the beginning of 2020. Compared to the family Coronaviridae such as well-known severe acute respiratory syndrome coronavirus (SARS-CoV) and Middle East respiratory syndrome coronavirus (MERS-CoV), SARS-CoV-2 is transmitted more rapidly than its predecessors and may lead to severe respiratory distress syndrome, even death [2-5]. Though the nucleic acid testing plays an indispensable role in the diagnosis and discharge of patients with COVID-19. However, the low sensitivity and false negative results of nucleic acid testing are greatly affected its performances in clinical. Consequently, the Diagnosis and Treatment Program (6th version) published by the National Health Commission of the People's Republic of China used radiologic features identified by radiologists to define the diagnostic and discharge criteria for COVID-19 [6]. The accurate chest computed tomography (CT)-based evaluation of viral pneumonia may indicate the need for isolation. Therefore, this radiologic modality plays an important role in the management of patients with suspected SARS-CoV-2 infection, especially when there are no scientifically proven therapies for COVID-19 [7]. However, it is difficult to determine the suitability for discharge of a patient with COVID-19 based on non-standardized CT features in a clinical setting. Recently, artificial intelligence (AI) using deep learning (DL) technology has demonstrated great success in the medical imaging domain due to its high capability of feature extraction [8-9]. Attempts have also made to detect various imaging features of chest CT [10]. In this study, we used deep learning based on three-dimensional deep convolutional neural network (3D-DCNN) framework on chest CT to provide guidance regarding the discharge of common COVID-19 patients with two consecutive negative nucleic acid tests for respiratory pathogens at a "square cabin" hospital of Wuhan in China.

Materials And Methods

Patients

Approval for this retrospective analysis of patients with COVID-19 was obtained from the Ethics Commission of Wuhan Union Hospital and the Affiliated Tumor Hospital of Zhengzhou Universitypatient consent was waived. Our retrospective cohort included 270 patients (102 men and 168 women; age range, 18–65 years; mean age ± standard deviation, 51.9 ± 15.6 years) who had received a confirmed positive result for nucleic acid testing for COVID-19 at Wuhan square cabin hospital from February 16 to March 7, 2020. All respiratory secretions for testing were collected using oropharyngeal swabs, and all viral testing was completed by the laboratory of Union Hospital in Wuhan, China. Patients who met the following criteria were included in the analysis: 1) age of 18–65 years; 2) return to normal body temperature for >3 days; 3) significant alleviation of respiratory symptoms; and 4) two consecutive negative respiratory pathogen nucleic acid tests (sampling interval: ≥1 day). The following exclusion

criteria were also applied: 1) COVID-19 accompanied by moderate or severe liver and kidney function impairment; 2) pregnancy concurrent with COVID-19; and 3) psychiatric symptoms or tumors. After applying these criteria, the CT images and clinical data of all eligible patients were analyzed.

CT Technique

All patients underwent low-dose CT (LDCT) scanning using a 40-slice multidetector CT scanner (uCT 550, United Imaging, Shanghai, China) with the following parameters: tube voltage, 120 KV; tube current, 30 mAs; field of view, 400 mm × 400 mm to 500 mm × 500 mm; matrix, 512×512; rotation time, 0.6 s; section width, 2.0 mm; reconstruction interval, 2.0 mm; and scan duration, 3–10s. Unenhanced spiral image acquisitions were obtained from the thoracic inlet to the lung base with breath-holding. The "Dose Report" function was used to record the dose parameters during spiral CT and a standard algorithm was used to reconstruction of images. All studies were reviewed on a PACS workstation at a window level of −500 to −700 Hounsfield units (HU) and window width of 1400 HU. Multiplanar images were obtained using the multiplanar reformatting (MPR) technique on the workstation.

DL framework based on 3D-DCNN algorithms

In this work, we used a network named as U-net, because of its U-shape architecture. Compared to traditional detection network in the pneumonia detection, the advantages of U-net was diaplayed by the following two reasons. One reason was that the lesion of pneumonia varied the size from center meters to the whole lung during the whole illness. Traditional best performance detection network for example Faster reversal convolutional neural network (R-CNN) [11-12] couldn't efficiently detect the lesion with so large size variation, because the box regression would be very hard for it. Another reason was that the pneumonia volume was an important clinical index to evaluate the stage of illness and prognostic. So, the precisely pixel level segmentation was necessary, and the U-net as the best and most popular segmentation architecture [13] became our first choice.Theoretically, the structure of U-net could kept multi scale's feature information when extracting the high-level context features by network down sampling, and gave accurate classification results by merging multi-layer context information which was obtained during the up-sampling process, shown in Figure 1. The reconstruction capability was strengthened by reconstructing each scale's feature from the deep layer aggregation. In this way, there was less information loss when multi-layer features were merged. And the loss function of deep supervision performed the supervision learning to each reconstruction result at each scale, which accelerated the convergent of the model.

Standard of discharge evaluated by DL and Image Interpretation

The degree of pneumonia in the lung was determined by the total volume ratio of lesions to lung (total volume ratio=volume of lesion1 + 2 + 3 +…/the volume of lung), and the standard of discharge was a volume ratio of lesions to the lung less than 50%. The LDCT data of all patients were interpreted independently by 3 thoracic radiologists with 7, 10, and 15 years of experience. All observations were assessed for major and ancillary features, after which the lung lesions were evaluated using the 4-grade

pneumonia scale. The statistical analysis was performed using SPSS 24.0 (SPSS Inc, Chicago, IL, USA). Measurement data are reported as means ± standard deviations (SDs). Continuous data are presented as frequencies and percentages.

Results

1. Patient and lesion characteristics

Table 1 demonstrates that of the 270 patients enrolled in this study, 57 (21.1%) had normal lung features and 213 (78.9%) had pneumonia. Of the latter group, respectively. Additionally, 100 (46.9%) and 15 (7.0%) of the 213 cases had mild or moderate interstitial fibrosis, respectively, and 166 (77.7%) of patients had lesions in ≥3 lobes. Regarding the locations of lesions in the lungs, distribution was mainly in the peripheral zone in 136 cases (63.8%), in the diffuse zone in 75 cases (35.2%), and in the central zone in 2 cases (0.9%). 16 (7.5%), 31 (14.6%), and 166 cases presented with lesions in 1, 2, or ≥3 lung lobes, respectively. Regarding CT findings, we identified 21 cases with vascular enlargement, 33 with pleural thickening, and 4 with mediastinal lymphadenopathy.

2. Experiment result and Performance metrics of DL

We use 110 CT scans for the evaluation. There are 1720 COVID-19 lesions. Volume of these lesions vary from tens of mm^3 to tens of thousands of mm^3, the distribution of volume can be seen in Fig. 2, more than half of the lesions are between 500 and 8000, more than 80% of the lesions are smaller than 12000 mm^3.

The evaluation is done by using intersection over union (IOU):

$$IOU = \frac{Intersection(ground\,truth, prediction)}{union(ground\,truth, prediction)}.$$

The average IOU over every lesions is:

$$AVG_{IOU} = \sum_{lesion\,i} \frac{Intersection(ground\,truth, prediction_i)}{union(ground\,truth, prediction_i)}$$

Higher IOU value means the prediction is more consistent with the label given by radiologist (ground truth). IOU of every predictions is shown in Fig 3. The average IOU is 0.7894. Some predictions of the AI system proposed in this paper were shown in Fig 4.

According to our discharge standard of a total volume ratio of lesions to total lung of less than 50% determined by DL, 40 of the total 270 cases (18.8%) remained hospitalized for continuous observation, and 230 (81.2%) were discharged. During a 14-day isolation period, three of the 40 hospitalized cases again presented with a positive nucleic acid test, shown in Fig 5. None of the 230 discharged cases had a subsequent positive nucleic acid test or manifested pneumonia progression.

Discussion

In this study, we designed and evaluated a three-dimensional DL model for providing standard discharge criteria for common COVID-19 patients, and we found that most discharged patients with common COVID-19 were managed well, and the three patients who later received a positive follow-up nucleic acid test after previous negative tests had been hospitalized based on our criteria and thus avoided cluster transmission or exacerbation of his own condition.

Previous histological examinations of biopsy samples collected from the lungs of COVID-19 patients showed diffuse alveolar damage with edema, cellular proteinaceous exudate, focal reactive pneumocytic hyperplasia with patchy inflammatory cellular infiltration, and multinucleated giant cells [14-15]. On CT, these lesions might appear as areas of ground glass opacity or consolidation [16]. Previous studies had successfully applied DL techniques to detect pneumonia in pediatric chest radiographs and chest CT [10, 17]. In this study, a three-dimensional DL framework was proposed to evaluate the serverity of COVID-19 patients. This framework using U-net network was able to extract 3D global representative features, which were benefit for integrating the 3D spacing information and making it clear about the distinction between the texture of lesions. The discharge criteria of common COVID-19 patients were managed well by DL and three cases with positive follow-up test after false negative tests in our study were also hospitalized again , which avoid the cluster transmission or exacerbation. Therefore, the management and discharge of COVID-19 patients must involve both nucleic acid testing combined with timely and accurate chest CT [7, 18].

The COVID-19 pneumonia manifests with chest CT imaging abnormalities even in asymptomatic patients, and evolves rapidly from focal unilateral to diffuse bilateral ground-glass opacities that progress to or co-exist with consolidations within 1–3 weeks. In our study, most patients with pneumonia (75.2%) met the criteria for the total volume of leisions to lung less than 50%. Moreover, 21 patients with pneumonia (9.1%) also presented with vascular enlargement, in contrast to the rate of 82.4% reported by Yan Li et al [10]. We attribute this inter-study difference to the status of our patients, in whom a negative nucleic acid test indicated that the recovery phase of COVID-19 had been reached. We speculate that vascular dilatation may be predictive of the short-term prognosis of patients with COVID-19 and suggest the need for a large-scale validation study of this deduction.

Our study had several limitations of note. First, the square cabin hospital is a temporary hospital. Accordingly, the populations of medical workers and patients change rapidly, and therefore the change of COVID-19 pneunonia on chest CT couldn’t be evaluated by DL due to the lack of data of baseline chest CT. Secondly, further study should be operated to evaluate the value of density variation of pneumonia detected by DL, which might benefit the doctor for managing the process of diseases.

In conclusion, DL enables the accurate management and discharge of COVID-19 patients quantitatively and further medical isolation is needed for COVID-19 patient with total volume of lesions to lung more than and equal to 50%, which can help avoid cluster transmission or exacerbation.Therefore the model presented by the “square cabin” hospital enabled optional management.

Abbreviations

DL= deep learning; COVID-19= coronavirus disease 2019; SARS-CoV= severe acute respiratory syndrome coronavirus; AI= artificial intelligence; LDCT= low-dose computed tomography; 3D-DCNN = three-dimensional deep convolutional neural network; IOU= intersection over union;

Declarations

Funding: This research did not receive any specific grant from funding agencies in the public, commercial, or not-for-profit sectors.

Competing interests: The authors declare no competing interests.

References

1. Perlman S. Another decade, another coronavirus. N Engl J Med. 2020 Feb 20;382(8):760-762. Richman DD, Whitley RJ, Hayden FG, eds. Clinical virology, 4th Washington: ASM Press; 2016.
2. Zhu N, Zhang D, Wang W, Li X, Yang B, Song J, et al. A novel coronavirus frompatients with pneumonia in China, 2019. N Engl J Med. 2020 Feb 20; 382 (8):727-733.
3. Huang C, Wang Y, Li X, et al. Clinical features of patients infected with 2019 novel coronavirus in Wuhan, China. Lancet. 2020 Feb 15;395(10223):497-506.
4. Wang D, Hu B, Hu C, et al. Clinical Characteristics of 138 Hospitalized Patients With 2019 Novel Coronavirus-Infected Pneumonia in Wuhan, China. JAMA. 2020, Feb 7 [Online ahead of print] (available on 2020-08-07)
5. National Health Commission of the People's Republic of China website. Diagnosis and treatment of novel coronavirus infection (trial version6). nhc.gov.cn/yzygj/s7653p/202002/8334a8326 dd94d329df351d7da8aefc2.shtml. Published February 18, 2020. Accessed February 19, 2020.3.12
6. Yan Li, Liming Xia. Coronavirus Disease 2019 (COVID-19): Role of Chest CT in Diagnosis and Management. AJR Am J Roentgenol 1-7 2020 Mar 4[Online ahead of print].
7. Kong B, Wang X, Bai J, et al. Learning tree-structured representation for 3D coronary artery Computerized Medical Imaging and Graphics 2020, 80: 101688.
8. Ye H, Gao F, Yin Y, et al. Precise diagnosis of intracranial hemorrhage and subtypes using a threedimensional joint convolutional and recurrent neural network. European Radiology, 2019, 29: 6191–6201.
9. Lin Li, Lixin Qin, Zeguo Xu et al. Artificial Intelligence Distinguishes COVID-19 from Community Acquired Pneumonia on Chest CT. Radiology 2020, [Online ahead of print]
10. Ren S, He K, Girshick R, Sun J. Faster R-CNN: Towards Real-Time Object Detection with Region Proposal Networks. IEEE Trans Pattern Anal Mach Intell. 2017 Jun;39(6):1137-1149.

11. Ding, A. Li, Z. Hu, L. Wang, Accurate pulmonary nodule detection in computed tomography images using deep convolutional neural networks, in: M. Descoteaux, L. Maier-Hein, A. Franz, P. Jannin, D.L. Collins, S. Duchesne (Eds.), International conference on Medical Image Computing and Computer-Assisted Intervention. Springer, Cham, 2017, pp. 559–567.
12. Ronneberger O, Philipp F, Thomas B. U-net: Convolutional networks for biomedical image segmentation. International Conference on Medical Image Computing and Computer-Assisted Intervention. Springer, Cham,2015.
13. Tian, S;Hu, W;Niu, L;Liu, H;Xu, H;Xiao, SY. Pulmonary pathology of early phase 2019 novel coronavirus (COVID-19) pneumonia in two patients with lung cancer. J Thorac Oncol, 2020 Feb 27 [Online ahead of print] .
14. Xu Z, Shi L; Wang Y, Zhang J, et al.Pathological findings of COVID-19 associated with acute respiratory distress syndrome. Lancet Respir Med. 2020 Feb 18:S2213-2600(20)30076-X. [Online ahead of print]
15. David M Hansell, Alexander A Bankier, Heber MacMahon, et al. Fleischner Society: glossary of terms for thoracic imaging . 2008 Mar;246(3):697-722.
16. S Rajaraman, S Candemir, Z Xue,et al. A Novel Stacked Generalization of Models for Improved TB Detection in Chest Radiographs. Conf Proc IEEE Eng Med Biol Soc, 2018, 718-721.
17. Heshui Shi, Xiaoyu Han, Nanchuan Jiang, et al. Radiological Findings From 81 Patients With COVID-19 Pneumonia in Wuhan, China: A Descriptive Study. Lancet Infect Dis 2020 Feb 24[Online ahead of print]

Tables

Table 1: Initial CT Findings of 270 Patients With Coronavirus Disease (COVID-19)	
CT findings	No (%) of patients
Normal	57(21.1)
Pneumonia	213(78.9)
Interstitial fibrosis	
Mild	100(46.9)
Moderate	15(7.0)
Lesion range	
One lobe	16(7.5)
Two lobe	31(14.6)
Multiple lobe	166(77.9)
Lesion distribution	
Peripheral zone	136(63.8)
Central zone	2(0.9)
Diffusion diatribution	75(35.2)
Vascular enlargement	21(9.9)
Thicken pleura	33(15.5)
Nodule	4(1.9)
Mediastinal lymphadenopathy	4(1.9)
Abbreviation: COVID-19= Coronavirus disease 2019; CT=computed tomography	

Figures

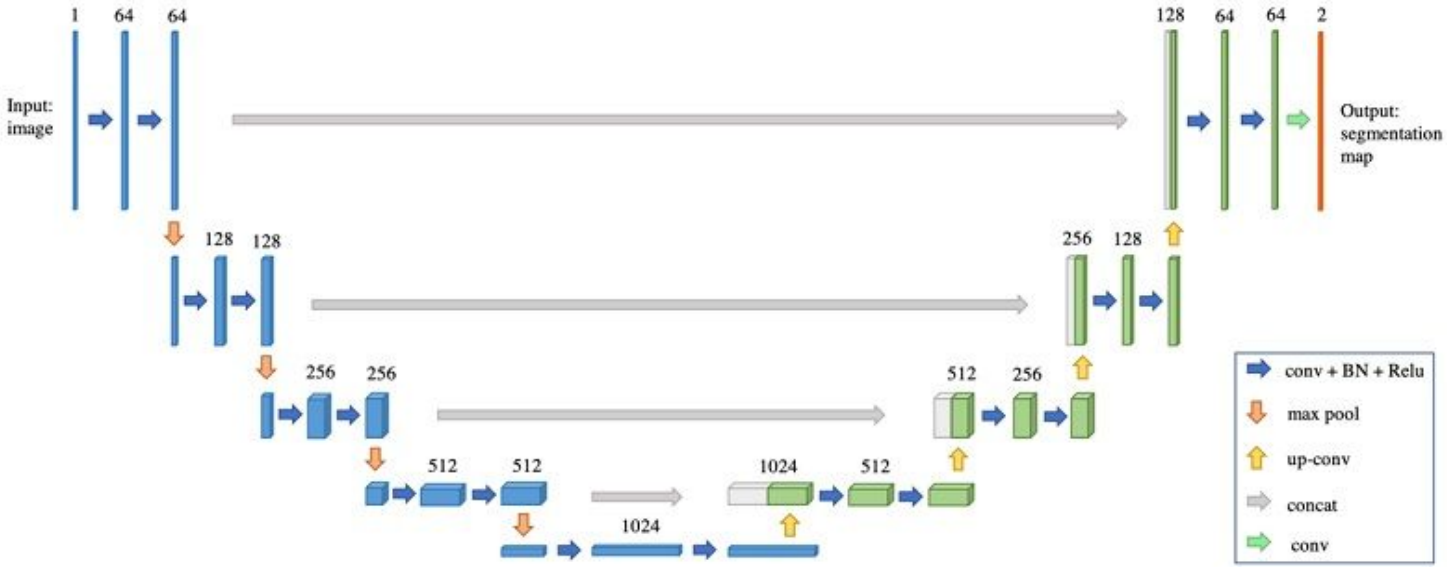

Figure 1

Unet architecture, the boxes represent feature map consist of multi channels, the number of channels in each layer is on the top of each box. The arrows colored by three colors corresponds to three kinds of convolutional operation which can be found on the right bottom of the figure.

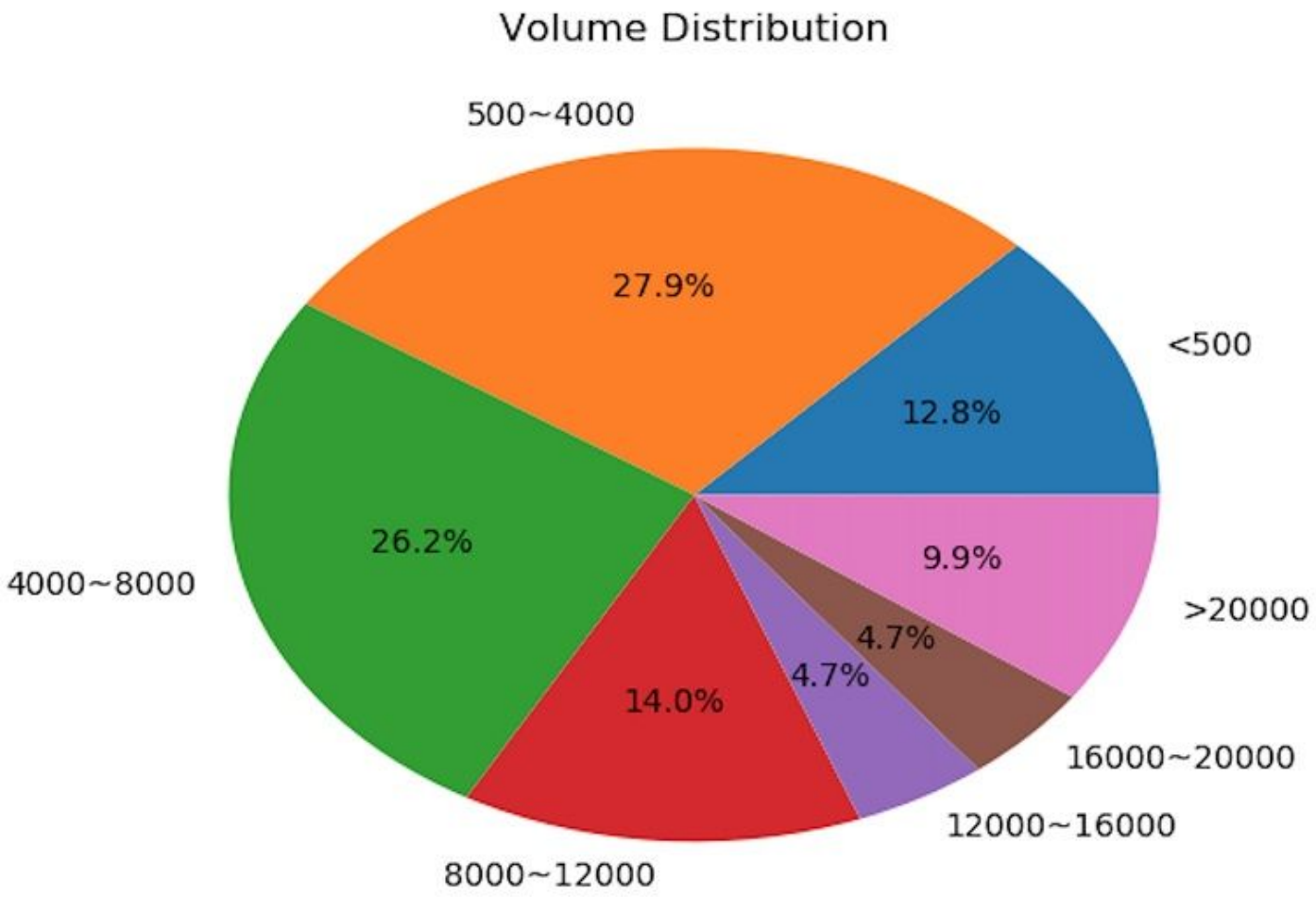

Figure 2

Volume distribution for all lesions

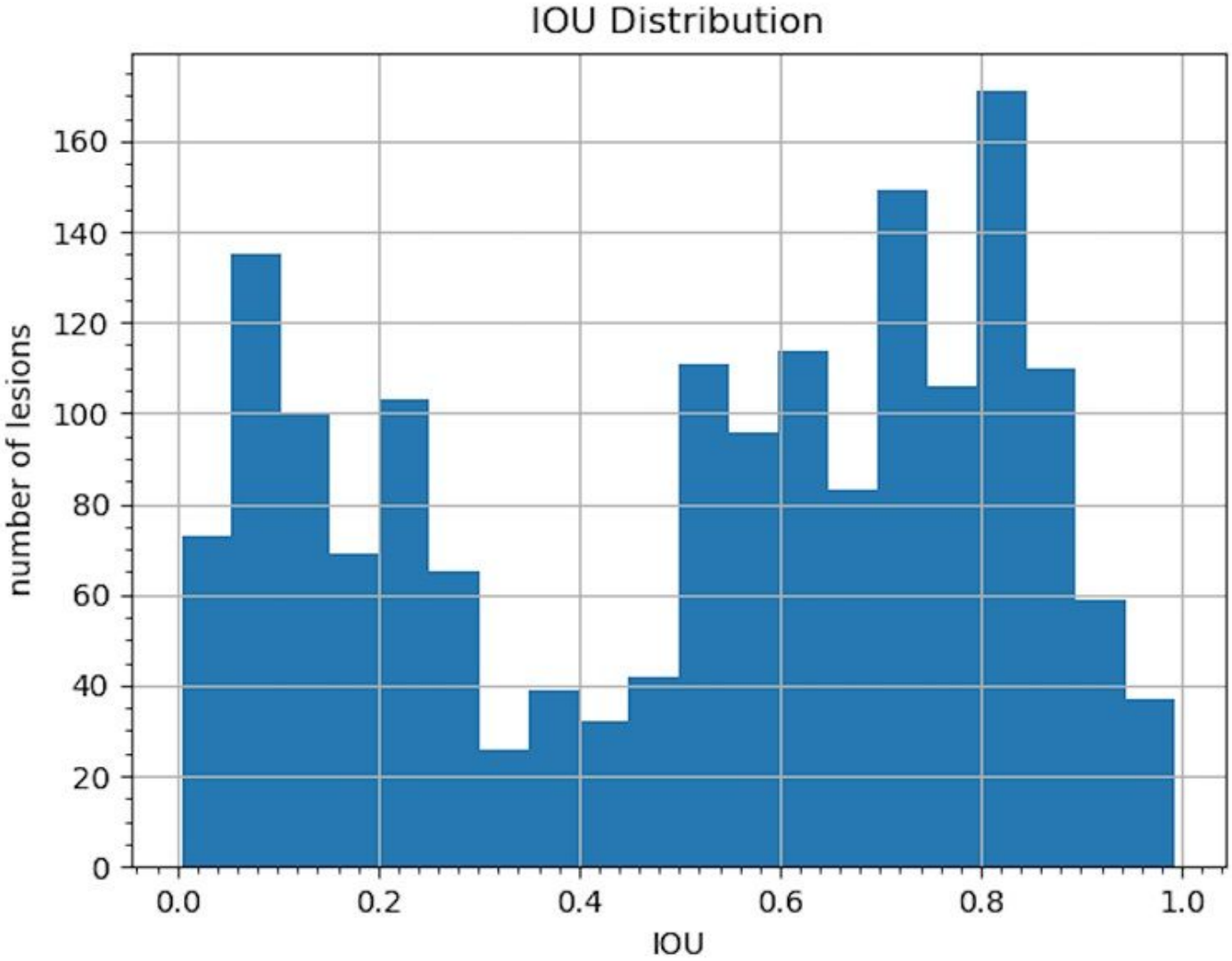

Figure 3

IOU distribution for all lesions. As we can see in this figure, there are two peaks in this distribution, that means most predictions may have high IOU value or very low IOU value, it is because, part of COVID-19 lesions are GGO, which are hard for both radiologist and AI system to find the margin.

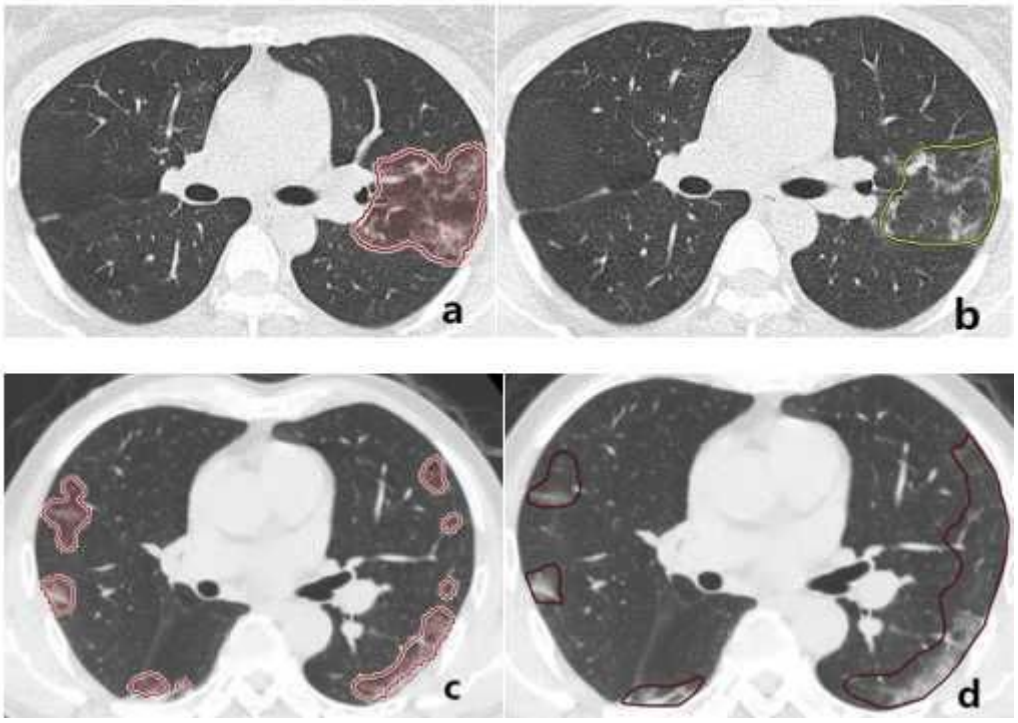

Figure 4

Predict results of the AI system. a,c: prediction, b,d: label by radiologist

Figure 5

This was the working model of DL on chest CT in a forty-nine years old women, and the total volume ratio of leisions to lung was more than 95% shown upper of right display Tab, and the three-dimensional diaplay and the density of lesions were also shown in the middle and the inferior of right Tab. So this COVID-19 patients was hospitalized again and presented with a positive nucleic acid test again.